

Urethral duplication in a dog: case report

[*Duplicação uretral em cão: relato de caso*]

R. Stedile, E.A. Contesini, S.T. Oliveira, C.A.C. Beck, E.C. Oliveira, M.M. Alievi,
D. Driemeie, M.S. Muccillo

Faculdade de Veterinária - UFRGS
Av. Bento Gonçalves, 9090
91540-000 – Porto Alegre, RS

ABSTRACT

A male Brazilian Fila dog was referred because of a perineal orifice with urine stream during micturition. To determine the extent of the accessory channel, a contrasted retrograde urethrocytography was performed. A surgical correction was undertaken. Histological study showed the presence of the urethral channel lined by multilayer transitional epithelium. The patient recovered well and there was no evidence of complications one year after surgery.

Keywords: dog, urethra, surgery, urinary, micturition

RESUMO

Um cão macho da raça Fila brasileiro foi atendido por apresentar, durante a micção, presença de jato de urina em orifício na região perineal. Uretrocistografia retrógrada contrastada foi realizada para determinar o trajeto do canal acessório. Fez-se a remoção cirúrgica da comunicação uretrocutânea. A avaliação histológica demonstrou a presença de um canal uretral revestido por epitélio de transição composta de várias camadas. O paciente teve boa recuperação, e após um ano, não havia apresentado complicações.

Palavras-chave: cão, uretra, cirurgia, urinário, micção

INTRODUCTION

Urethral duplication is a rare congenital anomaly in humans and other animals (Duffey et al., 1998), and it is unique to males (Haleblian et al., 2006). The embryologic alteration of urethral duplication is not clear, although several theories were proposed to explain the condition (Erdil et al., 2003).

Complete duplication, in humans, is defined as two urethras originating from the neck of the bladder that separate the external openings. Incomplete duplication may or may not originate from the neck of the bladder, and may not have an external opening. Incomplete urethral duplications are more common than complete

duplications in man (Duffey et al., 1998). Perineal urethral duplication is considered extremely rare in humans. In these cases, an accessory urethra originates from the primary urethra, and it possesses a perineal opening (Wagner et al., 1996).

Generally, in human medicine, urethra duplication is classified according to Effmann et al. (1976). According to this classification, the anomalies are distributed into three groups (or types). Type I is incomplete urethral duplication; Type II is complete patent urethral duplication (subtype IIA1 arises from separate bladder neck, Type IIA2 or Y type divides at the level of the posterior urethra, and type IIB refers to two urethra uniting into a common channel distally); and Type III is complete bladder duplication.

Recebido em 13 de julho de 2007

Aceito em 25 de março de 2008

E-mail: stediler@gmail.com

Also, this anomaly is classified into epispadiac, hipospadiac, spindle urethra, and Y duplication. Y duplication has two forms: usual, when the primary urethra is hypoplastic and nonfunctioning – so urine passes through the dominant accessory urethra; and unusual, when the orthotopic urethra is normal (Gupta et al., 2000; Arda and Hiçsonmez, 2002). Most human patients with urethral duplication are asymptomatic or complain only of a double urinary stream, although incontinence, dysuria, recurrent infection (Erdil et al., 2003), and perineal abscess may be observed (Arda and Hiçsonmez, 2002).

Only few reports of urethral duplication in dogs were found in the literature (Osborne et al., 1975; Tobias and Barbee, 1995; Duffey et al., 1998). Duffey et al. (1998) observed incontinence, nocturia, and swellings ventral and lateral to the prepuce in a dog that presented incomplete urethral duplication. Tobias and Barbee (1995) also described a urethral duplication in a miniature poodle, which presented other associated anomalies such as urethrorectal fistula, urethroperineal fistula, and caudal lumbar vertebral fusion. These authors continued to report clinical signs in this dog as urine scald, cystitis, hematuria, urolithiasis, and diarrhea; however, they believed that those signs were related to other urethral abnormalities, and not with urethral duplication. In this case, the surgical procedure for urethral duplication was considered unnecessary.

It was not found to possess specific classification for urethral duplication in animals. The purpose of this report is to describe a case of urethral duplication and its management in a male Brazilian dog.

CASE REPORT

A 16-month-old sexually intact male Brazilian Fila dog was referred to the veterinary hospital of Universidade Federal do Rio Grande do Sul (Brazil) due to abnormal urination with perineal urine stream. The dog presented normal urination for the primary urethra (orthotopic), without pain manifestation or urination difficulty. On physical examination, urine scald was not observed. After the hair of the perineum had been clipped, a pinpoint opening was found in

the median perineal raphe, approximately 5cm ventral to the anus. During the inspection, the genital organs appeared anatomically normal. The dog was sedated with acetylpromazine and fentanyl intramuscularly (IM) administered and the penile urethra was catheterized. The retrograde hydropropulsion confirmed the communication between the perineal orifice and the orthotopic urethra. To determine the extent of the accessory channel, a contrasted retrograde urethrocytography was performed (Fig. 1). Abnormalities were not noticed on abdominal ultrasonography. There were no other clinical signs.

One week later, the dog was anesthetized for surgical repair of the accessory urethra. Acetylpromazine (0.05mg kg^{-1} , IM) and petidine (0.05mg kg^{-1} , IM) were administered, followed by induction of anesthesia with propofol (4.0mg kg^{-1}) intravenously. Anesthesia was maintained with isoflurane given through an endotracheal tube. Ampicilin (22.0mg kg^{-1}) was intravenously administered at induction.

The dog was placed in dorsal recumbency with the pelvic members cranially pulled. The course of accessory channel was facilitated by the introduction of a probe in the orifice. An elliptic incision was accomplished in the skin around the opening and the surrounding tissues were delicately dissected up to near the bifurcation of the urethra. The ectopic channel received double ligation with 3-0 polyglactin, and it was excised. The subcutaneous tissue was closed with 3-0 polyglactin 910 and the skin was sutured with 3-0 mononylon, using an interrupted pattern.

The postoperative contrasted retrograde urethrocytography showed the absence of communication between urethra and skin; radiographic image demonstrated a remnant small channel of approximately 1cm from the primary urethra. The patient recovered well, and one year following surgery there was no evidence of complications.

Histological study of the removed segment showed the presence of the urethral channel lined by multilayer transitional epithelium, lamina propria with connective tissue, several vessels, and it was surrounded by muscular fibers (Fig. 2).

DISCUSSION

Contrary to the findings by Osborne et al. (1975), Tobias and Barbee (1995), and Duffey et al. (1998), the dog in this present report did not have complications associated with urethral duplication, and the owner opted for surgical treatment to correct the defect.

The owner had not located the perineal ostium, and only after the hair perineal clipping, it was possible to observe the perineal orifice. There were no dermatitis signs near the orifice. Catheterization of the primary urethra and retrograde hydropropulsion were useful to verify the communication of the primary and accessory urethras; however, radiographic examination was necessary to delimitate the origin and the route. A contrasted retrograde urethrocytography was performed to aid the diagnosis and surgical decision. It confirmed the course of both channels and the absence of stenosis in the orthotopic urethra. Contrasted radiographic examination of the urethra showed the orthotopic urethra appropriately, similar to the study of Haleblian et al. (2006) in human beings. Effmann et al. (1976) believed that the retrograde urethrocytography has an inestimable value in the clinical evaluation.

Wagner et al. (1996) considered that to classify these structures as fistulas instead of urethral duplication could be an incorrect denomination, because the presence of the transitional cells epithelium lining the tract is very supportive of a true urethral duplication, and one would expect a fistula to be lined with squamous epithelium. The presence of transitional cells with lamina propria of the removed fragment of the dog of the present case differs from an urethrocutaneous fistula (Fig. 2). Osborne et al. (1975) reported two cases of urethrorectal communication in dogs with distinct histological presentations among them; in one of these dogs, the lumen of the removed segment was recovered by transitional epithelium rounded by connective and muscular tissues, and the authors classified both as congenital urethral fistula. The dog presented a channel similar to the dog of this case report, with the bifurcation originating caudal to the prostate, but with anal opening. The authors believe that the case described by Osborne et al.

(1975) was also a case of urethral duplication due to its histological characteristics.

According to Ottoni et al. (2006), some types of urethral duplication in human beings are often followed by other malformations such as bladder exstrophy, hypospadias, epispadias, and cryptorchidism. Tobias and Barbee (1995) also observed associated anomalies in a dog such as urethrorectal and urethroperineal fistulas, and caudal lumbar vertebral fusion. However, in the case of the dog in the current report, associated malformations were not observed.

The classification for dogs that is suggested by the authors is based on a classification for human beings described by Effmann et al. (1976). According to this system, the case reported here described would be classified as Type II A2 (Y duplication), that is, a complete patent duplication with two meatus, with the second channel originating from the first and courses independently into a second meatus. As well as for urethral duplication, this classification could be used for cases of urethral fistulae, making it possible to standardize the descriptions of this anomaly in dogs (Fig. 3).

Typically, the orthotopic urethra is stenotic in human beings; so, the functional urethra is the accessory one. Cases of normal orthotopic urethra are rare (Arda and Hiçsonmez, 2002). The classification as urethral duplication is controversial, because according to Bates and Lebowitz (1995), when the primary urethra is functional, the channel should be denominated as congenital urethral fistula, and not as urethral duplication. Nevertheless, the authors believe that the classification should be based on the histological aspects of the accessory urethra.

Excision of the accessory channel is generally adequate for the correction, since the orthotopic urethra could be normal (Gupta et al., 2000). The perineal approach was described for the treatment of urethrorectal fistula in dogs by Ralphs and Kramek (2003), and this was the selected approach to correct the urethral duplication of the dog reported in this study, allowing an adequate visualization of the structures and removal of the accessory urethra.

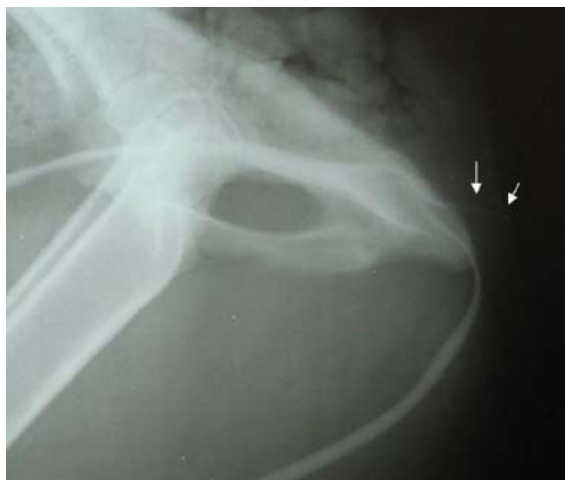

Figure 1. Retrograde urethrogram in a dog showing a normal distal urethra and an accessory urethra (arrows).

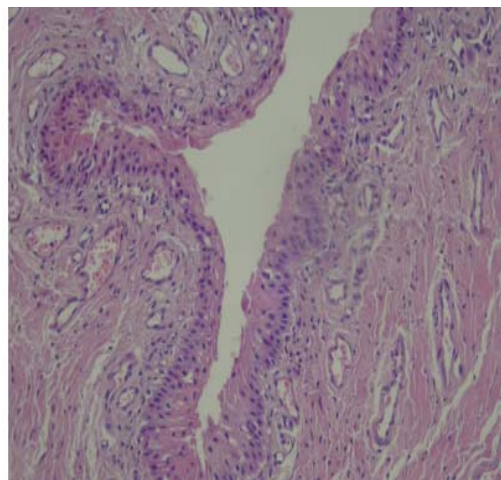


Figure 2. Histological aspect of the canine accessory urethra. The urethral lumen is lined by multilayered transitional epithelium, lamina propria with connective tissue, and abundant vessels surrounded by muscular fibers.

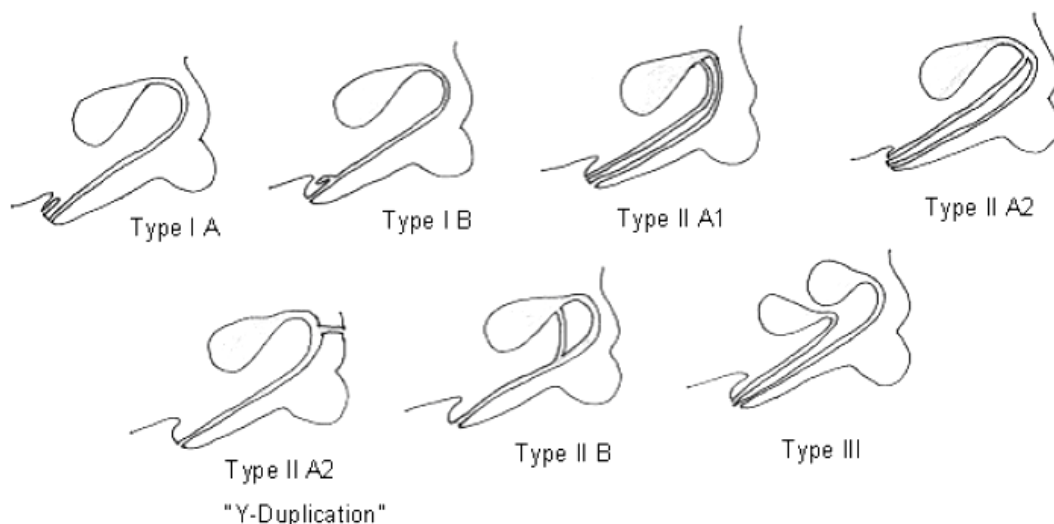


Figure 3. Classification of urethral duplication in dogs, based on the classification in human beings proposed by Effmann et al. (1976). Type I A: opens on the dorsal or ventral surface of penis but does not communicate with the urethra or bladder; Type I B: accessory urethra arises from the orthotopic urethra, but there is an incomplete duplication that ends blindly; Type II A1: complete urethral duplication arising independently from the bladder; Type II A2: complete urethral duplication with the accessory urethra arising from the orthotopic urethra; Type II A2 "Y Duplication": complete urethral duplication, in which the accessory urethra opens into the perineum or rectum arising from orthotopic urethra; Type II B: two urethras arising from the bladder or a distal urethral duplication with one meatus; Type III: complete duplication of bladder and urethra.

CONCLUSIONS

Urethral duplication is rare in dogs, and the contrasted radiography of the urinary tract is

very useful to delimitate the urethral channel. The perineal approach was satisfactory for the correction of the defect. The histological evaluation permitted to differentiate fistula from

urethral duplication. The prognosis of perineal urethral duplication with normal orthotopic urethra in dogs without other anomalies is good.

REFERENCES

- ARDA, J.S.; HIÇSONMEZ, A. An unusual presentation of Y-type urethral duplication with a perineal abscess: case report. *J. Ped. Surg.*, v.37, p.1213-1215, 2002.
- BATES, D.G.; LEBOWITZ, R.L. Congenital urethroperineal fistula. *Radiology*, v.194, p.501-504, 1995.
- DUFFEY, M.H.; BARNHART, M.D.; BARTHEZ, P.Y. et al. Incomplete urethral duplication with cyst formation in a dog. *J. Am. Vet. Med. Assoc.*, v.213, p.1287-1289, 1998.
- ERDIL, H.; MAVI, A.; ERDIL, S. et al. Urethral duplication. *Acta Med. Okayama*, v.57, p.91-93, 2003.
- EFFMANN, E.L.; LEBOWITZ, R.L.; COLODNY, A.H. Duplication of the urethra. *Radiology*, v.119, p.179-185, 1976.
- GUPTA, N.P.; ANSARI, M.S.; ARON, M. et al. Y duplication of urethra with complete atresia of the orthotopic channel: 1-stage reconstruction. *J. Urol.*, v.163, p.949-950, 2000.
- HALEBLIAN, G.; KRAKLAU, D.; WILCOX, D. et al. Y-type urethral duplication in the male. *Br. J. Urol.*, v.97, p.597-602, 2006.
- OSBORNE, C.A.; ENGEN, M.H.; YANO, B.L. et al. Congenital urethrorectal fistula in two dogs. *J. Am. Vet. Med. Assoc.*, v.166, p.999-1002, 1975.
- OTTONI, M.L.; DORNAS, M.C.; RUBSTEIN, I., et al. Duplicação uretral em homem adulto. *Rev. Col. Bras. Cirurg.*, v.33, p.336-338, 2006.
- RALPHS, S.C.; KRAMEK, B.A. Novel perineal approach for repair of an urethrorectal fistula in a bulldog. *Can. Vet. J.*, v.44, p.822-823, 2003.
- TOBIAS, K.S.; BARBEE, D. Abnormal micturition and recurrent cystitis associated with multiple congenital anomalies of the urinary tract in a dog. *J. Am. Vet. Med. Assoc.*, v.207, p.191-193, 1995.
- WAGNER, J.R.; CARR, M.C.; BAUER, S.B. et al. Congenital posterior urethral perineal fistulae: a unique form of urethral duplication. *Urology*, v.48, p.277-280, 1996.