

# Successful treatment of terbinafine in a case of sporotrichosis

## Sucesso terapêutico da terbinafina em um caso de esporotricose

Daiane Heidrich<sup>1</sup>  
Luciana Senter<sup>3</sup>  
Patricia Valente<sup>5</sup>

Cheila Denise Ottonelli Stopiglia<sup>2</sup>  
Gerson Vettoratto<sup>4</sup>  
Maria Lúcia Scroferneker<sup>6</sup>

**Resumo:** A esporotricose é uma infecção subaguda ou crônica, causada por fungos pertencentes ao Complexo *Sporothrix*. Relato do caso: esporotricose de localização nasal foi tratada com iodeto de potássio e como não se obteve sucesso, reiniciou-se o tratamento com associação de iodeto de potássio e itraconazol. Porém, ocorreu nova recidiva. As culturas dos exames micológicos foram submetidas a ensaios de atividade antifúngica *in vitro* para auxiliar no tratamento. A terbinafina foi o antifúngico que apresentou melhores resultados, por isso, o tratamento foi reiniciado com este antifúngico e, após dois anos do término do mesmo, não recidivou. Adicionalmente, ambas as culturas foram comparadas por RAPD, obtendo padrões de fragmentos distintos, indicando que os isolados são diferentes ou demonstrando um processo microevolutivo do microrganismo.

**Palavras-chave:** Antimicóticos; Esporotricose; Micoses; Sporothrix; Testes de sensibilidade a antimicrobianos por disco-difusão; Testes de sensibilidade microbiana

**Abstract:** Sporotrichosis is a chronic subacute infection caused by fungi belonging to the *Sporothrix* Complex. In the present clinical case, nasal sporotrichosis was treated with potassium iodide. This was unsuccessful, and the treatment was restarted with a combination of potassium iodide and itraconazole. This however resulted in a further recurrence of the infection. The mycological cultures were tested *in vitro* for antifungal activity to assist in treatment. Terbinafine, an antifungal drug, produced the best results and was therefore used for the rest of the treatment course, with no recurrence after two years of its completion. In addition, both cultures were compared using RAPD and different fragment patterns were observed. This indicated that the isolates were either different or indicated a microevolutionary process of this microorganism.

**Keywords:** Antifungal agents; Disk diffusion antimicrobial tests; Microbial sensitivity tests; Mycoses; Sporothrix; Sporotrichosis

Received on 15.12.2010.

Approved by the Advisory Board and accepted for publication on 22.1.11.

\* Study undertaken at the Human Pathogenic Fungi Laboratory, Institute of Basic Health Sciences, Federal University of Rio Grande do Sul (UFRGS), Porto Alegre, Brazil.

Conflict of interest: None / *Conflito de interesse: Nenhum*

Financial funding / *Suporte financeiro:* The authors are grateful for the financial support provided by the National Council for Scientific and Technological Development (CNPq), Coordinating Bureau for the Improvement of Higher Education Personnel (CAPES) and the Rio Grande do Sul Foundation for Research Support (FAPERGS)

<sup>1</sup> Degree in Pharmacy. MA student of the Post-Graduate Program in Medicine/Medical Sciences, Federal University of Rio Grande do Sul (UFRGS), Porto Alegre, Brazil.

<sup>2</sup> Degree in Pharmacy, specializing in clinical analysis.

<sup>3</sup> MA in Agricultural and Environmental Microbiology. CAPES Fellow. PhD student in the Agricultural and Environmental Microbiology Graduate Program, Federal University of Rio Grande do Sul (UFRGS), Porto Alegre, Brazil.

<sup>4</sup> MD. Dermatologist at the Santa Casa de Misericórdia de Porto Alegre Hospital, Porto Alegre, Brazil.

<sup>5</sup> PhD in Biological Sciences (Genetics). Associate Professor, Department of Microbiology, Immunology and Parasitology, teaches in the Post-Graduate Programs of Agricultural and Environmental Microbiology and Cellular and Molecular Biology, Federal University of Rio Grande do Sul (UFRGS), Porto Alegre, Brazil.

<sup>6</sup> Ph.D. in Biological Sciences (Microbiology and Immunology). Associate Professor, Department of Microbiology, teaches in the Post-Graduate Medicine/Medical Sciences Program and is Chairperson of the Medical Immunology Program, Federal University of Rio Grande do Sul (UFRGS), Porto Alegre, Brazil.

©2011 by Anais Brasileiros de Dermatologia

## INTRODUCTION

Sporotrichosis is a subacute or chronic infection caused by fungi belonging to the Sporothrix Complex: *S. schenckii*, *S. brasiliensis*, *S. Mexicana*, *S. globosa* and *S. albicans*. Sporotrichosis occurs all over the world, mainly in tropical and temperate climates. The highest number of cases of subcutaneous mycosis is found in the Brazilian state of Rio Grande do Sul.<sup>2</sup> The infection is normally caused by traumatic inoculation of the fungus into the skin or subcutaneous tissues, and can be either confined to the puncture point or reach the regional lymphatic system. It could even spread through the bloodstream causing systemic infection. Extracutaneous sporotrichosis is however a rare condition, affecting immunocompromised patients almost exclusively.<sup>3</sup>

The treatment of choice for sporotrichosis while still at the skin lesion stage is systemic chemotherapy with potassium iodide.<sup>4</sup> In its disseminated cutaneous forms, and with recurrent, extracutaneous and lymphocutaneous infections, amphotericin B is the most effective drug. Intolerance to iodine and the high toxicity of amphotericin B are however factors that often limit their use.<sup>5</sup> Recent years have seen the increased use of azoles (including ketoconazole, itraconazole and fluconazole) as a therapeutic alternative to the "classic" schemes, with itraconazole the most effective.<sup>6,7</sup> On the other hand, terbinafine, in view of its high activity *in vitro* and *in vivo*, is now being used to treat various fungal infections, although clinical experience with this drug for treating sporotrichosis is fairly limited.<sup>8</sup>

In this study we report a case of localized nasal sporotrichosis in which the strains isolated in the mycological culture were tested *in vitro* for antifungal activity to assist treatment. Molecular markers were also employed to conduct comparative analysis of the isolates.

## CASE REPORT

A 65-year-old diabetic craftswoman sought medical assistance at the Dermatology Department in August 2006, presenting a nasal nodular lesion after undergoing cauterization for a nasal polyp. Test results indicated a chronic pathological ulcerated inflammation with granulation tissue, but with no presence of fungal structures. Four days later a biopsy was performed of the site. Part of the material was subjected to mycological culture. Culture was done using Sabouraud agar incubated at 25 °C for seven days. Subsequently we conducted the phenotypic characterization in accordance with Marimon *et al.* (2007)<sup>1</sup>, which identified the pathogenic fungus *Sporothrix schenckii*. Initial treatment consisted of twenty drops of potassium iodide (KI) three times a day for three months until the lesion was

cured and treatment discontinued. Four months later, however, the patient presented again with the lesion, which was submitted again to mycological culture followed by phenotypic characterization. On that occasion the pathogen was identified as *Sporothrix* spp. A new treatment was started with KI (25 drops, 3 times a day) combined with itraconazole (200 mg/day). After 11 months of treatment the lesion appeared to have healed. The patient nevertheless returned to the hospital two months later with a new recurrence. A further mycological culture followed by phenotypic characterization confirmed the presence of *Sporothrix schenckii*. We then requested an antifungal activity test according to protocol M38-A2 of the *Clinical and Laboratory Standards Institute* (CLSI).<sup>9</sup> We used two isolates, one before treatment (the first) and one after the two treatments (the second), without success. The antifungal agents assessed were itraconazole, ketoconazole, fluconazole and terbinafine, in concentrations of between 0.25 and 128 µg/mL for fluconazole, 0.01 and 8 µg/mL for terbinafine and 16 and 0.03 µg/mL for itraconazole and ketoconazole. In the tests we included an antifungal control (growth control) and a microorganism-free control (sterility control). Determination of the minimum inhibitory concentration (MIC) was done visually by comparison with the growth control. The MIC was defined as the lowest drug concentration capable of completely inhibiting fungal growth for itraconazole and terbinafine and 50% growth for fluconazole and ketoconazole. All tests were performed in triplicate.

The profiles of antifungal activity *in vitro* for both strains of *S. schenckii* are shown in Table 1. The first isolate showed greater sensitivity to antifungal agents than the second, but both were more sensitive to terbinafine. As a result this drug was chosen to restart the treatment of the patient with a dosage of 500 mg/day for five months. Two years after the treatment ended no relapses were reported.

The DNA of the isolates was extracted by the *Power Soil DNA Isolation Kit* (MO BIO Laboratories) and subjected to *Random Amplified Polymorphic DNA* (RAPD), using the *primers* OPG-10, OPG-14 and OPG-19 (Prodimol Biotechnology SA, Brazil), with the components and amplification conditions according to Landell *et al.*<sup>10</sup> Polymorphic amplified patterns were subjected to electrophoresis on 1% agarose gel at 60 V for 90 minutes, followed by transluminator visualization under ultraviolet light. The two strains showed different fragment patterns when the *primer* OPG-10 was used. However, with the *primer* OPG-19 we observed two bands of the same molecular weight. No fragment was observed when using *primer* OPG-14 (Figure 1).

**TABLE 1:** Profile of the antifungal susceptibility to both strains of *S. schenckii*

Antifungals	MIC ( $\mu\text{g/mL}$ )	
	1 <sup>st</sup> strain	2 <sup>nd</sup> strain
Itraconazole	0.25	16.0
Cetoconazole	0.25	2.0
Fluconazole	32.0	64.0
Terbinafine	0.03	0.12

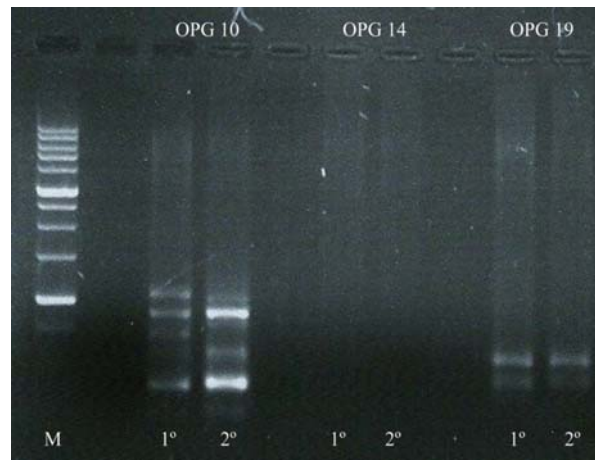
## DISCUSSION

Fungal infections are among the most common dermatological conditions affecting elderly people. A number of factors contribute to the increased prevalence of these infections in the elderly, including decreased skin barrier function, reduction of the functional capacity of the immune system of cells and the occurrence of diseases such as diabetes that inhibit scarring.<sup>11,12</sup>

In the dermis, and occasionally in the subcutaneous tissue, *S. schenckii* causes *sporotrichosis nodules* that may be confused with neoplasms.<sup>3</sup> The origin of the sporotrichosis in the present study case may be related to this or be a result of contamination after the cauterization of the patient's nasal polyps, which would provide a gateway for the fungus to enter.

The absence of fungal structures in our pathological examination was due to the *S. schenckii* yeasts being fairly sparse and difficult to observe. In this respect they are rarely found on direct examination and require cultivation of the isolate to diagnose the disease.<sup>3</sup> Moreover, the mycological culture was needed because the presence of nodules tending to ulceration is a common feature of so-called sticky mycoses, which are mainly caused by *S. schenckii* and, less frequently, by other types of fungi such as *Aspergillus* spp.<sup>3</sup>

The strains tested showed sensitivity profile to antifungal agents similar to the study of Marimon *et al.*<sup>13</sup> being more sensitive to terbinafine, followed by ketoconazole and itraconazole. In addition, they were resistant to fluconazole, as has been described by other authors.<sup>8,10,14</sup> The failure of therapy with itraconazole may be due to acquired resistance by the organism to the drug after treatment with this antifungal and/or even by the reduction of the production of gastric juice which often occurs in the elderly, reducing the bioavailability of the drug and thus its inability to reach the serum concentration needed to fight the fungus.<sup>9</sup> Thus, terbinafine is presented as an antifungal agent of choice for use in elderly patients com-



**FIGURE 1:** Fragments de DNA obtained by RAPD. Ladder molecular weight marker (M), the first and second strains amplified with OPG-10, the first and second with OPG-14 and the first and second with OPG-19

pared with itraconazole, since terbinafine is not influenced by gastric pH and presents fewer interactions with other drugs.<sup>12</sup>

The difference in the genotypic profile observed raises two assumptions: first, that the two strains are different, indicating that the fungal infection had been cured after treatment and that re-infection occurred, or (secondly) that the patient had been initially infected with two strains of *S. schenckii*. This hypothesis seems unlikely. Observing the genotypic profile obtained by the three *primers*, only with one of them (OPG-10) were small differences obtained. This leads us to venture the more probable hypothesis that the fungus could have undergone a microevolutionary process, with mutations occurring which caused sensitivity to antifungal agents to be reduced. Microevolution is an important factor during host colonization.<sup>15</sup> These mutations may have occurred during the treatments, since 22 months elapsed between the first and second collection. In order to elucidate this question it would be necessary to do the RAPD with several other *primers* or to sequence hypervariable regions in the DNA of the isolates.

Few reports exist on the correlation between *in vitro* susceptibility and therapeutic response in the treatment of sporotrichosis.<sup>8</sup> In the above reported case the test for sensitivity to antifungal agents was very important for selecting the appropriate antifungal, indicating that terbinafine is indeed a viable alternative for treating sporotrichosis. □

## REFERENCES

1. Marimon R, Cano J, Gené J, Sutton DA, Kawasaki M, Guarro J. *Sporothrix brasiliensis*, *S. globosa*, and *S. mexicana*, three new *Sporothrix* species of clinical interest. *J Clin Microbiol*. 2007;45:3198-6.
2. da Rosa AC, Scroferneker ML, Vettorato R, Gervini RL, Vettorato G, Weber A. Epidemiology of sporotrichosis: a study of 304 cases in Brazil. *J Am Acad Dermatol*. 2005;52:451-9.
3. Lacaz CS, Porto E, Martins JEC, Heins-Vaccari EM, de Melo NT. Tratado de Micologia Médica Lacaz. 9th ed. São Paulo: Sarvier; 2002. p. 479-497.
4. Coskun B, Saral Y, Akpolat N, Ataseven A, Cicek D. Sporotrichosis successfully treated with terbinafine and potassium iodide: case report and review of the literature. *Mycopathologia*. 2009;158:53-6.
5. Sterling JB, Heymann WR. Potassium iodide in dermatology: a 19th century drug for the 21st century - uses, pharmacology, adverse effects, and contraindications. *J Am Acad Dermatol*. 2000;43:691-7.
6. Meinerz ARM, Nascente PS, Schuch LFD, Cleff MB, Santin R, Brum CS, et al. Suscetibilidade in vitro de isolados de *Sporothrix schenckii* frente à terbinafina e itraconazol. *Rev Soc Bras Med Trop*. 2007;40:60-2.
7. Accioly Filho JW, Jacques CSC, Leverone AP, Oliveira JC, Mendonça IRSM, Azulay RD. Itraconazol no tratamento da esporotricose - Relato de 3 casos. *An Bras Dermatol*. 1993;68:117-9.
8. Kohler LM, Hamdana JS, Ferrari TCA. Successful treatment of a disseminated *Sporothrix schenckii* infection and in vitro analysis for antifungal susceptibility testing. *Diagn Microbiol Infect Dis*. 2007;58:117-20.
9. Clinical and Laboratory Standards Institute (CLSI). Reference method for Broth Dilution Antifungalsusceptibility testing of Filamentous Fungi, Approved Standard - 2nd ed. CLSI document M38-A2. Clinical and Laboratory Standards Institute, Wayne. 2008;28:1-52.
10. Landell MF, Stopiglia CD, Billodre RG, Heidrich D, Sorrentino JM, Vainstein MH, et al. Evaluation of the origin of a sample of *Sporothrix schenckii* that caused contamination of a researcher in southern Brazil. *Mycopathologia*. 2011;171:203-7.
11. Saeed S, Sagatys E, Wasserman JR, Morgan MB. *Geriatric Fungal Infections*. In: Norman RA, editor. *Diagnosis of aging skin diseases*. London: Springer; 2008. p.123-150.
12. Hof H. Mycoses in the elderly. *Eur J Clin Microbiol Infect Dis*. 2010;29:5-13.
13. Marimon R, Serena C, Gené J, Cano J, Guarro J. In vitro antifungal susceptibilities of five species of *Sporothrix*. *Antimicrob Agents Chemother*. 2008;52:732-4.
14. Gutierrez-Galhardo MC, Zancopé-Oliveira RM, Monzón A, Rodriguez-Tudela JL, Cuenca-Estrella M. Antifungal susceptibility profile in vitro of *Sporothrix schenckii* in two growth phases and by two methods: microdilution and E-test. *Mycoses*. 2010;53:227-1.
15. Fleischhacker M, Pasligh J, Moran G, Ruhnke M. Longitudinal genotyping of *Candida dubliniensis* isolates reveals strain maintenance, microevolution, and the emergence of itraconazole resistance. *J Clin Microbiol*. 2010;48:1643-0.

## MAILING ADDRESS / ENDEREÇO PARA CORRESPONDÊNCIA:

*Cheila Denise Ottonelli Stopiglia*  
*Rua Sarmento Leite, 500*  
*Laboratório 210 – Centro*  
*90050-170 Porto Alegre, RS, Brazil*  
*E-mail: cheila.dos@gmail.com*

How to cite this article/Como citar este artigo: Heidrich D, Stopiglia CDO, Senter L, Vettorato G, Valente P, Scroferneker ML. Successful treatment of terbinafine in a case of sporotrichosis. *An Bras Dermatol*. 2011;86(S1):S182-5.

*An Bras Dermatol*. 2011;86(4Supl1):S182-5.