

## Diffuse Iris Melanoma in a Cat

João Antonio Tadeu Pigatto<sup>1</sup>, Paula Stieven Hünning<sup>1</sup>, Ana Carolina da Veiga Rodarte de Almeida<sup>1</sup>, Fabiana Quartiero Pereira<sup>1</sup>, Luciana Vicente Rosa Paccico de Freitas<sup>1</sup>, Cristiano Gomes<sup>1</sup>, Fabiana Schiochet<sup>1</sup>, Grazziane Maciel Rigon<sup>2</sup> & David Driemeier<sup>1</sup>

### ABSTRACT

**Background:** Diffuse iris melanoma is rare, although is the most common primary intraocular neoplasm in cats, and is an unusual variant of anterior uveal melanoma. This neoplasm is malignant with high potential metastasized. Affects older cats without breed or sex predisposition. The diagnosis can be made with fine needle aspiration cytology of anterior segment. The treatment is variable and depends of clinical signs evolution. The enucleation is commonly indicated when occurred iridal pigment changes demonstrated as progressively increasing in size or number, or intractable uveitis or glaucoma. This work has for objectives to report a case of diffuse iris melanoma in a cat. Based on information available in the literature, this is the first case of diffuse iris melanoma in a cat documented in Brazil.

**Materials, Methods & Results:** A ten-year-old, female, domestic shorthaired cat was examined for slowly progressive hyperpigmentation of the left eye enlarging over a 1-year period. The left iris was diffusely pigmented and irregular. The pupillary light reflex and menace responses were positive in the left eye. Physical examination was normal. As complementary exams had been realized complete blood cell count and serum chemical profiles, that were unremarkable. The thoracic, abdominal, and skull radiography did not show any evidence of metastasis. The treatment was the surgically removed of the left eye. The histopathological evaluation confirmed the tumor as a malignant melanoma with diffuse involvement of the iris stroma. Two years after enucleation, the cat was clinically normal, and thoracic and abdominal radiography did not show any evidence of metastasis.

**Discussion:** The diffuse iris melanoma affects, mainly, cats than more nine years old. It typically presents as focal to diffuse iris hyperpigmentation rather than a discrete nodule or mass. In this cat, the clinical features and biological behavior were similar to other previous reports. The neoplasm has character infiltrate may lead to development of uveitis, glaucoma and metastasis in organs such as regional lymph nodes, lungs and liver. Pupillary deficits and buphtalmia may also be associated. In this case, no clinical signs other than the iris hyperpigmentation and irregularity of the iris surface was observed against of the complementary exams. The main differential diagnosis must be made of benign forms of iris hyperpigmentation secondary to chronic uveitis and iris melanosis. The diagnosis through of the fine needle aspiration cytology of anterior segment was considered, but not performed due to potential intraocular complications. The treatment of choice may depend on the tumor growth rate and the age of the patient, may be appropriate only to observe the tumor. The enucleation was indicated due to the extensive neoplastic invasion of the iris. Moreover, considering the metastatic rate of diffuse iris melanoma in cats and a long latency period of metastatic disease, the early enucleation, has been proposed by literature. After remotion of the affected eye definitive diagnosis was obtained by histopathology. The examination revealed pleomorphic spindle cells irregularly pigmented showing sometimes heavy pigmented round neoplastic cells "plump cells" and other slightly pigmented with increased mitotic figures compatible with diffuse iris melanoma. The prognosis of feline anterior uveal melanoma is poor with a high risk of metastatic diseases and a shortened life. The patient no evidenced metastasis and recurrence after two years, illustrating the importance of early diagnosis and treatment in order to avoid premature death.

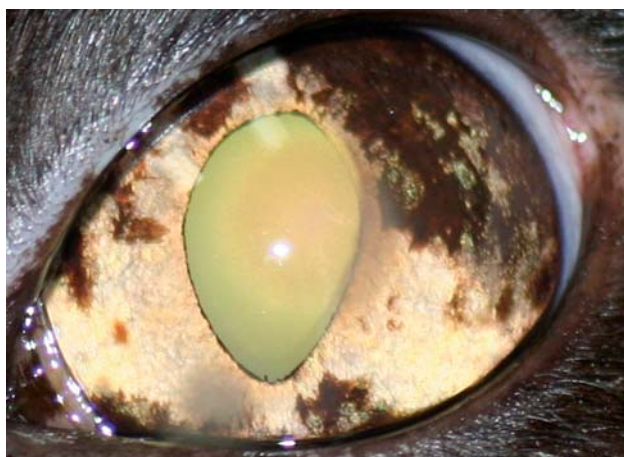
**Keywords:** feline, ocular tumor, progressive iridal hyperpigmentation.

## INTRODUCTION

Diffuse melanoma of the iris is an unusual variant of anterior uveal melanoma. The term diffuse uveal melanoma was denominated to indicate the occurrence of these tumors diffusely in the iris [1]. No breed or sex predisposition has been noted, and the average age of affected cats is 10 years at the time of diagnosis [3]. The treatment of feline uveal melanoma is variable and has to be designed for the individual patient [9]. Enucleation is commonly performed if iridal pigment changes have been demonstrated as progressively increasing in size or number, or if intractable uveitis or glaucoma has occurred [4,7]. Diffuse iris melanoma is the most common primary intraocular neoplasm in cats, although there have been few reports on diffuse iris melanoma in cats in the literature [3]. As long as we know, this is the first case of diffuse iris melanoma in a cat being reported in Brazil.

## CASE REPORT

A ten-year-old, female, domestic shorthaired cat was presented with a history of pigmentation of the left eye that had been progressively enlarging over a 1-year period. The cat was well-nourished and presented good clinical condition. Pupillary light reflex and menace responses were intact bilaterally. The right eye was visual on ophthalmic examination, while on ocular examination it was within normal limits with a yellow iris. The left iris was irregular and diffusely pigmented, particularly in the lateral portion (Figure 1). The cat had no other clinical signs. Physical examination was normal. Regional lymph nodes were not enlarged, and thoracic auscultation and abdominal palpation revealed no



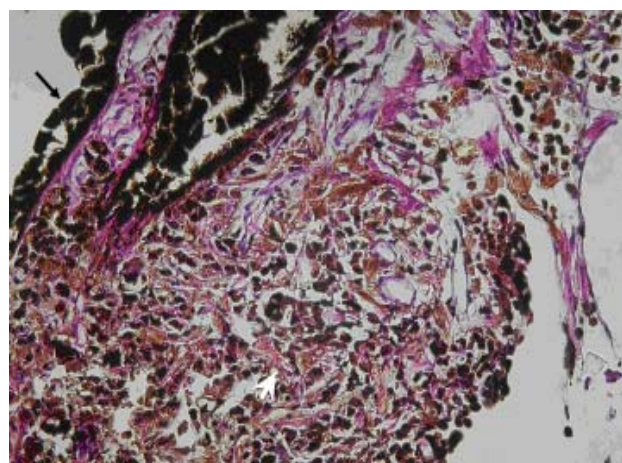
**Figure 1.** Left eye with iris diffusely pigmented.

abnormalities. Complete blood cell count and serum chemical profiles were unremarkable, and the thoracic, abdominal, and skull radiography did not show any evidence of metastasis. The left eye was enucleated and a histopathological evaluation confirmed the tumor as a malignant melanoma with diffuse involvement of the iris stroma. Besides, a histological examination revealed pleomorphic spindle cells irregularly pigmented showing sometimes heavy pigmented round neoplastic cells “plump cells” and other slightly pigmented with increased mitotic figures (Figure 2). Tumor cells invading adjacent iris epithelium and sclera. Two years after enucleation, the cat was clinically normal, and thoracic and abdominal radiography did not show any evidence of metastasis.

## DISCUSSION

Diffuse iris melanoma, although rare, has been the most common primary intraocular tumor in cats [3]. No breed or sex predisposition has been noted, and most cats are more than 9 years of age by the time of diagnosis [3]. It typically presents as focal to diffuse iris hyperpigmentation rather than a discrete nodule or mass [1]. In this case, the clinical features and biological behavior were similar to other previous reports.

Normally, diffuse melanoma of the iris is locally infiltrate, invades the intertrabecular spaces, plugs the drainage mechanism and causes glaucoma [1]. Pupillary deficits, buphtalmia and evidence of uveitis have been observed in cats with diffuse iris melanoma [8]. The cat, in our case, had no clinical signs other than the iris hyperpigmentation and irregularity of the iris surface. The diagnosis of diffuse iris melanoma is often difficult to make



**Figure 2.** Feline diffuse iris melanoma showing plump heavy pigmented cells (arrow) on the over left side and slightly pigmented pleomorphic epithelioid-to-spindle cells slightly pigmented disseminated in the iris (arrow head) [H&E, 100x].

and it is delayed because of the insidious onset and slow growth rate [6]. Chronic uveitis in cats may also be associated with a benign form of iris hyperpigmentation that is non-proliferative in appearance. A distinction among these conditions has not only been challenging but also essential. Fine-needle aspiration biopsy is a technique that may be useful in the differential diagnosis once it has been accurate with a rate of 90% in diagnosis and low risk of tumour seeding [2]. In this described case, fine needle aspiration cytology of anterior segment was considered but not performed due to potential intraocular complications [4]. In the present study, the diagnosis was confirmed on histopathology of the eye after enucleation.

The histological appearance was similar to that previously described. The main differential diagnoses are benign iris melanosis and chronic uveitis, and distinguishing these conditions by ophthalmic examination alone may be impossible. When diffuse iris melanoma is suspected, physical examination, ophthalmic examination, complete blood count and serum chemistry panel, thoracic and abdominal radiographs should be completed [3]. In this case, complete blood count and serum chemical panel were normal, and thoracic and abdominal radiographs showed no evidence of metastasis. There has been some controversy related to the best approach of treatment for cats with diffuse iris melanoma [7]. Depending on the tumor growth rate and age of the patient, it may be appropriate to observe the tumor. This is particularly suitable for older cats with other diseases that limit their life expectancy [7]. In the

present report, enucleation was indicated due to the extensive neoplastic invasion of the iris. Considering the metastatic rate of diffuse iris melanoma in cats and a long latency period of metastatic disease, the early enucleation, in affected cats, has been proposed [1,7]. Thus, when enucleation is done in the early stages of disease, while the tumor has been confined to the iris stroma, the affected cats may survive [1]. Some ophthalmologists have attempted to ablate small, focal, hyperpigmented foci on the iris of cats with a diode laser, thereby preserving their vision and their eyes [7]. However, the long-term success rate and side effects of this procedure have not been known.

Feline anterior uveal melanoma carries a guarded prognosis, with a shortened life expectancy and a high risk of metastatic disease [5]. The regional lymph nodes, liver and lungs have been the main sites for melanoma metastasis [3,8]. Our patient is still alive with no evidence of metastasis and recurrence after two years. There is a little information in the literature on the prognosis of diffuse iris melanoma in cats. Yet, there has been some suggestion that enucleation of small tumors may warrant a better prognosis than when gross distortion of the eye has occurred [7]. The better prognosis of iris lesions has been attributed to earlier detection. Hence, the treatment of the neoplasm with enucleation was successful. The present case has illustrated the importance of early diagnosis and treatment in order to avoid premature death. However, additional cases of diffuse iris melanoma in cats with long-term follow-up need to be studied to accurately assess the biological behavior of this tumor.

#### REFERENCES

- 1 Acland G.M., McLean I.W., Aguirre G.D. & Trucksa R. 1980. Diffuse iris melanoma in cats. *Journal of the American Veterinary Medical Association*. 176(1): 52-56.
- 2 Char D.H., Crawford J.B., Gonzales J. & Miller T. 1989. Iris melanoma with increased intraocular pressure. Differentiation of focal solitary tumors from diffuse or multiple tumors. *Archives of Ophthalmology*. 107(4): 548-555.
- 3 Duncan D.E. & Peiffer R.L. 1991. Morphology and prognostic indicators of anterior uveal melanoma in cats. *Progress in Veterinary and Comparative Ophthalmology*. 1: 25-32.
- 4 Gould D. 2003. Ocular tumors. In: Dobson J.M. & Lascelles B.D.X. (Eds). *Manual of Canine and Feline Oncology*. Gloucester: BSAVA, pp.329-337.
- 5 Kalishman J.B., Chappell R., Flood L.A. & Dubielzig R.R. 1998. A matched observational study of survival in cats with enucleation due to diffuse iris melanoma. *Veterinary Ophthalmology*. 1(1): 25-29.
- 6 Krohne S.G. 1998. Ocular tumors of the dog and cat. In: Morrison W.B. (Ed). *Cancer in Dogs and Cats Medical and Surgical Management*. Baltimore: Williams & Wilkins, pp.731-758.

**7 Miller P.E. & Dubielzig R.R. 1996.** Ocular tumors. In: MacEwen E.G. & Withrow S. (Eds). *Journal of Small Animal Clinical Oncology*. 2nd edn. Philadelphia: W.B. Saunders, pp.420-431.

**8 Patnaik A.K. & Mooney S. 1988.** Feline melanoma: a comparative study of ocular, oral, and dermal neoplasms. *Veterinary Pathology*. 25(2): 105-112.

**9 Willis A.M. & Wilkie D.A. 2001.** Ocular Oncology. *Clinical Techniques in Small Animal Practice*. 16(1): 77-85.