

Systematization, Description and Territory of The Middle and Rostral Cerebral Arteries in Broad-Snouted Caimans (*Caiman latirostris*)

Lygia Maria de Almeida¹ & Rui Campos²

ABSTRACT

Background: Information on the arterial vascularization of the broad-snouted caimans' brain (*Caiman latirostris*), a specie from the Brazilian fauna, is inexistent and the literature consulted yielded only one description about the development of embryonic circulation and post-birth cerebrovascular alterations in the brain of three caymans. The objective of this study was to describe and systematize the cerebral arterial vascularization of this reptile, by providing a standard irrigation model with its major variations, in addition to determining its territorial vascular areas.

Materials, Methods & Results: Thirty heads of male broad-snouted caimans (*Caiman latirostris*), with the neck segment, were used in the study. Additionally, two whole female and male specimens, with approximately 3 years of age and weighing between 8 to 10 Kg were also used. The animals were sacrificed according to routine slaughterhouse norms. The heads were sectioned at the third cervical vertebra level and the azygos carotid artery was cannulated. The arterial system was washed with 0.9% saline solution and filled with red-colored latex. The pieces were fixed in formaldehyde and the encephalon removed through a window made in the cranial vault, which was followed by removal of the dura mater and dissection of the arteries. The internal carotid arteries displayed an intercarotid anastomosis in the samples examined, continuing rostrally in 100% of the cases, exiting from the skull as the internal ophthalmic artery. The internal carotid arteries divided into a rostral branch and a short caudal branch at the hypophysis level, which continued naturally as the caudal cerebral artery. The rostral branch from both right and left antimeres was shown as a single branch in 86.7% and as double branch in 13.3% of the samples, and it formed the middle cerebral artery network. The rostral cerebral artery represented the terminal branch of the internal carotid artery's rostral branch, and an *osculum* anastomosis between its terminal end and its contralateral homologous artery occurred, forming the rostral communicating artery and thus closing the cerebral artery circle rostrally.

Discussion: To support the results of the discussion, we used information available on the encephalic vascularization of turtles, lizards, iguanas and crocodiles, due to the absence of important publications about *Caiman latirostris*. One single source of blood supply, solely originated from the left aortic arch, was observed in the two whole specimens. This source was called the azygos carotid artery. Such denomination was given because these species did not show a typical common carotid artery, as the ventral part of the neck, up to the mandible, was vascularized by branches from the subclavian arteries. Therefore, we named this single and unique source as the azygos carotid artery. The cerebral arterial circle was rostrally closed by an anastomosis between the terminal ends of the rostral cerebral artery. Consequently, the blood supply to the brain was made exclusively by the carotid system. The main differences of the cerebral vascularization observed in caymans were: a network formation of the middle cerebral artery.

Keywords: encephalic vascularization, cerebral arteries, reptiles, broad-snouted, *Caiman latirostris*.

INTRODUCTION

Due to the farming of broad-snouted caymans, a species belonging to the Brazilian fauna, and to IBAMA's (Brazilian Institute of Environment and Natural Renewable Resources) authorization to commercialize their valuable skin and meat because of the increasing interest in their production for national and international markets. Information available on the cerebral irrigation of this reptile is rare and the literature consulted yielded only a few descriptions about the embryonic development of the brain circulation of three caimans and the cerebrovascular alterations occurred after birth [4]. In addition to that, there were also some descriptions about the cerebral vascularization in turtles [2,7,9,11], and the intracranial arterial system of *Crotaphytus collaris* [3] and *Sphenodon punctatus* [5].

Several methods and different animal species have been employed in the anatomic study of the vessels that supply the necessary nutrients for nervous tissues to perform their normal activities.

This research aims at expanding the information existing in the morphological science area, in addition to describing and systematizing the middle and rostral cerebral arteries from the surface of the broad-snouted caiman's brain (*Caiman latirostris*), therefore providing a standard irrigation model, with its main variations and vascular territory.

MATERIALS AND METHODS

Thirty broad-snouted cayman heads containing the neck segment were used, in addition to two whole specimens. The animals were approximately three years old, weighting between 8 and 10 kg, originated from Criatório Mister Cayman, in Maceió, state of Alagoas, under the authorization of the Brazilian Institute of Environment and Renewable Natural Resources (IBAMA). The animals were sacrificed according to routine slaughterhouse norms. The thirty heads were sectioned at the third cervical vertebra level. The azygos carotid artery was cannulated shortly before its division into internal carotid arteries, and the arterial system was washed with 100 mL saline solution 0.9% mixed with 2500 IU heparin¹ per animal, and cooled at 15°C. Drainage was made through the jugular veins. In the sequence, the arterial system was filled with latex² colored in red by a specific³ pigment at a volume of 10 mL/animal. The samples remained for at least one hour under running water for latex polymerization purposes. A window was then

made in the skullcap. The samples were then fixed in formaldehyde 20.0% for seven days. The brain was removed with a spinal cord segment. Additionally, the dura mater was also removed and the arteries were dissected. The whole specimens were fixated with formaldehyde 20% and, seven days later, they were opened through a ventral median line incision in the thoraco-abdominal cavity up to the ventral part of the mandible, for observation of the brain blood supply.

The material was analyzed under magnifying glasses^{4,5} and a schematic drawing of the ventral view of the brain hemispheres was elaborated to produce the results.

Considering that caimans are reptiles whose morphological aspects are more similar to birds than to mammals, the vessels were named according to Nomina Anatomica Avium (1993) [1] and Nomina Anatomica Veterinaria (2005) [10], and some designations were given according to the interpretation of authors based on previous studies. In order to illustrate the documentation, some samples have been photographed. The occurrence and distribution of the vessels were expressed as the percentage of a total number of 30 encephalon samples examined.

RESULTS

The azygos carotid artery only arose from the left aortic arch in two whole specimens. It projected cranio-medially until it reached the ventral median line, dorsally to the oesophagus. Then it penetrated the deep muscles of the neck, until it reached the caudal base of the skull, ventrally to the first cervical vertebrae. We named it as azygos carotid artery for being an unique vessel and for not corresponding to the ramifications of a common carotid artery, as the ventral, neck and mandible components were vascularized by branches from the subclavian arteries. The skin of the head was completely attached to the bone, not showing a developed external vascularization characteristic of an external carotid artery. The internal carotid artery gave off branches for the vascularization of the entire head.

The azygos carotid artery, upon its proximity to the brain base of the skull, divided into two internal carotid arteries at an approximate divergence angle of 70° in all examined samples, which then penetrated into the carotid foramens, laterally to the only occipital condyle and to the foramen magnum. The internal carotid artery ran along the carotid canal until it reached the sella turcica, where it arose caudo-laterally to the hypophysis. An intercarotic anastomosis occurred just before reaching this point, which was generally oblique and of varied caliber.

During its intraosseous course, the carotid artery gave off branches to the external side of the cranial cavity.

After the intercarotid anastomosis, it continued rostrally in 100% of the samples as the internal ophthalmic artery, which is a vessel of considerable caliber. The internal ophthalmic artery left the cranial cavity into the orbital cavity through its own foramen, which was located laterally to the optical foramen. After originating the internal ophthalmic artery, the internal carotid artery became dorsally curved, then juxtaposed with the tuber cinereum wall and, from its base, gave off a rostral medium-caliber branch and continued as a caudal large-caliber branch (Figures 1 and 2). The short portion of the caudal branch continued naturally as the caudal cerebral artery, after giving off the medium-caliber portion of this branch, caudally. The large caudal cerebral artery caliber is

explained by the blood supply to the nasal cavity, made by its terminal branch, the ethmoidal artery.

The rostral branch of the internal carotid artery, a medium-caliber vessel, projected rostro-laterally from the tuber cinereum, crossing the optical tract ventrally towards the cerebral hemisphere base until it reached the optical nerve. Then it became medially curved, passing over this latter as its terminal branch—the rostral cerebral artery (Figures 1 and 2).

During this course, the rostral branch gave off one

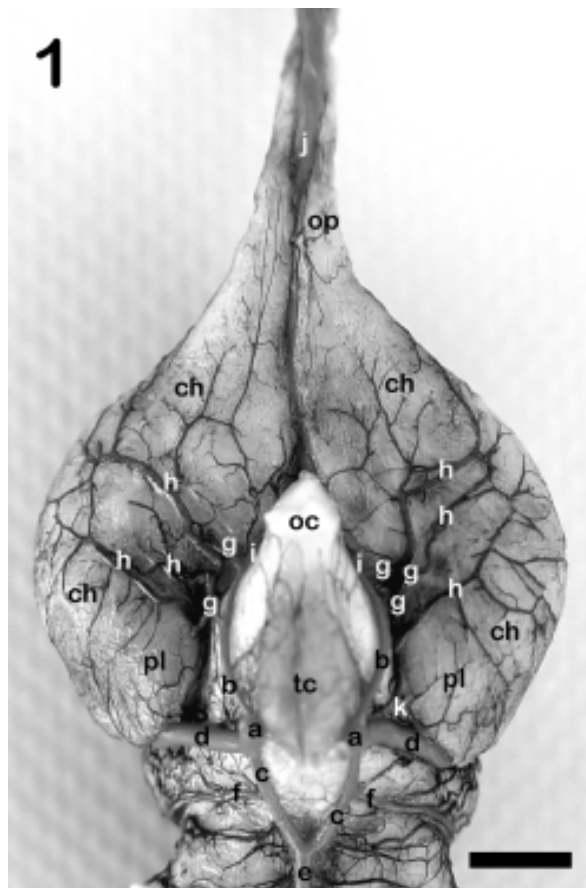


Figure 1. Ventral view of the base of the cerebral hemispheres in *Caiman latirostris* showing the distribution and ramification of the branches of the rostral and middle cerebral artery network (Obs. 23). **a**, internal carotid artery; **b**, rostral branch of **a**; **c**, caudal branch of **a**; **d**, caudal cerebral artery; **e**, basilar artery; **f**, mesencephalic artery; **g**, branches that form the middle cerebral artery; **h**, middle cerebral artery network; **i**, rostral cerebral artery; **j**, common ethmoidal artery; **op**, olfactory peduncles; **ch**, cerebral hemisphere; **oc**, optic chiasm; **tc**, tuber cinereum; **pl**, piriform lobe. Bar= 3,8mm.

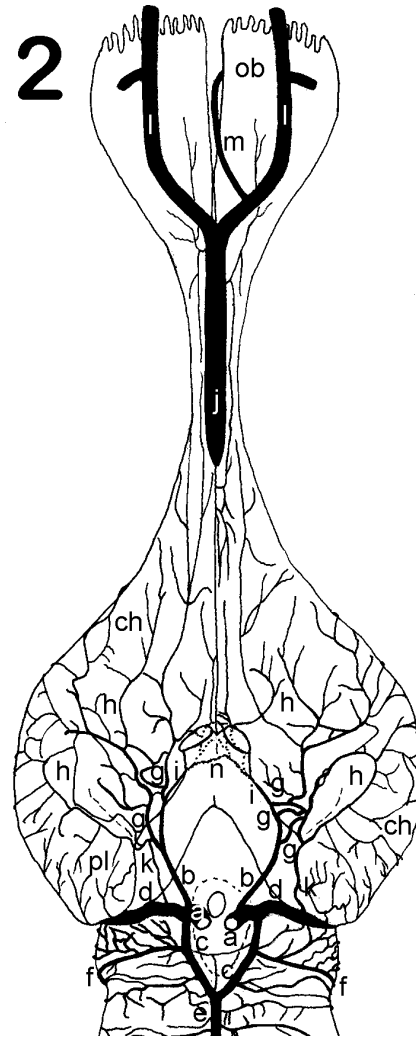


Figure 2. Schematic drawing of the ventral view of the cerebral hemisphere in *Caiman latirostris* showing the distribution and ramification of the branches of the rostral and middle cerebral artery. **a**, internal carotid artery; **b**, rostral branch of **a**; **c**, caudal branch of **a**; **d**, caudal cerebral artery; **e**, basilar artery; **f**, mesencephalic artery; **g**, branches that form the middle cerebral artery; **h**, middle cerebral artery network; **i**, rostral cerebral artery; **j**, common ethmoidal artery; **k**, I central branch of the caudal cerebral artery; **l**, ethmoidal artery; **m**, medial artery of the olfactory bulb; **n**, rostral communicating artery; **ob**, olfactory bulb; **ch**, cerebral hemisphere; **pl**, piriform lobe.

to five collateral branches, which formed the middle cerebral artery network. The right and left rostral branches of the internal carotid artery were single in 86.7% and double in 13.3% of cases (Figure 3).

The middle cerebral artery did not occur as an individualized vessel as it normally does in other animal species (Figure 1). It was rather constituted of a peculiar network-like formation, originated from one to five vessels which were sequentially projected as collateral branches of the rostral internal carotid artery branch (Table 1).

The middle cerebral artery network was projected laterally on the ventral surface of the cerebral hemisphere forming successive anastomoses, whose main branches were distributed on the larger ventrolateral part of the ven-

tral surface of the cerebral hemisphere. Its terminal branches anastomosed in *osculum* with the convex hemispherical collateral branches of the interhemispheric artery at the beginning of the convex surface of the cerebral hemisphere. The most rostral branches of the middle cerebral artery network anastomosed like a large-caliber vessel, whereas the anastomosis caliber of most caudal branches was at the capillary level. Caudally, at the cerebral hemisphere base, in the region that would correspond to the piriform lobe, the terminal branches of the middle cerebral artery network anastomosed with the terminal branches of the I central branch of the caudal cerebral artery. The middle cerebral artery territory corresponded to the whole ventral surface of the cerebral hemisphere, with the exception of the most caudal area, which corresponded to the piriform lobe of mammals. The lateral limit advanced until its lateral junction with the convex surface (Figure 4).

The rostral cerebral artery, a small-caliber vessel, projected rostro-medially from the rostral branch, arising from the last component of the middle cerebral artery network and penetrating between the optic chiasm and the ventral surface of the cerebral hemisphere (Figure 2). It branched out rostrally (Table 2), as so did the vessel that formed the rostral communicating artery. These branches rostrally projected surrounding the cerebral longitudinal fissure and, then, penetrating this latter dorsally. An *osculum* anastomosis of the terminal end of the rostral cerebral artery with its contralateral counterpart occurred, forming the rostral communicating artery dorso-rostrally to the optic chiasm (Figure 2). This vessel of considerable caliber, closed rostrally the cerebral arterial circle. It appeared as a single vessel in 90.0%, and as a double vessel in 10.0% of the cases. The territory of the rostral cerebral artery was comprised of a narrow band, which extended from the optic chiasm to the base where the olfactory peduncles are inserted, surrounding the cerebral longitudinal fissure ventrally and also penetrating it (Figure 4).

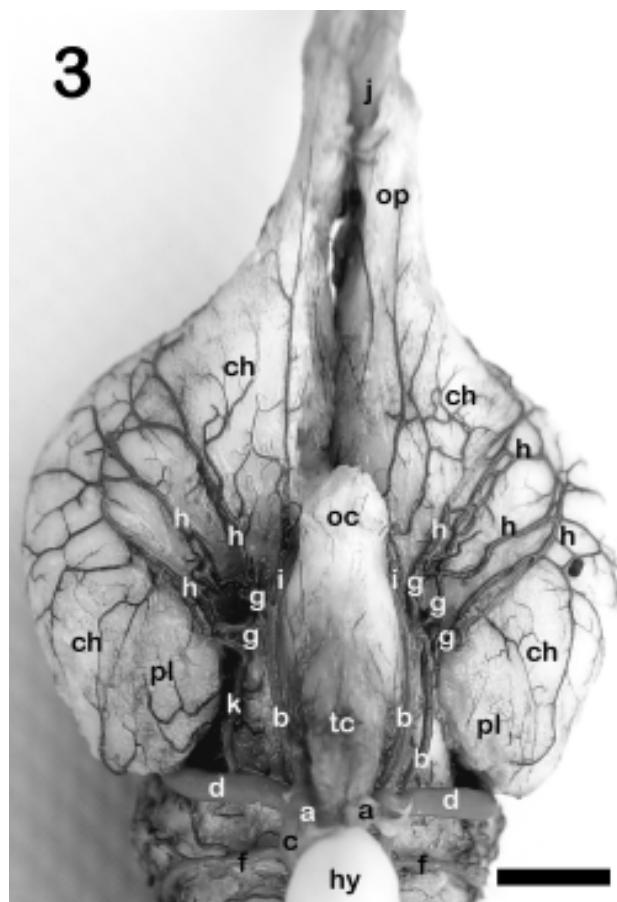


Figure 3. Ventral view of the brain base of *Caiman latirostris* showing the duplication of the rostral branch of the internal carotid artery (Obs. 14) **a**, internal carotid artery; **b**, rostral branch of **a**; **c**, caudal branch of **a**; **d**, caudal cerebral artery; **f**, mesencephalic artery; **g**, branches that form the middle cerebral artery; **h**, middle cerebral artery network; **i**, rostral cerebral artery; **j**, common ethmoidal artery; **k**, I central branch of the caudal cerebral artery; **op**, olfactory peduncles; **ch**, cerebral hemisphere; **oc**, optic chiasm; **tc**, tuber cinereum; **pl**, piriform lobe; **hy**, hypophysis. Bar= 3,5mm.

DISCUSSION

With regard to the cerebral blood supply in *Caiman latirostris*, no reference on the subject was found in all literature consulted, as authors would start their description based on a carotid artery already at the base of the skull. Only one single source of blood supply, solely originated from the left aortic arch, was observed in the two whole specimens. This source was called azygos

Table 1. Number of branches which formed the middle cerebral artery of *Caiman latirostris*.

Number of branches	RMCA (%) average range (X±s)	LMCA (%) average range (X±s)
1	3.3±3.3	10.0±5.5
2	63.3±8.8	53.3±9.1
3	23.4±7.7	26.7±8.1
4	6.7±4.5	6.7±4.5
5	3.3±3.3	3.3±3.3

RMCA - right middle cerebral artery

LMCA - left middle cerebral artery

Table 2. Collateral branches of the rostral cerebral artery *Caiman latirostris*.

Collateral branches	RRCA (%) average rate (x±s)	LRCA (%) average range (x±s)
0	6.7±4.5	-
1	43.3±9.0	39.7±8.8
2	43.3±9.0	56.6±9.0
3	6.7±4.5	6.7±4.5

RRCA - right rostral cerebral artery

LRCA - left rostral cerebral artery

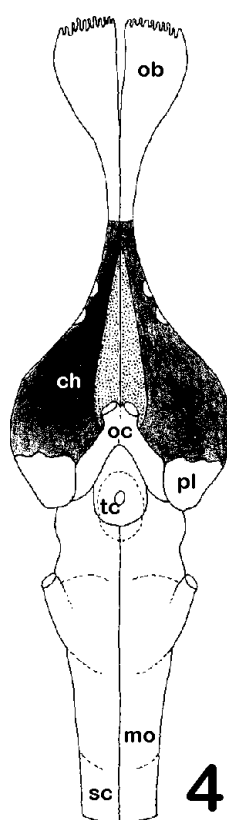


Figure 4. Schematic representation of the brain base of *Caiman latirostris*, showing the territory of the rostral cerebral artery (stippled area) and middle cerebral artery network (black area); **ob**, olfactory bulb; **ch**, cerebral hemisphere; **pl**, piriform lobe; **oc**, optic chiasm; **tc**, tuber cinereum; **mo**, medulla oblongata; **sc**, spinal cord.

carotid artery. Such denomination was given because this species did not show a typical common carotid artery, as the ventral part of the neck, up to the mandible, was vascularized by branches from the subclavian arteries. Therefore, we named this single and unique source as the azygos carotid artery.

With regard to the behavior of cerebral vessels in three adult alligators, it has been described that the internal carotid artery passed through the carotid canal on the floor of the basisphenoid bone, at the caudal limit of the hypophyseal fossa, then it curved dorsally and penetrated into the cranial cavity [4]. These results coincide with the ones observed in the *Caiman latirostris*. According to the same author, both internal carotid arteries anastomosed inside the cranial cavity, immediately caudally to the hypophysis, forming an intercarotid anastomosis which occurred in all specimens studied, even though it was poorly developed in one of the samples [2,4]. On the other hand, with regard to the encephalic arteries of three *Crotaphytus collaris* (lizards), no anastomosis between the internal carotid arteries was observed [3]. Such intercarotid anastomosis was observed in the *Caiman latirostris*, which presented a varied caliber and was generally oblique. After the intercarotid anastomosis, the internal carotid artery originated a large orbital artery rostrally, which arose from the cranial cavity through a special foramen in the rostral limit of the hypophyseal fossa [2,4]. In *Caiman latirostris*, a similar artery arose after the intercarotid anastomosis, which then extended rostrally through its own foramen located laterally to the optic foramen. This artery was called internal ophthalmic artery [9,11]. In turtles belonging to the genus *Pseudemys* [2], the internal carotid artery, after the orbital artery origin, continued rostrally as the cerebral carotid artery, which then divided into the rostral encephalic arteries (rostral branch) and the caudal encephalic artery (caudal branch) [3,4,6,9]. In a comparative study of the blood supply to the brain of lizards, turtles and alligators [7,8], it was described that the internal carotid artery divided into a rostral and a caudal branch [5,11], and the same was observed in all *Cayman latirostris* samples. In a study on reptiles, it was reported that the rostral and caudal branch

of the cerebral carotid artery in turtles presented identical calibers, whereas in saurians and crocodylians, the caliber of the rostral branch was larger than its caudal counterpart [6]. However, another author reported that, in reptiles, the caliber of the caudal branch of the internal carotid artery was slightly larger than the rostral branch [8]. According to the reports of this latter author, the caudal branch was more developed than the rostral one in *Caiman latirostris*, presenting two portions: one with a large and the other with a medium caliber.

In alligators, the rostral encephalic artery (rostral branch) projected rostrally, originating a large middle cerebral artery and continuing as rostral cerebral artery, around the rostral edge of the optic chiasm [4]. In *Sphenodon punctatus*, it was observed that the rostral portion (rostral branch) of the internal carotid artery originated the caudal, middle and rostral cerebral arteries [5], whereas in turtles it was observed that the rostral encephalic artery (rostral branch of the internal carotid artery), originated one lateral choroidal artery, one ophthalmic artery and one middle cerebral artery, then ending as the rostral cerebral artery [2,11]. In *C. latirostris*, the rostral branch gave off one to five collateral branches, which formed the middle cerebral artery network, continuing rostrally as the rostral cerebral artery's terminal branch.

In alligators, the rostral encephalic artery (rostral branch) originated a large middle cerebral artery, which gave off several secondary branches to the largest part of the convex surface of the cerebral hemisphere [4]. In turtles, the middle cerebral artery also presented a single origin for the rostral division (rostral branch) of the internal carotid artery [11]. Furthermore, the author described in detail the branches of the middle cerebral artery, including the difference in size of the caliber of vessels and their vascular territory [11]. In reptiles, the middle cerebral artery either was originated as a single trunk, which quickly became subdivided into several arteries, or was formed from many short trunks, which were branched and distributed through the piriform cortex, on the ventrolateral surface of the cerebral hemisphere and paleopallium area, continuing dorsolaterally towards the convex surface of the cerebral hemisphere [8]. In *Sphenodon punctatus*, the middle cerebral artery continued rostromedially to the olfactory tract as the olfactory artery [5]. In *C. latirostris*, the middle cerebral artery was not an individualized vessel, rather forming a network, either originated from one single vessel or formed of several branches. With regard to the middle

cerebral artery territory, its terminal branches made an *osculum* anastomosis with the terminal branches of the convex hemispheric collateral branches of the interhemispheric artery, at the beginning of the convex surface of the cerebral hemisphere. Additionally, the middle cerebral artery anastomosed caudally with the I central branch of the caudal cerebral artery in the region corresponding to the piriform lobe. This issue has not been described in any consulted references.

In *Sphenodon punctatus* [5], the rostral portion (rostral branch), after originating the middle cerebral artery, continued rostromedially inside the cerebral longitudinal fissure. Additionally, a connection between the rostral cerebral arteries was not observed and, consequently, the cerebral arterial circle remained rostrally open [6,11]. In alligators, the rostral cerebral artery was originated from the rostral portion of the cerebral carotid artery, after giving off the middle cerebral artery; however, a medial branch was given off to the cerebral longitudinal fissure, which anastomosed with its contralateral counterpart, forming the rostral communicating artery and thus closing the cerebral arterial circle rostrally [4]. This origin and arrangement of the rostral communicating artery has also been observed in *C. latirostris*; this artery, moreover, gave off two collateral branches rostrally, in addition to the vessel that forms the rostral communicating artery.

In turtles, the rostral cerebral artery bifurcated into a medial and a lateral branch, and the collateral branches of the lateral branch supplied the ventral and lateral surface and the dorsal half of the olfactory bulb. On the other hand, the collateral branches of the medial branch projected to the medial surface and to the other dorsal half of the olfactory bulb [11]. Contrarily to turtles, which present a sessile olfactory bulb, *C. latirostris* have a long olfactory peduncle, containing a large olfactory bulb at one end. This anatomic difference explains the relevant vascular differences of the brain vascularization. Therefore, the vascularization of olfactory bulbs in *C. latirostris* was made by the branches of the common ethmoidal artery, the terminal branch of the caudal cerebral artery. The rostral cerebral artery terminal branches irrigated only the initial third of the ventral surface of the olfactory peduncles.

CONCLUSIONS

Based on the results of this study, we can conclude that the vascularization of the brain in *Caiman latirostris* is exclusively made by an unique source, the azygos carotid

artery. The internal carotid arteries are connected by an intercarotid anastomosis, and are divided into a rostral and caudal branch. The rostral branch originates the middle cerebral artery network, and vascularizes most of the ventral surface of the cerebral hemisphere. The rostral cerebral artery corresponds to the terminal end of the rostral branch of the internal carotid artery. It has an extremely restricted territory and, differently from birds and mammals in general, it does not continue as the ethmoidal artery. The cerebral arterial circle is rostrally closed by the rostral communicating artery.

SOURCES AND MANUFACTURERS

- ¹Heparin - Cristalia Produtos Quimicos Farmaceuticos Ltda, Itapira, SP, Brazil)
- ²Cola 603 - Bertoncini Ltda, São Paulo, SP, Brazil.
- ³Suvinil Corante - BASF S.A., São Bernardo do Campo, SP, Brazil.
- ⁴Lupa com lâmpada LTS. aumento de 5x.
- ⁵Stemi SV8 Zeiss - Goettingen, Germany.

REFERENCES

- 1 Baumel J.J., King A.S., Breazile J.E., Evans H.E. & Berge J.C.V. 1993.** *Handbook of avian anatomy: Nomina anatomica avium*. 2nd edn. Cambridge: Nuttall Ornithological Club, 778p.
- 2 Burda D. 1965.** Development of intracranial arterial patterns in turtles. *Journal of Morphology*. 116: 171-188.
- 3 Burda D. 1966.** Embryonic modifications of lacertilian. Intracranial arteries. *American Journal of Anatomy*. 118: 743-754.
- 4 Burda D. 1969.** Developmental aspect of intracranial arterial supply in the alligator brain. *Journal of Comparative Neurology*. 135: 369-380.
- 5 Dendy A. 1909.** The intracranial vascular system of *Sphenodon*. *Philosophical Transactions of the Royal Society of London, Biological Sciences*. 200: 403-426.
- 6 De Vriese B. 1905.** Sur la signification morphologique des artères cérébrales. *Archives de Biologie*. 21: 357-457.
- 7 Frizzo M.E.S, Campos R., Severino A.G. & Achaval M. 1994.** The vasculature of the subfornical organ of the turtle *Chrysemys dorbigni*. *Italian Journal of Anatomy and Embryology*. 99(2): 109-121.
- 8 Gillilan L. 1967.** A comparative study of the extrinsic and intrinsic arterial bloodsupply to brains of the submammalian vertebrates. *American Journal of Anatomy*. 130: 175-196.
- 9 Kappers C.U.A. 1933.** The forebrain arteries of plagiostomes, reptiles, birds, and monotremes. *Proceedings of the Royal Academy of Amsterdam*. 36: 52-62.
- 10. International Committee on Veterinary Gross Anatomical Nomenclature. 2005.** *Nomina Anatomica Veterinaria*. 5th edn. New York, 198p.
- 11. Schepers G.W.H. 1939.** The blood vascular system of the brain of *Testudo geometrica*. *Journal of Anatomy*. 73: 451-495.

