

# IRON AND GLUCOSE-REGULATED PROTEIN 78: FUNDAMENTAL COMPONENTS IN THE COINFECTION OF *RHIZOPUS ORYZAE* AND SARS-CoV-2

Manoela Almeida Martins Mace<sup>1</sup> , Bárbara S. da Costa<sup>2</sup> ,  
Rubia do N. Fuentefria<sup>3</sup> , Alexandre M. Fuentefria<sup>1,2</sup> 

## ABSTRACT

Along with the growing number of fatalities and lack of specific treatment at the time, the increasing incidence of mucormycosis worried world health agencies, as it ran the risk of more threatening outcomes for COVID-19 patients. In this context, this review aims to assemble case reports of COVID-19 associated mucormycosis and discuss virulence and host factors involved in the progress of these infections – key aspects that might unveil biological targets and pharmacological approaches to treat these infections. Recently, elevated serum iron levels during SARS-CoV-2 infection have been reported in the literature. Besides being a clinical characteristic of diabetic patients, iron overload is described as a risk factor for *Rhizopus oryzae* infection. Furthermore, the increased expression of human heat-shock protein GRP78 during iron overload and coronavirus infection display a crucial role as a mediator in Mucorales invasion. These remarkable mechanisms might explain the high incidence of mucormycosis in COVID-19 patients with diabetes and, therefore, suggest regulation of GRP78 expression, management of glycemia and glucocorticoid treatment as potential therapeutic targets of this severe coinfection.

**Keywords:** SARS-CoV-2; COVID-19; Mucormycosis; Iron; GRP78

## INTRODUCTION

The outbreak of the coronavirus disease 2019 (COVID-19) in China at the end of 2019 became a global pandemic threat in early 2020. Severe acute respiratory syndrome coronavirus 2 (SARS-CoV-2) emerged as a remarkable issue of concern due to the rapid increase in mortality rates and the lack of any specific pharmacological therapy<sup>1</sup>. Mucormycosis is a life-threatening fungal infection that mostly affects immunocompromised subjects, such as COVID-19 patients<sup>2,3</sup>. The global mortality from mucormycosis is 46% and underlying medical conditions could lead to a 93% fatality rate<sup>4,5</sup>.

Uncontrolled diabetes mellitus, corticosteroid therapy, organ transplantation, hematologic diseases and neutropenia are all relevant risk factors that support the most serious outcomes in mucormycosis infection<sup>6</sup>. However, these medical conditions can also trigger lethal coinfection with COVID-19. Major clinical complications include acute respiratory distress syndrome and rhinocerebral impairment, which establish a potential risk to the hosts of these pathogens<sup>1,2</sup>.

Virulence factors and the host response have an important role in the pathogenesis of infections<sup>7</sup>. High affinity iron permease (FTR1) upregulation by Mucorales in hyperglycemic mice and COVID-19 patients with an elevated expression of glucose-regulated protein 78 (GRP78), which binds with the spore coat (Coth) protein of Mucorales, suggests that these mechanisms could be crucial components of the coinfection<sup>8-10</sup>.

The lethal alliance of mucormycosis and COVID-19 has a diagnosis that relies substantially on histopathological findings and molecular techniques. In addition, the few pharmacological alternatives available, often lead to nephrotoxicity and surgical debridement<sup>1,11</sup>. Understanding the association between the virulence factors and the host characteristics can reveal a key aspect of the infection's progression and could provide a more efficient therapeutic strategy.

*Clin Biomed Res.* 2023;43(2):180-200

1 Faculdade de Farmácia,  
Universidade Federal do Rio Grande  
do Sul. Porto Alegre, RS, Brasil.

2 Programa de Pós-Graduação  
de Ciências Farmacêuticas,  
Universidade Federal do Rio Grande  
do Sul. Porto Alegre, RS, Brasil.

3 Hospital de Clínicas de Porto Alegre.  
Porto Alegre, RS, Brasil.

### Corresponding author:

Manoela Almeida Martins Mace  
manoelamace10@gmail.com  
Faculdade de Farmácia,  
Universidade Federal do Rio  
Grande do Sul  
Rua São Luís, 154  
90620-170, Porto Alegre, RS, Brasil.

## METHODS

### Research strategy

The study was carried out in July 2021 in the form of systematic review in the ScienceDirect and PubMed databases, using original studies, case reports and reviews published between 2019

and July of 2021. The keywords used in the search were combined into three groups: ["SARS-CoV-2" or "COVID-19"], ["mucormycosis" or "mucor" or "rhizomucor" or "rhizopus" or "mucorales" or "zygomycosis"] and ["ferritin" or "iron" or "GRP78"]. No language restriction was applied. Antifungal susceptibility studies, chapters of books and clinical trials were excluded (Figure 1).

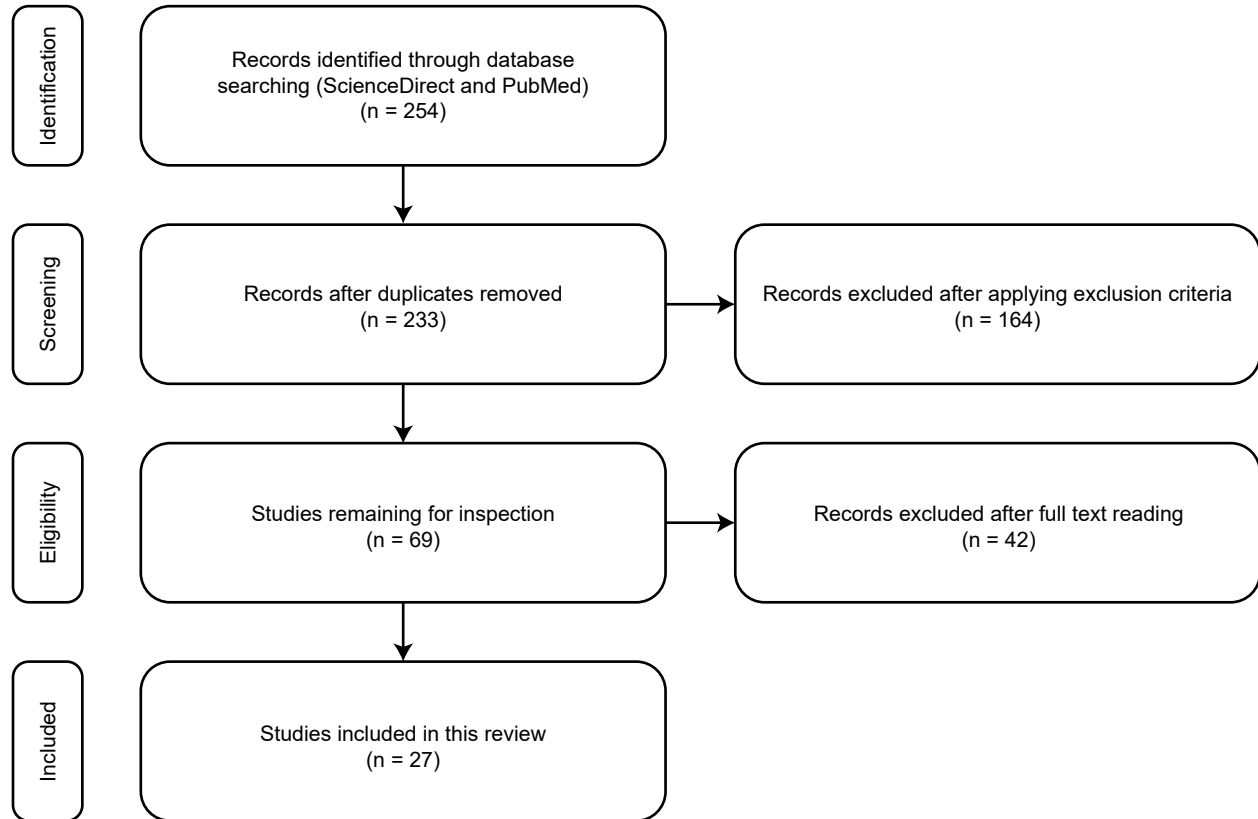


Figure 1: Flowchart of research evidence and criteria for inclusion and exclusion of studies.

## RESULTS AND DISCUSSION

### Risk factors

#### Iron uptake and FTR1 expression

Zygomycosis is a fungal infection caused by *Zygomycetes*, a class of fungi that encompasses the orders Mucorales and Entomophthorales. Diverging from entomophthoromycosis, rare infections that usually affect immunocompetent individuals, fungi of the order Mucorales cause worldwide life-threatening infections in immunocompromised hosts, which are known as mucormycosis<sup>2</sup>. In 1885, the first case of mucormycosis in humans was reported and identified as "Mycosis Mucorina". The detailed information

described in Paltauf's<sup>12</sup> paper strongly suggested that *Absidia corymbifera*, a mold that belongs to the order Mucorales, was the etiologic agent of the disseminated infection referred to in a cancer patient<sup>12</sup>. Nowadays, the incidence of mucormycosis is progressively increasing around the world. However, a high number of cases in Asia is observed, more specifically in India. A computational approach estimated the prevalence of mucormycosis at 140 cases per million in India, reaching about 170,000 cases annually. Further on, the manifestation of this pathology is already well known due to rhino-orbital involvement, the most common form of mucormycosis<sup>13</sup>. These studies are in line with the findings of Table 1, which revealed more reports from the Asian continent and presented mostly rhino-orbital involvement.

**Table 1:** Characteristics of the case reports of mucormycosis and COVID-19 coinfection.

References	Infectious Disease Process	Underlying medical conditions	Therapeutics	Case outcome	Type of Mucormycosis	Location	Mucormycosis risk factors
<i>Alekseyev, Didenko and Chaudhry (2021)</i> <sup>14</sup>	A 41-year-old male. Reported cough and severe pain in the nose and a black eschar was observed in the oral cavity in the hospital admission. A chest radiography showed pneumonia. Chest CT exhibited peripheral lung infiltrates and sinusitis. The patient had a positive PCR test result for COVID-19. The surgical debridements indicated mucormycosis and all necrotic tissue was removed. Breathing support not informed.	Type 1 Diabetes mellitus	<u>COVID-19:</u> Systemic steroid, HCQ. <u>Other treatment:</u> Insulin, FEP and AMB.	Survived.	Rhinocerebral	USA	T1DM, steroid therapy
<i>Arana et al. (2021)</i> <sup>15</sup>	<u>Case I:</u> A 62-year-old male reported shortness of breath on the hospital admission due to pneumonia caused by COVID-19 and required assisted breathing. Chest radiography revealed clinical improvement. However, one week later the patient had fever, headache and facial swelling. Facial CT presented left sinusitis. Nasal endoscopy and sinus debridement were performed and swab culture confirmed mucormycosis caused by <i>Rhizopus oryzae</i> . Oxygen supplementation.	Diabetes mellitus II, immunosuppressive treatment, kidney transplant, history of cryptococcosis, ischemic heart disease.	<u>COVID-19:</u> DEX. <u>Other treatment:</u> CRO, AZT, AMB, ISZ and PSZ.	Survived.	Rhino-orbital	Spain	T2DM, immunosuppression, steroid therapy, prior systemic mycosis

Continua...

Tabela 1: Continuação.

References	Infectious Disease Process	Underlying medical conditions	Therapeutics	Case outcome	Type of Mucormycosis	Location	Mucormycosis risk factors
	<u>Case II:</u> A 48-year-old male was admitted to the hospital with pneumonia caused by COVID-19. Three weeks later, the patient reported pain in the right lower leg showing a hematoma. Surgical debridement revealed necrotic muscle tissue and fungal culture confirmed the diagnosis as musculoskeletal mucormycosis caused by <i>Lichtheimia ramosa</i> . Oxygen supplementation.	Hypertension, hypothyroidism, chronic renal disease, kidney transplant, immunosuppressive therapy, chronic allograft dysfunction	<u>COVID-19:</u> PDN. <u>Other treatment:</u> AZT, HCQ, LPV/r, AMB and ISZ.	Survived.	Musculoskeletal	Spain	Immunosuppression, steroid therapy
<i>Garg et al. (2021)</i> <sup>16</sup>	A 55-year-old male reported in his admission fever, cough and shortness of breath. Chest CT revealed bilateral interstitial opacities and cardiomegaly. He had a positive COVID-19 result. Repeat chest CT exhibited pleural effusion. Sputum samples were collected which grew fluffy grayish colonies and aseptate hyphae, suggestive of Mucorales. MALDI-TOF technique confirmed the identification as <i>Rhizopus microsporus</i> . After improvement in his clinical condition, he was discharged. Oxygen supplementation.	Hypertension, ischemic cardiomyopathy, diabetes mellitus and end-stage renal disease	<u>COVID-19:</u> DEX and REM. <u>Other treatment:</u> MER and AMB.	Survived.	Pulmonary	India	Diabetes, steroid therapy

Continua...

Tabela 1: Continuação.

References	Infectious Disease Process	Underlying medical conditions	Therapeutics	Case outcome	Type of Mucormycosis	Location	Mucormycosis risk factors
<i>Johnson et al. (2021)</i> <sup>17</sup>	A 79-year-old male was admitted to the hospital with fever, cough and dyspnea. The patient tested positive for SARS-CoV-2. A chest X-Ray revealed bibasilar infiltrates and a chest CT showed bilateral ground-glass opacities. He developed ventilator-associated pneumonia. Samples of bronchoalveolar lavage were collected. Direct examination revealed aseptate hyphae. Microbiological diagnosis confirmed <i>Rhizopus arrhizus</i> and <i>Aspergillus fumigatus</i> . Tracheostomy was performed.	Diabetes mellitus and hypertension	<u>COVID-19:</u> REM and DEX. <u>Other treatment:</u> CRO, AZT, VAN, VOZ and AMB.	Hospitalized.	Pulmonary	USA	Diabetes and steroid therapy
<i>Kanwar et al. (2021)</i> <sup>18</sup>	A 56-year-old male tested positive for COVID-19. The patient presented fatigue, respiratory failure and hemoptysis. A chest radiography revealed pleural effusion. Sputum samples revealed filamentous fungi on direct examination. Sequence analysis of DNA identified as <i>Rhizopus azygosporus</i> . Chest CT showed lung necrosis and the patient was submitted to lung decortication. Blood cultures were positive for vancomycin-resistant <i>Enterococcus</i> spp. implying cardiac arrest and death. Mechanical ventilation was used.	End-stage renal disease (on hemodialysis)	<u>COVID-19:</u> mPRED and TCZ. <u>Other treatment:</u> VAN, TZP and AMB.	Deceased.	Pulmonary	USA	Steroid therapy

Continua...

Tabela 1: Continuação.

References	Infectious Disease Process	Underlying medical conditions	Therapeutics	Case outcome	Type of Mucormycosis	Location	Mucormycosis risk factors
<i>Karimi-Galougahi, Arastou and Haseli (2021)</i> <sup>19</sup>	A 61-year-old female was hospitalized with COVID-19 and reported facial pain that evolved into a facial numbness and visual impairment. A black eschar was observed recovering the periorbital skin region, right eye proptosis, loss of vision and mydriasis. CT scan showed opacification of the sinuses and acute sinusitis. The patient required intubation. Histopathologic findings confirmed the diagnosis of mucormycosis. Sinonasal debridement removed the necrotic tissue and the right eye was exenterated.	None	<u>COVID-19:</u> REM, IFN $\alpha$ , systemic corticosteroids. <u>Other treatment:</u> Insulin and systemic antifungals.	The study did not specify the case outcome.	Rhino-orbital	Iran	Steroid therapy
<i>Khatri et al. (2021)</i> <sup>20</sup>	A 68-year-old male was admitted to the hospital with cough, diarrhea, fever and a sternal wound discharge. A chest CT revealed ground-glass opacities and bilateral thickening. The patient tested positive for COVID-19 and developed encephalopathy and acute kidney injury. After chest wall reconstruction surgery with skin grafting the patient developed swelling with purplish skin in the right axilla. Brown fluid samples were aspirated and revealed aseptate hyphae confirmed as <i>Rhizopus microsporus</i> . Required mechanical ventilation.	Type 2 Diabetes mellitus, hypertension, heart transplant, chronic kidney disease, immunosuppressive therapy	<u>COVID-19:</u> HCQ, MEP and PDN. <u>Other treatment:</u> VAN, MER, CYA, AMB and PSZ.	Deceased.	Cutaneous mucormycosis	USA	T2DM, immunosuppression, steroid therapy, orthotopic heart transplant.

Continua...

Tabela 1: Continuação.

References	Infectious Disease Process	Underlying medical conditions	Therapeutics	Case outcome	Type of Mucormycosis	Location	Mucormycosis risk factors
<i>Krishna et al. (2021)</i> <sup>21</sup>	A 22-year-old male was admitted to the hospital with COVID-19, due to severe pneumonitis requiring assisted breathing. A chest radiography revealed bilateral opacification. He had an episode of septic shock. Fungal biomarkers were negative. Samples of bronchoalveolar lavage were collected and submitted to microbiological cultures and had negative results. The patient died on day 20 following his admission due to multi-organ failure. Autopsy confirmed disseminated mucormycosis in the lungs, hilar nodes, pericardium and brain.	Hypothyroidism	<u>COVID-19:</u> Systemic steroids and HCQ. <u>Other treatment:</u> AZT, CAS, TGC, MER and teicoplanin.	Deceased.	Disseminated mucormycosis	England	Steroid therapy
<i>Maini et al. (2021)</i> <sup>22</sup>	A 38-year-old male was admitted to the hospital presenting fever, cough, dyspnea and body ache and tested positive for COVID-19. Two weeks later, the patient reported lid swelling. A head MRI revealed mucosal thickening and edema in the retrobulbar tissue. Histopathologic diagnosis found aseptate hyphae, suggestive of mucormycosis infection. Surgical debridement and amphotericin B lavage was performed. Repeat head MRI showed no recurrence of infection and the eye movements was normal. Oxygen support.	None	<u>COVID-19:</u> Remdesivir, MEP and DEX. <u>Other treatment:</u> TZP, FLU, MTZ, AMB, TOB and nepafenac.	Survived.	Rhino-orbital	India	Steroid therapy

Continua...

Tabela 1: Continuação.

References	Infectious Disease Process	Underlying medical conditions	Therapeutics	Case outcome	Type of Mucormycosis	Location	Mucormycosis risk factors
<i>Mehta and Pandey (2020)</i> <sup>23</sup>	A 60-year-old male was admitted to the hospital with shortness of breath, fever, malaise and the patient required assisted breathing. He tested positive for COVID-19 and the chest CT revealed opacification of the lungs. Mechanical ventilation. MRI of the head revealed swelling of the malar region, proptosis and ethmoidal sinus thickening. Nasal biopsy revealed aseptate hyphae suggesting mucormycosis, confirmed by Sabouraud Agar culture. No surgical debridement was performed due the consistent hypotension.	Diabetes mellitus	<u>COVID-19:</u> OTV, MEP, DEX and TCZ. <u>Other treatment:</u> MER, VAN, insulin, SG, MF and AMB.	Deceased.	Rhino-orbital	India	Diabetes, steroid therapy
<i>Mekonnen et al. (2021)</i> <sup>24</sup>	A 60-year-old male reported to an emergency department with shortness of breath and hyperglycemia. The patient tested positive for SARS-CoV-2 and demanded intubation. A swelling in the right eye was observed. Head CT revealed proptosis and opacification of sinuses. Histopathological diagnosis confirmed mucormycosis infection caused by <i>Rhizopus</i> sp. The patient was submitted to an otolaryngologic surgical debridement.	Diabetes mellitus, asthma, hypertension	<u>COVID-19:</u> DEX. <u>Other treatment:</u> VAN, FEP, AMB, PSZ and CAS.	Deceased.	Rhino-orbital	USA	Diabetes, steroid therapy

Continua...



Tabela 1: Continuação.

References	Infectious Disease Process	Underlying medical conditions	Therapeutics	Case outcome	Type of Mucormycosis	Location	Mucormycosis risk factors
<i>Monte Jr. et al. (2020)</i> <sup>25</sup>	An 86-year-old male was admitted to the hospital reporting diarrhea, shortness of breath, cough and fever. He tested positive for COVID-19. Chest CT revealed ground-glass opacification in the lungs evolving to acute respiratory distress syndrome with mechanical ventilation. The patient presented melena and severe anemia. An esophagogastric endoscopy was performed and exhibited gastric ulcers with a hemorrhagic base. Histopathological diagnosis confirmed gastrointestinal mucormycosis. Neither antifungal therapy was started.	Hypertension	<u>COVID-19:</u> Hydrocortisone, OTV. <u>Other treatment:</u> AZT, CRO, OMEP.	Deceased.	Gastrointestinal	Brazil	Steroid therapy
<i>Nehara et al. (2021)</i> <sup>26</sup>	<u>Case I:</u> A 59-year-old female was admitted at the hospital with COVID-19 requiring assisted breathing. Headache and ptosis were reported. Physical examination showed visual impairment, proptosis, a black eschar in the oral cavity and a black discharge in the nasal mucosa. Paranasal CT and MRI of the head findings were suggestive for mucormycosis infection. Mechanical ventilation was used. The nasal discharge was submitted to microbiological culture in Sabouraud Agar and confirmed the diagnosis as mucormycosis caused by <i>Rhizopus arrhizus</i> . The severe hypotension precluded surgical debridement.	Type 2 Diabetes mellitus and hypertension	<u>COVID-19:</u> REM and DEX. <u>Other treatment:</u> MER, AZT, enoxaparin, insulin and AMB.	Deceased.	Rhino-orbital	India	T2DM, steroid therapy

Continua...

Tabela 1: Continuação.

References	Infectious Disease Process	Underlying medical conditions	Therapeutics	Case outcome	Type of Mucormycosis	Location	Mucormycosis risk factors
	<u>Case II:</u> A 52-year-old male was admitted to the hospital with COVID-19 and reported headache, visual impairment, and red eye. The physical examination revealed proptosis, visual loss, swelling of the periorbital region, restrict ocular movement and black discharge in the nasal mucosa. MRI showed thickening of the sinuses. Histopathological diagnosis was mucormycosis caused by a <i>Rhizopus</i> species. The microbiological culture in Sabouraud Agar was confirmed as <i>Rhizopus arrhizus</i> . Breathing support not informed	Type 2 Diabetes mellitus	COVID-19: PRDL. Other treatment: Insuline, MER, VAN, AMB and PSZ.	Survived.	Rhino-orbital	India	T2DM, steroid therapy
	<u>Case III:</u> A 62-year-old female with previous COVID-19 pneumonia was readmitted to the hospital reporting painless facial swelling, visual impairment and a black spot on the right eye. A head MRI exhibited endophthalmitis and sinus thrombosis. Direct examination with KOH of nasal scraping was suggestive for mucormycosis caused by a <i>Rhizopus</i> species. The patient had surgical debridement and lost the right eye. Breathing support not informed	Type 2 Diabetes mellitus and hypertension	COVID-19: None mentioned. Other treatment: MER, LZD, AMB and insulin.	Hospitalized.	Rhino-orbital	India	T2DM

Continua...

Tabela 1: Continuação.

References	Infectious Disease Process	Underlying medical conditions	Therapeutics	Case outcome	Type of Mucormycosis	Location	Mucormycosis risk factors
	<u>Case IV:</u> 70-year-old female was admitted to the hospital with COVID-19 after reporting painless facial swelling, visual impairment and double vision in the left eye. Head MRI findings showed pansinusitis and orbital cellulitis. Nasal scraping submitted to a histopathological diagnosis confirmed as mucormycosis. Microbiological culture was performed and identified the fungi as <i>Rhizopus arrhizus</i> . Surgical debridement was not performed due to relative's refusal. Breathing support not informed	Type 2 Diabetes mellitus	COVID-19: REM and DEX. Other treatment: Antibiotics, insulin and AMB.	Hospitalized.	Rhino-orbital	India	T2DM, steroid therapy
	<u>Case V:</u> 68-year-old female was admitted to the hospital with COVID-19 and pneumonia. The patient started reporting headache, facial swelling, ptosis, visual impairment and a black discharge in the nasal mucosa. MRI findings include orbital cellulitis, pansinusitis and lacunar infarct. Nasal scraping was collected and submitted to a histopathological analysis confirming as mucormycosis. Through microbiological culture, mucormycosis caused by <i>Rhizopus arrhizus</i> was diagnosed. Due to her hemodynamic condition, the surgical debridement could not be done. Breathing support not informed	Type 2 Diabetes mellitus	COVID-19: None mentioned. Other treatment: AMB and antibiotics.	Deceased.	Rhino-orbital	India	T2DM

Continua...

Tabela 1: Continuação.

References	Infectious Disease Process	Underlying medical conditions	Therapeutics	Case outcome	Type of Mucormycosis	Location	Mucormycosis risk factors
<i>Placik, Taylor and Wnuk (2020)</i> <sup>27</sup>	A 49-year-old male was admitted to the emergency center with fever, cough, respiratory failure and required mechanical ventilation. He had a positive PCR test result for COVID-19. A chest radiography revealed right pneumothorax. The patient required intubation due to respiratory failure. Cardiothoracic surgery was performed and a necrotic empyema was noticed. Samples were collected for histopathological diagnosis, which was suggestive of mucormycosis.	None	COVID-19: DEX, REM and TCZ. Other treatment: CRO, AZT, other antibiotics and AMB.	Deceased.	Pulmonary	USA	Steroid therapy
<i>Rao, Shetty and Nagesh (2021)</i> <sup>28</sup>	A 66-year-old male was admitted to the hospital reporting headache, periorbital pain and visual impairment in the left eye. The patient was on a 12-day course of steroid therapy due to a prior COVID-19 diagnosis. The physical examination revealed eye proptosis, ptosis and periorbital edema. MRI of the head showed ethmoid sinusitis and ischemia of the optic nerve. Nasal endoscopy was performed. The microbiological diagnosis was mucormycosis. The left eye was exenterated. Breathing support not informed	Diabetes, history of diabetic retinopathy	COVID-19: Systemic steroids. Other treatment: AMB.	The study did not specify the case outcome.	Rhino-orbital	India	Diabetes, steroid therapy

Continua...

Tabela 1: Continuação.

References	Infectious Disease Process	Underlying medical conditions	Therapeutics	Case outcome	Type of Mucormycosis	Location	Mucormycosis risk factors
<i>Revannavar et al. (2021)</i> <sup>29</sup>	A middle-aged female reported facial pain, fever and left eye ptosis. CT paranasal revealed opacification of sinuses and an MRI brain presented an acute infarct in the left parieto-occipital lobe. She tested positive for COVID-19 without signs of lung damage. Biopsy samples were collected during a functional endoscopic sinus surgery and revealed aseptate hyphae. Fungal culture was performed and confirmed infection by <i>Rhizopus</i> species. The eye ptosis was not resolved. Breathing support was not required.	Diabetes mellitus	COVID-19: None mentioned. Other treatment: AMB and aspirin.	Survived.	Rhino-orbital-cerebral	India	Diabetes
<i>Waizel-Haiat et al. (2021)</i> <sup>30</sup>	A 24-year-old female presented respiratory failure, pain in the left midface region, lid swelling and edema of left mucosa. Chest CT revealed atypical pneumonia due to COVID-19. Fungal culture in Sabouraud agar and direct examination revealed non-septate hyphae, characteristic of infection caused by the order Mucorales. Due complications of DKA, pulmonary aggravation and acute renal damage, the patient died. Mechanical ventilation was used.	Diabetes mellitus	COVID-19: None mentioned. Other treatment: AM-CL, IPM/LZD and AMB.	Deceased.	Rhino-orbital	Mexico	Diabetes

Continua...

Tabela 1: Continuação.

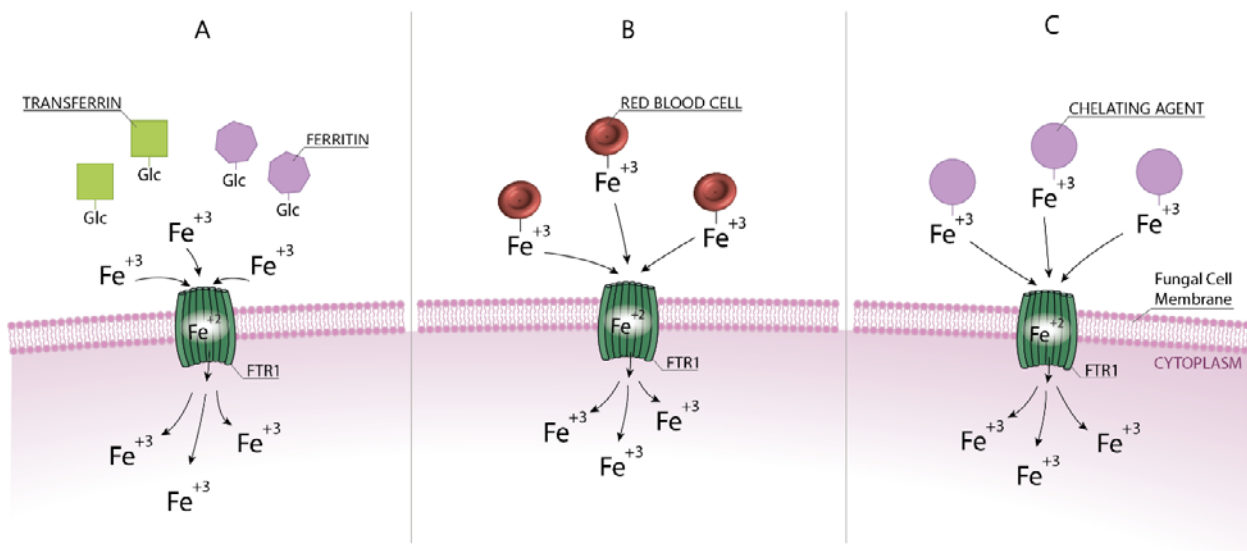
References	Infectious Disease Process	Underlying medical conditions	Therapeutics	Case outcome	Type of Mucormycosis	Location	Mucormycosis risk factors
Werthman-Ehrenreich (2021) <sup>4</sup>	A 33-year-old female was admitted with altered mental status, vomiting, cough and dyspnea. Left eye ptosis was noticed and brown dry secretion was found in the palate through physical examination. Chest X-Ray revealed lobe consolidation and pneumonia. A head CT exhibited sinus mucosal thickening and opacities. The microbiological diagnosis confirmed mucormycosis infection. Ischemia and infarction were demonstrated in the brain MRI. Neurosurgery intervention was not performed. Breathing support not informed.	Hypertension and asthma	COVID-19: REM. Other treatment: VAN, TZP and AMB.	Deceased.	Rhino-orbital-cerebral	USA	None
Zurl et al. (2021) <sup>31</sup>	A 53-year-old male reported having dysosmia, sore throat and fever while hospitalized. Chest CT revealed bilateral infiltrates in the lungs. After testing positive for SARS-CoV-2, the patient developed moderate acute respiratory distress syndrome and asked for assisted breathing. The patient died after a worsening of his hemodynamic condition. Autopsy revealed fungal hyphae in lung tissue. Genetic sequencing confirmed as <i>Rhizopus microsporus</i> .	Acute myeloid leukemia, obesity, myelodysplastic syndrome	COVID-19: TCZ and PRDL. Other treatment: VOZ, TZP + LZD.	Deceased.	Pulmonary	Austria	Immunosuppression, steroid therapy

CAS: Caspofugine; AMB: Amphotericin B; VOZ: Voriconazole; AZT: Azithromycin; AM-CL: Amoxicillin-Clavulanate; HCQ: Hydroxychloroquine; MER: Meropenem; REM: Remdesivir; DEX: Dexamethasone; FEP: Cefepime; CRO: Ceftriaxone; PRDL: Prednisolone; ISZ: Isavuconazole; FLU: Fluconazole; PSZ: Posaconazole; VAN: Vancomycin; mPRED: Methylprednisolone; TCZ: Tocilizumab; PDN: Prednisone; TZP: Piperacillin-Tazobactam; LPV/r: Lopinavir-Ritonavir; IFN $\alpha$ : Interferon alfa; CYA: Cyclosporine; TGC: Tigecycline; TEC: Teicoplanin; MTZ: Metronidazole; TOB: Tobramycin; OTV: Oseltamivir; SG: Sitagliptin; MF: Metformin; OMEP: Omeprazole; LZD: Linezolid; IPM: Imipenem; MALDI-TOF: Matrix-Assisted Laser Desorption Ionization – Time of Flight; DKA: Diabetic ketoacidosis.

The majority of isolated species in patients with mucormycosis belong to the *Mucoraceae* family, especially *Rhizopus oryzae*<sup>2</sup>. This ubiquitous mold is the most frequent *Rhizopus* species in the environment and has been identified all around the world<sup>32,33</sup>, which might explain why *R. oryzae* is the most common cause of mucormycosis. The infectious process by fungi of the order Mucorales begins through the inhalation of spores, or even by inoculation in mechanical traumas and through their ingestion – colonizing the gastrointestinal tract. After spore germination, angioinvasion allows the pathogen to spread through the blood, affecting multiple organs<sup>34</sup>. In this scenario, mechanical ventilation used in COVID-19 patients becomes a potential gateway for mucormycosis agents – which benefit from the patients' altered state of immunity. In addition to this condition, these fungi have important virulence factors that contribute to the establishment of fungal disease<sup>34</sup>, which may justify its high incidence in COVID-19 patients. Besides, Ibrahim et al.<sup>35</sup>, revealed that *R. oryzae* hyphae and spores have the ability to adhere to endothelial cells in vitro and damage them.

Furthermore, *R. oryzae* can obtain iron from the host through high affinity iron permease

(FTR1), a component of a cytoplasmic membrane reductive-oxidase complex. Iron is an essential micronutrient for human life that has an important role in cell growth and virulence of several pathogens. However, increased iron serum levels can result in toxicity, mucosal damage and impaired immune response due to oxidative cell injury, enhancing the risk of fungal infections<sup>36,37</sup>. Iron is stripped by the FTR1 system from heme, transferrin, ferritin and chelating agents, such as deferoxamine, which was introduced in 1960s and became to be the first iron chelator used in clinical practice<sup>38</sup> (Figure 2). The ferric iron is reduced into its more soluble form, carried through the fungus cell membrane into the cytoplasm and oxidated into ferric iron, that enhances the virulence of the pathogen, over a mechanism that remains unclear<sup>33</sup>. Ibrahim et al.<sup>10</sup>, study revealed that FTR1 expression by *Rhizopus oryzae* is upregulated in a murine model of hyperferritinemia. However, Ibrahim further showed that FTR1 inhibition decreased the virulence and passive anti-FTR1 immunotherapy in diabetic ketoacidosis (DKA) mice protected against *R. oryzae* infection, which suggests that iron is a crucial component in the progression of mucormycosis<sup>10</sup>.



**Figure 2:** Mechanisms of Mucorales FTR1 complex involved in iron sequestration during mucormycosis. A: Hyperglycemic state of diabetic patients leads to a glycosylation (Glc) of transferrin and ferritin, releasing ferric iron (Fe<sup>+3</sup>) into the blood stream, which is carried through the fungal cell membrane by the FTR1 complex; B: Ferric iron contained in red blood cells is stripped from heme and transported intracellularly by the high affinity iron permease system; C: Chelating agents used as therapeutic measures during iron overload in diabetic patients also provide source of a ferric iron, which is carried across the fungal cell membrane by the FTR1 system.

First described in *Saccharomyces cerevisiae*, FTR1 is a highly conserved gene in fungi that, later, was found to be expressed in *Candida albicans* as well as in green algae<sup>39-41</sup>. However, in these organisms, the FTR1 upregulation occurs in low iron concentrations, which contrasts with *R. oryzae* upregulated FTR1 during iron overload – a condition that can occur in diabetic and COVID-19 patients<sup>40-43</sup>. Since the use of deferoxamine worsens the survival of animal models of mucormycosis and lead to a higher mortality rate in patients with the fungal infection<sup>44</sup>, recent data has suggested using lactoferrin to manage iron serum levels. This potential iron-chelator shows that its fungistatic and immune regulator activity can be a helpful tool in the adjuvant therapy of mucormycosis<sup>45</sup>.

In a similar way to Mucorales infection, COVID-19 modifies the iron metabolism of the host. Increased ferritin levels and iron overload associated with coronavirus disease have been described in the literature<sup>46</sup>. During SARS-CoV-2 infection, the inflammatory process releases cytokines that increase intracellular iron, leaking the metal into the bloodstream and establishing a higher risk of mucormycosis<sup>47</sup>. In this context, ferritin – an iron storage protein and marker for acute inflammation, might be an abundant source of iron for Mucorales – additionally to transferrin, chelating agents and red blood cells previously described by Ibrahim et al.<sup>33,48</sup>. Since ferritin levels increase in diabetic patients and during SARS-CoV-2 infection<sup>26,49</sup>, this globular protein could offer Mucorales easy access to iron, increasing its virulence mechanisms, facilitating the fungus to establish itself in the host and providing more fatal outcomes. In this review, only five case reports presented patients with hyperferritinemia<sup>14,17,20,21,27</sup> (Table 1), although it is known that most case reports did not have described serum iron and ferritin levels and it is likely that more patients may have had an iron overload that potentiated the progression of mucormycosis.

### GRP78 expression and COTH3 interaction

GRP78 is a class of stress-responsive heat-shock proteins involved with the unfolded protein response process in the endoplasmic reticulum lumen. Under normal conditions, GRP78 directs misfolded proteins to refolding and degradation mechanisms. However, under stress conditions, GRP78 can break out of the endoplasmic reticulum and settle in the cell membrane as an exposed protein, characteristic of different types of cancer and an enabler of various viral infections, such as Dengue Virus, Zika Virus, Middle-East Respiratory Syndrome Coronavirus and, most recently, SARS-CoV-2<sup>50-52</sup>.

Curiously, GRP78 was revealed as a mediator in host cell invasion by Mucorales as well<sup>53</sup>.

In 2014, Gebremariam et al.<sup>53</sup> identified a spore coating protein family in *Rhizopus oryzae*, CoH3, which mediates the attachment to GRP78 and promotes fungal endocytosis, invading host endothelial cells. They also demonstrated that anti-CoH antibodies (Abs) therapy protected a murine model of DKA from mucormycosis and showed that a mutant of *R. oryzae* with downregulated CoH expression presented decreased virulence. Furthermore, GRP78 expression is upregulated in hyperglycemic mice with iron overload and anti-GRP78 Abs therapy protected the murine model from mucormycosis<sup>8</sup>. In this context, the remarkable ability of the fungus to invade and damage host cells challenges the immunity of patients with DKA which, among its many complications, expresses a ligand – GRP78 that facilitates the fungal infection. Considering that until this moment no records have been found in the literature that GRP78 binds to any other fungi, it is possible that this interaction may be unique to these eukaryotes, which requires further research to prove the supposed exclusivity.

Moreover, recent data<sup>54</sup> has shown that there is increased GRP78 serum levels in COVID-19 patients, which supports Ibrahim et al.<sup>51</sup> findings that indicated GRP78 was a receptor for SARS-CoV-2. However, the impact of increased expression of GRP78 on the prognosis of COVID-19 patients is not fully determined. Although GRP78 levels have not been measured in any case report, is expected that its expression would be increased, since all patients tested positive for COVID-19 and most were diabetic (Table 1), which provides potentially aggravating components for the development of mucormycosis and its fatal outcomes. In addition, most of case reports were described in India – where over than 65 million adults has diabetes<sup>55</sup>, a risk factor for COVID-19 and mucormycosis<sup>6,56</sup>.

### Host factors

#### Systemic corticosteroid therapy

Corticosteroids are among the most commonly prescribed medications available and these drugs are used quite broadly due to their potent anti-inflammatory and immunosuppressive properties<sup>57</sup>. The use of glucocorticoids (GC) during the COVID-19 pandemic as an adjuvant therapy has significantly increased. The World Health Organization has initially not recommended its use outside of clinical trials. However, in September 2020, new guidance based on moderate certainty evidence was proposed with a strong recommendation about using steroid therapy to treat patients with severe COVID-19, in order to control the cytokine storm caused by the infection<sup>58-60</sup>. The effectiveness of corticosteroid therapy on SARS-CoV-2 infections remains controversial.

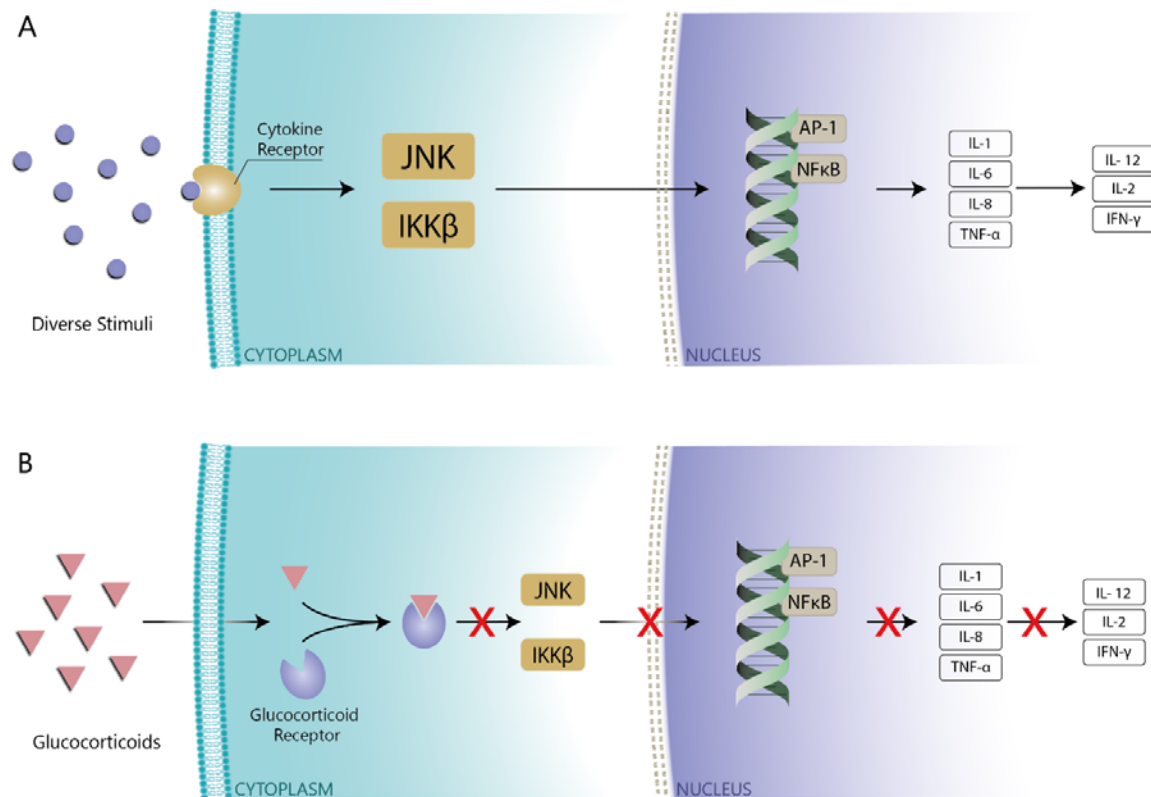


COVID-19 patients demonstrated delayed viral clearance times and there has been shown to be a not significantly statistical improvement in survival rates when steroid treatment was been used<sup>61</sup>.

According to the selected case reports in this review arranged in Table 1, patients who were treated for COVID-19 with corticosteroids developed mucormycosis. These findings corroborate Rickerts, Böhme and Just-Nübling<sup>6</sup> study, which suggested systemic corticosteroid therapy was a risk factor for the fungal infection and supports Lionakis and Kontoyiannis<sup>62</sup> data, which proposed that high dose steroid treatment and its long-term use increased the susceptibility to opportunistic fungal infections – as invasive aspergillosis, candidaemia, cryptococcosis and zygomycosis, due to GC immunosuppressive effects. In this context, the risk of infection is directly affected by underlying medical conditions that determine the duration of corticosteroid therapy and the dosage. Moreover, viral, bacterial and parasitic infections can be predisposed by GC as well<sup>63</sup>.

The suppression of host immunity due to chronic high-dose steroid therapy, associated with microangiopathy of diabetes, peripheral microthrombi in SARS-CoV-2 infection and the inherent

angioinvasive nature of Mucorales provide an ideal set of factors for the progression of mucormycosis<sup>64</sup>. The transcriptional modulation mechanism of glucocorticoids inhibits the c-Jun N-terminal kinase (JNK) pathway and kinase- $\beta$  (IKK $\beta$ ) resulting in the repression of nuclear factor- $\kappa$ B (NF $\kappa$ B) and activator protein 1 (AP-1), important transcription factors involved in monocyte-macrophage activation. The inhibition of NF $\kappa$ B and AP1 reduces the macrophage secretion of pro-inflammatory cytokines, like interleukin-1 (IL-1), IL-6, IL-8 and tumor necrosis factor- $\alpha$  (TNF- $\alpha$ ), which are essential to the innate immunity's line of defense against fungi. In addition, steroid therapy reduces the secretion of IL-12, IL-2 and interferon  $\gamma$ , which affects the adaptive immune response (Figure 3). Furthermore, glucocorticoids cause an imbalance in T-helper (Th) cells, which produces an enhanced Th2 cytokine response that leads to an impaired phagocytic function. Associated with NF $\kappa$ B inhibition by steroids, anti-apoptotic effects are observed in dysfunctional neutrophils and suppression of cell adhesion molecules required for lymphocytic signaling, as CD18 and intercellular adhesion molecule 1 (ICAM-1), were observed as well<sup>62,65,66</sup>.



**Figure 3:** Mechanisms of the host immune response mediated by glucocorticoids. A: Diverse stimuli can mobilize the JNK and IKK $\beta$  pathway leading to the activation of transcriptional factors AP-1 and NF $\kappa$ B, which promotes expression of inflammatory genes that provide an effective immune response; B: Glucocorticoids enter the cell and bind to glucocorticoids receptor, inhibiting the JNK and IKK $\beta$  pathway, which represses the AP-1 and NF $\kappa$ B transcriptional factors – leading to

a dysfunctional immune response.

Besides, steroid therapy can develop resistance to neuromuscular blocking drugs – generally used in patients that require mechanical breathing support, hyperglycemia, neutropenia and can also predispose multiple opportunistic infections<sup>67</sup>. These features could explain the high incidence of mucormycosis in diabetic patients with COVID-19 that were treated with corticosteroids and reveal that strict monitoring and management of corticosteroid therapy might be a valuable tool to control the progression of SARS-CoV-2 and Mucorales infections.

### Hyperglycemia and diabetes mellitus

Similar to the immunosuppressive effects of corticosteroid therapy, hyperglycemia and ketoacidosis can also suppress the immune system by impairing chemotaxis and phagocytic function. Mooradian et al.<sup>68</sup> study revealed that peripheral mononuclear blood cells isolated from diabetic patients had a lower levels of IL-1 secretion compared to healthy controls. Additional data also showed that diabetic patients presented suppression of IL-2, IL-6 and IL-10 cytokine secretion, which affects antibody production and increases the risk of infection. Diabetic patients exhibited greater tumor necrosis factor alpha (TNF- $\alpha$ ) and IL-8 levels as well. However, it is has been reported in the literature that high concentrations of TNF- $\alpha$  cause insulin resistance by inhibiting the peroxisome proliferator-activated receptor-gamma, which leads to a worsening of hyperglycemia condition<sup>69</sup>. Clinical evidence revealed that patients with diabetes and dysfunctional phagocytes are more susceptible to developing fungal infection<sup>2</sup>. Furthermore, hyperglycemia induces transferrin and ferritin glycosylation, which decreases the iron binding to these proteins and increases the serum and intracellular iron levels (Figure 2), generating reactive oxygen species that lead to tissue damage<sup>70</sup>. The described mechanisms above support the increased risk of mucormycosis in diabetic patients, since cytokine production is suppressed and the amount of serum iron is increased.

Notably, some patients described in this review, who reported a history of diabetes, had episodes of DKA when hospitalized (Table 1). The acidic environment caused by hyperglycemia decreased the transferrin's iron-binding ability, which released the metal into the bloodstream<sup>71</sup>. High iron serum levels lead to a higher expression of GRP78, that binds to

spore coat protein of Mucorales and mediates the fungal invasion<sup>53</sup>. However, Gebremariam et al.<sup>72</sup> study found that sodium bicarbonate reversed the acidosis in ketoacidotic mice, which protected them from mucormycosis and highlighted the importance of pH correction as a therapeutic measure.

Similarly, the spike protein of SARS-CoV-2 also binds to GRP78, which expression is increased during the infection, allowing virus attachment and cell invasion. Furthermore, COVID-19 induces hyperglycemia by affecting the function of pancreatic beta cells, requiring insulin therapy even in euglycemic patients<sup>51,73</sup>. In these circumstances, hyperglycemia creates a potential gateway for both pathogens and suggests strict glycemic control as a possible target to prevent the progression of mucormycosis and SARS-CoV-2 infection.

### Conclusion

Mucormycosis and COVID-19 coinfection demonstrates outstanding strategies to invade the human organism and survive against the immune response. These actions include taking advantage of a weakened immune system with a reduced response, which given the virulence factors of these pathogens, is very limited. The expression of ligands that interact with human receptors, such as the Coth3-GRP78 and spike protein-GRP78 interaction, enable Mucorales and SARS-CoV-2, respectively, to enter the host. Highlighting the opportunism and invasion skills of these microorganisms, host factors as diabetes, iron overload and systemic corticosteroid therapy facilitate these infections. However, understanding the mechanisms Mucorales and SARS-CoV-2 operate to accomplish the infection reveals a key point to, possibly, an effective therapy. Strict glycemic control, as well as adequate management of iron stores, might destabilize the main point of the infectious process, which relies on iron and glucose to establish itself. Without these components, the virulence of Mucorales is affected and the host's immune response can operate more effectively. In addition, GRP78 might be a therapeutic target to prevent the entry of both pathogens. Anti-GRP78 Abs therapy, as well as anti-Coth and anti-SARS-CoV-2 allied to supportive care approaches, could prevent the invasion of Mucorales and Coronavirus and improve its fatal outcomes.

## REFERENCES

1. Huang C, Wang Y, Li X, Ren L, Zhao J, Hu Y, et al. Clinical features of patients infected with 2019 novel coronavirus in Wuhan, China. *Lancet*. 2020;395(10223):497-506.
2. Spellberg B, Edwards J Jr, Ibrahim A. Novel perspectives on mucormycosis: pathophysiology, presentation, and management. *Clin Microbiol Rev*. 2005;18(3):556-69.
3. Gandra S, Ram S, Levitz SM. The "Black Fungus" in India: the emerging syndemic of COVID-19-associated mucormycosis. *Ann Intern Med*. 2021;174(9):1301-2.
4. Werthman-Ehrenreich A. Mucormycosis with orbital compartment syndrome in a patient with COVID-19. *Am J Emerg Med*. 2021;42:264.e5-264.e8.
5. Tedder M, Spratt JA, Anstadt MP, Hegde SS, Tedder SD, Lowe JE. Pulmonary mucormycosis: results of medical and surgical therapy. *Ann Thorac Surg*. 1994;57(4):1044-50.
6. Rickerts V, Böhme A, Just-Nübling G. [Risk factor for invasive zygomycosis in patients with hematologic malignancies]. *Mycoses*. 2002;45 Suppl 1:27-30.
7. Brunke S, Mogavero S, Kasper L, Hube B. Virulence factors in fungal pathogens of man. *Curr Opin Microbiol*. 2016;32:89-95.
8. Liu M, Spellberg B, Phan QT, Fu Y, Fu Y, Lee AS, et al. The endothelial cell receptor GRP78 is required for mucormycosis pathogenesis in diabetic mice. *J Clin Invest*. 2010;120(6):1914-24.
9. Allam L, Ghriji F, Mohammed H, El Hafidi N, El Jaoudi R, El Harti J, et al. Targeting the GRP78-dependant SARS-CoV-2 cell entry by peptides and small molecules. *Bioinform Biol Insights*. 2020;14:1177932220965505.
10. Ibrahim AS, Gebremariam T, Lin L, Luo G, Husseiny MI, Skory CD, et al. The high affinity iron permease is a key virulence factor required for *Rhizopus oryzae* pathogenesis. *Mol Microbiol*. 2010;77(3):587-604.
11. Walsh TJ, Gamaletsou MN, McGinnis MR, Hayden RT, Kontoyiannis DP. Early clinical and laboratory diagnosis of invasive pulmonary, extrapulmonary, and disseminated mucormycosis (zygomycosis). *Clin Infect Dis*. 2012;54 Suppl 1:S55-60.
12. Paltauf A. Mycosis mucorina: ein beitrag zur kenntniss der menschlichen fadenpilzkrankungen. *Archiv F Pathol Anat*. 1885;102:543-64.
13. Prakash H, Chakrabarti A. Global epidemiology of mucormycosis. *J Fungi (Basel)*. 2019;5(1):26.
14. Alekseyev K, Didenko L, Chaudhry B. Rhinocerebral mucormycosis and COVID-19 pneumonia. *J Med Cases*. 2021;12(3):85-9.
15. Arana C, Cuevas Ramírez RE, Xipell M, Casals J, Moreno A, Herrera S, et al. Mucormycosis associated with COVID-19 in two kidney transplant patients. *Transpl Infect Dis*. 2021;23(4):e13652.
16. Garg D, Muthu V, Sehgal IS, Ramachandran R, Kaur H, Bhalla A, et al. Coronavirus Disease (Covid-19) Associated Mucormycosis (CAM): case report and systematic review of literature. *Mycopathologia*. 2021;186(2):289-98.
17. Johnson AK, Ghazarian Z, Cendrowski KD, Persichino JG. Pulmonary aspergillosis and mucormycosis in a patient with COVID-19. *Med Mycol Case Rep*. 2021;32:64-7.
18. Kanwar A, Jordan A, Olewiler S, Wehberg K, Cortes M, Jackson BR. A fatal case of *Rhizopus azygosporus* pneumonia following COVID-19. *J Fungi (Basel)*. 2021;7(3):174.
19. Karimi-Galougahi M, Arastou S, Haseli S. Fulminant mucormycosis complicating coronavirus disease 2019 (COVID-19). *Int Forum Allergy Rhinol*. 2021;11(6):1029-30.
20. Khatri A, Chang KM, Berlinrut I, Wallach F. Mucormycosis after Coronavirus disease 2019 infection in a heart transplant recipient – case report and review of literature. *J Mycol Med*. 2021;31(2):101125.
21. Krishna V, Morjaria J, Jalandari R, Omar F, Kaul S. Autoptic identification of disseminated mucormycosis in a young male presenting with cerebrovascular event, multi-organ dysfunction and COVID-19 infection. *IDCases*. 2021;25:e01172.
22. Maini A, Tomar G, Khanna D, Kini Y, Mehta H, Bhagyasree V. Sino-orbital mucormycosis in a COVID-19 patient: a case report. *Int J Surg Case Rep*. 2021;82:105957.
23. Mehta S, Pandey A. Rhino-orbital mucormycosis associated with COVID-19. *Cureus*. 2020;12(9):e10726.
24. Mekonnen ZK, Ashraf DC, Jankowski T, Grob SR, Vagefi MR, Kersten RC, et al. Acute invasive rhino-orbital mucormycosis in a patient with COVID-19-associated acute respiratory distress syndrome. *Ophthalmic Plast Reconstr Surg*. 2021;37(2):e40-80.
25. Monte ES Jr, Santos MEL, Ribeiro IB, Luz GO, Baba ER, Hirsch BS, et al. Rare and fatal gastrointestinal mucormycosis (zygomycosis) in a COVID-19 patient: a case report. *Clin Endosc*. 2020;53(6):746-9.
26. Nehara HR, Puri I, Singhal V, Ih S, Bishnoi BR, Sirohi P. Rhinocerebral mucormycosis in COVID-19 patient with diabetes a deadly trio: case series from the north-western part of India. *Indian J Med Microbiol*. 2021;39(3):380-3.
27. Placik DA, Taylor WL, Wnuk NM. Bronchopleural fistula development in the setting of novel therapies for acute respiratory distress syndrome in SARS-CoV-2 pneumonia. *Radiol Case Rep*. 2020;15(11):2378-81.
28. Rao R, Shetty AP, Nagesh CP. Orbital infarction syndrome secondary to rhino-orbital mucormycosis in a case of COVID-19: clinico-radiological features. *Indian J Ophthalmol*. 2021;69(6):1627-30.
29. Revannavar SM, P S S, Samaga L, V K V. COVID-19 triggering mucormycosis in a susceptible patient: a new phenomenon in the developing world? *BMJ Case Rep*. 2021;14(4):e241663.
30. Waizel-Haiat S, Guerrero-Paz JA, Sanchez-Hurtado L, Calleja-Alarcon S, Romero-Gutierrez L. A case of fatal rhino-orbital mucormycosis associated with new onset diabetic ketoacidosis and COVID-19. *Cureus*. 2021;13(2):e13163.
31. Zurl C, Hoenigl M, Schulz E, Hatzl S, Gorkiewicz G, Krause R, et al. Autopsy proven pulmonary

- mucormycosis due to *Rhizopus microsporus* in a critically ill COVID-19 patient with underlying hematological malignancy. *J Fungi (Basel)*. 2021;7(2):88.
32. Ribes JA, Vanover-Sams CL, Baker DJ. Zygomycetes in human disease. *Clin Microbiol Rev*. 2000;13(2):236-301.
33. Ibrahim AS, Spellberg B, Walsh TJ, Kontoyiannis DP. Pathogenesis of mucormycosis. *Clin Infect Dis*. 2012;54 Suppl 1:S16-22.
34. Steinbrink JM, Miceli MH. Mucormycosis. *Infect Dis Clin North Am*. 2021;35(2):435-52.
35. Ibrahim AS, Spellberg B, Avanesian V, Fu Y, Edwards JE Jr. *Rhizopus oryzae* adheres to, is phagocytosed by, and damages endothelial cells in vitro. *Infect Immun*. 2005;73(2):778-83.
36. Bhogireddy R, Krishnamurthy V, Jabaris S SL, Pullaiah CP, Manohar S. Is mucormycosis an inevitable complication of Covid-19 in India? *Braz J Infect Dis*. 2021;25(3):101597.
37. Chu S, McCormick TS, Lazarus HM, Leal LO, Ghannoum MA. Invasive fungal disease and the immunocompromised host including allogeneic hematopoietic cell transplant recipients: improved understanding and new strategic approach with sargramostim. *Clin Immunol*. 2021;228:108731.
38. Umemura M, Kim JH, Aoyama H, Hoshino Y, Fukumura H, Nakakaji R, et al. The iron chelating agent, deferoxamine detoxifies Fe(Salen)-induced cytotoxicity. *J Pharmacol Sci*. 2017;134(4):203-10.
39. Stearman R, Yuan DS, Yamaguchi-Iwai Y, Klausner RD, Dancis A. A permease-oxidase complex involved in high-affinity iron uptake in yeast. *Science*. 1996;271(5255):1552-7.
40. Mamouei Z, Zeng G, Wang YM, Wang Y. *Candida albicans* possess a highly versatile and dynamic high-affinity iron transport system important for its commensal-pathogenic lifestyle. *Mol Microbiol*. 2017;106(6):986-98.
41. Allen MD, del Campo JA, Kropat J, Merchant SS. FEA1, FEA2, and FRE1, encoding two homologous secreted proteins and a candidate ferrireductase, are expressed coordinately with FOX1 and FTR1 in iron-deficient *Chlamydomonas reinhardtii*. *Eukaryot Cell*. 2007;6(10):1841-52.
42. Schothorst J, Zeebroeck GV, Thevelein JM. Identification of Ftr1 and Zrt1 as iron and zinc micronutrient transceptors for activation of the PKA pathway in *Saccharomyces cerevisiae*. *Microb Cell*. 2017;4(3):74-89.
43. Habib HM, Ibrahim S, Zaim A, Ibrahim WH. The role of iron in the pathogenesis of COVID-19 and possible treatment with lactoferrin and other iron chelators. *Biomed Pharmacother*. 2021;136:111228.
44. Spellberg B, Ibrahim AS, Chin-Hong PV, Kontoyiannis DP, Morris MI, Perfect JR, et al. The Deferasirox-AmBisome Therapy for Mucormycosis (DEFEAT Mucor) study: a randomized, double-blinded, placebo-controlled trial. *J Antimicrob Chemother*. 2012;67(3):715-22.
45. Singh A, Ahmad N, Varadarajan A, Vikram N, Singh TP, Sharma S, et al. Lactoferrin, a potential iron-chelator as an adjunct treatment for mucormycosis – a comprehensive review. *Int J Biol Macromol*. 2021;187:988-98.
46. Perricone C, Bartoloni E, Bursi R, Cafaro G, Guidelli GM, Shoenfeld Y, et al. COVID-19 as part of the hyperferritinemic syndromes: the role of iron depletion therapy. *Immunol Res*. 2020;68(4):213-24.
47. Mahalaxmi I, Jayaramayya K, Venkatesan D, Subramaniam MD, Renu K, Vijayakumar P, et al. Mucormycosis: an opportunistic pathogen during COVID-19. *Environ Res*. 2021;201:111643.
48. Wang W, Knovich MA, Coffman LG, Torti FM, Torti SV. Serum ferritin: past, present and future. *Biochim Biophys Acta*. 2010;1800(8):760-9.
49. Kaye TB, Guay AT. Increased serum ferritin levels in patients with diabetes mellitus. *Mayo Clin Proc*. 1994;69(5):498-9.
50. Elfiky AA, Baghdady AM, Ali SA, Ahmed MI. GRP78 targeting: hitting two birds with a stone. *Life Sci*. 2020;260:118317.
51. Ibrahim IM, Abdelmalek DH, Elshahat ME, Elfiky AA. COVID-19 spike-host cell receptor GRP78 binding site prediction. *J Infect*. 2020;80(5):554-62.
52. Vuorio A, Kovanen PT. Mucormycosis and glucose-regulated protein 78 in COVID-19: amenable to statin treatment? *J Intern Med*. 2021;290(4):931-3.
53. Gebremariam T, Liu M, Luo G, Bruno V, Phan QT, Waring AJ, et al. CoH3 mediates fungal invasion of host cells during mucormycosis. *J Clin Invest*. 2014;124(1):237-50.
54. Sabirli R, Koseler A, Goren T, Turkcuer I, Kurt O. High GRP78 levels in Covid-19 infection: a case-control study. *Life Sci*. 2021;265:118781.
55. Nanditha A, Ma RC, Ramachandran A, Snehalatha C, Chan JC, Chia KS, et al. Diabetes in Asia and the Pacific: implications for the global epidemic. *Diabetes Care*. 2016;39(3):472-85.
56. Bloomgarden ZT. Diabetes and COVID-19. *J Diabetes*. 2020;12(4):347-8.
57. Schäcke H, Döcke WD, Asadullah K. Mechanisms involved in the side effects of glucocorticoids. *Pharmacol Ther*. 2002;96(1):23-43.
58. Yang JW, Yang L, Luo RG, Xu JF. Corticosteroid administration for viral pneumonia: COVID-19 and beyond. *Clin Microbiol Infect*. 2020;26(9):1171-7.
59. World Health Organization. *Corticosteroids for COVID-19: living guidance, 2 September 2020* [Internet]. Geneva: WHO; 2020 [cited 2023 July 18]. Available from: <https://apps.who.int/iris/handle/10665/334125>.
60. Liu Z, Shi F, Liu JX, Liu JQ, Li J, Wang Q, et al. Clinical efficacy of corticosteroids in the early stages of deterioration in COVID-19 pneumonia. *Infect Drug Resist*. 2021;14:2667-74.
61. Wang J, Yang W, Chen P, Guo J, Liu R, Wen P, et al. The proportion and effect of corticosteroid therapy in patients with COVID-19 infection: a systematic review and meta-analysis. *PLoS One*. 2021;16(4):e0249481.
62. Lionakis MS, Kontoyiannis DP. Glucocorticoids and invasive fungal infections. *Lancet*. 2003;362(9398):1828-38.

63. Cutolo M, Seriola B, Pizzorni C, Secchi ME, Soldano S, Paolino S, et al. Use of glucocorticoids and risk of infections. *Autoimmun Rev.* 2008;8(2):153-5.
64. Moorthy A, Gaikwad R, Krishna S, Hegde R, Tripathi KK, Kale PG, et al. SARS-CoV-2, uncontrolled diabetes and corticosteroids-an unholy trinity in invasive fungal infections of the maxillofacial region? A retrospective, multi-centric analysis. *J Maxillofac Oral Surg.* 2021;20(3):418-25.
65. Song IH, Gold R, Straub RH, Burmester GR, Buttgerit F. New glucocorticoids on the horizon: repress, don't activate! *J Rheumatol.* 2005;32(7):1199-207.
66. Bruna A, Nicolàs M, Muñoz A, Kyriakis JM, Caelles C. Glucocorticoid receptor-JNK interaction mediates inhibition of the JNK pathway by glucocorticoids. *EMBO J.* 2003;22(22):6035-44.
67. Mattos-Silva P, Felix NS, Silva PL, Robba C, Battaglini D, Pelosi P, et al. Pros and cons of corticosteroid therapy for COVID-19 patients. *Respir Physiol Neurobiol.* 2020;280:103492.
68. Mooradian AD, Reed RL, Meredith KE, Scuderi P. Serum levels of tumor necrosis factor and IL-1 alpha and IL-1 beta in diabetic patients. *Diabetes Care.* 1991;14(1):63-5.
69. Berbudi A, Rahmadika N, Tjahjadi AI, Ruslami R. Type 2 diabetes and its impact on the immune system. *Curr Diabetes Rev.* 2020;16(5):442-9.
70. Chavda VP, Apostolopoulos V. Mucormycosis – an opportunistic infection in the aged immunocompromised individual: a reason for concern in COVID-19. *Maturitas.* 2021;154:58-61.
71. Artis WM, Fountain JA, Delcher HK, Jones HE. A mechanism of susceptibility to mucormycosis in diabetic ketoacidosis: transferrin and iron availability. *Diabetes.* 1982;31(12):1109-14.
72. Gebremariam T, Lin L, Liu M, Kontoyiannis DP, French S, Edwards JE Jr et al. Bicarbonate correction of ketoacidosis alters host-pathogen interactions and alleviates mucormycosis. *J Clin Invest.* 2016;126(6):2280-94.
73. Jose A, Singh S, Roychoudhury A, Kholakiya Y, Arya S, Roychoudhury S. Current understanding in the pathophysiology of SARS-CoV-2-associated rhino-orbito-cerebral mucormycosis: a comprehensive review. *J Maxillofac Oral Surg.* 2021;20(3):373-80.

Received: 17 mar, 2022

Accepted: 17 mar, 2023