












## Conjunctival dermoid in a cat: case report

Page 1 a 4

[*Dermoide conjuntival em um gato: relato de caso*]

J.A.T. Pigatto , M. Torikachvili , M.P. Seibel , A.F. Silva , N.P. Méndez , L.S. Cargnin ,  
R.S. Rocha , J.G. Wronski , L. Sonne 

Universidade Federal do Rio Grande do Sul, UFRGS, Porto Alegre, RS, Brasil

### ABSTRACT

A dermoid is the presence of normal skin in an abnormal place. A mixed-breed, male, 4-month-old cat was presented with a history of ocular discomfort in the right eye. Ophthalmic examination on the right eye revealed lacrimation, blepharospasm, ocular discomfort and mild conjunctival hyperaemia. A mass with hair with a diameter of 5 mm on the temporal part of the bulbar conjunctiva was observed. Surgical excision of the mass was recommended. Histopathology of the excised tissue confirmed the diagnosis of a dermoid. There was no evidence of lesion recurrence 12 months after surgery. In the present case, complete surgical excision of the dermoid was curative. Although rare, dermoid should be included in the differential diagnosis of conjunctival disorders in cats.

Keywords: feline, ocular, choristoma, surgery

### RESUMO

*Dermoide é a presença de pele normal em local inadequado. Um gato, sem raça definida, macho, com quatro meses de idade, apresentou histórico de desconforto ocular no olho direito. O exame oftálmico do olho direito revelou lacrimejamento, blefarospasmo, desconforto ocular e hiperemia conjuntival. Observou-se uma massa com pelos de 5mm de diâmetro na parte temporal da conjuntiva bulbar. A excisão cirúrgica da massa foi recomendada. A histopatologia do tecido excisado confirmou o diagnóstico de dermoide. Não houve recidiva da lesão 12 meses após a cirurgia. No presente caso, a excisão cirúrgica completa do dermoide foi curativa. Embora raros, os dermoides devem ser incluídos no diagnóstico diferencial de afecções conjuntivais em gatos.*

*Palavras-chave: felino, ocular, coristoma, cirurgia*

### INTRODUCTION

A dermoid, or choristoma, is the presence of normal cutaneous tissue in an abnormal location in the body (Badanes and Ledbetter, 2019). Dermoids normally contain elements of normal skin such as epidermis, dermis, fat, sebaceous glands, hair follicles and, frequently, hair (Badanes and Ledbetter, 2019).

Several animal species can be affected by dermoids, including dogs (Balland *et al.*, 2015; Badanes and Ledbetter, 2019; Saraiva and Delgado 2020), cats (Cathelin *et al.*, 2022), cattle (Brudenall *et al.*, 2008), horses (Gornik *et al.*,

2015), among others (Wappler *et al.*, 2002). In addition to affecting animals, ocular dermoids have also been diagnosed in humans (Zhong *et al.*, 2018) and can occur anywhere in the body (Christmas, 1992). Ocular dermoids may affect the eyelids, conjunctiva, third eyelid and cornea (LoPinto *et al.*, 2016; Saraiva and Delgado, 2020). The definitive diagnosis is made by histopathological examination (Gornik *et al.*, 2015), and the recommended treatment typically consists of surgical removal of the dermoid (Badanes and Ledbetter, 2019). Ocular dermoid is uncommon in cats (Cathelin *et al.*, 2022). Review of the literature reveals few documented cases of corneal dermoids in cats (Labue, *et al.*, 1985; LoPinto, *et al.*, 2016) and a multicentre

retrospective study performed in France (Cathelin *et al.*, 2022). This is the first clinical case of an ocular dermoid in a cat documented in Brazil.

### CASE REPORT

A mixed-breed, male, 4-month-old cat presented at the Ophthalmology Section of Ophthalmology Section of the Federal University of Rio Grande do Sul (UFRGS), Porto Alegre, RS, Brazil, with a history of ocular discomfort in the right eye. Upon clinical examination, the cat had an optimum body condition score. Ophthalmic examination on the right eye revealed lacrimation, blepharospasm, ocular discomfort and mild conjunctival hyperaemia. A skin with hair mass with a diameter of 5 mm on the temporal part of the bulbar conjunctiva was observed (Fig. 1). Fluorescein staining of the cornea was negative. Biomicroscopic examination (SL-15 Portable Slit Lamp, Kowa, Japan) of the anterior segment was normal. Intraocular pressure was 19 and 17 mm Hg OD in the right and left eye, respectively, measured via rebound tonometry (Tonovet Finland Oy). No alterations were verified with fundoscopic examination. The ophthalmic examination did not show any abnormalities in the left eye. Based on the clinical presentation, the diagnosis of a dermoid was made. Complete blood count and serum chemistry profiles were normal. Surgical

excision of the mass was recommended. The procedure was performed under inhalation anesthesia and using an operating microscope. The surgical area was aseptically prepared. Using conjunctival scissors and conjunctival forceps the mass was excised. No intraoperative complications occurred during the procedure. Minimal hemorrhaging was observed during the dissection of the mass. The conjunctiva was not sutured, and the surgical wound healed by secondary intention. An Elizabethan collar was placed on the patient for 1 week. The cat was treated with dipyrone, 25mg/kg PO, every 24 hours for 3 days. Eye drops based on ciprofloxacin 0.3% and ketorolac tromethamine 0.5%, both every 6 hours, were administered for 15 days. Following surgery, the cat had no signs of ocular discomfort. The eyelid appearance was normal (Fig. 2). The mass excised was fixed in 10% neutral buffered formalin, prepared for light microscopy, and sections were stained with hematoxylin eosin. Histopathological examination revealed the presence of skin tissue containing keratinized stratified squamous epithelium, as well as skeletal muscle, collagen, blood vessels, hair follicles, sebaceous glands and sweat glands (Fig. 3). Periodic eye examinations were performed. Signs of blepharospasm were never seen again, and there was no evidence of lesion recurrence 12 months after surgery.

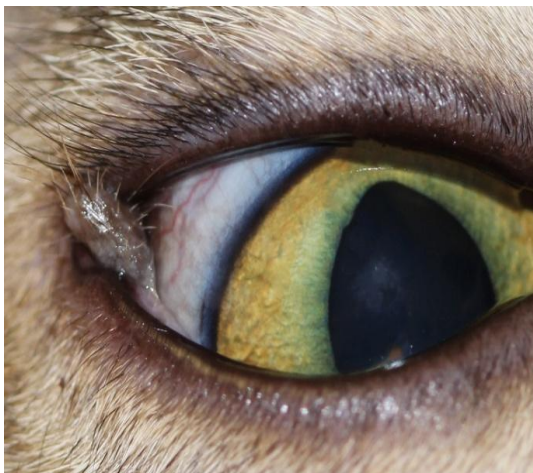

Figure 1. Conjunctival dermoid at the temporal bulbar conjunctiva in a mixed-breed, male, 4-month-old cat.

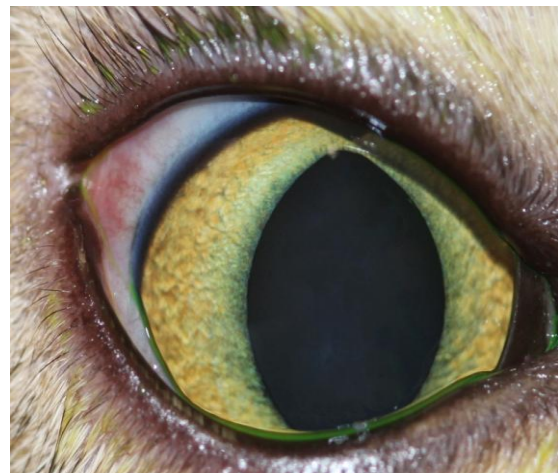

Figure 2. Image of the right eye 15 days after the surgical procedure in a mixed-breed, male, 4-month-old cat.

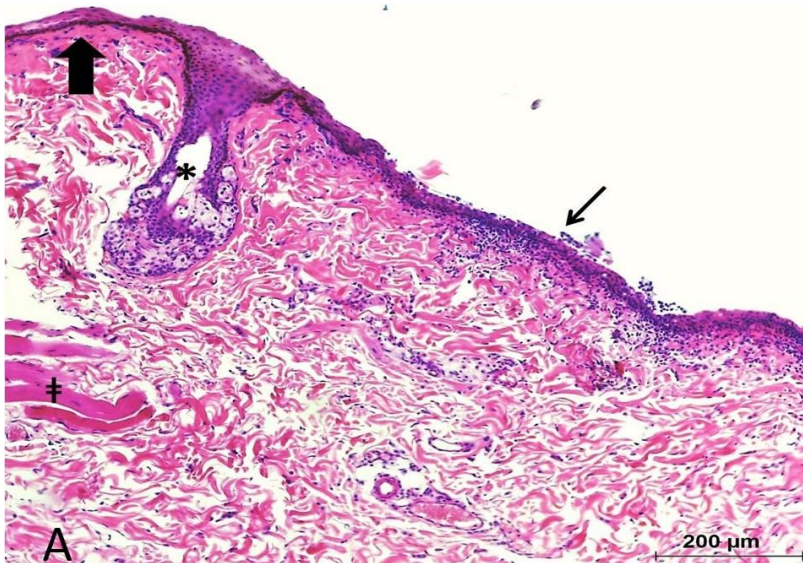


Figure 3A. Transition between normal conjunctival epithelium (narrow arrow) and squamous differentiation (thick arrow) of the conjunctival dermoid in a mixed-breed, male, 4-month-old cat. Glands attached to hair follicles (asterisk) and muscles (cross) are also demonstrated.

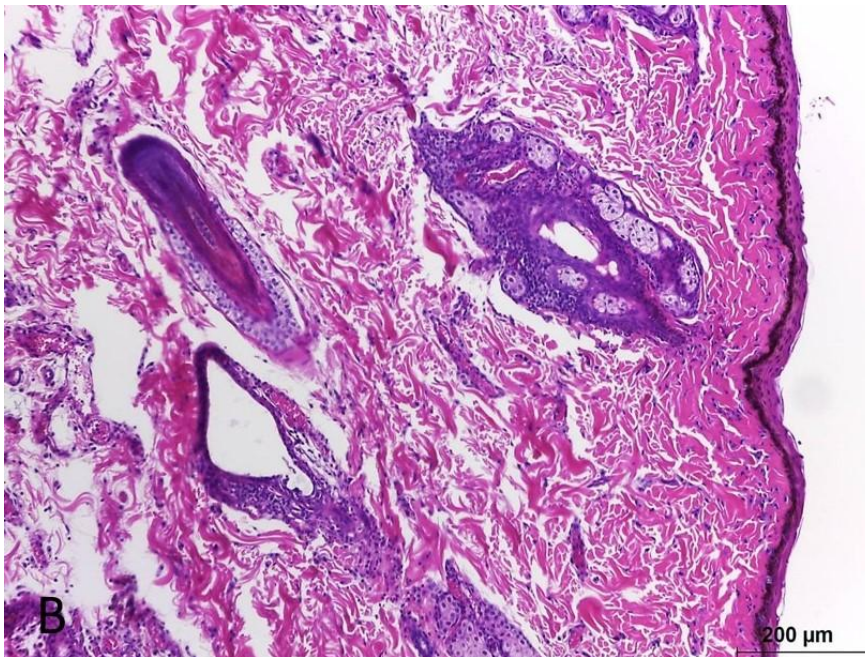


Figure 3B. Conjunctival dermoid in a mixed-breed, male, 4-month-old cat, demonstrating epithelium with squamous differentiation, hair follicles and glands attached sweat and sebaceous.

### DISCUSSION

Ocular dermoids have been reported in some species of animals (Badanes and Ledbetter, 2019) and in humans, at sites such as the conjunctiva, eyelid or nictitating membrane (Badanes and Ledbetter, 2019). Dermoids can be

unilateral or bilateral (Balland *et al.*, 2015). Although there are reports of bilateral dermoids in dogs, cattle and humans, they most commonly present unilaterally (Balland *et al.*, 2015). Dermoids in cats are rare, and ocular dermoids occur mainly in the temporal limbus (Labue, *et al.*, 1985, Cathelin *et al.*, 2022) and more rarely

in the dorsal cornea (LoPinto, *et al.*, 2016). In the present case, the dermoid was unilateral and located in the temporal bulbar conjunctiva. The main clinical signs caused by dermoids include blepharospasm, epiphora and conjunctival congestion (Balland *et al.*, 2015). Corneal injuries can be concomitantly present (Brudenall *et al.*, 2008). Hair from the lesions is responsible for irritation, resulting in chronic inflammation with significant discomfort and secondary complications (Cathelin *et al.*, 2022). In this case, the dermoid caused ocular irritation, blepharospasm and epiphora. Clinically, dermoids are easy to detect and diagnose (Zhong *et al.*, 2018). The clinical presentation of the dermoid in the present case was similar to that described in a previously reported case (Badanes and Ledbetter, 2019). The diagnosis of a conjunctival dermoid in the present case was based on clinical signs and confirmed by histopathology. For the treatment of ocular dermoids, surgery is generally performed to improve vision or cosmetic appearance, to impede growth and to prevent conjunctival and corneal irritation and subsequent inflammation (Cathelin *et al.*, 2022). In this case, it was decided to perform excisional biopsy to confirm the diagnosis. No complications were observed during the surgical procedure. The minimal hemorrhage observed during dermoid dissection was controlled with anesthetic and vasoconstrictor eye drops. The composition of dermoids varies, but frequently, they have the characteristics of normal skin (Wappler *et al.*, 2022; Badanes and Ledbetter, 2019). After surgical treatment of the ocular dermoid, there is a complete remission of clinical signs (Cathelin *et al.*, 2022). In the case reported after surgical treatment, no signs of ocular discomfort were ever observed again. If the dermoid is completely excised surgically, it does not recur (Cathelin *et al.*, 2022). In the present case, the dermoid was completely removed, and recurrence was not evident.

### CONCLUSION

Although rare, dermoids should be included in the differential diagnosis of conjunctival disorders in felines. In the present report, surgical excision was effective in treating a conjunctival dermoid in a cat.

### ACKNOWLEDGMENT

We would like to thank “Coordination for the Improvement of Higher Education Personnel” (CAPES) which provided the fellowship for three of the authors (M. Torikachvili, M.P. Seibel, and A. Fernandez).

### REFERENCES

- BADANES, Z.; LEDBETTER, E.C. Ocular dermoids in dogs: a retrospective study. *Vet. Ophthalmology*, v.22, p.760-766, 2019.
- BALLAND, O.; RAYMOND, I.; MATHIESON, I. *et al.* Canine bilateral conjunctivo-palpebral dermoid: description of two clinical cases and discussion of the relevance of the terminology. *Case Rep. Vet. Med.*, v.2015, p.1-6, 2015.
- BRUDENALL, D.K.; WARD, D.A.; KERR, L.A.; NEWMAN, S.J. Bilateral corneo-conjunctival dermoids and nasal choristomas in a calf. *Vet. Ophthalmol.*, v.11, p.202-206, 2008.
- CATHELIN, A.; AUGSBURGER, A.S.; ANNE, J. *et al.* Ocular dermoids in 13 cats: a multicentre retrospective study. *J. Feline Med. Surg.*, v.24, p.745-753, 2022.
- CHRISTMAS, R. Surgical correction of congenital ocular and nasal dermoids and third eyelid gland prolapse in related Burmese kittens. *Can. Vet. J.*, v.33, p.265-266, 1992.
- GORNIK, K.R.; PIRIE, C.G.; BEAMER, G.L. Unilateral choristoma of the nictitating membrane in a horse. *J. Am. Vet. Med. Assoc.* v.246, p.231-235, 2015.
- LABUE, R.; JONES, B.; JOHNSTONE, A. Congenital dermoid in a cat. *N. Z. Vet. J.*, v.33, p.154-155, 1985.
- LOPINTO, A.J.; PIRIE, C.G.; HUYHN, T.; BEAMER, G. Dorsally located corneal dermoid in a cat. *J. Feline Med. Surg. Open Rep.*, v.2, p.1-4, 2016.
- SARAIVA, I.Q.; DELGADO, E. Congenital ocular malformations in dogs and cats: 123 cases. *Vet. Ophthalmol.*, v.23, p.964-978, 2020.
- WAPPLER, O.; ALLGOEWER, I.; SCHAEFFER, E.H. Conjunctival dermoid in two guinea pigs: a case report. *Vet. Ophthalmol.*, v.5, p.245-248, 2002.
- ZHONG, J.; DENG, Y.; ZHANG, P. *et al.* New grading system for limbal dermoid: a retrospective analysis of 261 cases over a 10-year period. *Cornea*, v.37, p.66-71, 2018.