

Drug-based therapy for advanced adenoid cystic carcinoma: Current landscape and challenges based on an overview of registered clinical trials

Vivian Petersen Wagner^{a,*}, Renata Ferrarotto^b, Pablo Agustin Vargas^c,
Manoela Domingues Martins^{c,d}, Colin D. Bingle^e, Lynne Bingle^a

^a Academic Unit of Oral and Maxillofacial Medicine and Pathology, Department of Clinical Dentistry, University of Sheffield, Sheffield, UK

^b Department of Thoracic Head & Neck Medical Oncology, The University of Texas MD Anderson Cancer Center, Houston, TX, USA

^c Department of Oral Diagnosis, Piracicaba Dental School, University of Campinas, Piracicaba, São Paulo, Brazil

^d Oral Pathology Department, Federal University of Rio Grande do Sul, Porto Alegre, Brazil

^e Academic Unit of Respiratory Medicine, Department of Infection, Immunity and Cardiovascular Disease, University of Sheffield, Sheffield, UK

ARTICLE INFO

Keywords:

Head and neck cancer
Salivary gland cancer
Oncology
Chemotherapy

ABSTRACT

Adenoid cystic carcinoma (ACC) has a significant patient-population in need of effective systemic therapy, as no drug is currently approved by the FDA for its management. We critically reviewed ACC-clinical trials (CT) registered on the ClinicalTrials.gov website using "ACC" under condition or disease. Trials specifically designed to test a drug-based therapy for ACC (n = 33) were analyzed with most being one-arm phase II trials enrolling advanced, recurrent/metastatic, incurable ACC cases. Site restriction, maximum ECOG status, and period of disease progression varied as inclusion criteria. Small-molecule inhibitors were those most commonly investigated with Apatinib, Axitinib and Lenvatinib showing the best results in association with rigid enrollment criteria. The overall median time to progression remains modest and more efforts are urgently needed in this field. CTs designed to test drugs that act on key pathways associated with ACC aggressiveness are being conducted and represent a promising pathway if efficacy is proved.

1. Introduction

"Of all tumors in the head and neck region, the adenoid cystic carcinoma is one of the most biologically deceptive and frustrating in management. This is the opening statement of the classic Conley and Dingman report on the treatment of adenoid cystic carcinoma (ACC) (Conley and Dingman, 1974). Almost 75 years later, this feeling of frustration persists when managing advanced and metastatic cases as, to date, no significantly effective systemic therapy for ACC has been discovered. The current American Society of Clinical Oncology (ASCO) guidelines suggest that systemic therapy for ACC (and other salivary gland cancers) should not be offered outside of clinical trials (CT) due to the lack of robust evidence to support efficacy (Geiger et al., 2021).

ACC is one of the most common salivary gland cancers, but represents a rare cancer in the general population, with an incidence rate of 0.35 per 100,000 in the United States (US) (Boyle et al., 2020). This malignancy is acknowledged as "a slow killer" due to its tendency for late recurrences or metastasis and disease-related deaths occurring up to

30 years after the initial diagnosis (Andreasen, 2018). As a result, the 5-year survival rate of ACC underestimates its aggressiveness. For example, a study comprising 201 cases of ACC with long-term follow-up analysis showed that the 5-, 10- and 15-year survival rates were 90%, 75% and 68%, respectively (Bjørndal et al., 2015). Local recurrence can be difficult to treat because the site will already have been subjected to prior surgical intervention, often with associated radiotherapy (RT), which can negatively affect the tissue healing capacity. According to ASCO guidelines, postoperative RT should be offered to all patients with ACC who have undergone surgical resection due to the late-aggressive nature of the tumor (Geiger et al., 2021). Distant metastasis is diagnosed in around 55% of patients, representing a recurrent challenge in ACC management (van der Wal et al., 2002). The lungs are the most common site, but other sites include the liver, bones, and brain (Bjørndal et al., 2015).

Effective systemic therapies for ACC are urgently needed, yet no drug is currently fully approved by the FDA for ACC treatment. The process of drug discovery is laborious but for rare cancers, such as ACC, the

* Correspondence to: Academic Unit of Oral and Maxillofacial Medicine and Pathology, 19 Claremont Cres, Broomhall, Sheffield S10 2TA, UK.

E-mail address: v.wagner@sheffield.ac.uk (V.P. Wagner).

¹ ORCID: 0000-0002-1447-2135.

challenge is even higher. The aim of this paper was to determine the current status of the search for new systemic therapies by reviewing registered clinical trials.

2. Methods

2.1. Guideline

The PRISMA guideline for scoping reviews (PRISMA-ScR) was followed (Supplementary Table 1).

2.2. Search strategy

A manual search on the ClinicalTrials.gov website using “Adenoid Cystic Carcinoma” under condition or disease was undertaken in July 2022 and only interventional studies (clinical trials) were included. No restriction was made for status, eligibility criteria, study results, study phase, funder type or study documents. 124 clinical trials were identified (Supplementary Table 2).

2.3. Study selection

After an initial analysis, trials that did not evaluate a drug-based therapy were excluded (analysis of side effects of treatment, diagnostic methods, surgical interventions, or RT approaches). Drug-based trials that included ACC among the diagnoses eligible for entering the study, but where outcomes were evaluated alongside other tumors, were also excluded from analysis. While some trials had a biological rationale behind the decision to include ACC, such as MYB-driven tumors (n = 1) or radioresistant tumors (n = 1), most of the studies that included ACC aimed to evaluate interventions on salivary gland cancer (n = 15), head and neck cancer (n = 9), solid malignancies (n = 23) or rare tumors (n = 2) (Supplementary Table 2). In other trials the decision to include ACC was based on disease site (e.g., sinonasal tumors, n = 2) or stage, such as advanced/metastatic/recurrent cases (n = 5), and not the diagnosis per se. Considering the important differences between ACC tumorigenesis and that of other head and neck tumors (including other salivary gland cancers) and other solid tumors, we decided not to further investigate these broader trials. Moreover, the number of ACC patients in the broader trials was very low meaning that the trial results are not easy to transpose to all ACC patients.

2.4. Data collection

Data associated with eligibility criteria (disease status, site, age, ECOG status and evidence of disease progression), CT status (completed, recruiting, active but not recruiting, not yet recruiting or unknown status), centers enrolling patients and drug being tested were extracted from the ClinicalTrials.gov database. Methodological data (CT phase, sample size) and outcomes (primary endpoint, complete response (CR), partial response (PR), and stable disease (SD) rates and progression free survival (PFS) time) were extracted from the following hierarchical order: 1- full journal manuscript; 2- conference proceedings; 3 - ClinicalTrials.gov database. The drugs being tested were also investigated with regard to class, FDA approval status, molecular target and adverse effects. The PFS time (in months) and confidence interval (CI) were retrieved and analyzed using GraphPad Prism (version 8.4.3 for macOS, GraphPad Software, San Diego, California, USA). A graph was constructed to compare the PFS time and confidence intervals of the different trials: y axis refers to the drugs tested and x axis represents PFS time in months. The bars represent lower and upper limits of confidence interval and the symbol the median PFS time.

3. Results and discussion

3.1. General characteristics of clinical trials

Thirty-three trials evaluating systemic therapy for ACC were analyzed (Supplementary Table 3). According to the ClinicalTrials.gov website, 17 were “completed”, 5 “recruiting”, 5 “active but not recruiting”, 1 “not yet recruiting” and 5 of “unknown status”. Fifteen trials were being conducted in the US only and a further 3 in the US and other countries. These findings, however, need to be interpreted with caution as ClinicalTrials.gov is a resource provided by the US National Library of Medicine (NLM), and despite being open for the registration of research studies being conducted around the world, a greater representation of American trials would be expected. Interestingly, and reinforcing this hypothesis, we identified published results of ACC-related CT conducted in countries such as the UK (Thomson et al., 2015) and Israel (Pfeffer et al., 2007) that were not originally found in our search.

In 12 of the trials (36.3%) reviewed patients were enrolled by more than one oncology center; range 2–51 centers. Collaborative networking is crucial to the success of clinical trials for rare cancers, as achieving a sample size that will allow statistical analysis can represent a significant challenge (Casali et al., 2015) and multicentre clinical trials (MCCT) have increased external validity as the subjects included are more heterogeneous. Furthermore, MCCT are led by experts with different backgrounds and their joint efforts, along with diverse experiences, strengthen the trial design and conclusions. Despite all these advantages, it is important to highlight that planning a MCCT can be more demanding as coordinating the tasks among the multiple centers and getting funding represent important challenges (Chung et al., 2010).

3.2. Types of drugs evaluated

The drugs investigated varied with most being evaluated by only one CT. A few, however, were investigated in more than one trial, including Apatinib (US and China), Dovitinib (Canada, US and Korea), Lenvatinib (US and Italy), Axitinib (China and US) and Tretinoin/ATRA (US and China). Small-molecule inhibitors (Apatinib, Dovitinib, Imatinib, Lenvatinib, Regorafenib and Axitinib) were more commonly investigated than monoclonal antibodies (mAbs) (Pembrolizumab, Brontictuzumab, Cetuximab, and Avelumab). There are important differences between these classes of drug, such as molecular weight, half-life, method of administration, degradation and individual variability, resulting in different pharmacokinetic properties (Imai and Takaoka, 2006). Small-molecule inhibitors have a smaller molecular weight than mAbs, allowing them to pass through the cell membrane and further penetrate solid tumors (Imai and Takaoka, 2006). The literature lacks a deeper discussion about which class of drug might be more suitable for salivary gland cancers, including ACC. As solid tumors, it might be presumed that the increased penetration by small-molecule inhibitors would suggest effectiveness in the treatment of salivary gland cancers. Interestingly, the two drugs which currently have full FDA approval for the treatment of secretory salivary gland carcinoma, for example, are small-molecule inhibitors: Larotrectinib (Hong et al., 2020) and Entrectinib (Doebele et al., 2020). These treatments were approved in 2018 and 2019, respectively, for cases with NTRK rearrangement. However, ASCO guidelines have endorsed mAbs for the systemic therapy of some salivary gland cancers, for example, that of HER2-positive salivary gland carcinoma, the most common salivary duct carcinoma, by mAbs such as trastuzumab, pertuzumab or adotrastuzumab (Geiger et al., 2021). The key to success appears to rely more on deregulated molecular pathways and drugs that can effectively interact with this, than the class of drug.

Only two of the mAbs tested in the ACC-related CT are considered immunotherapeutic agents: Pembrolizumab (PD-1 inhibitor) and Avelumab (PD-L1 inhibitor), demonstrating that this type of therapy is not

commonly assessed in ACC. Basic research has suggested that ACC is characterized by an immuno-depleted microenvironment alongside a low somatic tumor mutational burden (TMB), in comparison to other salivary gland cancers (Linxweiler et al., 2020). TMB and immune cell infiltration are considered complementary measures that can predict the response to immune checkpoint inhibitors blocking PD-1/PD-L1, and the profile observed in ACC suggests that PD-1/PD-L1 are not the best targets for future CT (Linxweiler et al., 2020), at least as monotherapy. The preliminary results of a US clinical trial evaluating Avelumab in association with Apatinib were recently presented at the 2022 ASCO Meeting (Ferrarotto et al., 2022a). The study reached its primary endpoint with 5 objective responses out of 28 evaluable patients (17.9%) and the median progression free survival, of 7.2 months, was satisfactory considering the usual time to progression without intervention (Ferrarotto et al., 2022a).

3.3. Clinical trials with published results

Of the 33 trials reviewed, results from only 9 (27%) were deposited in the ClinicalTrials.gov database (8 completed and 1 active, not recruiting). We performed a literature search using the trial reference numbers and identified a further 14 registered CT (42.4%) with full or preliminary results published in journal articles or conference proceedings. Detailed information on the outcomes of all 23 trials (Table 1) will be discussed from this point. Twenty-two (95%) were phase II trials and one did not report the phase status but was designed to evaluate disease progression after therapy, and so could be considered a phase II trial. Most trials (21/23–91%) were single arm trials and only two had comparison groups: pembrolizumab associated or not with radiotherapy in one study (Mahmood et al., 2021) and axitinib versus observation in the other (Kang et al., 2021). Phase II trials are historically designed as single-arm studies in which all the patients receive the same experimental therapy and the outcomes are compared to historical data on the standard response to current therapies or experts' opinion. Randomization and inclusion of two-arms in phase II trials is increasingly a topic of debate in the literature and it appears to be important when there is a gold-standard therapy or a substantial uncertainty about the response to the standard agent (Sambucini, 2015). With regard to the treatment of ACC we believe using single-arm phase II trials represents a more feasible approach as recruiting patients is not easy due to the rare nature of the tumor and a representative sample size in the experimental group increases the statistical power. A basic ethical aspect for CT protocols is that patients should not be offered a treatment inferior to what is otherwise available in clinical practice (Daugherty et al., 2008). As currently there are no standard drugs or therapy with proven efficiency for locally advanced, metastatic/recurrent, incurable ACC there are no ethical limitations for single-arm trials. Also, many single-arm phase II trials are conducted to test drug efficacy in metastatic disease, after progression on standard therapies, and again as ACC has no standard therapies there is no ethical limitation. Some consideration does need to be paid to the lack of observational groups in CT results and to the limited information about the mean PFS of advanced cases of ACC, prospectively and in a controlled setting. Kang et al., (2021) circumvented this by allowing crossover between observation and experimental group when progression was detected. Some drugs have been shown to significantly increase PFS times in advanced cases of ACC, as we will discuss further in this review. The inclusion of such drugs might be discussed for future randomized CT with comparison groups.

3.4. Patient enrollment

The number of patients enrolled in the reviewed CT ranged from 1 to 68, with a median of 28. Eligibility criteria is a key aspect in CT and can be categorized in terms of scientific features (e.g., diagnosis and disease stage), safety features (e.g., organ function and performance status), ethical features (e.g., life expectancy), and regulatory reasons (Kim

et al., 2015). Key criteria for enrollment are presented in Table 2. Most studies included locally advanced, recurrent or metastatic tumors with measurable and progressive disease. In 7 trials (30%) the tumor site (salivary gland or head and neck) was considered an inclusion criterion (the information was extracted from the inclusion criteria segment on the website but also from the trial title where present). Four trials reported that non-salivary gland cases were also eligible and in the remaining this information was not clearly stated. Patients under 18 years-old were only eligible in one CT, the remaining enrolling only adult patients. ECOG status varied between studies with a maximum score of 1 or 2 being allowed. Evidence of disease progression also varied between not being necessary, presence in any given time interval and in specific intervals before the initiation of the trial (varying between 6 and 12 months). Many other inclusion and exclusion criteria were described such as measurable disease according to Response Evaluation Criteria in Solid Tumors (RECIST), and adequate hematologic, renal and hepatic function for inclusion and presence of other cancers or baseline diseases, HIV positivity, pregnancy, lactant status, central nervous system disease and brain metastasis for exclusion.

Inclusion and exclusion criteria are important in guaranteeing similar baseline factors that could affect the response to therapy and exclude patients who may present increased risk of adverse effects, improving the trial safety (Jin et al., 2017). Nevertheless, there is a concern among oncologists that overly strict eligibility criteria can hinder patient enrollment, leading to lengthy trials, with increased complexity and cost (Jin et al., 2017). As an example, ECOG maximum performance status varied between 1 and 2 in the trials reviewed here and many studies only included adult patients. A survey conducted with physicians and faculty at the ASCO - American Association of Cancer Research Methods in Clinical Cancer Research (MCCR) Workshop revealed that respondents felt that age and ECOG status of 2 should not be considered exclusion criteria from trials of molecularly targeted agents in 83% and 53% of instances, respectively (Kim et al., 2015). ACC is more commonly diagnosed around the 5th and 6th decades, yet cases in adolescents do occur (Bjørndal et al., 2015). According to FDA guidance released in 2019, adolescents between the ages of 12 and 17 should be eligible for enrollment in adult oncology clinical trials at any stage of drug development if the tumor histology and disease course are similar to adult cancer under investigation, or the drug molecular target is also applicable (FDA guidance). Interestingly, adolescents have the lowest proportion of enrollment in CT compared to young children (under 12) and adults (Bleyer, 2007). We believe that exclusion of adolescents in ACC-related CT should be reconsidered and debated as their inclusion could represent a slight, but significant, increase in the eligible population for enrollment.

There is evidence of different behaviors of head and neck / salivary gland ACC and ACC at other sites. For example, while the 5-year survival rate for salivary gland ACC varies between 56% and 65% (Ciccolallo et al., 2009), rates for breast ACC are around 98%, directly contrasting with other triple-negative breast tumors (77%) and salivary gland ACC (Kulkarni et al., 2013). It is important to note that the rates are estimated based on the overall population and that most ACCs arising in the breast are diagnosed as localized disease with a low rate of node and distant metastases (Kulkarni et al., 2013). At the molecular level, it appears that ACC from different sites are similar, mostly being associated with MYB overactivation triggered by chromosomal translocations (Persson et al., 2009), which could be used as a biological rationale to not include site as an inclusion criterion in clinical trials, making the chances of patient enrollment higher.

3.5. Drug targets, approval status and adverse effects

In the CT with available results 18 different drugs were tested (Table 3) with small-molecule drugs being more commonly investigated (10/18 – 56%) than other classes of drugs. Five compounds (28%), AL101, Apatinib, Brontictuzumab, Dovitinib and MK2206, are not

Table 1
Main data and results from registered ACC CT with available results.

CT number / reference	Drug name	Phase	N	Primary Endpoint	Complete Response	Partial Response	Stable Disease	Median PFS (95% CI) in months
NCT00017498 * (van Herpen et al., 2008)	Gemcitabine	II	21	ORR by RECIST	0	0	61% (5/18)	NA
NCT00077428 * (Argiris et al., 2011)	Doxorubicin and Bortezomib	II	24	ORR by RECIST	0	0 for Bortezomib alone and 10% (1/10) for Bortezomib + Doxorubicin	71% (15/21) for Bortezomib alone and 60% (6/10) for Bortezomib + Doxorubicin	6.37 (1.61–8.74) – considering all patients enrolled
NCT00581360 (ClinicalTrials.gov)	Doxorubicin and Bortezomib	II	9	ORR by RECIST	0	0	100% (9/9)	8 (2–26)
NCT00886132 * (Chau et al., 2012)	Sunitinib	II	14	ORR by RECIST	0	0	84.6% (11/13)	7.2 months (2.2–9.0) – time to progression
NCT01065844 (Hoover et al., 2015)	Nelfinavir	II	15	Tumor progression by RECIST	0	0	46.6% (7/15)	5.5 (4.4 – not estimable)
NCT01152840 * (Kim et al., 2014)	Everolimus (RAD001)	II	33	PFS rate at 4 months by RECIST	0	0	79.4% (27/34)	11.2 (3.6–15.8)
NCT01175980 (Goncalves et al., 2017)	Vorinostat	II	30	ORR by RECIST	0	6% (2/30)	81% (27/30)	11.4 (7.1 – 20.5) - 90% CI
NCT01417143 * (Keam et al., 2015)	Dovitinib	II	32	PFS rate at 4 months by RECIST	0	3.1% (1/32)	93.8% (30/32)	6.0 (4.4–7.6)
NCT01524692 (Dillon et al., 2017)	Dovitinib	II	34	ORR by RECIST	0	6% (2/34)	65% (22/34)	8.2 (7.3 – 11) –90% CI
NCT01558661 (Ho et al., 2016a)	Axitinib	II	33	ORR by RECIST	0	9.1% (3/33)	75.8% (25/33)	5.7 (5.3 – 9.1)
NCT01604772 (ClinicalTrials.gov)	MK2206	II	16	ORR by RECIST	0	0	92% (13/14)	9.2 (3.8–11.0)
NCT01678105 * (Hotte et al., 2016)	Dovitinib	II	21	Clinical benefit rate by RECIST	0	0	71.4% (15/21)	NA
NCT02098538 * (Ho et al., 2016b)	Regorafenib	II	38	Patients alive without disease progression by RECIST	0	0	44.7% (17/38)	NA
NCT02662608 (ClinicalTrials.gov)	Brontictuzumab	NA	1	Number of Participants With Disease Progression by RECIST	NA	NA	NA	NA
NCT02775370 * (Zhu et al., 2021)	Apatinib	II	68	PFS rate at 6 months by RECIST	0	46.2% (30/65)	52.3% (34/65)	19.7 (11.8–26.0) – Interquartile range
NCT02780310 * (Tchekmedyian et al., 2019)	Lenvatinib	II	32	Best overall response rate by RECIST	0	15.6% (5/32)	75% (24/32)	17.5 (7.2 – not estimable)
NCT02859012 * (Kang et al., 2021)	Axitinib	II	60 (two arms)	PFS rate at 6 months by RECIST	0	0	52.3% (11/21)	10.8 (7.1–13.6) – axitinib arm 2.8 (1.7–4.2) – observation arm
NCT02860936 * (Locati et al., 2020)	Lenvatinib	II	28	ORR by RECIST	0	11.5% (3/26)	76.9% (20/26)	9.1 (5.5–13.8)
NCT03087019 (Mahmood et al., 2021)	Pembrolizumab	II	20 (two arms)	ORR by RECIST (non-irradiated lesions)	0	0	60% (7 pembro alone and 5 pembro + RT) (no significant difference between arms)	4.5 (1.4 – 20.6) for pembro + RT; 6.6 (2.4 – 13.1) for pembro alone
NCT03691207 * (Ferrarotto et al., 2022b)	AL101	II	77	ORR by RECIST	0	11.6% (9/77)	57.1% (44/77)	NA
NCT03999684 (Hanna et al., 2021)	Tretinoin (ATRA)	II	18	ORR by RECIST	0	0	61% (5/18)	3.7 (1.8–3.9)
NCT04433169 * (Ye et al., 2021)	Tretinoin (ATRA) and Apatinib	II	16	ORR by RECIST	0	19% (3/16)	81% (13/16)	NA
NCT03990571 * (Ferrarotto et al., 2022a)	Axitinib and Avelumab	II	28	ORR by RECIST or modified MD Anderson bone criteria [§]	0	ORR 17.9% (5/28)		7.2 (3.7–11.7)

Legend: N – number of patients enrolled; PFS – progression free survival, CI – confidence interval; ORR – overall response rate; RECIST - Response Evaluation Criteria in Solid Tumors

*Studies that reported “no results available” on ClinicalTrials.gov database but preliminary or full results were identified in the published literature.

[§]Bone-specific response criteria developed by The University of Texas MD Anderson Cancer Center in 2004 for evaluation of bone metastases

Table 2

Inclusion criteria for ACC CT with available results (information extracted from ClinicalTrials.gov website).

CT number / reference	Drug name	Disease status	Site restriction	Age restriction	ECOG status	Evidence of progression
NCT00017498 * (van Herpen et al., 2008)	Gemcitabine	Recurrent, or metastatic, incurable disease	Head and neck	> 18 years	WHO 0–2	Symptomatic and/or progressive disease
NCT00077428 * (Argiris et al., 2011)	Doxorubicin and Bortezomib	Locally advanced, recurrent, or metastatic, incurable disease	Head and neck	> 18 years	0–2	9 months interval
NCT00581360 (ClinicalTrials.gov)	Doxorubicin and Bortezomib	Locally advanced, recurrent, or metastatic, incurable disease	Head and neck	> 18 years	0–2	Not mandatory
NCT00886132 * (Chau et al., 2012)	Sunitinib	Recurrent, or metastatic, incurable disease	Salivary gland	> 18 years	NI	6 months interval
NCT01065844 (Hoover et al., 2015)	Nelfinavir	Recurrent or end-stage with/without metastases who have failed all other therapy	Head and neck	> 18 years	0–2	NI
NCT01152840 * (Kim et al., 2014)	Everolimus (RAD001)	Local, locally-advanced or metastatic incurable disease	NI	> 18 years	0 or 1	Yes, any time interval
NCT01175980 (Goncalves et al., 2017)	Vorinostat	Locally advanced, recurrent, or metastatic, incurable disease	NI	> 18 years	0–2	NI
NCT01417143 * (Keam et al., 2015)	Dovitinib	Locally advanced, recurrent, or metastatic, incurable disease	NI	> 18 years	0 or 1	Yes, any time interval
NCT01524692 (Dillon et al., 2017)	Dovitinib	Recurrent, or metastatic, incurable disease	NI	> 18 years	0–2	Yes, interval not defined
NCT01558661 (Ho et al., 2016a)	Axitinib	Locally advanced, recurrent, or metastatic, incurable disease	Any site	> 18 years	0–2	6 months interval
NCT01604772 (ClinicalTrials.gov)	MK2206	Locally advanced, recurrent, or metastatic, incurable disease	Any site	> 18 years	0–2	6 months interval
NCT01678105 * (Hotte et al., 2016)	Dovitinib	Recurrent, or metastatic, incurable disease	Salivary gland	> 18 years	0–2	12 months interval
NCT02098538 * (Ho et al., 2016b)	Regorafenib	Recurrent, or metastatic, incurable disease	Any site	> 18 years	0–2	6 months interval
NCT02662608 (ClinicalTrials.gov)	Brontictuzumab#	NI	NI	> 18 years	0 or 1	NI
NCT02775370 * (Zhu et al., 2021)	Apatinib	Recurrent, or metastatic, incurable disease	NI	18–75 years	Karnofsky score > 60	Yes, any time interval
NCT02780310 * (Tchekmedyan et al., 2019)	Lenvatinib	Recurrent, or metastatic, incurable disease	Any site	> 18 years	0–2	6 months interval
NCT02859012 * (Keam et al., 2020)	Axitinib	Local, locally-advanced or metastatic incurable disease	NI	Child, Adult, Older Adult	0–1	9 months interval
NCT02860936 * (Locati et al., 2020)	Lenvatinib	Recurrent, or metastatic, incurable disease	Salivary gland	18–99 years	0–2	6 months interval
NCT03691207 * (Ferrarotto et al., 2022a)	AL101	Recurrent, metastatic or unresectable disease with known NOTCH 1/2/3/4 activating mutation	NI	> 18 years	0 or 1	6 months interval
NCT03087019 (Mahmood et al., 2021)	Pembrolizumab	Recurrent, metastatic, unresectable disease	NI	> 18 years	0 or 1	12 months interval
NCT03999684 (Hanna et al., 2021)	Tretinoin (ATRA)	Recurrent, metastatic or advanced, unresectable disease	NI	> 18 years	0 or 1	12 months interval
NCT04433169 * (Ye et al., 2021)	Tretinoin (ATRA) and Apatinib	Advanced, recurrent, or metastatic disease	NI	> 18 years	0 or 1	NI
NCT03990571 * (Ferrarotto et al., 2022b)	Axitinib and Avelumab	Recurrent, metastatic or unresectable disease	NI	> 18 years	0 or 1	6 months interval

approved by the FDA for any means, while the rest are approved for oncologic purposes or HIV therapy (Nelfinavir). The use of approved drugs represents a cheaper, safer, and faster approach, as all essential data on safety and toxicity is available and the process for commercialization is ready (Sleire et al., 2017). For an anti-tumor drug to gain approval for treatment of a new cancer, robust evidence is needed and for rare cancers, such as ACC, this is more challenging. The “orphan drug act” adopted by the US in 1983 (Orphan Drug Act, 1983), and now followed by many governments, represents a key pathway to promote faster approval for rare disease treatments. The orphan drug initiative involves many aspects including financial support, fast-track or accelerated procedure, priority or separate review, lower data requirements and a market exclusivity period (Korchagina et al., 2019). Currently, the FDA grants this title for drugs used to manage diseases that affect fewer than 200,000 people in the US.

According to the FDA database, four drugs have been granted orphan

drug designation for ACC treatment: dovitinib (2013), para-toluenesulfonamide (2017), AL101 (2019) and Apatinib (2021) (U.S Food and Drug Administration). Intratumoral injection of para-toluenesulfonamide has been assessed and found to be effective in decreasing airway tumor size and reducing the rate of airway obstruction in pulmonary ACC with severe central airway obstruction (Guan et al., 2018). Dovitinib and Apatinib are small-molecule tyrosine kinase inhibitors and while Dovitinib has multiple targets, such as VEGFR, PDGFR, c-Kit, CSF-1R, RET, TrkA, FLT3 and FGFRs 1–3 (Dillon et al., 2017), Apatinib specifically inhibits tumor angiogenesis by targeting VEGFR-2 (Zhu et al., 2021). AL101, also a small molecule drug, is a γ -secretase inhibitor that potently inhibits Notch1–4. Pre-clinical results using ACC patient-derived xenografts demonstrated a robust antitumor activity for tumors with Notch activating mutations (Ferrarotto et al., 2019). Among the trials reviewed in this study, Dovitinib, Apatinib and AL101 were tested in 3, 2 and 1 clinical trials with available results,

Table 3
List of drugs evaluated in CT with available results.

Drug name	Drug class	FDA approved	Target
AL101	Small-molecule	No (orphan drug designation for ACC)	γ -secretase inhibitor (blocks Notch)
Apatinib	Small-molecule	No (orphan drug designation for ACC)	VEGFR2
Avelumab	Monoclonal antibody	Merkel cell carcinoma, urothelial carcinoma and renal cell carcinoma	PD-L1 (immunotherapy)
Axitinib	Small-molecule	Renal cell carcinoma	VEGFRs 1–3, KIT, and PDGFRs A/B
Brontictuzumab	Monoclonal antibody	No	Notch 1
Dovitinib	Small-molecule	No (orphan drug designation for ACC)	VEGFR, PDGFR, c-Kit, CSF-1R, RET, TrkA, FLT3, FGFRs 1–3
Doxorubicin	Anthracycline	Multiple malignancies (not ACC)	Topo isomerase 2
Bortezomib	Proteasome inhibitor	Multiple myeloma and mantle cell lymphoma	26 S proteasome
Everolimus (RAD001)	Protein kinase inhibitor	Multiple tumors (not ACC)	mTOR
Gemcitabine	Antimetabolite	Multiple advanced / unresponsive malignancies (not ACC)	Pyrimidine antagonist
Lenvatinib	Small-molecule	Multiple advanced / unresponsive malignancies (not ACC)	VEGFR1 – 3, FGFR1, 2, 3, and 4; PDGFR α and β , KIT, and RET
MK2206	Small-molecule	No	Akt
Nelfinavir	Protease inhibitors	HIV infection	HIV-1 protease inhibitor
Pembrolizumab	Monoclonal antibody	Recurrent or metastatic head and neck squamous cell carcinoma	PD-1
Regorafenib	Small-molecule	Multiple advanced / unresponsive malignancies (not ACC)	Multiple targets*
Sunitinib	Small-molecule	Renal cell carcinoma and gastrointestinal stromal tumor	PDGF-R, VEGFR, KIT, RET, CSF-1R, and flt3
Tretinoin (ATRA)	Small-molecule	Acute promyelocytic leukemia	Retinoic Acid
Vorinostat	Small-molecule	Cutaneous T-cell lymphoma	Histone deacetylase (HDAC) inhibitor

* RET, VEGFR1, VEGFR2, VEGFR3, KIT, PDGFR-alpha, PDGFR-beta, FGFR1, FGFR2, TIE2, DDR2, TrkA, Eph2A, RAF-1, BRAF, BRAFV600E, SAPK2, PTK5, and Abl

respectively and responses to treatment and PFS rates will be discussed at a later stage in this report.

Reporting on drug adverse effects varied considerably with most studies only specifying the most common toxicities or those adverse effects that led to treatment discontinuation. In many studies it was not clear if severe adverse effects were not reported because they did not occur during therapy or because they were rare events and only the most common ones were reported. This potentially impeded collection of reliable data. A literature review by Pitrou et al. (2009) analyzed CT results published in general medical journals with a high impact factor and observed that even though the majority of studies (88%) reported adverse effects, almost one third of them restricted the reporting to

either most common, more severe or those with statistically significant differences between groups. Tolerability of therapy is a key factor, as drugs with similar prospects of achieving disease stability or objective response are often chosen based on the highest level of tolerability, determined by assessing the risk, type and severity of adverse effects.

3.6. Primary endpoint results

In the 23 trials reviewed here, no case of complete response was identified during follow-up (Table 1). Partial response rates varied from 0% to 46%, the highest score being achieved with Apatinib (30 patients out of 65). Stable disease as best response was also variable among trials, ranging from 44% (Regorafenib, 17 out of 38 patients) to 100% (Doxorubicin associated with Bortezomib, 9 out of 9 patients). Most studies presented survival data as median of PFS in months alongside the 95% CI. Some studies used PFS with 90% CI or interquartile range and one study presented the data as time to progression (TTP). The summarized survival data is presented in Fig. 1. The median PFS (or TTP) ranged from 3.7 (Tretinoin) to 19.7 months (Apatinib) and although most trials were single-arm studies, the median PFS time after therapy can be compared with historical data of observation groups (no treatment) and also among the experimental treatments. Among the trials reviewed, one had an observation arm, which achieved a median PFS of 2.8 months (Kang et al., 2021) and was included for comparison purposes. Even though no patient achieved complete response within the CT reviewed, many drugs led to significantly longer PFS as compared to 2.8 months, such as Apatinib, Axitinib, Dovitinib, Lenvatinib, Nelfinavir and Vorinostat (Fig. 1).

Stable disease duration could be viewed as having limited value for indolent malignancies such as ACC as it is more challenging to conclude if disease stabilization occurred as a result of the drug or if it is part of the tumor's natural history. Thus, evidence of disease progression prior to trial enrollment could be considered an important inclusion criterion. Among the reviewed trials, two stated that evidence of disease progression was not mandatory, and three didn't mention this criterion (Table 2). Most studies, however, did include disease progression (with variable time intervals) as a key inclusion criterion strengthening the validity of the PFS times achieved after therapy. Also, all CT assessed treatment response (primary endpoint) based on RECIST (Eisenhauer et al., 2009) (Table 1). While the majority of trials used objective response rates (ORR), represented by the number of patients presenting CR or PR divided by the total number of patients evaluated, some CT used the PFS rates at 4 months or clinical benefit rates, which is defined as an objective response or stable disease of ≥ 24 weeks (6 months) duration. RECIST takes into consideration the baseline and final sum of diameters of target lesions to determine the response rates: a decrease of at least 30% needs to be achieved for PR, for example, and at least 20% increase to define disease progression (considering the baseline or any other smallest sum during treatment) (Eisenhauer et al., 2009). Some authors suggest that changes in tumor size, volume or density might represent a better method for assessment of treatment response in some types of solid tumors, such as gastrointestinal stromal tumors (Choi et al., 2007) and lung cancer (Mozley et al., 2010). It appears that changes in tumor volume could predict clinical response earlier than RECIST as this measure is more sensitive than changes in unidimensional diameters (Mozley et al., 2010). For example, Locati et al. (2016) investigated the effects of Sorafenib in recurrent and/or metastatic salivary gland carcinomas (ACC and non-ACC types) and observed 6 cases of PR based on RECIST, while the Choi method (Choi et al., 2007), based on tumor density, revealed 15 cases of PR. The discordance rate between methods was significant (57%) and, interestingly, no association between PFS time with response rates, according to both RECIST and Choi, was observed. It appears that until a better method is developed and validated, RECIST should continue to be used for primary endpoint, as it allows standardization and comparisons between trials. Including information on the number of patients that experienced

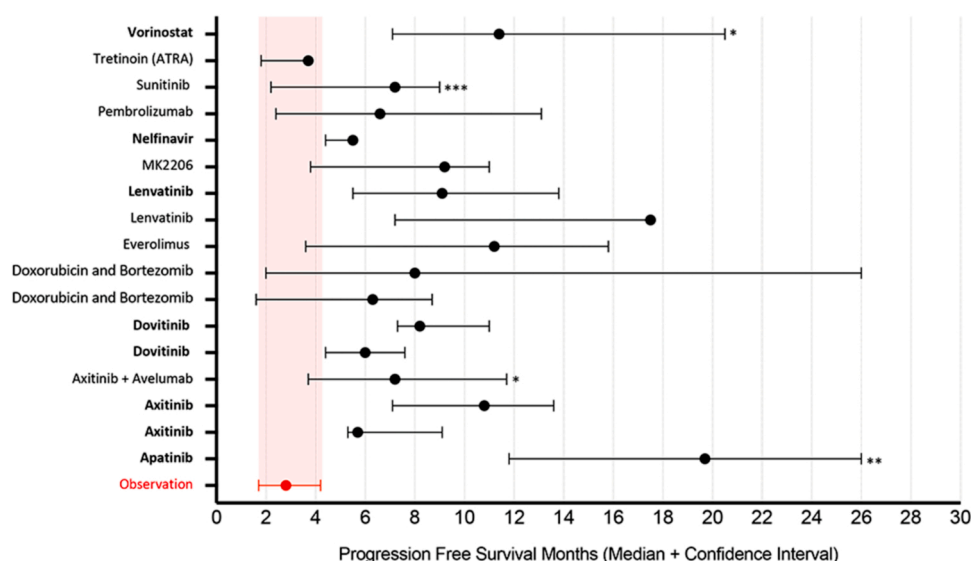


Fig. 1. Median and 95% Confidence Interval (CI) of Progression Free Survival (PFS) of drugs tested in ACC-related CT with available results. PFS for an observation group (Kang et al., 2021) is included for comparison purposes (95% CI highlighted in gray). Drugs in bold have 95% CI that do not cross the observation 95% CI (significant increase in patients PFS). * 90% CI instead of 95% CI; ** Interquartile range instead of 95% CI; *** Time to progression instead of PFS time.

volume shrinkage might also be relevant, however, and should be incorporated in full manuscripts detailing therapy response.

Duration of response (DOR) is defined as the period between response initiation (first time either CR or PR is observed) and progression or death, whichever occur first. A major shortcoming of conventional DOR, however, is that it is limited to responders and can result in biased assessment of the duration (Huang et al., 2020). Mean DOR was reported (or calculated based on available data) for Vorinostat (30.1 months, based on 2 responders), Apatinib (17.7 months, for 30 responders), Lenvatinib (3.1 months, for 3 responders) and Axitinib associated with Avelumab (5.2 months, for 5 responders) (Goncalves et al., 2017; Zhu et al., 2021; Locati et al., 2020; Ferrarotto et al., 2022a). Mahmood et al., (2021) showed a graphical representation of DOR among responders treated with Pembrolizumab, yet the exact values could not be calculated from the provided figure. Other CT reviewed reported that DOR was among the secondary endpoints but the results were not detailed (Kim et al., 2014; Keam et al., 2015; Kang et al., 2021). Two studies reported duration of stable disease that could be considered similar (Argiris et al., 2011; Chau et al., 2012), however, no clear definition was given precluding accurate interpretation. In addition, Hanna et al. (2021) included duration of stability as a secondary endpoint but defined this as time from registration to disease progression; differing from DOR.

3.7. Most promising therapies based on ORR and PFS time

Among the drugs tested in the CT we reviewed, Apatinib achieved the most remarkable results. Patients with recurrent or metastatic ACC of the head and neck achieved the highest rate of PR (46%) (Zhu et al., 2021) while combining PR and SD rates indicated 98.5% of patients achieved disease control during the trial. Patients treated with Apatinib also presented the highest PFS median time, of 19.7 months. In their published paper, the authors present the median PFS alongside the interquartile range instead of 95% CI, thus care should be taken when comparing the lines in Fig. 1. The trial enrolled 68 patients diagnosed with ACC, mainly from salivary glands (minor and major) but also other head and neck sites. The therapy efficacy was analyzed in 65 patients, the greatest number among all trials reviewed and thus providing a meaningful sample size. It is important to note that this study was conducted in a single institution ((Shanghai; Zhu et al., 2021) and we suggest further studies, preferably multicentre trials with a more diverse

population, are needed to confirm these promising results. The same group from Shanghai investigated the effect of Tretinoin (all-trans retinoic acid - ATRA) with low doses of Apatinib (Ye et al., 2021). While in the first CT the optimal dose was defined as 500 mg/day orally (Zhu et al., 2021), in the second trial the Apatinib dose was 250 mg/day with 20 mg/day of Tretinoin (Ye et al., 2021). The preliminary results, presented as conference proceedings, indicated three out of 16 (19%) patients achieved partial response and the remaining 13 achieved stable disease (Table 1), which brings the total disease control rate to 100%. The median PFS after therapy is not detailed (not shown in Fig. 1), but the 6-month and 12-month progression-free survival rates were 100% and 80%, respectively (Ye et al., 2021).

Dovitinib did not obtain remarkable PR rates (0, 3.1% and 6% - Table 1), yet the SD rates were considered very significant in three trials evaluating this drug: 65%, 93% and 71% (Keam et al., 2015; Hotte et al., 2016; Dillon et al., 2017). The median PFS times varied from 6.0 (95% CI - 4.4–7.6 months) to 8.2 months (90% CI - 7.3 – 11 months), which suggests that despite a limited effect in reducing disease burden, the drug can efficiently increase the time of disease stability. These results should, however, be interpreted with caution as the interval for evidencing disease progression prior to entering the trial was either not defined (Keam et al., 2015; Dillon et al., 2017) or 12-months (Hotte et al., 2016), which might be considered too long. It is not clear if the disease stability is due to the drug activity or associated with natural ACC indolent behavior.

Lenvatinib, a small molecule multitargeted tyrosine kinase inhibitor that targets VEGFR 1–3, FGFRs 1–4, KIT, PDGFR α and β , KIT and RET treatment, also showed promising results. Two studies evaluated the drug and reported a median PFS of 17.5 months (n = 32) (Tchekmedyian et al., 2019) and 9.1 months (n = 26) (Locati et al., 2020). Once again, the promising results achieved in the first trial need to be interpreted with caution and might be over-estimated as many patients were censored. A post-trial analysis of event-free survival revealed a more modest time of 8.2 months (95% CI, 7.1–17.4 months) (Tchekmedyian et al., 2019). Currently, this drug is approved by the FDA for the treatment of differentiated thyroid cancer, renal cell carcinoma, hepatocellular carcinoma and endometrial carcinoma (Lenvima prescribing information FDA). In the CT reviewed, disease control was achieved in 90.6% (29/32) (Tchekmedyian et al., 2019) and 88.4% (23/26) (Locati et al., 2020) of patients, with PR rates ranging from 11% to 15% (Tchekmedyian et al., 2019; Locati et al., 2020). A real-world experience

of recurrent or metastatic ACC cases treated with Lenvatinib within the UK was published recently but the response rate was not as promising as those achieved in the CT (Feeney et al., 2021). Twenty-three patients from eleven cancer centers receiving Lenvatinib monotherapy were evaluated. The median PFS was 4.1 months, no CR or PR was observed, and SD was achieved in only 52.4% of patients (Feeney et al., 2021). Different hypotheses were proposed to explain such discrepancies including the starting dose of Lenvatinib (lower than the usual 24 mg used in the CT in 60% of patients due to reduced performance status, impaired hepatic function or toxicity concern) and the possibility that enrolled patients had later stage disease compared to those in previous CT (Feeney et al., 2021).

Vorinostat, also known as suberoylanilide hydroxamic acid (SAHA), is a small molecule inhibitor of histone deacetylase (HDAC). This epigenetic drug has been tested in ACC and achieved a good rate of disease stabilization: 29/30 patients, among which 2 (6%) had PR and the remaining SD (Goncalves et al., 2017). The drug was taken to trial following a promising response in two ACC patients who enrolled in a previous broader solid tumors trial (Ramalingam et al., 2010) and also because next generation sequencing (NGS) studies have shown that ACC has a low mutation rate but presents frequent mutations in genes involved in epigenetic regulation such as KDM6A and CREBBP (Ho et al., 2013). Despite the fact that disease progression was not mandatory for enrollment, which might represent a shortcoming, 90% of enrolled patients had radiological evidence of prior disease progression (Goncalves et al., 2017). The median PFS time was 11.4 months representing a good achievement in ACC CT trials. The authors also highlighted the fact that, despite SD being the best response in 27 patients, 20 had evidence of tumor size decrease, which again brings into question the limitations of RECIST in accessing early/initial treatment response (Goncalves et al., 2017). The clinical activity is corroborated by a study conducted with ACC cell lines and patient-derived xenografts in which Vorinostat administration reduced the percentage of cancer stem cells (highly tumorigenic cell population, with self-renewal and differentiation potential) both in vivo and in vitro (Almeida et al., 2017).

3.8. Challenges and opportunities

CT for orphan diseases such as ACC face many challenges, including sufficient patient enrollment to allow a significant sample size. It is important to emphasize that CT for rare cancers represent a two-way relationship, for the research group, patient participation is significant and for the patient, it might represent the best chance of receiving a rational systemic therapy and to be treated by world experts in the management of their rare disease. For rare cancers, patient-orientated foundations represent an important tool in finding open trials, which in the context of ACC, the ACC Research Foundation has a full list of open CT that patients can access for information on treatment opportunities (<https://accrf.org/>).

Despite all the difficulties and the fact that no drug has, to date, been approved for the treatment of advanced ACC, recent FDA approvals in relation to salivary gland cancers brings some optimism. Pan-TRK inhibition with Larotrectinib (Hong et al., 2020) or Entrectinib (Doebele et al., 2020) were approved in 2018 and 2019 respectively, for solid tumors harboring NTRK rearrangements which includes the majority of secretory salivary gland carcinoma cases. For ACC, MYB rearrangements are found in around 60% of ACC cases (Fujii et al., 2017) triggering an increase in Myb protein levels (Presson et al., 2009; Gao et al., 2014). Drugs that target MYB-associated events could represent a promising route for ACC management and basic research is key to identifying compounds that can target MYB. An example of this bench to bedside approach is the case of Tretinoin (all-trans retinoic acid - ATRA). A genetic screen of zebrafish models identified retinoic acid agonists, among more than 3800 bioactive small molecules, as potent suppressors of MYB (Mandelbaum et al., 2018). The use of ATRA was effective in inhibiting ACC growth in patient-derived xenograft models (Mandelbaum et al.,

2018). Two CT reviewed for this paper investigated Tretinoin use: one in isolation (Hanna et al., 2021) and one in association with Apatinib (previously discussed) (Ye et al., 2021). Tretinoin monotherapy was tested in 18 patients with recurrent, metastatic ACC with eleven patients (68%) achieving disease stability; no case of PR was observed (Hanna et al., 2021) and the PFS rates achieved (median 3.7, 95%CI - 1.8–3.9) were not considerably higher than that usually seen with observation (Kang et al., 2021). The authors hypothesized that the dose and/or schedule might not have been adequate to generate the expected responses. Interestingly, it appears that the patients with low MYB expression in immunohistochemical analysis were the ones that benefited more from Tretinoin in that they achieved longer PFS rates compared to high-MYB cases. This could suggest the drug is better able to downregulate MYB gene transcription and the positive feedback loop in cases with low MYB expression (Hanna et al., 2021).

Among the broader trials (including non-ACC cases) excluded in our initial search (Supplementary Table 2), we found a phase I trial investigating the use of a TetMYB vaccine that targets MYB, in association with an anti-PD1 antibody, BGB-A317 (MYPHISMO study protocol). The trial is being conducted on patients diagnosed with ACC or colorectal cancer, which can also be MYB-driven (Pham et al., 2019). Preliminary in vivo results using nude mice demonstrated that the vaccine as monotherapy, administered 2-days post tumor cell inoculation, with boosts on days 7 and 12, was effective. However, the positive effects were only observed if the therapy was started when the tumor burden was low, with no positive effects if initiated beyond this point. In order to overcome the limitation that CT usually focus on advanced metastatic cases combined immunotherapy was included and initial results were promising, even if the vaccine was administered at a later time point when there was a higher tumor burden (Cross et al., 2015). The ongoing clinical trial represents the first testing of this vaccine in humans (Pham et al., 2019).

A study by Ho et al. (2019) identified that recurrent/metastatic ACC, those which will benefit from systemic therapy, are enriched for alterations in key Notch genes compared to primary tumors (NOTCH1, 26.3% vs. 8.5%; NOTCH2, 4.6% vs. 2.3%; NOTCH3, 5.7% vs. 2.3%; NOTCH4, 3.6% vs. 0.6%) (Ho et al., 2019). The patient cohort in the Tretinoin monotherapy CT was subjected to next-generation sequencing with the most frequent alteration identified being NOTCH1 (22% of patients) (Hanna et al., 2021). ACC cases harboring NOTCH1 mutations have also been demonstrated to have a more aggressive phenotype compared with NOTCH1 wildtype tumors, evidenced by a higher likelihood of solid histological subtype, diagnosis at an advance stage, increased risk of liver and bone metastasis and shorter relapse-free and overall survival (Ferrarotto et al., 2017). A recent proteogenomic study confirmed that this distinct population of ACC cases, with a poorer prognosis, were enriched for NOTCH-activating mutations but also presented strong upregulation of MYC, MYC target genes and mRNA splicing (Ferrarotto et al., 2021). Brontictuzumab targets the Notch1 pathway and was successful in inhibiting the growth of an ACC - PDX model with an activating NOTCH1 mutation (Ferrarotto et al., 2017). In a broader CT including tumors bearing NOTCH1 mutations Brontictuzumab also prolonged disease stabilization in 3 patients diagnosed with ACC (Ferrarotto et al., 2018). This broader trial was conducted with ACC patients but also those diagnosed with colorectal cancer, esophageal cancer, breast cancer, pancreatic cancer, cholangiocarcinoma, gastric cancer, and small-cell lung cancer, with the need of evidence of NOTCH1 mutation in the NRR or PEST domain or high frequency of Notch1 pathway activation defined by immunohistochemistry as inclusion criteria (Ferrarotto et al., 2018). Among 36 subjects assessed for treatment efficacy, diagnosed with different histological malignancies, only two (5%) had unconfirmed partial response (PR), but both of these were diagnosed with ACC (Ferrarotto et al., 2018). AL101, which has orphan drug designation for ACC, has been shown to successfully inhibit tumor growth in ACC PDX models with Notch activating mutations (n = 2), but lacked effectiveness in PDX models without such mutations (n = 2)

(Ferrarotto et al., 2019). ACCURACY is an open-label, multicentre study of AL101 in patients with recurrent or metastatic ACC who harbor NOTCH 1,2,3,4 activating mutations. Preliminary results from 77 patients were recently presented at the 2022 ASCO meeting demonstrating that disease control was achieved in 53 (68.8%) patients: 9 (11.6%) achieved partial response and 44 (57.1%) stable disease as best response (Ferrarotto et al., 2022). This broader trial includes 18 recruiting centers across the US, Canada, Israel, Netherlands and United Kingdom with an estimated enrollment of 87 patients and a completion date of December 2022.

The latest National Comprehensive Cancer Network (NCCN) guideline, published in 2022, in agreement with the ASCO guideline, suggests that there is no preferred regimen for salivary gland malignancies. However, the guideline does recommend some regimens that oncologists can follow to manage unresectable metastatic or recurrent salivary gland cancers, including ACC, such as cisplatin/vinorelbine, cisplatin/doxorubicin/cyclophosphamide, paclitaxel and carboplatin/paclitaxel. Other useful drugs suggested by the guideline include Lenvatinib, Axitinib, Sorafenib and Pembrolizumab (for high-TMB tumors) (NCCN Clinical Practice Guidelines in Oncology, 2022). The guideline follows robust evidence and some drugs previously described in this review as achieving significant PFS times, such as Vorinostat, have not been included. This is possibly due to enrollment limitations, such as absence of evidence of disease progression before trial, which is particularly important in the context of an indolent disease. While the aim of this study was to review registered CT specifically designed for ACC, and all of the studies included targeted drugs, it is important to acknowledge that conventional chemotherapy, with most of the evidence to support efficacy coming from broader salivary gland cancer trials, provides essential therapeutic tools, particularly while we continue the search for a standard therapy, (NCCN Clinical Practice Guidelines in Oncology, 2022).

3.9. Directions for future trials

Drug choice: as much as drugs with positive ACC-related pre-clinical results appear to provide the most promising approach (as those mostly target specific deregulated pathways of ACC), inconsistent results have been observed among drugs that have already advanced to CT. The use of drug repurposing from other successful trials in solid tumors continues to be a good strategy and should be maintained. Only three CT in this review investigated the use of two drugs in association. Advanced solid tumors can greatly benefit from multi-target therapy as the risk of a subpopulation of tumor cells being resistant to a specific pharmacological agent could be mitigated by the use of a concomitant drug in parallel. While the likelihood of achieving tumor control in highly metastatic tumors with mono therapy has been previously estimated to be null, the chances increase significantly with dual therapy (Bozic et al., 2013).

Inclusion criteria: Not using age and site as exclusion criteria could allow increased patient enrollment while expert opinion surrounding the organization of trials for targeted therapies indicates that ECOG status of 2 should not be considered an exclusion criterion. Evidence of disease progression prior to trial enrollment is a very important inclusion criteria as ACC is an indolent disease. Without this rigid enrollment criteria it is not possible to determine if patients who present disease stability achieved it due to the tested drug or if this is just inherent to the disease biology.

Primary and secondary endpoints and reporting results: ORR by RECIST criteria appears to be the primary endpoint, as it allows comparison of results with the majority of other trials published. While many authors reported the use of other secondary endpoints, it was often not possible to find this data in the publication. We recommend all data be made publicly available (potentially as [supplementary material](#)) including information on the number of patients that experienced volume shrinkage and the DOR. The PFS time should also be indicated with

the best way to present being as $\text{media} + 95\%$ confidence interval; this would allow comparison between studies.

Results reporting should follow all of the recommendations of the CONSORT 2010 Statement guidelines (Schulz et al., 2010).

3.10. Limitations

Fig. 1 attempts to compare PFS time between different CT, however, the inclusion and exclusion criteria used for patient enrollment, sample size, data measurements (e.g.: 95% or 90% confidence interval vs interquartile range) varied significantly between studies, such that any comparison needs to be interpreted with caution. Moreover, the values used for the observational group are based on only one trial. Even though the authors had appropriate inclusion criteria, with the need of evidence of disease progression prior to trial enrollment, this result is based on only one specific population comprised of 27 patients.

As this is a literature review, full data extraction was not possible for all CT due to missing information. This resulted in limited information gathered on adverse effects. The search was performed on only one online database (clinicaltrials.gov) and only studies that analyzed drug-based therapies exclusively in ACC were considered eligible for full data extraction. Studies that evaluated all types of salivary gland cancers were not assessed, even if ACC cases were included, which might represent a further limitation.

4. Conclusion

This review confirmed that advances have been made in the search for a standard therapy for ACC yet there are still challenges to overcome. No CT uncovered complete response but small-molecule inhibitors such as Axitinib, Apatinib and Lenvatinib showed good response rates and/or long PFS times. These drugs represent promising alternatives while basic research and pre-clinical studies continue to advance our understanding of ACC tumorigenesis. Key data with translational value has been discovered, including the fact that MYB activation seems to be an important event for tumor progression (Gao et al., 2014), and that NOTCH is more active in recurrent / metastatic cases (Ho et al., 2019) and associated with a more aggressive phenotype (Ferrarotto et al., 2017). This is now directing the drug choice of key ACC CT, for example, the AL101 CT. While CT designed to test drugs that act on key pathways for ACC continue and increase in number, small molecule tyrosine kinase inhibitors such as Apatinib and Lenvatinib, which use a broader rationale of pathways involved with solid tumor progression, appear to increase disease stability for a significant period of time. The efforts being made are substantial and will be key for identifying effective drugs for treatment of recurrent advanced / metastatic cases of ACC. Finally, as all CT reviewed were designed for advanced cases, the efficacy of these drugs as adjuvant therapy after surgery in less aggressive/advanced cases has yet to be determined.

Funding

This project has received funding from the European Union's Horizon 2020 research and innovation programme under the Marie Skłodowska-Curie grant agreement No 894938. This work was also supported by the State of São Paulo Funding Agency (FAPESP), grant no 16/05710-4.

CRedit authorship contribution statement

Vivian P. Wagner and Lynne Bingle contributed to the conception and design of the study. Vivian P. Wagner reviewed the literature, extracted the data and wrote the initial draft. All authors critically revised the data retrieved, revised and gave inputs into the manuscript and approved the final version.

Conflict of Interest

The authors declare no competing interests. The funders had no role in study design, data collection, and analysis, decision to publish, or preparation of the paper.

Appendix A. Supporting information

Supplementary data associated with this article can be found in the online version at doi:10.1016/j.critrevonc.2022.103886.

References

- Almeida, L.O., Guimaraes, D.M., Martins, M.D., Martins, M.A.T., Warner, K.A., Nör, J.E., Castilho, R.M., Squarize, C.H., 2017. Unlocking the chromatin of adenoid cystic carcinomas using HDAC inhibitors sensitize cancer stem cells to cisplatin and induces tumor senescence. *Stem Cell Res.* 21, 94–105. <https://doi.org/10.1016/j.scr.2017.04.003>. Epub 2017 Apr 8. PMID: 28426972; PMCID: PMC7071815.
- Andreasen, S., 2018. Molecular Features of Adenoid Cystic Carcinoma with an Emphasis on microRNA Expression, 126. *APMIS*, pp. 7–57. <https://doi.org/10.1111/apm.12828>. PMID: 29924420.
- Argiris, A., Ghebremichael, M., Burtneß, B., Axelrod, R.S., Deconti, R.C., Forastiere, A. A., 2011. A phase 2 trial of bortezomib followed by the addition of doxorubicin at progression in patients with recurrent or metastatic adenoid cystic carcinoma of the head and neck: a trial of the Eastern Cooperative Oncology Group (E1303). *Cancer* 117 (15), 3374–3382. <https://doi.org/10.1002/ncr.25852>. PMID: 21246525.
- Bjørndal, K., Krogdahl, A., Therkildsen, M.H., Charabi, B., Kristensen, C.A., Andersen, E., Schytte, S., Primdahl, H., Johansen, J., Pedersen, H.B., Andersen, L.J., Godballe, C., 2015. Salivary adenoid cystic carcinoma in Denmark 1990–2005: outcome and independent prognostic factors including the benefit of radiotherapy. Results of the Danish Head and Neck Cancer Group (DAHANCA). *Oral Oncol.* 51 (12), 1138–1142. <https://doi.org/10.1016/j.oraloncology.2015.10.002>. Epub 2015 Oct 21. PMID: 26476712.
- Bleyer, A., 2007. Adolescent and young adult (AYA) oncology: the first A. *Pediatr. Hematol. Oncol.* 24 (5), 325–336. <https://doi.org/10.1080/08880010701316850>. PMID: 17613877.
- Boyle, T.A.C., St. Laurent, S., Semus, S., Joseph, N., 2020. Epidemiology of adenoid cystic carcinoma in the United States. *J. Clin. Oncol.* 38 (15 suppl) e13600–e13600.
- Bozic, I., Reiter, J.G., Allen, B., Antal, T., Chatterjee, K., Shah, P., Moon, Y.S., Yaquib, A., Kelly, N., Le, D.T., Lipson, E.J., Chapman, P.B., Diaz Jr, L.A., Vogelstein, B., Nowak, M.A., 2013. Evolutionary dynamics of cancer in response to targeted combination therapy. *Elife* 2, e00747. <https://doi.org/10.7554/eLife.00747>. PMID: 23805382; PMCID: PMC3691570.
- Casali, P.G., Bruzzi, P., Bogaerts, J., Blay, J.Y., 2015. Rare Cancers Europe (RCE) Consensus Panel. Rare Cancers Europe (RCE) methodological recommendations for clinical studies in rare cancers: a European consensus position paper. *Ann. Oncol.* 26 (2), 300–306. <https://doi.org/10.1093/annonc/mdu459>. Epub 2014 Oct 1. PMID: 25274616; PMCID: PMC4304377.
- Chau, N.G., Hotte, S.J., Chen, E.X., Chin, S.F., Turner, S., Wang, L., Siu, L.L., 2012. A phase II study of sunitinib in recurrent and/or metastatic adenoid cystic carcinoma (ACC) of the salivary glands: current progress and challenges in evaluating molecularly targeted agents in ACC. *Ann. Oncol.* 23 (6), 1562–1570. <https://doi.org/10.1093/annonc/mdr522>. PMID: 22080184.
- Choi, H., Charnsangavej, C., Faria, S.C., Macapinlac, H.A., Burgess, M.A., Patel, S.R., Chen, L.L., Podoloff, D.A., Benjamin, R.S., 2007. Correlation of computed tomography and positron emission tomography in patients with metastatic gastrointestinal stromal tumor treated at a single institution with imatinib mesylate: proposal of new computed tomography response criteria. *May 1 J. Clin. Oncol.* 25 (13), 1753–1759. <https://doi.org/10.1200/JCO.2006.07.3049>.
- Chung, K.C., Song, J.W., WRIST Study Group, 2010. A guide to organizing a multicentre clinical trial. *Plast. Reconstr. Surg.* 126 (2), 515–523. <https://doi.org/10.1097/PRS.0b013e3181df64fa>. PMID: 20375760; PMCID: PMC2917608.
- Ciccolallo, L., Licitra, L., Cantù, G., Gatta, G., EURO CARE Working Group, 2009. Survival from salivary gland adenoid cystic carcinoma in European populations. *Oral Oncol.* 45 (8), 669–674 (Aug).
- Conley, J., Dingman, D.L., 1974. Adenoid cystic carcinoma in the head and neck (cylindroma). *Arch. Otolaryngol.* 100 (2), 81–90. <https://doi.org/10.1001/archotol.1974.00780040087001>.
- Cross, R.S., Malaterre, J., Davenport, A.J., Carpinteri, S., Anderson, R.L., Darcy, P.K., Ramsay, R.G., 2015. Therapeutic DNA vaccination against colorectal cancer by targeting the MYB oncoprotein. *Clin. Transl. Immunol.* 4 (1), e30 <https://doi.org/10.1038/cti.2014.29>.
- Daugherty, C.K., Ratain, M.J., Emanuel, E.J., Farrell, A.T., Schilsky, R.L., 2008. Ethical, scientific, and regulatory perspectives regarding the use of placebos in cancer clinical trials. *J. Clin. Oncol.* 26 (8), 1371–1378. <https://doi.org/10.1200/JCO.2007.13.5335>.
- Dillon, P.M., Petroni, G.R., Horton, B.J., Moskaluk, C.A., Fracasso, P.M., Douvas, M.G., Varhegyi, N., Zaja-Milatovic, S., Thomas, C.Y., 2017. A phase II study of dovitinib in patients with recurrent or metastatic adenoid cystic carcinoma. *Clin. Cancer Res.* 23 (15), 4138–4145. <https://doi.org/10.1158/1078-0432.CCR-16-2942>. Epub 2017 Apr 4. PMID: 28377480; PMCID: PMC5540767.
- Doebele, R.C., Drilon, A., Paz-Ares, L., Siena, S., Shaw, A.T., Farago, A.F., Blakely, C.M., Seto, T., Cho, B.C., Tosi, D., Besse, B., Chawla, S.P., Bazhenova, L., Krauss, J.C., Chae, Y.K., Barve, M., Garrido-Laguna, I., Liu, S.V., Conkling, P., John, T., Fakih, M., Sigal, D., Loong, H.H., Buchsacher Jr, G.L., Garrido, P., Nieva, J., Steuer, C., Overbeck, T.R., Bowles, D.W., Fox, E., Riehl, T., Chow-Maneval, E., Simmons, B., Cui, N., Johnson, A., Eng, S., Wilson, T.R., Demetri, G.D., trial investigators, 2020. Entrectinib in patients with advanced or metastatic NTRK fusion-positive solid tumours: integrated analysis of three phase 1–2 trials. *Lancet Oncol.* 21 (2), 271–282. [https://doi.org/10.1016/S1470-2045\(19\)30691-6](https://doi.org/10.1016/S1470-2045(19)30691-6).
- Eisenhauer, E.A., Therasse, P., Bogaerts, J., Schwartz, L.H., Sargent, D., Ford, R., Dancy, J., Arbuck, S., Gwyther, S., Mooney, M., Rubinstein, L., Shankar, L., Dodd, L., Kaplan, R., Lacombe, D., Verweij, J., 2009. New response evaluation criteria in solid tumours: revised RECIST guideline (version 1.1). *Eur. J. Cancer* 45 (2), 228–247. <https://doi.org/10.1016/j.ejca.2008.10.026>.
- Elevar Therapeutics announces Orphan Drug Designation for Rivoceranib (apatinib) for the treatment of adenoid cystic carcinoma (ACC), News release. February 8, 2021. Accessed January 7, 2022. (<https://bit.ly/36RCOET>).
- FDA, 2019. Considerations for the Inclusion of Adolescent Patients in Adult Oncology Clinical Trials Guidance for Industry. FDA, Silver Spring, MD. (<https://www.fda.gov/Drugs/GuidanceComplianceRegulatoryInformation/Guidances/default.htm>).
- Feeney, L., Jain, Y., Beasley, M., Donnelly, O., Kong, A., Molero, R., Nallathambi, C., Rolles, M., Sanghera, P., Tin, A., Ulahannan, D., Walter, H.S., Webster, R., Metcalf, R., 2021. Centralised RECIST assessment and clinical outcomes with lenvatinib monotherapy in recurrent and metastatic adenoid cystic carcinoma. *Cancers* 13 (17), 4336. <https://doi.org/10.3390/cancers13174336>. PMID: 34503145; PMCID: PMC8431195.
- Ferrarotto, R., Alpert, G., Gluschnaider, U., Rauch, R., Mondshine, A., Solomon, O., Kramer, B., Izumchenko, E., Heymach, J., Vergara-Silva, A., Aster, J., Davis, M., 2019. AL101 mediated tumor inhibition in Notch mutated ACC PDX models [abstract]. In: Proceedings of the American Association for Cancer Research Annual Meeting 2019; 2019 Mar 29–Apr 3; Atlanta, GA. Philadelphia (PA): AACR; Cancer Res; 79(13 Suppl):Abstract nr 4885.
- Ferrarotto, R., Bell, D., Feng, L., Li, K., Mott, F., Blumenschein, G.R., Guimaraes de Sousa, L., Altan, M., Marques-Piubelli, M.L., Dal Lago, E.A., Kaya, D., Godoy, M., Kupferman, M.E., Glisson, B.S., El-Naggar, A.K., Elamin, Y.Y., 2022a. A phase 2 clinical trial of axitinib and avelumab in patients with recurrent/metastatic adenoid cystic carcinoma (ACC). *J. Clin. Oncol.* 40 (suppl 16) https://doi.org/10.1200/JCO.2022.40.16_suppl.6019.
- Ferrarotto, R., Eckhardt, G., Patnaik, A., LoRusso, P., Faoro, L., Heymach, J.V., Kapoun, A.M., Xu, L., Munster, P., 2018. A phase I dose-escalation and dose-expansion study of brotixumab in subjects with selected solid tumors. *Ann. Oncol.* 29 (7), 1561–1568. <https://doi.org/10.1093/annonc/mdy171>.
- Ferrarotto, R., Metcalf, R., Rodriguez, C.P., Muzaffar, J., Even, C., Perez, C.A., Van Herpen, C.M.L., Oliva, M., Xia, B., Bowles, D.W., Popovtzer, A., Winquist, E., Wirth, L.J., Hao, D., Kang, H., Hotte, S.J., Stemmer, S.M., Mehra, R., Worden, F.P., Ho, A.L., 2022b. Results of ACCURACY: a phase 2 trial of AL101, a selective gamma secretase inhibitor, in subjects with recurrent/metastatic (R/M) adenoid cystic carcinoma (ACC) harboring Notch activating mutations (Notchmut). *J. Clin. Oncol.* 40 (suppl 16) <https://doi.org/10.1200/JCO.2022.40.16>.
- Ferrarotto, R., Mitani, Y., Diao, L., Gujjarro, I., Wang, J., Zweidler-McKay, P., Bell, D., William Jr, W.N., Glisson, B.S., Wick, M.J., Kapoun, A.M., Patnaik, A., Eckhardt, G., Munster, P., Faoro, L., Dupont, J., Lee, J.J., Futreal, A., El-Naggar, A.K., Heymach, J. V., 2017. Activating NOTCH1 mutations define a distinct subgroup of patients with adenoid cystic carcinoma who have poor prognosis, propensity to bone and liver metastasis, and potential responsiveness to Notch1 inhibitors. *J. Clin. Oncol.* 35 (3), 352–360. <https://doi.org/10.1200/JCO.2016.67.5264>. Epub 2016 Nov 21. PMID: 27870570; PMCID: PMC5456373.
- Ferrarotto, R., Mitani, Y., McGrail, D.J., Li, K., Karpinet, T.V., Bell, D., Frank, S.J., Song, X., Kupferman, M.E., Liu, B., Lee, J.J., Glisson, B.S., Zhang, J., Aster, J.C., Lin, S.Y., Futreal, P.A., Heymach, J.V., El-Naggar, A.K., 2021. Proteogenomic analysis of salivary adenoid cystic carcinomas defines molecular subtypes and identifies therapeutic targets. *Clin. Cancer Res.* 27 (3), 852–864. <https://doi.org/10.1158/1078-0432.CCR-20-1192>. Epub 2020 Nov 10. PMID: 33172898; PMCID: PMC7854509.
- Fujii, K., Murase, T., Beppu, S., Saida, K., Takino, H., Masaki, A., Ijichi, K., Kusafuka, K., Iida, Y., Onitsuka, T., Yatabe, Y., Hanai, N., Hasegawa, Y., Inagaki, H., 2017. MYB, MYBL1, MYBL2 and NFIB gene alterations and MYC overexpression in salivary gland adenoid cystic carcinoma. *Histopathology* 71 (5), 823–834. <https://doi.org/10.1111/his.13281>.
- Gao, R., Cao, C., Zhang, M., Lopez, M.C., Yan, Y., Chen, Z., Mitani, Y., Zhang, L., Zajac-Kaye, M., Liu, B., Wu, L., Renne, R., Baker, H.V., El-Naggar, A., Kaye, F.J., 2014. A unifying gene signature for adenoid cystic cancer identifies parallel MYB-dependent and MYB-independent therapeutic targets. *Oncotarget* 5 (24), 12528–12542. <https://doi.org/10.18632/oncotarget.2985>.
- Geiger, J.L., Ismail, A., Beadle, B., Caudell, J.J., Chau, N., Deschler, D., Glastonbury, C., Kaufman, M., Lamarre, E., Lau, H.Y., Licitra, L., Moore, M.G., Rodriguez, C., Roshal, A., Seethala, R., Swiecicki, P., Ha, P., 2021. Management of salivary gland malignancy: ASCO guideline. *J. Clin. Oncol.* 39 (17), 1909–1941. <https://doi.org/10.1200/JCO.21.00449>. Epub 2021 Apr 26. PMID: 33900808.
- Goncalves, P.H., Heilbrun, L.K., Barrett, M.T., Kummur, S., Hansen, A.R., Siu, L.L., Piekarz, R.L., Sukari, A.W., Chao, J., Pilat, M.J., Smith, D.W., Casetta, L., Boerner, S. A., Chen, A., Lenkiewicz, E., Malasi, S., LoRusso, P.M., 2017. A phase 2 study of vorinostat in locally advanced, recurrent, or metastatic adenoid cystic carcinoma. *Oncotarget* 8 (20), 32918–32929. <https://doi.org/10.18632/oncotarget.16464>. PMID: 28415633; PMCID: PMC5464838.

- Guan, W.J., Li, S.Y., Zhong, N.S., 2018. Effects of para-toluenesulfonamide intratumoral injection on pulmonary adenoid cystic carcinoma complicating with severe central airway obstruction: a 5-year follow-up study. *J. Thorac. Dis.* 10 (4), 2448–2455. <https://doi.org/10.21037/jtd.2018.03.70>. PMID: 29850151; PMCID: PMC5949465.
- Hanna, G.J., O'Neill, A., Cutler, J.M., Flynn, M., Vijaykumar, T., Clark, J.R., Wirth, L.J., Lorch, J.H., Park, J.C., Mito, J.K., Lohr, J.G., Kaufman, J., Burr, N.S., Zon, L.I., Haddad, R.L., 2021. A phase II trial of all-trans retinoic acid (ATRA) in advanced adenoid cystic carcinoma. *Oral. Oncol.* 119, 105366 <https://doi.org/10.1016/j.oraloncology.2021.105366>. PMID: 34091189.
- van Herpen, C.M., Locati, L.D., Buter, J., Thomas, J., Bogaerts, J., Lacombe, D., de Mulder, P., Awada, A., Licitra, L., Bernier, J., Vermorken, J.B., 2008. Phase II study on gemcitabine in recurrent and/or metastatic adenoid cystic carcinoma of the head and neck (EORTC 24982). *Eur. J. Cancer.* 44 (17), 2542–2545. <https://doi.org/10.1016/j.ejca.2008.08.014>. PMID: 18819792.
- Ho, A.L., Dunn, L., Sherman, E.J., Fury, M.G., Baxi, S.S., Chandramohan, R., Dogan, S., Morris, L.G., Cullen, G.D., Haque, S., Sima, C.S., Ni, A., Antonescu, C.R., Katabi, N., Pfister, D.G., 2016a. A phase II study of axitinib (AG-013736) in patients with incurable adenoid cystic carcinoma. *Ann. Oncol.* 27 (10), 1902–1908. <https://doi.org/10.1093/annonc/mdw287>. Epub 2016 Aug 26. PMID: 27566443; PMCID: PMC5035791.
- Ho, A.L., Sherman, E.J., Baxi, S.S., Haque, S., Ni, A., Antonescu, C.R., Katabi, N., Morris, L.G., Chan, T.A., Pfister, D.G., 2016b. Phase II study of regorafenib in progressive, recurrent/metastatic adenoid cystic carcinoma. *J. Clin. Oncol.* 34 (15 suppl), 6096–6096.
- Ho, A.S., Kannan, K., Roy, D.M., Morris, L.G., Ganly, I., Katabi, N., Ramaswami, D., Walsh, L.A., Eng, S., Huse, J.T., Zhang, J., Dolgalev, I., Huberman, K., Heguy, A., Viale, A., Drobnjak, M., Leversha, M.A., Rice, C.E., Singh, B., Iyer, N.G., Leemans, C. R., Bloemena, E., Ferris, R.L., Seethala, R.R., Gross, B.E., Liang, Y., Sinha, R., Peng, L., Raphael, B.J., Turcan, S., Gong, Y., Schultz, N., Kim, S., Chiosea, S., Shah, J. P., Sander, C., Lee, W., Chan, T.A., 2013. The mutational landscape of adenoid cystic carcinoma. *Nat. Genet.* 45 (7), 791–798. <https://doi.org/10.1038/ng.2643>. Epub 2013 May 19. PMID: 23685749; PMCID: PMC3708595.
- Ho, A.S., Ochoa, A., Jayakumar, G., Zehir, A., Valero Mayor, C., Tepe, J., Makarov, V., Dalin, M.G., He, J., Bailey, M., Montesion, M., Ross, J.S., Miller, V.A., Chan, L., Ganly, I., Dogan, S., Katabi, N., Tsiouras, P., Ha, P., Agrawal, N., Solit, D.B., Futreal, P.A., El Naggar, A.K., Reis-Filho, J.S., Weigelt, B., Ho, A.L., Schultz, N., Chan, T.A., Morris, L.G., 2019. Genetic hallmarks of recurrent/metastatic adenoid cystic carcinoma. *J. Clin. Investig.* 129 (10), 4276–4289. <https://doi.org/10.1172/JCI128227>. PMID: 31483290; PMCID: PMC6763222.
- Hong, D.S., DuBois, S.G., Kummer, S., Farago, A.F., Albert, C.M., Rohrberg, K.S., van Tilburg, C.M., Nagasubramanian, R., Berlin, J.D., Federman, N., Mascarenhas, L., Georger, B., Dowlati, A., Pappo, A.S., Bielack, S., Doz, F., McDermott, R., Patel, J.D., Schilder, R.J., Tahara, M., Pfister, S.M., Witt, O., Ladanyi, M., Rudzinski, E.R., Nanda, S., Childs, B.H., Laetsch, T.W., Hyman, D.M., Drilon, A., 2020. Larotrectinib in patients with TRK fusion-positive solid tumours: a pooled analysis of three phase 1/2 clinical trials. *Lancet Oncol.* 21 (4), 531–540. [https://doi.org/10.1016/S1470-2045\(19\)30856-3](https://doi.org/10.1016/S1470-2045(19)30856-3). Epub 2020 Feb 24. PMID: 32105622; PMCID: PMC7497841.
- Hoover, A.C., Milhem, M.M., Anderson, C.M., Sun, W., Smith, B.J., Hoffman, H.T., Buatti, J.M., 2015. Efficacy of nelfinavir as monotherapy in refractory adenoid cystic carcinoma: Results of a phase II clinical trial. *Head Neck* 37 (5), 722–726. <https://doi.org/10.1002/hed.23664>. PMID: 24596143.
- Hotte, S.J., Hao, D., Pond, G.R., Laurie, S.A., Winquist, E., Filion, M., Levine, M.N., 2016. Dovitinib in advanced adenoid cystic carcinoma of the salivary glands: Ontario Clinical Oncology Group DOVE trial. *Ann. Oncol.* 27 (6), vi335. <https://doi.org/10.1093/annonc/mdw376.24>.
- Huang, B., Tian, L., McCaw, Z.R., Luo, X., Talukder, E., Rothenberg, M., Xie, W., Choueiri, T.K., Kim, D.H., Wei, L.J., 2020. Analysis of response data for assessing treatment effects in comparative clinical studies. *Ann. Intern. Med.* 173 (5), 368–374. <https://doi.org/10.7326/M20-0104>.
- Imai, K., Takaoka, A., 2006. Comparing antibody and small-molecule therapies for cancer. *Nat. Rev. Cancer* 6 (9), 714–727. <https://doi.org/10.1038/nrc1913>. PMID: 16929325.
- Jin, S., Pazdur, R., Sridhara, R., 2017. Re-evaluating eligibility criteria for oncology clinical trials: analysis of investigational new drug applications in 2015. *J. Clin. Oncol.* 35 (33), 3745–3752. <https://doi.org/10.1200/JCO.2017.73.4186>. Epub 2017 Oct 2. PMID: 28968168; PMCID: PMC5692723.
- Kang, E.J., Ahn, M.J., Ock, C.Y., Lee, K.W., Kwon, J.H., Yang, Y., Choi, Y.H., Kim, M.K., Ji, J.H., Yun, T., Nam, B.H., Kim, S.B., Keam, B., 2021. Randomized phase II study of axitinib versus observation in patients with recurrent or metastatic adenoid cystic carcinoma. *Clin. Cancer Res.* <https://doi.org/10.1158/1078-0432.CCR-21-1061>. Epub ahead of print. PMID: 34315722.
- Keam, B., Kim, S.B., Shin, S.H., Cho, B.C., Lee, K.W., Kim, M.K., Yun, H.J., Lee, S.H., Yoon, D.H., Bang, Y.J., 2015. Phase 2 study of dovitinib in patients with metastatic or unresectable adenoid cystic carcinoma. *Cancer* 121 (15), 2612–2617. <https://doi.org/10.1002/ncr.29401>. Epub 2015 Apr 22. PMID: 25903089.
- Kim, D.W., Oh, D.Y., Shin, S.H., Kang, J.H., Cho, B.C., Chung, J.S., Kim, H., Park, K.U., Kwon, J.H., Han, J.Y., Kim, M.J., Bang, Y.J., 2014. A multicenter phase II study of everolimus in patients with progressive unresectable adenoid cystic carcinoma. *BMC Cancer* 14, 795. <https://doi.org/10.1186/1471-2407-14-795>. PMID: 25362970.
- Kim, E.S., Bernstein, D., Hilsenbeck, S.G., Chung, C.H., Dicker, A.P., Ersek, J.L., Stein, S., Khuri, F.R., Burgess, E., Hunt, K., Ivy, P., Bruinooge, S.S., Meropol, N., Schilsky, R.L., 2015. Modernizing eligibility criteria for molecularly driven trials. *J. Clin. Oncol.* 33 (25), 2815–2820. <https://doi.org/10.1200/JCO.2015.62.1854>. Epub 2015 Jul 20. PMID: 26195710.
- Korchagina, D., Jaroslowski, S., Jadot, G., Toumi, M., 2019. Orphan drugs in oncology. *Recent Results Cancer Res.* 213, 109–142. https://doi.org/10.1007/978-3-030-01207-6_8.
- Kulkarni, N., Pezzi, C.M., Greif, J.M., Suzanne Klimberg, V., Bailey, L., Korourian, S., Zuraek, M., 2013. Rare breast cancer: 933 adenoid cystic carcinomas from the National Cancer Data Base. *Ann. Surg. Oncol.* 20 (7), 2236–2241.
- Lenvima prescribing information FDA, Accessed January 13 2022, Available online at (https://www.accessdata.fda.gov/drugsatfda_docs/label/2021/206947s020lbl.pdf).
- Linxweiler, M., Kuo, F., Katabi, N., Lee, M., Nadeem, Z., Dalin, M.G., Makarov, V., Chowell, D., Dogan, S., Ganly, I., Hakimi, A.A., Wong, R.G., Riaz, N., Ho, A.L., Chan, T.A., Morris, L.G.T., 2020. The immune microenvironment and neoantigen landscape of aggressive salivary gland carcinomas differ by subtype. *Clin. Cancer Res.* 26 (12), 2859–2870. <https://doi.org/10.1158/1078-0432.CCR-19-3758>. Epub 2020 Feb 14. PMID: 32060100; PMCID: PMC7918996.
- Locati, L.D., Galbiati, D., Calareso, G., Alfieri, S., Singer, S., Cavalieri, S., Bergamini, C., Bossi, P., Orlandi, E., Resteghini, C., Platini, F., Granata, R., Quattrone, P., Mancinelli, M., Mariani, L., Lo Vullo, S., Licitra, L.F., 2020. Patients with adenoid cystic carcinomas of the salivary glands treated with lenvatinib: activity and quality of life. *Cancer* 126 (9), 1888–1894. <https://doi.org/10.1002/ncr.32754>. Epub 2020 Feb 7. PMID: 32031693.
- Locati, L.D., Perrone, F., Cortelazzi, B., Bergamini, C., Bossi, P., Civelli, E., Morosi, C., Lo Vullo, S., Imbimbo, M., Quattrone, P., Dagrada, G.P., Granata, R., Resteghini, C., Mirabile, A., Alfieri, S., Orlandi, E., Mariani, L., Saibene, G., Pilotti, S., Licitra, L., 2016. A phase II study of sorafenib in recurrent and/or metastatic salivary gland carcinomas: translational analyses and clinical impact. *Eur. J. Cancer* 69, 158–165. <https://doi.org/10.1016/j.ejca.2016.09.022>. Epub 2016 Nov 5. PMID: 27821319.
- Mahmood, U., Bang, A., Chen, Y.H., Mak, R.H., Lorch, J.H., Hanna, G.J., Nishino, M., Manuszak, C., Thrash, E.M., Severgnini, M., Sanborn, M., Sridharan, V., Margalit, D. N., Tishler, R.B., Busse, P.M., Willers, H., Mamon, H.J., Yoo, H.J., Pai, S.I., Wirth, L. J., Haddad, R.L., Chau, N.G., Schoenfeld, J.D., 2021. A randomized phase 2 study of pembrolizumab with or without radiation in patients with recurrent or metastatic adenoid cystic carcinoma. *Int. J. Radiat. Oncol. Biol. Phys.* 109 (1), 134–144. <https://doi.org/10.1016/j.ijrobp.2020.08.018>. Epub 2020 Aug 8. PMID: 32781104.
- Mandelbaum, J., Shestopalov, I.A., Henderson, R.E., Chau, N.G., Knoechel, B., Wick, M. J., Zon, L.I., 2018. Zebrafish blastomere screen identifies retinoic acid suppression of MYB in adenoid cystic carcinoma. *J. Exp. Med.* 215 (10), 2673–2685. <https://doi.org/10.1084/jem.20180939>. PMID: 30209067.
- Mozley, P.D., Schwartz, L.H., Bendtsen, C., Zhao, B., Petrick, N., Buckler, A.J., 2010. Change in lung tumor volume as a biomarker of treatment response: a critical review of the evidence. *Ann. Oncol.* 21 (9), 1751–1755. <https://doi.org/10.1093/annonc/mdq051>. Epub 2010 Mar 23. PMID: 20332135.
- NCCN Clinical Practice Guidelines in Oncology (NCCN Guidelines®) - Head and Neck Cancers. Version 2.2022 — April 26, 2022. Available at: (https://www.nccn.org/pdf/officials/physician_gls/pdf/head-and-neck.pdf).
- Orphan Drug Act, 1983. Public Law 97-414. United States of America.
- Persson, M., Andrén, Y., Mark, J., Horlings, H.M., Persson, F., Stenman, G., 2009. Recurrent fusion of MYB and NFIB transcription factor genes in carcinomas of the breast and head and neck. *Proc. Natl. Acad. Sci. USA* 106 (44), 18740–18744. <https://doi.org/10.1073/pnas.0909114106>.
- Pfeffer, M.R., Talmi, Y., Catane, R., Symon, Z., Yosepovitch, A., Levitt, M., 2007. A phase II study of imatinib for advanced adenoid cystic carcinoma of head and neck salivary glands. *Oral Oncol.* 43 (1), 33–36. <https://doi.org/10.1016/j.oraloncology.2005.12.026>. Epub 2006 Jun 6. PMID: 16757202.
- Pham, T., Pereira, L., Roth, S., Galletta, L., Link, E., Akhurst, T., Solomon, B., Michael, M., Darcy, P., Sampurno, S., Heriot, A., Ramsay, R., Desai, J., 2019. First-in-human phase I clinical trial of a combined immune modulatory approach using TetMYPB vaccine and Anti-PD-1 antibody in patients with advanced solid cancer including colorectal or adenoid cystic carcinoma: the MYPHISMO study protocol (NCT03287427). *Contemp. Clin. Trials Commun.* 16, 100409 <https://doi.org/10.1016/j.conctc.2019.100409>.
- Pitrou, I., Boutron, I., Ahmad, N., Ravaud, P., 2009. Reporting of safety results in published reports of randomized controlled trials. *Arch. Intern. Med.* 169 (19), 1756–1761. <https://doi.org/10.1001/archinternmed.2009.306>.
- Ramalingam, S.S., Kummer, S., Sarantopoulos, J., Shibata, S., LoRusso, P., Yerk, M., Holleran, J., Lin, Y., Beumer, J.H., Harvey, R.D., Ivy, S.P., Belani, C.P., Egorin, M.J., 2010. Phase I study of vorinostat in patients with advanced solid tumors and hepatic dysfunction: a National Cancer Institute Organ Dysfunction Working Group study. *J. Clin. Oncol.* 28 (29), 4507–4512. <https://doi.org/10.1200/JCO.2010.30.2307>. Epub 2010 Sep 13. PMID: 20837947; PMCID: PMC2988640.
- Sambucini, V., 2015. Comparison of single-arm vs. randomized phase II clinical trials: a Bayesian approach. *J. Biopharm. Stat.* 25 (3), 474–489. <https://doi.org/10.1080/10543406.2014.920856>.
- Schulz, K.F., Altman, D.G., Moher, D., CONSORT Group, 2010. CONSORT 2010 Statement: updated guidelines for reporting parallel group randomised trials. *BMC Med.* 8, 18. <https://doi.org/10.1186/1741-7015-8-18>. PMID: 20334633; PMCID: PMC2860339.
- Sleire, L., Forde, H.E., Netland, I.A., Leiss, L., Skeie, B.S., Enger, P.O., 2017. Drug repurposing in cancer. *Pharm. Res.* 124, 74–91. <https://doi.org/10.1016/j.phrs.2017.07.013>. Epub 2017 Jul 13. PMID: 28712971.
- Tchekmedyan, V., Sherman, E.J., Dunn, L., Tran, C., Baxi, S., Katabi, N., Antonescu, C. R., Ostrovnya, I., Haque, S.S., Pfister, D.G., Ho, A.L., 2019. Phase II study of lenvatinib in patients with progressive, recurrent or metastatic adenoid cystic carcinoma. *J. Clin. Oncol.* 37 (18), 1529–1537. <https://doi.org/10.1200/JCO.18.01859>. Epub 2019 Apr 2. PMID: 30939095; PMCID: PMC6599407.
- Thomson, D.J., Silva, P., Denton, K., Bonington, S., Mak, S.K., Swindell, R., Homer, J., Sykes, A.J., Lee, L.W., Yap, B.K., Slevin, N.J., 2015. Phase II trial of sorafenib in

- advanced salivary adenoid cystic carcinoma of the head and neck. *Head Neck* 37 (2), 182–187. <https://doi.org/10.1002/hed.23577>. Epub 2014 Mar 13. PMID: 24346857.
- U.S Food and Drug Administration orphan drug database, Accessed on 12/01/2022 - available at (<https://www.accessdata.fda.gov/scripts/opdlisting/oopd/detailedIndex.cfm?cfgridkey=388012>).
- van der Wal, J.E., Becking, A.G., Snow, G.B., van der Waal, I., 2002. Distant metastases of adenoid cystic carcinoma of the salivary glands and the value of diagnostic examinations during follow-up. *Head Neck* 24 (8), 779–783. <https://doi.org/10.1002/hed.10126>. PMID: 12203804.
- Ye, L., Zhang, L., Li, R., Zhu, G., 2021. Preliminary results of the efficacy and safety of all-trans retinoic acid combined with low-dose apatinib in the treatment of patients with recurrent/metastatic adenoid cystic carcinoma of the head and neck, 6026-6026 *J. Clin. Oncol.* 39 (15 suppl). https://doi.org/10.1200/JCO.2021.39.15_suppl.6026.
- Zhu, G., Zhang, L., Dou, S., Li, R., Li, J., Ye, L., Jiang, W., Dong, M., Ruan, M., Yang, W., Zhang, C., 2021. Apatinib in patients with recurrent or metastatic adenoid cystic carcinoma of the head and neck: a single-arm, phase II prospective study. *Ther. Adv. Med. Oncol.* 13, 17588359211013626 <https://doi.org/10.1177/17588359211013626>. PMID: 33995600.

Vivian Petersen Wagner: DDS, PhD in Oral Pathology and Marie Skłodowska-Curie Fellow. Dr. Wagner is currently a lecturer at The School of Clinical Dentistry at The University of Sheffield. Her research focuses on salivary gland tumors, head and neck pathology and targeted therapies.

Renata Ferrarotto: MD, Clinical Fellow in Medical Oncology and Thoracic/Head and Neck Medical Oncology. Dr. Ferrarotto is an Associate Professor and Director of Head and Neck Oncology. She is involved with patient care and clinical and translational research.

Her work focuses on clinical development of new personalized cancer therapies, with a particular interest in salivary gland cancers.

Pablo Agustin Vargas: DDS, MSc, PhD in Oral Pathology and FRCPath (The Royal College of Pathologists-UK). Dr. Vargas is a Professor at the University of Campinas and Extraordinary Professor at University of Pretoria-South Africa. He is a diagnostic pathologist of oral lesions in Piracicaba and his main research fields are molecular pathology of salivary gland lesions, cysts and odontogenic tumors and oral cancer.

Manoela Domingues Martins: DDS, PhD in Oral Pathology. Dr. Martins is an Associate Professor at the Federal University of Rio Grande do Sul and Professor of the Post-Graduate Program in Oral Medicine and Pathology at the University of Campinas. Her research interests include oral wound healing, oral mucositis, deregulated pathways in oral cancer and target therapies.

Colin D. Bingle: BSc, PhD. Professor Bingle is a Professor of Respiratory Cell and Molecular Biology in the Department of Infection, Immunity and Cardiovascular Disease, University of Sheffield. His research interests include molecular basis of cell type specific gene expression, particularly the regulation, structure, expression and function of pulmonary epithelial genes.

Lynne Bingle: BSc, PhD. Dr Bingle is a Reader in the Academic Unit of Oral and Maxillofacial Pathology, School of Clinical Dentistry, University of Sheffield. Her research interests include the role and regulation of epithelial secretory proteins, the development of 3D in vitro model systems to study these proteins in airway epithelium. She has also developed 3D models to study tumorigenesis in salivary gland cancer by introducing novel fusion genes often found in these glandular tumors.