

## Left External Iliac Artery Aneurysm in horse – Case report

Aneurisma da Artéria Ilíaca Externa Esquerda em equino – Relato de caso

Aneurisma de la Arteria Ilíaca Externa Izquierda en un equino – Reporte de un caso

Received: 11/18/2023 | Revised: 12/02/2023 | Accepted: 12/03/2023 | Published: 12/05/2023

### **Anelise da Costa Silva**

ORCID: <https://orcid.org/0009-0007-1883-2859>  
Universidade Federal do Rio Grande do Sul, Brasil  
E-mail: [costanelise5@gmail.com](mailto:costanelise5@gmail.com)

### **Isadora Born**

ORCID: <https://orcid.org/0009-0000-1415-2089>  
Universidade Federal do Rio Grande do Sul, Brasil  
E-mail: [isadoraborn93@gmail.com](mailto:isadoraborn93@gmail.com)

### **Tainã Kuwer Jacobsen**

ORCID: <https://orcid.org/0000-0002-3497-4175>  
Universidade Federal do Rio Grande do Sul, Brasil  
E-mail: [tainajacobsen@gmail.com](mailto:tainajacobsen@gmail.com)

### **Grasiela De Bastiani**

ORCID: <https://orcid.org/0000-0002-4748-7560>  
Universidade Federal do Rio Grande do Sul, Brasil  
E-mail: [grasielabastiani@ufrgs.br](mailto:grasielabastiani@ufrgs.br)

### **Angela Siviero dos Santos**

ORCID: <https://orcid.org/0009-0003-3954-7396>  
Universidade Federal do Rio Grande do Sul, Brasil  
E-mail: [angsiviero@gmail.com](mailto:angsiviero@gmail.com)

### **Bruna Silveira Rodrigues**

ORCID: <https://orcid.org/0009-0003-6548-7163>  
Universidade Federal do Rio Grande do Sul, Brasil  
E-mail: [brunasilveirarodrigues@hotmail.com](mailto:brunasilveirarodrigues@hotmail.com)

### **Abstract**

An aneurysm is defined as the abnormal and localized dilation of a blood vessel, which can be congenital or acquired. The main consequence is vessel rupture, leading to hemorrhage, hypovolemic shock, and subsequent sudden death. Clinical signs can also be silent or resemble other pathologies, making the diagnosis complex. This study aims to report the clinical case of a Criollo mare diagnosed with an aneurysm of the left external iliac artery, as well as the treatment and diagnostic methods. During the anamnesis, it was observed that the patient experienced episodes of acute abdominal discomfort with rapid and spontaneous resolution, anorexia, and progressive weight loss for approximately a year. Musculoskeletal evaluation revealed grade III lameness in the left pelvic limb. Rectal palpation revealed a parasagittal increase in volume near the lumbosacral segment with a palpable pulse in the region of the left abdominal aorta. Rectal ultrasound with a linear probe (5.5 MHz) revealed decreased and retrograde blood flow compared to the contralateral vessel, suggesting an aneurysm of the left external iliac artery. The prescribed treatment involved the administration of acepromazine, omeprazole, and acetylsalicylic acid for 90 days. Ultrasonography was essential for the final diagnosis and resolution of the reported case, along with the combination of drugs described in the therapeutic protocol.

**Keywords:** Aneurysm; Equine; Artery; Iliac.

### **Resumo**

O aneurisma é definido quando ocorre uma dilatação anormal e localizada de um vaso sanguíneo, podendo ser congênita ou adquirida. A principal consequência é a ruptura do vaso, hemorragia, choque hipovolêmico e por seguinte morte súbita. Os sinais clínicos também podem ser silenciosos ou assemelhando-se a outras patologias, o que torna o diagnóstico complexo. O presente trabalho tem como objetivo relatar o caso clínico de uma égua, crioula, diagnosticada com aneurisma da artéria ilíaca externa esquerda, bem como o tratamento e métodos de diagnóstico. Durante anamnese, constatou-se que a paciente apresentava quadros de desconforto abdominal agudos e com resolução rápida e espontânea, anorexia e emagrecimento progressivo há mais ou menos um ano. Na avaliação musculoesquelética, evidenciou-se claudicação grau III no membro pélvico esquerdo (MPE). Por meio da palpação retal, observou-se um aumento de volume parasagital ao segmento lombo sacral com pulso evidente na região da aorta abdominal esquerda. Foi realizada ultrassonografia retal acoplado a uma probe linear retal (5,5 MHz). Na avaliação com método doppler se notou fluxo sanguíneo diminuído e retrógrado quando comparada ao vaso contralateral, sugerindo desta forma, um quadro de aneurisma de artéria ilíaca externa esquerda. O tratamento prescrito baseou-se na administração de acepromazina,

omeprazol e ácido acetilsalicílico, durante 90 dias. O exame ultrassonográfico foi essencial para o diagnóstico final e resolução do caso relatado, bem como, a associação dos fármacos descritos no protocolo terapêutico.

**Palavras-chave:** Aneurisma; Equino; Arteria; Íliaca.

### Resumen

Un aneurisma se define como la dilatación anormal y localizada de un vaso sanguíneo, pudiendo ser congénita o adquirida. La principal consecuencia es la ruptura del vaso, hemorragia, shock hipovolémico y, posteriormente, muerte súbita. Los signos clínicos también pueden ser silenciosos o parecerse a otras patologías, lo que dificulta el diagnóstico. Este estudio tiene como objetivo informar el caso clínico de una yegua Criolla diagnosticada con un aneurisma de la arteria íliaca externa izquierda, así como el tratamiento y los métodos de diagnóstico. Durante la anamnesis, se observó que la paciente presentaba episodios de malestar abdominal agudo con resolución rápida y espontánea, anorexia y pérdida de peso progresiva durante aproximadamente un año. En la evaluación musculoesquelética se evidenció claudicación de grado III en el miembro pélvico izquierdo. La palpación rectal reveló un aumento de volumen parasagital cerca del segmento lumbosacro con un pulso palpable en la región de la aorta abdominal izquierda. Se realizó una ecografía rectal con una sonda lineal (5,5 MHz). En la evaluación con el método Doppler se observó un flujo sanguíneo disminuido y retrógrado en comparación con el vaso contralateral, sugiriendo así un cuadro de aneurisma de la arteria íliaca externa izquierda. El tratamiento prescrito consistió en la administración de acepromazina, omeprazol y ácido acetilsalicílico durante 90 días. La ecografía fue esencial para el diagnóstico final y la resolución del caso, junto con la combinación de los fármacos descritos en el protocolo terapéutico.

**Palabras clave:** Aneurisma; Equino; Arteria; Íliaca.

## 1. Introduction

The iliac artery aneurysm is uncommon in horses, being more frequently described in the aortic artery. The use of ultrasonography for diagnosis is important and necessary because it involves lesions in different locations of the iliac artery and different courses of pathological development. Post-mortem diagnosis is also possible in cases of sudden death (Oliveira & Silva, 2017).

The main complication of an aneurysm is the potential rupture of the affected vessel, leading to hemorrhage, hypovolemic shock, and subsequent sudden death (Vera et al., 2021). In most cases of aneurysm in animals, the condition is idiopathic, with *Strongylus vulgaris* being the primary cause in horses (Almeida & Mello, 2015). This parasite can lead to thrombosis and, consequently, vessel rupture. The aorta is the primary artery that carries oxygenated blood from the heart to other arteries (Klein, 2021); when it ruptures, it causes hemorrhage and ultimately the death of the animal (Hurcombe, 2022). Unfortunately, in the majority of cases, symptoms are silent, and when the condition is advanced, treatment is ineffective (Oliveira & Silva, 2017).

The present study aims to report the clinical case of a Criollo mare diagnosed with an aneurysm of the left external iliac artery, as well as the treatment and diagnostic methods.

## 2. Methodology

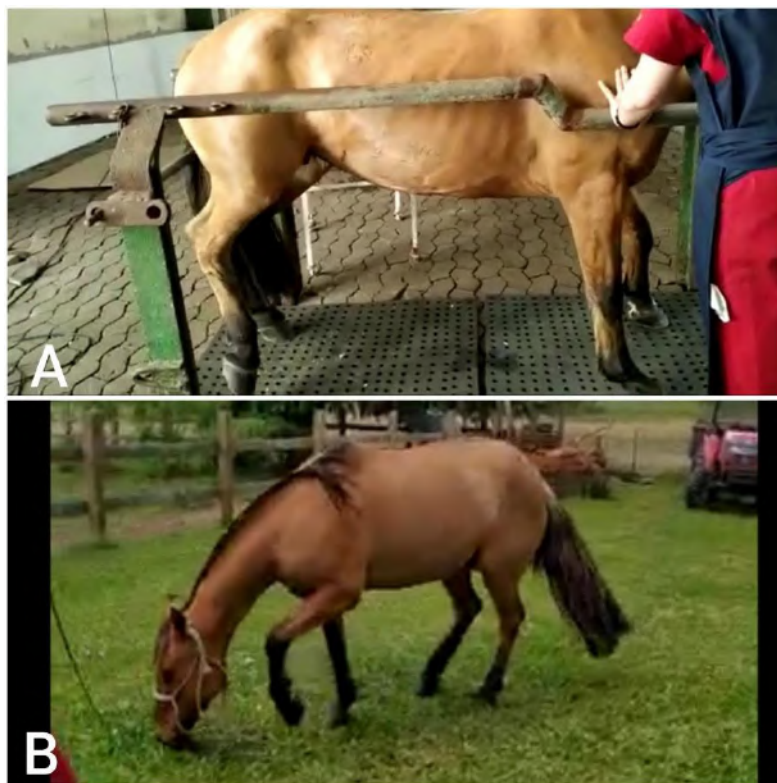
An equine, female, Criollo breed, approximately 18 years old and weighing around 365 kg, was referred to the Veterinary Clinics Hospital (HCV) of the Federal University of Rio Grande do Sul (UFRGS) (latitude - 30.0759715298907, longitude -51.12703974879086). According to the medical history, the mare had been experiencing episodes of abdominal discomfort for approximately a year, which worsened in the final third of the previous pregnancy, accompanied by anorexia, lack of appetite, and progressive weight loss.

In the general clinical examination, the mare exhibited apathetic behavior, a body condition score of 3, docile temperament, a heart rate (HR) of 40 beats per minute (bpm), a respiratory rate (RR) of 20 breaths per minute (bpm), rectal temperature of 37.8°C, capillary refill time (CRT) of 2 seconds, pale pink mucous membranes, and normal abdominal auscultation findings. Throughout the hospitalization period, the patient maintained appetite, passed feces with a soft texture and formed fecal balls (síbalas), and exhibited normal urine production without alterations.

In the assessment of the musculoskeletal system, grade 3 lameness (AAEP, 2005) was evident in the left pelvic limb. In the evaluation of the axial skeleton, there was observed myopenia in the thoracolumbar region associated with mild myopenia in the left hindquarter. Additionally, there was an absence of lateralization mobility in the cervical spine, along with reduced extension and flexion mobility in the thoracolumbar spine, accompanied by painful reactions to manual manipulation of the same segment.

During hospitalization, the patient exhibited recurrent episodes of excessive contraction of the abdominal musculature and attempts to lie down and roll, suggestive of abdominal discomfort (Figure 1). These episodes had an average duration of minutes, and after each episode, the horse returned to grazing normally. Transabdominal ultrasound did not reveal noteworthy changes. Blood evaluations, including a complete blood count and biochemical analysis, as well as macroscopic and microscopic examination of peritoneal fluid, showed no significant alterations.

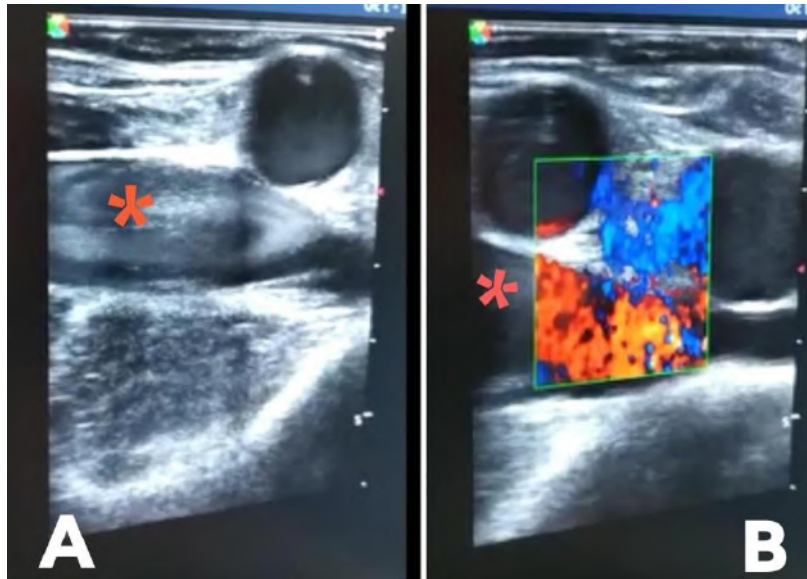
**Figure 1** - Horse exhibiting a sawhorse position, abdominal muscle contraction, and discomfort during a pain crisis (A). Horse grazing with signs of discomfort and attempts to lie down during a pain crisis (B).



Source: Authors (2023).

During rectal palpation of the abdominal and pelvic cavity, no alterations in gastrointestinal or genital segments were noted. However, there was an apparent parasagittal increase in volume in the lumbosacral segment with a palpable pulse when compared to the contralateral segment. To further investigate, rectal ultrasonography using a Sonoescape probe with a linear frequency of 5.5 MHz was performed. The probe was positioned ventrally to the L6 promontory, moving to the left along the intertransverse joint, reaching a considerable increase in volume compared to the contralateral vessel of the external iliac artery. Additionally, a thin vessel wall in longitudinal section associated with caudal dilation was observed. Doppler evaluation revealed decreased and retrograde blood flow compared to the right contralateral vessel, suggesting a condition of left external iliac artery aneurysm (Figure 2).

**Figure 2** - Rectal ultrasonographic examination in a horse, left external iliac artery (red asterisk). A thin vessel wall associated with caudal dilation is observed (A). Doppler evaluation shows decreased and retrograde blood flow compared to the right contralateral vessel (B).



Source: Authors (2023).

Due to the complexity of the clinical presentation and the findings in imaging exams, the case was discussed with three veterinary experts in the field, along with an in-depth literature review to consider the diagnostic interpretation. The lameness in the left pelvic limb, along with frequent episodes of abdominal discomfort, excessive contraction of the abdominal musculature, and the imaging alterations in the external iliac artery, directed the therapeutic treatment towards the administration of 1% acepromazine (0.03 mg/kg, twice daily, orally), omeprazole (4.4 mg/kg, once daily, orally), and acetylsalicylic acid (8.5 mg/kg, once daily, orally). The described treatment was maintained for 90 days.

In a new ultrasonographic evaluation, twelve months after the hospitalization period, a decrease in the diameter of the left external iliac artery was observed. Additionally, there were no clinical signs as described earlier, according to information provided by the owner (Figure 3). The owner also indicated that the horse is kept in an extensive grazing system with *Lolium multiflorum* pasture (ryegrass) and supplemented with 1% of its body weight, resulting in a weight gain of approximately 70 kg and an alert demeanor.

**Figure 3** - The owner reported that the patient no longer experiences abdominal discomfort and shows stability in the case.



Source: Authors (2023).

### 3. Results and Discussion

The aorta is the most important vessel in the general blood circulation, originating at the base of the left ventricle and extending distally as the thoracic aorta, and subsequently as the abdominal aorta. The terminal branches of the abdominal aorta are called the iliac arteries. The iliac arteries play a crucial role in supplying blood to the pelvic region, with the external iliac arteries specifically responsible for irrigating the pelvic limbs (Singh, 2019).

Aneurysms or dilations of the arterial wall are clinically significant due to the high risk of death from rupture, as well as the potential for severe sequelae. The ante-mortem diagnosis of a sinus of Valsalva aneurysm or aortocardiac fistula can be performed through echocardiography and Doppler. Aneurysms of this nature may be associated with aortic regurgitation (due to an aneurysm in the aortic sinus) or as a consequence of ventricular septal defects (Reed et al., 2021). On the other hand, iliac artery aneurysms are rarely diagnosed in veterinary medicine, and the diagnostic method of rectal ultrasonography can be employed (Ortega et al., 2022).

Iliac artery aneurysm is a complex diagnosis due to limited information available in the literature regarding its classification, clinical signs, and treatments. It is of utmost importance in veterinary medicine, as it is a frequent cause of sudden death in horses (Vera et al., 2020). Through ultrasonographic images, the flow, size, and shape of vessels can be observed, allowing the diagnosis of cases of arterial dilation and rupture, hemorrhages, and flow alterations (Buhl & Erbsoll, 2004). The goal of using the Doppler ultrasound method is to assist in observing blood flow and the degree of dilation (Silva & Mamprim, 2009). In the present report, rectal ultrasonography revealed retrograde blood flow in the left iliac artery associated with a decrease in wall thickness (Ortega et al., 2022).

The significance of this study lies not only in the challenge of diagnosis but in presenting possibilities for patients with

this condition to achieve a satisfactory and long-lasting quality of life. It is worth emphasizing that in these cases, the use of ultrasonographic images becomes indispensable, as it allows for diagnosis during the patient's lifetime (Ploeg & Saey, 2017).

A acepromazine belongs to the phenothiazine group and can be used either alone as a tranquilizer or in combination with an opioid for sedation. It can be administered intravenously, intramuscularly, or subcutaneously. Studies report that its effects last for 4 to 8 hours (Knych & Semionoff, 2018). Through the use of palliative therapeutic treatments like acepromazine, it was possible to reduce the frequency and intensity of episodes due to its tranquilizing effect, potentially providing a better quality of life for the animal and extending its lifespan (López et al., 2022).

Omeprazole is an orally administered medication used to maintain the natural pH of the stomach and prevent gastric ulcers from possible acids with a pH above the acceptable range for the stomach mucosa. It binds to proton pumps and inactivates their function, reducing acid production (Pagan & Petroski-Rose, 2020). In this case, the medication was recommended to protect the gastric mucosa and maintain pH, as the patient was concurrently using two other oral medications.

Acetylsalicylic acid is a non-steroidal anti-inflammatory drug with analgesic and antipyretic properties. Additionally, through its anti-inflammatory action, it inhibits platelet aggregation and vasoconstriction. In horses, among other pathologies, it is recommended for thrombosis prevention. It can be administered orally (Spinosa & Górniak, 2017). Therefore, this medication was beneficial in assisting with the treatment, particularly as a vasoconstrictor to prevent thrombosis (Sistla et al., 2023).

Furthermore, in equine veterinary medical practice, there is a lack of information regarding the reproducibility of locally and regionally derived arterial wall stiffness parameters obtained through ultrasound (Vera et al., 2019). It is known that the arterial wall stiffens with aging due to a combination of increased lumen and arterial wall thickening, making arterial rupture predominantly affect older horses (Reymond & Westerhof, 2012). It is worth noting that the patient in this case is 18 years old, aligning with the reported data.

#### 4. Conclusion

Aneurysm in horses presents itself as an uncommon pathology, with nonspecific clinical signs that can be confused with other conditions. The importance of ultrasonographic examination in veterinary clinical practice was highlighted, as the final diagnosis of aneurysm of the left external iliac artery was only possible through imaging. Regarding treatment, the combination of acepromazine and acetylsalicylic acid proved effective in controlling clinical signs by reducing the frequency and intensity of painful episodes. The therapeutic approach used was of paramount importance for the successful recovery of the patient.

Therefore, the importance of further research in the face of this uncommon pathology in horses is emphasized. This is to ensure that new methods of clinical and complementary diagnosis are developed and reported.

#### References

- Almeida, T. L. & Mello, J. M. (2015). Arterite verminótica em equinos: revisão. *Pubvet*, 4(12).
- Belknap, J. K. & Black, S. J. (2005). Review of the pathophysiology of the developmental stages of equine laminitis. *51st Annual Convention of the American Association of Equine Practitioners (AAEP)*, Seattle, WA, USA.
- Buhl, R., Ersboll, A. K., Eriksen, L., & Koch, J. (2004). Sources and magnitude of variation of echocardiographic measurements in normal standardbred horses. *Veterinary Radiology & Ultrasound*, 45(6):505-512.
- Klein, B. G. (2021). *Cunningham Tratado de Fisiologia Veterinária*. Grupo GEN. E-book. 184-185.
- Knych, H. K., Semionoff, K., Mckemie, D. S. & Kass, P. H. (2018). Pharmacokinetics, pharmacodynamics, and metabolism of acepromazine following intravenous, oral, and sublingual administration to exercised Thoroughbred horses. *Journal of veterinary pharmacology and therapeutics*, 41(4), 522–535.
- Oliveira, R. G., Silva, T. P. D., dos Santos, A. B. N., Saquetti, C. H. C., Alves, S. R. & Rajão, M. D. (2017). Aneurisma de artéria ilíaca em equinos. *Acta Scientiae Veterinariae*, 45(5). doi.org/10.22456/1679-9216.85346.
- Pagan, J. D., Petroski, R. L., Mann, A. & Hauss, A. (2020). Omeprazole Reduces Calcium Digestibility in Thoroughbred Horses. *Journal of equine veterinary science*, 86, 102851.

- Ploeg, M., Saey, V., Van Loon, G. & Delesalle, C. (2017). Thoracic aortic rupture in horses. *Equine Vet J*, 49: 269-274.
- Reed, S. M., Bayly, W. M. & Sellon, D. C. (2021). *Medicina Interna Equina*. Disponível em: Minha Biblioteca, (4a ed.). Grupo GEN. 401-514
- Reymond, P., Westerhof, N. & Stergiopulos, N. (2011). Systolic hypertension mechanisms: effect of global and local proximal aorta stiffening on pulse pressure. *Ann Biomed Eng.* 40(3):742-9. doi: 10.1007/s10439-011-0443-x.
- Silva, V. C., Mamprim, M. J., Vulcano, L. C. & Doiche, D. P. (2009). Ultra-sonografia Doppler e angiografia tomográfica computadorizada no diagnóstico de desvios portossistêmicos - *revisão de literatura*. *Clínica Veterinária*. 78: 70-78.
- Singh, B. (2019). *Tratado de Anatomia Veterinária*. Disponível em: Minha Biblioteca, (5th edição). Grupo GEN. 224-239.
- Spinosa, H. S., Górnaiak, S. L. & Bernardi, M. M. (2017). *Farmacologia Aplicada à Medicina Veterinária*, (6a ed.) Grupo GEN. 256-264
- Vera, L., Arias, D. C., Muylle, S., Stergiopulos, N., Segers, P., & Van Loon, G. (2019). A 1D computer model of the arterial circulation in horses: An important resource for studying global interactions between heart and vessels under normal and pathological conditions. *PLoS One*. Aug 21;14(8):e0221425. doi: 10.1371
- Vera, L., Van, S. G., Decloedt, A., Chiers, K., & Van, L. G. (2020). Diferenças relacionadas à idade na pressão arterial, diâmetros arteriais derivados de ultrassom e parâmetros de rigidez da parede arterial em cavalos. *Equine Veterinary Journal*. Volume 52. Edição: 6.
- Vera, L., Muylle, S., Van, S. G., Segers, P., Decloedt, A., Chiers, K. & Van, L. G. (2021). Histological and biomechanical properties of systemic arteries in young and old Warmblood horses. *PLoS One*. Jul 12;16(7):e0253730.
- Ortega, C. F., Gómez, A. V., Martín, C. F. E., Gil, M. C., Peña, F. J., Gaitskell, P. G. & Da Silva, A. E. (2022). Advances in the ultrasound diagnosis in equine reproductive medicine. New approaches. *Reprod Domest Anim*. 57(5):34-44. 10.1111/rda.14192.
- Sistla, P., Kheder, K., Jourinets, J., Arora, P., Desai, P.V., Brailovsky, Y. & Darki, A. (2023). Catheter-Directed Thrombolysis or Catheter-Based Thrombectomy in Acute Pulmonary Embolism. *Horses for Courses. Interv Cardiol Clin*. Jul;12(3):309-321. 10.1016/j.iccl.2023.03.003.
- López, S. F. J., Montes, F. G., Gómez, C. D., Izquierdo, M. J., Varela Del Arco, M. & Manso, D. G. (2022). Morphine with or without Acepromazine in Horses. *A Kinematic Evaluation. Animals (Basel)*. 12(9):1193. 10.3390/ani12091193.
- Hurcombe, S. D. A., Radcliffe, R. M., Cook, V. L. & Divers, T. J. (2022). The pathophysiology of uncontrolled hemorrhage in horses. *Journal of Veterinary Emergency and Critical Care*. 32(S1):63-71. 10.1111/vec.13122.