

## Cutaneous Myxoma in Broiler Chicken Detected during Slaughtering

Thales Quedi Furian<sup>ORCID</sup>, Karen Apellanis Borges<sup>ORCID</sup>, Gabriela Zotis Chitolina, Karine Patrin Pontin<sup>ORCID</sup>,  
Luiz Cesar Bello Fallavena<sup>ORCID</sup>, Vladimir Pinheiro do Nascimento<sup>ORCID</sup>,  
Carlos Tadeu Pippi Salle<sup>ORCID</sup> & Hamilton Luiz de Souza Moraes<sup>ORCID</sup>

### ABSTRACT

**Background:** A cutaneous or superficial myxoma is a benign neoplasm of dermal or subcutaneous fibroblast origin. Although rare, it has been previously described in several species, including poultry. It presents as a single node or soft mass with a gelatinous cut surface. Histopathological analysis is essential for diagnosis and to differentiate it from other mesenchymal neoplasms and inflammatory or degenerative processes. Microscopically, it consists of dermal or subcutaneous lobules of plump, stellate, or spindle-shaped, bland-looking cells embedded in a basophilic myxoid matrix. This report describes the pathological findings in a rare case of cutaneous myxoma in a 42-day-old broiler flock.

**Cases:** During *ante mortem* inspection of a 42-day-old broiler flock at a slaughterhouse under the authority of the Federal Inspection Service (southern Brazil), nodular lesions or encrusted areas with yellow and black areas were observed in the head skin of less than 1% of animals. These lesions, approximately 0.5 cm in diameter, were observed on the comb, in the periocular skin region, and close to the animals' nostrils. During the breeding period, no health or epidemiological events were observed. Fragments of the lesions in the comb and periocular skin were collected and fixed in buffered 10% formalin. The samples were sent to the laboratory, routinely processed, and stained with hematoxylin and eosin and Alcian blue. Microscopically, the lesions consisted of irregular multifocal proliferation of connective tissue showing spindle cells with poorly demarcated borders and scarce cytoplasm in a slightly basophilic myxoid aspect matrix. The adjacent epidermis is compressed due to neoplastic proliferation. No areas of epithelial hyperplasia or inclusion bodies were observed. According to the pathologic description and considering its descriptive epidemiology, our main clinical suspicion was cutaneous fowl pox, a pathology characterized by the appearance of nodules in regions devoid of feathers. However, the microscopic changes observed were compatible with those described for cutaneous myxomas. In addition, the extracellular matrix was positive for Alcian Blue staining, which is an indicator of myxoma. In the present case, the SIF did not report the same macroscopic lesions in other flocks of the same origin.

**Discussion:** Connective tissue tumors, including myxomas, occur considerably less frequently under field conditions. In addition, these neoplasms are more frequent in mature birds and are not usually described in broilers, as observed in this report. The cutaneous myxoma described in broilers is usually a sporadic neoplasm that does not cause zootechnical losses, as observed in the case report. Its etiology is unknown and has been associated with various factors, such as local trauma and foreign bodies. Some fragments of plant material from the breeding environment were microscopically detected in the encrusted areas, which may indicate previous trauma or a foreign body. Myxoma has been associated with avian leukosis virus (ALV) subgroup A, but SIF did not report the same macroscopic lesions in other flocks of the same breeder hen's origin in the present case. Furthermore, sporadic connective tissue tumors associated with the virus occur in mature chickens but not in broilers. Myxoma lesions should be considered in the differential diagnosis of other connective tissue tumors and infectious agents that cause lesions in the skin and subcutaneous tissue.

**Keywords:** benign neoplasia, connective tissue tumor, histopathology, poultry.

DOI: 10.22456/1679-9216.127830

Received: 27 October 2022

Accepted: 6 February 2023

Published: 20 March 2023

Centro de Diagnóstico e Pesquisa em Patologia Aviária (CDPA), Departamento de Medicina Animal (DMA), Faculdade de Veterinária (FAVET), Universidade Federal do Rio Grande do Sul (UFRGS), Porto Alegre, RS, Brazil. CORRESPONDENCE: K.A. Borges [karen.borges@ufrgs.br]. Centro de Diagnóstico e Pesquisa em Patologia Aviária (CDPA) - UFRGS. Av. Bento Gonçalves n. 9090 CEP 91540-000 Porto Alegre, RS, Brazil.

## INTRODUCTION

Cutaneous myxoma, also known as superficial myxoma or superficial angiomyxoma, is a rare and benign neoplasm of dermal or subcutaneous fibroblast origin [8,14]. Myxoid tumors are rare and occur at a low frequency in both wild and domestic birds [10]. They are characterized by a myxomatous matrix rich in mucopolysaccharides, which are produced by mesenchymal cells [2,10].

In addition to the skin and subcutaneous tissues, myxomas can also occur in other regions and tissues, including the heart, bones, genitourinary tract, skeletal muscle, and any structure that contains connective tissue [8,16,18]. Swelling in these tissues requires histopathological analysis, which is essential for tumor diagnosis and differentiation from other mesenchymal neoplasms and inflammatory or degenerative processes [2,9]. On clinical examination, cutaneous myxomas are single nodes or soft masses with a gelatinous cut surface [2,16]. Microscopically, they consist of dermal or subcutaneous lobules of plump, stellate, or spindle-shaped, bland-looking cells embedded in a basophilic, highly vascular, myxoid matrix [3].

Although its incidence is rare, there are some sporadic descriptions of myxoma in canines and felines [4,5], bovines [15], and different bird species [2,10,16]. Considering the domestic chicken species (*Gallus gallus*), some reports have described myxoma lesions in fancy breed chickens [13], gamecock [18], and layer hens [17]. Typically, affected animals are older adults [18].

The present report describes the pathological findings of a rare case of cutaneous myxoma in a 42-day-old broiler flock detected during slaughter in southern Brazil.

## CASES

A total of 14,400 broilers were housed in a conventional poultry shed with a 1,200 m<sup>2</sup> area (100 m × 12 m). Broilers were vaccinated against infectious bursal disease, avian infectious bronchitis, fowl pox, and Marek's disease. During the breeding period, the total mortality rate was approximately 8.7%, and no health or epidemiological events were described in the breeding control formulary or in the health report, which accompanied the animals for slaughter. In total, 13,152 42-day-old broilers were transported to a slaughterhouse. However, 238 birds expired during transportation.

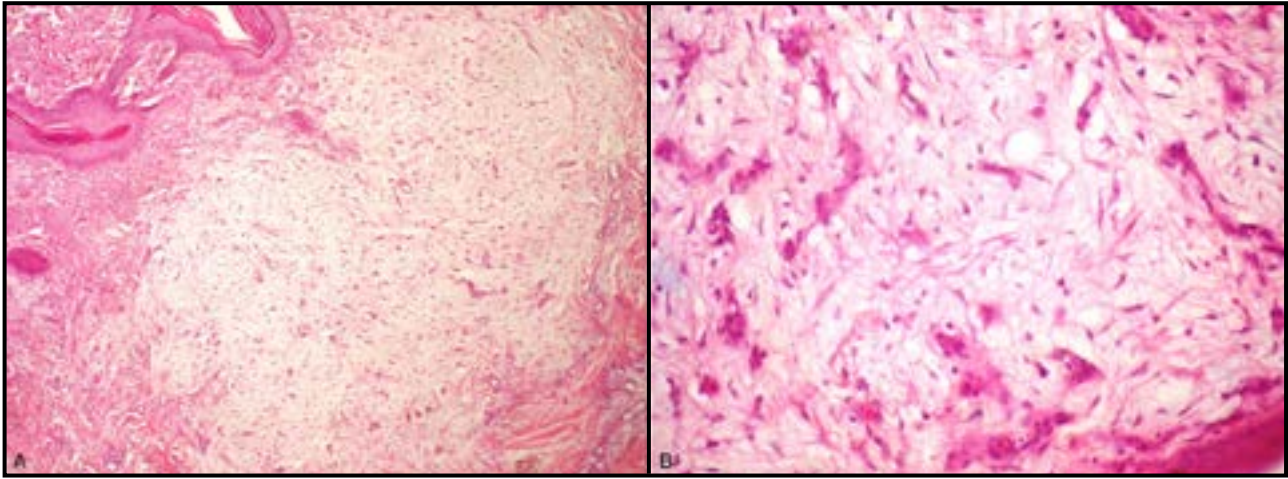
The poultry slaughterhouse was under the authority of the Federal Inspection Service (SIF) and was located in Lajeado (Rio Grande do Sul, Brazil). The slaughterhouse has a capacity for the daily slaughter of approximately 178,000 broilers. During *ante mortem* inspection at the poultry slaughterhouse, nodular lesions or encrusted areas with yellow and black areas were observed in the head skin of less than 1% of the animals (Figure 1). These lesions were approximately 0.5 cm in diameter and were observed on the comb, periocular skin region, and close to the animals' nostrils. Broilers also showed mild subcutaneous swelling of the combs.

After *ante mortem* and *post mortem* inspections at the slaughterhouse, fragments of the lesions in the comb and periocular skin were collected and fixed in buffered 10% formalin. The material for laboratory analysis was sent to the Centro de Diagnóstico e Pesquisa em Patologia Aviária (CDPA) of the Universidade Federal do Rio Grande do Sul (UFRGS), Porto Alegre, RS, Brazil. The samples were routinely processed and stained with hematoxylin<sup>1</sup> and eosin<sup>1</sup> (HE) and Alcian blue<sup>2</sup>.

Microscopically, the lesions consisted of irregular multifocal proliferation of connective tissue showing spindle cells with poorly demarcated borders and scarce cytoplasm in a slightly basophilic myxoid aspect matrix (Figure 2). The adjacent epidermis was compressed by neoplastic proliferation. No areas of epithelial hyperplasia or inclusion bodies were observed. The scabs were characterized by amorphous eosinophilic material containing inflammatory cells (heterophils and lymphocytes), bacterial basophilic



**Figure 1.** Macroscopic lesions of a cutaneous myxoma in a 42-day-old broiler. Numerous nodular proliferative lesions on the comb, periocular skin region, and on the nostrils of the bird.



**Figure 2.** Microscopic lesions of a cutaneous myxoma in a 42-day-old broiler (H&E). Multifocal proliferation of connective tissue showing spindle cells with poorly demarcated borders and scarce cytoplasm contained in a slightly basophilic myxoid aspect matrix. [A- Obj.10x & B- Obj.40x].

lumps, and fragments of plant material from the breeding environment. The extracellular matrix was positive for Alcian blue staining (Figure 3). The diagnosis of myxoma was confirmed based on macroscopic and microscopic findings.

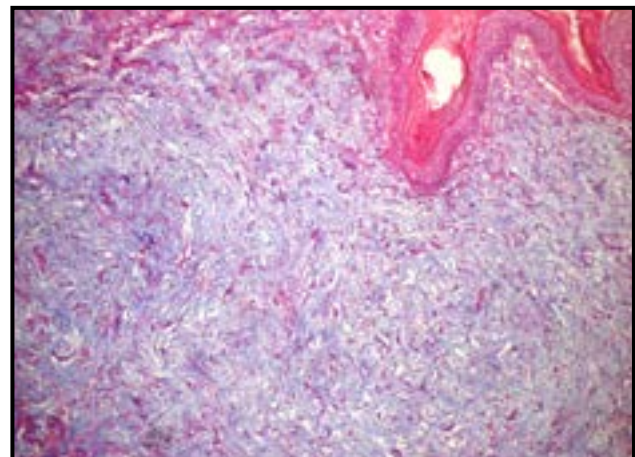
### DISCUSSION

In general, connective tissue tumors occur considerably less frequently under field conditions, and their incidence in chickens is probably less than one in 1,000 [14]. Myxomas are reported to be extremely rare in birds [18], occurring naturally at a frequency that varies between 1.2% in poultry and 2.1% in diverse wild bird species [6,10,16]. In addition, these rare neoplasms are more frequent in mature birds [18] and are not usually described in broilers, as observed in this report. It is important to emphasize that broilers are usually slaughtered at six weeks of age, and tumors, regardless of origin, are less frequent at this age.

Gross lesions of cutaneous myxomas are characterized by single nodules with soft masses [2,18]. In the present case, nodular proliferative lesions were also associated with encrusted areas. According to the pathologic description and considering the descriptive epidemiology, including flock age and disease incidence, the main clinical suspicion was the cutaneous form of fowl pox, characterized by the appearance of nodules in regions devoid of feathers that form large masses that may obstruct eyesight or the opening of the beak [11]. The histological diagnosis of fowl pox is based on the presence of typical large intracytoplasmic eosinophilic inclusion bodies [7,8]. However, the microscopic changes observed in our case were consistent with those

described in cases of myxoma. Pathological findings are similar to those reported in other studies, which also describe neoplasms in the spleen, kidney, hind limbs, and thoracic cavity [2,10,18]. In addition, the main histologic findings which differentiate cutaneous myxoma from other connective tissue neoplasms, especially fibroma, is the appearance of a benign fibrous histiocytoma with mucinous stroma [3].

The etiology of myxomas is unknown, and approximately one-third recur locally; however, there have been no reports of metastases [1]. In some species, myxomas have been associated with different factors such as local trauma, foreign bodies, parasites, and other causes [10]. In the present report, some fragments of plant material from the breeding environment were detected in the encrusted areas, which may indicate previous local trauma.



**Figure 3.** Extracellular matrix positive for Alcian Blue (10x), an indicator of myxoma.

Myxoma or myxosarcoma etiology in chickens has been associated with avian leukosis virus (ALV) subgroup A in some studies [13,17]. Subgroups of ALV in the family *Retroviridae* cause a variety of benign and malignant neoplasms in chickens, such as leukosis and, rarely, connective tissue tumors [12]. Nevertheless, neoplasms caused by ALV are usually observed in many chickens in the suspected flock, and as a congenital or genetic disease, animals from another farm originating from the same lot of breeder hens may also be affected [13]. In the present case, SIF did not report the same macroscopic lesions in other flocks of the same breeder hen's origin. Furthermore, sporadic connective tissue tumors associated

with the virus occur in mature chickens but not in broilers [12].

Finally, cutaneous myxoma in broilers is usually a sporadic neoplasm that does not cause zootechnical losses, as observed in the present case report. This neoplastic lesion should be considered in the differential diagnosis of other connective tissue tumors and infectious agents that cause lesions in the skin and subcutaneous tissue.

#### MANUFACTURERS

<sup>1</sup>Êxodo Científica. Sumaré, SP, Brazil.

<sup>2</sup>Dinâmica Química. Diadema, SP, Brazil.

**Declaration of interest.** The authors report no conflicts of interest. The authors alone are responsible for the content and writing of paper.

## REFERENCES

- 1 **Allen P.W. 2000.** Myxoma is not a single entity: A review of the concept of myxoma. *Annals of Diagnostic Pathology*. 4(2): 99-123.
- 2 **Blume G.R., Pereira F.M.A.M., Reis J.L. & Sant'Ana F.J.F. 2015.** Cutaneous myxoma in a pintagol (*Sporagra magellanica* X *Serinus canaria*). *Ciência Rural*. 45(9): 1641-1643.
- 3 **Calonje E., Lazar A.J. & Luzar B. 2020.** Miscellaneous Tumors of Uncertain Differentiation. In: Calonje E., Lazar A.J. & Luzar B. (Eds). *Diagnostic Atlas of Cutaneous Mesenchymal Neoplasia*. Amsterdam: Elsevier, pp.539-603.
- 4 **Campbell M.D. & Gelberg H.B. 2000.** Endocardial ossifying myxoma of the right atrium in a cat. *Veterinary Pathology*. 37(5): 460-462.
- 5 **Craig L.E., Krimer P.M. & Cooley A.J. 2010.** Canine Synovial Myxoma: 39 Cases. *Veterinary Pathology*. 47(5): 931-936.
- 6 **Ertürk E. & Pamukçu A.M. 1974.** Neoplastic and nonneoplastic poultry diseases seen in the District of Ankara in the period of 1933–1974. *Ankara Üniversitesi Veteriner Fakültesi Dergisi*. 21: 13-20.
- 7 **Fallavena L.C., Canal C.W., Salle C.T.P., Moraes H.L.S., Rocha S.L.S., Pereira R.A. & Silva A.B. 2002.** Presence of avipoxvirus DNA in avian dermal squamous cell carcinoma. *Avian Pathology*. 31(3): 241-246.
- 8 **Folpe A.L. 2020.** Tumors of Miscellaneous Type or Uncertain Lineage. In: Folpe A.L. & Inwards C.Y. (Eds). *Bone and Soft Tissue Pathology*. Philadelphia: Churchill Livingstone Elsevier, pp.276-305.
- 9 **Goldschmidt M.H. & Hendrick M.J. 2002.** Tumors of the skin and soft tissues. In: Meuten D.J. (Ed). *Tumors in Domestic Animals*. 4th edn. Ames: Iowa State University, pp. 45-117.
- 10 **Henríquez A., Loyola M. & Leichtle J. 2019.** Subcutaneous myxomas in kelp gulls (*Larus dominicanus*) in Chile. *Journal of Wildlife Diseases*. 55(1): 270-272.
- 11 **Murer L., Westenhofen M., Kommers G., Furian T.Q., Borges K.A., Kunert Filho H.C., Streck A.F. & Lovato M. 2018.** Identification and phylogenetic analysis of clade C Avipoxvirus in a fowlpox outbreak in exotic psittacines in southern Brazil. *Journal of Veterinary Diagnostic Investigation*. 30(6): 946-950.
- 12 **Nair V. & Fadly A.M. 2013.** Leukosis/Sarcoma Group. In: Swayne D.E., Glisson J.R., McDougald L.R., Nolan L.K., Suarez D.L. & Nair V. (Eds). *Diseases of Poultry*. 13th edn. Hoboken: Wiley-Blackwell, pp.513-673.
- 13 **Ono M., Tsukamoto K., Tanimura N., Haritani M., Kimura K.M., Suzuki G., Okuda Y. & Sato S. 2004.** An epizootic of subcutaneous tumors associated with subgroup A avian leukosis/sarcoma virus in young layer chickens. *Avian Diseases*. 48(4): 940-946.
- 14 **Okamoto S., Hisaoka M., Meis-Kindblom J.M., Kindblom L.G. & Hashimoto H. 2002.** Juxta-articular myxoma and intramuscular myxoma are two distinct entities. *Virchows Archiv*. 440(1): 12-15.
- 15 **Pinto M.H.B, Blume G.R., Medeiros J.T., Bilego U.O. & Sant'Ana F.J.F. 2018.** Mixoma oral em um bovino. *Acta Scientiae Veterinariae*. 46: 328. 4p.

- 16 Reece R.L. 1992.** Observations on naturally occurring neoplasms in birds in the state of Victoria, Australia. *Avian Pathology*. 21(1): 3-32.
- 17 Williams S.M., Barbosa T., Hafner S. & Zavala G. 2010.** Myxosarcomas associated with avian leucosis virus subgroup A infection in fancy breed chickens. *Avian Diseases*. 54(4): 1319-1322.
- 18 Yaman I., Durgun T. & Karabulut E. 2004.** Case report of a myxoma in a gamecock. *Veterinarni Medicina - Czech Academy of Agricultural Sciences*. 49(7): 268-270.