

ORIGINAL ARTICLE

# Curved canal morphological changes after over instrumentation and apical foramen shaping with R-Pilot<sup>®</sup>, ProDesign Logic<sup>®</sup> and ProGlider<sup>®</sup>

## ABSTRACT

**Aim:** To evaluate the apical canal morphological change, centering ability, and apical transportation of curved canals after foraminal enlargement 1 mm beyond the apex with different instruments and after apical foramen shaping.

**Methodology:** Thirty-three mesiobuccal molars' canals with curvatures between 25 and 35 and a radius of less than 10 mm were selected and divided according to the instrument used 1 mm beyond the apical foramen: R-Pilot #12.5/.04(RPG), ProDesign Logic #25/.01(PDG), and ProGlider #16/.02(PGG). After over instrumentation, #25/.05 ProDesign Logic prepared the canals until the apical foramen. Micro-CT scans obtained before instrumentation (time point 1), after instruments use 1 mm beyond foramen (time point 2) and after final preparation (time point 3) were used to evaluate apical canal morphological changes according to the area, the ratio of Feret's diameters and circularity, transportation and centering. Data were analyzed by parametrical or non-parametrical tests ( $\alpha=0.05$ ).

**Results:** PDG increased the apical foramen area from time point 1 to 3 ( $P=0.03$ ). There were no differences in the ratio of Feret's diameters or circularity ( $P>.05$ ). In all groups, apical transportation was in mesial direction and increased after final preparation in RPG ( $P=0.01$ ). Instrument centering ability was better at time point 3 than 2 in PDG ( $P=0.01$ ), and PDG presented better centering than RPG at time point 3 ( $P=0.02$ ).

**Conclusion:** Instruments used 1 mm beyond the apical foramen combined with #25/.05 final preparation did not lead to apical canal morphological change. ProDesign Logic #25/.01 followed by #25/.05 improved centering without increasing transportation in root canals.

Eduardo Ourique Rotta  
Natália Jardim De Lamare  
Carolina Bender Hoppe  
Patrícia Maria Poli Kopper  
Tiago André Fontoura de Melo  
Fabiana Soares Grecca\*

Federal University of Rio Grande do Sul, Dentistry College, Department of Conservative Dentistry, Porto Alegre, RS, Brazil

Received 2022, April 12

Accepted 2022, August 30

**KEYWORDS** Apical foramen, endodontics, root canal, root canal preparation

### Corresponding Author

Fabiana Soares Grecca | Federal University of Rio Grande do Sul, Dentistry College, Department of Conservative Dentistry, Rua Ramiro Barcelos, 2492 Bairro Santana CEP 90035-003, Porto Alegre, RS | Brazil  
E-mail: [fabiana.grecca@ufrgs.br](mailto:fabiana.grecca@ufrgs.br), Phone: +55 (51) 3308-5430

Peer review under responsibility of Società Italiana di Endodonzia

[10.32067/GIE.2022.36.02.06](https://doi.org/10.32067/GIE.2022.36.02.06)

Società Italiana di Endodonzia. Production and hosting by Ariesdue. This is an open access article under the CC BY-NC-ND license (<http://creativecommons.org/licenses/by-nc-nd/4.0/>).



## Introduction

**C**leaning and shaping curved root canals remains a challenge during endodontic treatments. Successful treatment is linked to numerous factors, such as the correct instrumentation and debridement of the canal and the preservation of its original anatomical trajectory (1).

The ideal limit of canal therapy in teeth with vital pulp or infected canals is controversial. Extended root canal preparation techniques, by over instrumentation with or without enlarging the foramina are being investigated (2, 3, 4). This maneuver could promote a more efficient mechanical debridement and disinfection (5) apart from favoring repair, mainly in cases of apical periodontitis (6). However, one of the major concerns regarding apical foramen enlargement is the possibility of postoperative pain. Studies suggested that apical enlargement and non-enlargement techniques resulted in the same response for postoperative pain (7, 8). On the other hand, the effects of over instrumentation with NiTi rotary systems on foramen might promote morphological changes of the apical foramen, especially when curved canals are cleaned.

Reciprocating and continuous rotary systems to realize this maneuver are available, with different designs, structures, and materials manufactured using different heat treatments. ProGlider® rotary files (Dentsply/Maillefer Instruments S.A., Ballaigues, Switzerland), manufactured from M-wire, have a square cross-section, tip size 16 and taper .02 to .08. ProDesign Logic® (Easy Dental Equipment, Belo Horizonte, Brazil), also continuous rotary files, are manufactured from the CM alloy and have a helix-shaped cross-section, tip size 25, and continuous taper .01. The reciprocating systems available on the market include the M-wire R-Pilot® (VDW, Munich, Germany) files, which have an S-shaped cross-section, a tip size 12.5, and a continuous taper .04.

This study evaluated the apical canal

morphological change, centering ability, and apical transportation of curved canals after foraminal enlargement 1mm beyond the apex with different instruments and after apical foramen shaping by means of micro-computed tomography images. The null hypothesis was that the use of different instruments 1 mm beyond the apical foramen and apical foramen shaping will not lead anatomical changes in the root canal.

## Methodology

This study was approved by the Research Committee of the School of Dentistry of the Federal University of Rio Grande do Sul (UFRGS), Brazil, and by the Research Ethics Committee of the same institution (protocol CAAE 78641417.7.0000.5347).

### *Sample selection*


Extracted human permanent maxillary molars with fully formed roots and no history of endodontic treatment were included in the study. Mesio Buccal root canal curvature was determined according to the degree (9) and radius (10) of canal curvature. Curvatures between 25° and 35° degrees and a radius of less than 10 mm were selected. After examination of the teeth under micro-computed tomography (Micro-CT) (time point 1), only those whose mesio Buccal canals had an apical foramen diameter of 100 to 150 µm were included (n=33).

Sample size calculation was performed in G\*Power 3.1.4 (G\*Power 3.1 for Macintosh; Heinrich Heine, Universität Düsseldorf, Dusseldorf, Germany), an effect size of 0.1 was estimated, and power of 80%, into a one-way ANOVA procedure.

The selected teeth were distributed randomly into three groups according to the instrument used (n=11) (Table 1). The samples were stored in distilled water during all experimental period.

### *Endodontic procedures*

Spherical diamond tip (1012, KG Sorensen, Barueri, Brazil) accessed the cavities and Endo Z tip (Dentsply/Maillefer) completely removed the pulp chamber



**Figure 1**  
Images illustrating the boundary of the apical foramen anatomical changes after the use of instruments 1mm beyond foramen (time point 2) and final preparation (time point 3) in comparison with baseline images (time point 1).

roof. The mesiobuccal canals were explored using a #08 K-type file (Dentsply/Maillefer) until its tip reached the foramen. The length measured on this file was defined as the working length (WL), on the anatomical apex.

After that, the samples were randomly distributed in one of the experimental groups, according to the instrumented used to instrument the canal 1 mm beyond the WL:

- RPG: #12.5/04 R-Pilot® in reciprocating motion;

- PDG: #25/01 ProDesign Logic® in rotary motion at 350 rpm and torque of 1N;

- PGG: #16/02 ProGlider® in rotary motion at 300 rpm and torque of 2N.

Next, a #25/05 ProDesign Logic® in rotary motion at 950 rpm and torque of 4N prepared the entire length canals (WL), until the apical foramen (final preparation). All files were used in an endodontic VDW Silver engine (VDW, Munich, Germany), operated with a 16:1 contra-angle, with a slow, in-and-out pecking motion, according to the manufacturer's instructions. When the instrument reached the WL, it was removed from the canal. The same trained operator performed all endodontic procedures. Each set of files was used to prepare four canals. At each instrument change, canals were irrigated with 2 mL of 2.5% sodium hypochlorite (Iodontosul - Industrial Odontológica do Sul LTDA, Porto Alegre, Brazil), using a conventional disposable syringe and a 29-gauge side-vented Endo-Eze irrigation needle (Ultradent,

South Jordan, UT).

*Micro-computed tomography (micro-CT)*  
Images were acquired using a SKYSCAN (Bruker Micro-CT, Kontich, Belgium) scanner at 70 kV, 100 mA, 13.3 mm FOV (XY), 7.0 mm FOV (Z) and 0.013 mm/Pix voxel size.

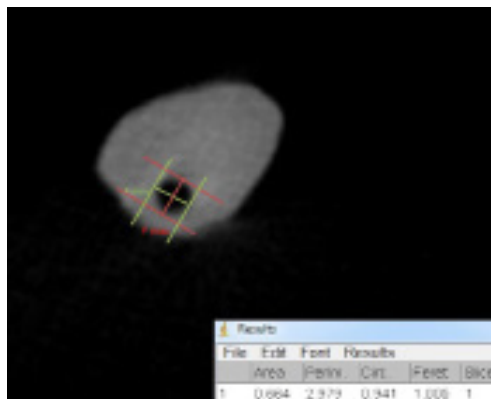
Teeth were scanned at three time points: 1-before instrumentation, 2-after the use of instruments 1 mm beyond foramen, and 3-after final preparation. A support model made from Express™ XT Putty Soft (3M ESPE, St. Paul, MN) addition silicone was used to standardize the individual positioning of each tooth for micro-CT scanning. Reconstructed axial slices (2D) were visualized using the DataViewer software (Extron, Anaheim, CA), which was used to process images for matching and cutting plane selection. The apical third was analyzed by one blinded and trained evaluator. The root canal section orthogonal to the canal axis was defined on the first apical section where the apical foramen was visible. The number used to identify the position of the selected section was the same at the three time points.

*Analysis of area, ratio of Feret's diameters and circularity of the apical foramen*

Image J software (National Institute of Health, Bethesda, MD) calculated area, ratio of Feret's diameters and circularity of the apical foramen at the three time points. The boundary of the apical foramen of each specimen was traced ma-

**Figure 2**

The maximum (Fmax) and minimum (Fmin) Feret's diameters are defined as the furthest and shortest distances, respectively, between two parallel tangents on the boundary of a shape.



nually using the Draw tool (Figure 1). The area, circularity, and Feret's diameters were calculated using the Set Measurements tool. Circularity was determined based on a perfect circle, which tends towards 1.0, in contrast with a straight line, which is 0.0. Feret's diameters were defined as the longest distance between two parallel straight lines that are tangent to the shape. Ratio of Feret's diameters was calculated as the ratio of maximum to minimum Feret's diameters (Figure 2).

*Analysis of apical transportation and centering*

Apical transportation and centering ability were analyzed in a linear mesiodistal direction using Adobe Photoshop software CS6 (v. 13.0x32, Adobe Systems, San Jose, CA). Transportation and centering were evaluated after instrumentation 1 mm beyond foramen, comparing the images at time points 1 and 2; and after final preparation, comparing the images at time points 2 and 3 (Figure 3). Apical

transportation was calculated as follows:

$$(X1-X2) - (Y1-Y2)$$

where X1 was the shortest distance from the distal portion of the root to the periphery of the unprepared canal; X2, the shortest distance from the distal portion of the root to the periphery of the prepared canal; Y1, the shortest distance from the mesial portion of the root to the periphery of the unprepared canal; and Y2, the shortest distance from the mesial portion of the root to the periphery of the prepared canal.

A result of zero indicated no canal transportation; a positive result indicated transportation toward the distal region; and a negative result indicated transportation toward the mesial region (11).

Centering was calculated using the following formula:

$$(X1-X2)/(Y1-Y2) \text{ or } (Y1-Y2)/(X1-X2)$$

The numerator of the formula was the lowest number found when the values were unequal. A value close to 1 indicated a better centering, and a value close to 0, a poorer centering (11).


*Statistical analysis*

The Shapiro Wilk test evaluated data normality.

Repeated-measures analysis of variance (ANOVA), followed by the Tukey test for multiple comparisons, compared the area and ratio of Feret's diameters at the three time points in the same group. One-way ANOVA compared different groups at the same time point. As circularity data did not have a normal distribution, time points in the same group were com-

**Table 1**  
**Test groups and treatment time points**

Groups	n	Time point of analysis under micro-CT according to file used		
		Time point 1	Time point 2	Time point 3
R-Pilot® (RPG)	11	Without endodontic preparation	After the use of RPG	Final Preparation (#25/.05 ProDesign Logic)
ProDesign Logic® (PDG)	11	Without endodontic preparation	After the use of PDG	Final Preparation (#25/.05 ProDesign Logic)
ProGlider® (PGG)	11	Without endodontic preparation	After the use of PGG	Final Preparation (#25/.05 ProDesign Logic)



**Figure 3**  
Time Point 1, 2 and 3 micro-CT images for determination of canal transportation and centering ratio. X1=shortest distance from the distal portion of the root to the periphery of the unprepared canal; X2= shortest distance from the distal portion of the root to the periphery of the prepared canal; Y1shortest distance from the mesial portion of the root to the periphery of the unprepared canal; and Y2=shortest distance from the mesial portion of the root to the periphery of the prepared canal.

pared using the Friedman non-parametric test, and the Kruskal-Wallis compared groups at the same time point. The data about apical transportation and centering at the same time point were compared between groups using one-way ANOVA, and data for the same group at time points 2 and 3 by dependent t test. The level of significance was set at 5% ( $P \leq 0.05$ ). GraphPad Prism 7 software (GraphPad Software Inc., San Diego, CA) performed statistical analyses.

**Results**

Although there was an increase in apical foramen area from time point 1 to 3 in all

groups, this increase was significant only in PDG from time point 1 (before preparation) to time point 3 (after final preparation) ( $P=0.03$ ). Apical foramen ratio of Feret's diameters and circularity were similar at the three time points for all groups ( $P > 0.05$ ). The comparison of foramen area, ratio of Feret's diameters and circularity between groups at the same time point revealed no significant differences ( $P > 0.05$ ) (Table 2).

Table 3 shows data about apical transportation and centering. There was a tendency to transportation in the mesial direction of the canal after over instrumentation and final preparation in all groups. There were no significant differences

**Table 2**  
Mean and standard deviation ( $\pm$ ) of root canal area ( $\text{mm}^2$ ), ratio of Feret's diameters ( $\text{mm}/\text{mm}$ ) and median value (maximum value; minimum value) of canal circularity ( $\text{mm}^2/\text{mm}^2$ ) in the test groups at time points 1 (no preparation), 2 (after the use of instruments 1mm beyond foramen) and 3 (after final preparation) ( $p > 0.05$ )

		RPG	PDG	PGG
Area	Time point 1	0.52 $\pm$ 0.37	0.46 $\pm$ 0.24 <sup>a</sup>	0.51 $\pm$ 0.29
	Time point 2	0.71 $\pm$ 0.31	0.66 $\pm$ 0.26 <sup>ab</sup>	0.63 $\pm$ 0.36
	Time point 3	0.92 $\pm$ 0.39	0.83 $\pm$ 0.26 <sup>b</sup>	0.81 $\pm$ 0.27
Ratio of Feret's diameters	Time point 1	0.51 $\pm$ 0.29	0.72 $\pm$ 0.16	1.19 $\pm$ 0.44
	Time point 2	0.63 $\pm$ 0.36	0.75 $\pm$ 0.14	1.23 $\pm$ 0.45
	Time point 3	0.81 $\pm$ 0.27	0.78 $\pm$ 0.12	1.31 $\pm$ 0.38
Circularity	Time point 1	0.82 (0.93; 0.44)	0.84 (0.94; 0.43)	0.74 (0.90; 0.53)
	Time point 2	0.82 (0.93; 0.47)	0.88 (0.94; 0.52)	0.74 (0.92; 0.54)
	Time point 3	0.85 (0.93; 0.51)	0.87 (0.98; 0.47)	0.78 (0.93; 0.57)

\*Different lowercase letters indicate significant differences in the same column ( $P < 0.05$ )



Table 3

Mean and standard deviation ( $\pm$ ) of apical transportation (mm) and centering (mm) in the test groups after the use of instruments 1 mm beyond foramen (time point 2) and final preparation (time point 3)

		RPG	PDG	PGG	P value
Apical transportation	Time point 2	-0.27 <sup>a</sup> $\pm$ 0.18	-0.57 <sup>a</sup> $\pm$ 0.36	-0.25 <sup>a</sup> $\pm$ 0.27	
	Time point 3	-0.89 <sup>b</sup> $\pm$ 0.61	-0.44 <sup>a</sup> $\pm$ 0.31	-1.04 <sup>b</sup> $\pm$ 1.04	
P value		0.01			
Centering ability	Time point 2	0.27 <sup>a</sup> $\pm$ 0.33	0.05 <sup>a</sup> $\pm$ 0.17	0.25 <sup>a</sup> $\pm$ 0.24	
	Time point 3	0.10 <sup>aA</sup> $\pm$ 0.15	0.52 <sup>bB</sup> $\pm$ 0.34	0.22 <sup>aAB</sup> $\pm$ 0.22	0.02
P value			0.01		

\*Different lowercase letters indicate significant differences in the same column ( $P < .05$ )

\*Different uppercase letters indicate significant differences in the same line ( $P < .05$ )

between groups at the same time point ( $P > .05$ ), and transportation increased significantly after final preparation in RPG ( $P = 0.01$ ). Instrument centering ability was significantly better at time point 3 than at time point 2 in PDG ( $P = 0.01$ ), and PDG presented significantly better centering than RPG at the time point 3 ( $P = 0.02$ ).

### Discussion

Preserve the original shape of the canal after instrumentation is associated with better endodontic treatment results (1). This study analyzed the shaping ability of three types instruments used for instrumentation 1 mm beyond the apical foramen followed by final preparation to entire canal length, that is, to the apical foramen, using a #25/.05 rotary file. There was an increase in apical foramen area in PDG from time point 1 to 3, the transportation increased significantly after final preparation in RPG and PGG, and PDG improved centering ability after final preparation, rejecting the null hypothesis. The use of a file with a caliber smaller than that of the apical foramen may not clean the canal efficiently. Correct foraminal enlargement is achieved using larger instruments. When the canal is instrumented past the apical foramen, there is a better bacterial removal, which promotes

healing (5). Foraminal enlargement creates conditions for the growth of connective tissue in the space of the unfilled apical portion during the repair process (12). However, enlargement may promote apical morphological changes, especially in curved canals, and lead to unsatisfactory filling (13). The present study showed that even with foraminal enlargement in all groups, the foramen circularity was maintained.

Each instrument analyzed has a distinct cross-section, taper and tip diameter. ProDesign Logic® has a double helix cross-section, tip #25 and taper .01 (14); ProGlider® has a square cross-section, #16 tip and a variable taper, beginning at .02 in the first millimeter (15); and, R-Pilot® has an S-shaped cross-section, #12.5 tip and taper .04 (16). Therefore, as we performed an overlap of 1 mm during root canal preparation, the resulting foraminal diameter when using ProDesign Logic®, ProGlider® and R-Pilot® were #18, #16.5 and #26, respectively. Regarding apical enlargement, R-Pilot®, ProDesign Logic®, and ProGlider® did not change the circularity and ratio of Feret's diameters after use, thus preserved the foramen anatomical features. After final preparation using #25/.05 file, few changes from circular to oval shape were observed in all groups, although they had increased the foraminal surface area. Similar results were observed



using Reciproc Blue R25 in the apical foramen and beyond the apex (17), and using Reciproc Blue R25 and XP-endo Shaper at the apical foramen limit (18). The foramen ovalization has been reported following canal over instrumentation. The major foramen was photographed before and after over instrumentation with ProTaper Universal and ProFile Vortex, resulting in changes in the original position of the foramen (4). Using a digital microscope for analyses, foramen deformation was observed after using Reciproc (#25/.08), WaveOne (#25/.08), and ProDesign R (#25/.06) in two different working lengths, 0.00 mm and 1.0 mm beyond the foramen (3). Even, after the use of #25/.08 files, 1 mm beyond the foramen (19). Our results may be correlated with prior instrumentation with small diameter and taper instruments 1 mm beyond the foramen.

As previously observed, the analysis of canal transportation revealed that all tested files led to transportation towards the external (mesial) wall in the apical third (4, 20). Transportation in this direction might be explained by the fact that the distal wall pushes the file, particularly if the file has a larger taper, in a direction against the mesial wall, opposed to the curvature (21). Despite the absence of significant differences between groups, apical transportation was significantly greater in RPG after final preparation (time point 3). In PDG, however, transportation did not change significantly after the final preparation, which may be associated with the fact that the #25.05 ProDesign Logic® worked with a free tip at the apical foramen during final preparation. However, apical transportation becomes clinically relevant when it exceeds 300  $\mu\text{m}$  (22), which occurred in all groups after final preparation. It also was observed in PDG after the over instrumentation, which may be explained by the fact that the tip diameter of the #25.01 ProDesign Logic® files is greater than that of the other two tested instruments.

At time point 3, PDG showed better centering ability than RPG. Also in PDG

canal centering was significantly better after final preparation than after over instrumentation. As previously mentioned, at PDG the apical foramen was enlarged during the use of #25/.01 ProDesign Logic®, leaving the #25/.05 ProDesign Logic® tip work freely during final preparation, which might have contributed to our results.

However, the preservation of the original anatomical path decreases with increasing apical preparation, in this sense, the apical preparation was limited to the size 25 file in the present study, which may be a limitation of the study.

As in previous studies, the curvature degree of the mesiobuccal roots ranged from 25 to 35, and their radius was shorter than 10 mm (9, 10). These curvature degrees may be at a greater risk of canal transportation (21). Moreover, selecting only canals with apical foramen diameter measuring from 150  $\mu\text{m}$  to 200  $\mu\text{m}$  ensured that at least one of the used files would touch the foramen.

Axial sections of the canal apical third were selected for the analyses because this region is the most critical for endodontic treatment. Correct cleaning and shaping of this region are directly associated with treatment success (1). Procedural accidents, such as apical transportation, may prevent the removal of microorganisms and organic tissue from the dentin walls, compromising the disinfection and sealing of the canal system (23). Apical transportation and centering were analyzed using micro-CT images, which ensured good precision, validity, and data reproducibility (15, 24). Other methods of analysis, such as serial cuts, clearing, and scanning electron microscopy, result in structural changes. Such changes would preclude the analysis of transportation and centering at the three time points performed herein. Apical transportation was evaluated only on the mesiodistal axial sections, as the canal along this direction is narrower than in the buccopalatal direction (25).

Despite the *in vitro* study limitations, the present results highlighted that the com-

bined use of R-Pilot®, ProDesign Logic®, or ProGlider® 1mm beyond apical foramen with #25/.05 final preparation until the apical foramen did not lead apical morphological changes. ProDesign Logic® followed by a final preparation improved canal centering without increasing canal transportation.

### Clinical Relevance

The use of small caliber files beyond the apical foramen combined with final preparation until the apical foramen did not impair canal shaping.

### Conflict of Interest

The authors declare that they have no conflict of interest.

### Acknowledgments

Eduardo Ourique Rotta received funding from Coordenação de Aperfeiçoamento de Pessoal de Ensino Superior (CAPES) agency, Brazil.

### References

- 1 Sjogren U, Hagglund B, Sundqvist G, et al. Factors affecting the long-term results of endodontic treatment. *J Endod.* 1990;16:498-504.
- 2 Belladonna FG, Rodrigues LLC, Leal ASM, et al. Is canal overinstrumentation able to produce apical root dentinal microcracks in extracted teeth? *Int Endod J.* 2021;54:1647-1652.
- 3 Frota MMA, Bernardes RA, Vivan RR, et al. Debris extrusion and foraminal deformation produced by reciprocating instruments made of thermally treated NiTi wires. *J Appl Oral Sci.* 2018;26:e20170215.
- 4 González Sanchez JA, Duran-Sindreu F, de Noé S, et al. Centring ability and apical transportation after overinstrumentation with ProTaper Universal and ProFile Vortex instruments. *Int Endod J.* 2012;45:542-551.
- 5 Rodrigues RC, Zandi H, Kristoffersen AK, et al. Influence of the apical preparation size and the irrigant type on bacterial reduction in root canal-treated teeth with apical periodontitis. *J Endod.* 2017;43:1058-63.
- 6 Brandão PM, Figueiredo JAP, Morgental RD, et al. Influence of foraminal enlargement on the healing of periapical lesions in rat molars. *Clin Oral Inv.* 2019;23:1985-1991.
- 7 Silva EJNL, Menaged K, Ajuz N, et al. Postoperative pain after foraminal enlargement in anterior teeth with necrosis and apical periodontitis: a prospec-

- 8 Cruz Junior JA, Coelho MS, Kato AS, et al. The effect of foraminal enlargement of necrotic teeth with the Reciproc system on postoperative pain: a prospective and randomized clinical trial. *J Endod.* 2016;42:8-11.
- 9 Schneider SW. A comparison of canal preparations in straight and curved root canals. *Oral Surg Oral Med Oral Pathol.* 1971;32:271-5.
- 10 Schafer E, Diez C, Hoppe W, et al. Roentgenographic investigation of frequency and degree of canal curvatures in human permanent teeth. *J Endod.* 2002;28:211-6.
- 11 Gambill JM, Alder M, del Rio CE. Comparison of nickel-titanium and stainless steel hand-file instrumentation using computed tomography. *J Endod.* 1996;22:369-75.
- 12 Benatti O, Valdrighi L, Biral R R, et al. A histological study of the effect of diameter enlargement of the apical portion of the root canal. *J Endod.* 1985;11:428-34.
- 13 Silva JM, Brandão GA, Leal Silva EJN, et al. Influence of working length and foraminal enlargement on foramen morphology and sealing ability. *Indian J Dent Res.* 2016;27:66-72.
- 14 Menezes SEAC, Batista SM, Lira JOP, et al. Cyclic fatigue resistance of WaveOne Gold, ProDesign R and ProDesign Logic files in curved canals in vitro. *Iranian E J.* 2017;12:468-7.
- 15 Alovisi M, Cemenasco A, Mancini L, et al. Micro-CT evaluation of several glide path techniques and ProTaper Next shaping outcomes in maxillary first molar curved canals. *Int Endod J.* 2017;50:387-397.
- 16 Uslu G, Özyürek T, Yilmaz K, et al. Cyclic fatigue resistance of R-Pilot, HyFlex EDM and PathFile nickel-titanium glide path files in artificial canals with double (S-shaped) curvature. *Int Endod J.* 2018;51:584-89.
- 17 Vieira MLO, Dantas HV, Sousa FD, et al. Morphological changes of apical foramen and microcracks formation after foraminal enlargement: a scanning electron microscopy and micro-computed tomography analysis. *J Endod.* 2020;46:1726-32.
- 18 Daou C, El Hachem R, Naaman A, et al. Effect of 2 heat-treated nickel-titanium files on enlargement and deformation of the apical foramen in curved canals: a scanning electronic microscopic study. *J Endod.* 2020;46:1478-1484.
- 19 Silva Santos AM, Portela FMSF, Coelho MS, et al. Foraminal Deformation after Foraminal Enlargement with Rotary and Reciprocating Kinematics: A Scanning Electronic Microscopy Study. *J Endod.* 2018;44:145-48.
- 20 Carvalho GM, Sponchiado Junior EC, Garrido AD, et al. Apical transportation, centering ability, and cleaning effectiveness of reciprocating single-file system associated with different glide path techniques. *J Endod.* 2015;41:2045-9.
- 21 Gergi R, Osta N, Bourbouze G, et al. Effects of three nickel titanium instrument systems on root canal geometry assessed by micro-computed tomography. *Int Endod J.* 2015;48:162-70.
- 22 Fan B, Wu MK, Wesselink PR. Leakage along warm gutta-percha fillings in the apical canals of curved roots. *Endod Dent Traumatol.* 2000;16:29-33.





- 23 Wu MK, Fan B, Wesselink PR. Leakage along apical root fillings in curved canals. Part I. Effects of apical transportation on seal of root fillings. *J Endod.* 2000a;26:210-6.
- 24 Balto K, Mueller R, Carrington DC, et al. Quantification of periapical bone destruction in mice by micro-computed tomography. *J Den Res.* 2000;79:35-40.
- 25 Wu MK, R'oris A, Barkis D, et al. Prevalence and extent of long oval canals in the apical third. *Oral Surg Oral Med Oral Pathol Oral Radiol Endod.* 2000;89:739-43.