



Image-guided Temporal Bone Dissection Course

Diego Sgarabotto Ribeiro¹ Geraldo Pereira Jotz² Natália Cândido de Sousa³ Enio Tadashi Setogutti⁴
Gustavo Rassier Isolan⁵ Marco Antonio Stefani^{2,6} Ricardo Ferreira Bento³ Joel Lavinsky^{2,6,7}

¹Radiologist and Researcher in Porto Alegre, RS, Brazil

²Department of Morphological Sciences, Institute of Basic Health Sciences, Universidade Federal do Rio Grande do Sul, Porto Alegre, RS, Brazil

³Department of Otolaryngology, Hospital das Clínicas, Faculdade de Medicina, Universidade de São Paulo, São Paulo, SP, Brazil

⁴Department of Radiology, Hospital Ernesto Dornelles, Porto Alegre, RS, Brazil

⁵Department of Neurosurgery, Centro Avançado de Neurologia e Neurocirurgia (CEANNE), Porto Alegre, RS, Brazil

⁶Postgraduate Program in Medicine: Surgical Sciences, Universidade Federal do Rio Grande do Sul, Porto Alegre, RS, Brazil

⁷Division of Otolaryngology, Clínica Lavinsky, Porto Alegre, RS, Brazil

Address for correspondence Joel Lavinsky, MD, PhD, Clínica Lavinsky, Rua Quitino Bocaiúva, 673, 4o andar, Moinhos de Vento, Porto Alegre, RS, 90440-051, Brazil (e-mail: jlavinskybr@yahoo.com).

Int Arch Otorhinolaryngol 2021;25(4):e594–e601.

Abstract

Introduction Temporal bone anatomy is complex and demands a profound anatomical knowledge. Association between surgery and imaging helps in the process of learning three-dimensional (3D) anatomy and surgical techniques. High definition temporal bone imaging can play an important role in dissection training.

Objective To describe a computed tomography (CT) image-guided temporal bone dissection course for surgical training in otolaryngology and to verify the satisfaction level of the students with the course.

Methods Descriptive research. The course took place at a research laboratory, with three experienced temporal bone surgeons. The participants were 12 otolaryngology residents. The laboratory has 7 modern workstations with microscope and monitors linked with a computerized video system. Cadaveric temporal bones were donated to the university. Imaging acquisition of the cadaveric temporal bones used in the course was performed in a multislice CT scanner. The CT images of cadaveric temporal bones were available with real-time access on the laboratory monitor's screens during dissections.

Results A total of 13 temporal bones were included for dissection. Students had the opportunity to view on the same screen, simultaneously, both the dissection video and the respective CT images of their temporal bone anatomical specimens. This allowed correlating surgical and imaging aspects of temporal bone anatomy. At the end of the course, participants answered a satisfaction survey.

Conclusion Considering imaging methods are routinely used during most otologic surgeries, detailed knowledge of CT imaging should be explored in conjunction with the temporal bone anatomical dissection.

Keywords

- temporal bone
- dissection
- anatomy
- computed tomography

received
December 28, 2019
accepted
June 5, 2020
published online
March 29, 2021

DOI <https://doi.org/10.1055/s-0040-1716573>.
ISSN 1809-9777.

© 2021. Fundação Otorrinolaringologia. All rights reserved.

This is an open access article published by Thieme under the terms of the Creative Commons Attribution-NonDerivative-NonCommercial-License, permitting copying and reproduction so long as the original work is given appropriate credit. Contents may not be used for commercial purposes, or adapted, remixed, transformed or built upon. (<https://creativecommons.org/licenses/by-nc-nd/4.0/>)

Thieme Revinter Publicações Ltda., Rua do Matoso 170, Rio de Janeiro, RJ, CEP 20270-135, Brazil

Introduction

The temporal bone anatomy is complex and requires detailed anatomical knowledge. This specific anatomical teaching and learning is performed in laboratories especially prepared for temporal bone dissection. Anatomical studying is crucial for surgical practice of otolaryngologists. Considering medical training in otorhinolaryngology, among the different skills to be developed, temporal bone surgery is considered one of the most technically challenging procedures.¹ Thus, many resources are spent in the development of training programs that can qualify a beginner surgeon and transform him into an efficient surgeon when completing a medical residency in otolaryngology.¹ In addition to a detailed comprehension of the anatomy and of dissection procedures, precise images of the temporal bone are important for diagnosis, for surgical planning and for postoperative follow-up.² Therefore, the role of high definition imaging in temporal bone dissection practice is also important, since association between surgery and imaging helps in the learning process of surgical techniques and three-dimensional (3D) anatomy.

In temporal bone surgery, using detailed imaging to plan and guide the procedure is important. Currently, multislice computed tomography (CT with multiple detector rows) is a very useful technique to accomplish both of these tasks. Usually, only reports of the use of CT imaging in cadaveric temporal bones strictly for research purposes are found in the literature. No description was found in the current literature of the use of CT imaging of cadaveric anatomical specimens as a guide in temporal bone dissection training. Therefore, the use of CT imaging to guide a temporal bone dissection course is an innovative methodology of medical training and learning. This article aims to describe an unprecedented temporal bone dissection course guided by CT imaging of the respective cadaveric anatomical specimens used during surgical training. The current article also had as an objective to verify the satisfaction level of the participants with the course.

Method

The present article is a descriptive research about a novel methodology applied to teaching ear surgery guided by computed tomography technology. Our primary aim was to describe a temporal bone dissection course guided by CT imaging (including postprocessed images with 3D reconstructions) of the respective cadaveric anatomical specimens used during surgical training. The secondary objective was to verify the satisfaction level of otolaryngology residents with the course.

Cadaver Preparation

The temporal bones used in the course originated from cadavers donated to the Institute of Basic Health Sciences, Department of Morphological Sciences, Federal University of Rio Grande do Sul (DCM/ICBS/UFRGS, respectively) in southern Brazil. These temporal bones were prepared in the anatomy laboratory by a technician (► **Fig. 1**). Cadaver heads

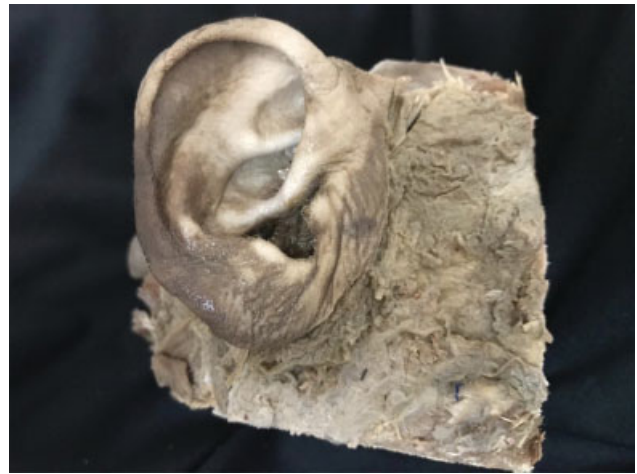

Fig. 1 Photograph of one of the cadaveric temporal bones utilized in the course.

were fixed in a 10% formalin solution. After the anatomical cuts were made and the temporal bones removed from the heads (skulls), they were kept in a conservative solution until the beginning of the dissection course. This conservative solution was composed of 10% glycerin, 5% alcohol, 10% colorless liquid disinfectant and water. All cadaveric temporal bones were donated to DCM/UFRGS through a written consent form signed by the donor or his/her family members. This consent form includes the authorization to use biological material for scientific (research) and learning purposes.

The temporal bone anatomical specimens were packed in plastic material and sealed in a thermal container for transport to the CT scanner. For course documentation purposes and CT imaging acquisition, the temporal bones were numbered and had their sides identified in plastic packages with labels. On these labels, an alphanumeric code was written to identify the temporal bones. This code was composed by grouping the number and the positioning side (laterality in the skull) of each temporal bone. For example, temporal bone number one was positioned (laterality) to the left in its skull (head) of origin; thus, this bone received the code 1L (one left); temporal bone number three was positioned to the right in its skull (head) of origin; thus, this bone received the code 3R (three right); and so on, this coding process was performed for all the temporal bones available.

Imaging Acquisition

The acquisition of CT images of cadaveric temporal bones used in the course was performed in a medical imaging/radiology clinic, located inside a large tertiary hospital in Porto Alegre, Brazil. There were no financial costs for performing temporal bone CT scans, since one of the staff radiologists at the aforementioned diagnostic imaging clinic where the images were acquired is research partners and collaborator of the authors of the current article. The CT images of 13 temporal bones specimens were acquired in a Discovery Multislice CT scanner (General Electric Company [GE], Boston, MA, USA)► **Fig. 2**, with 128 detector rows and

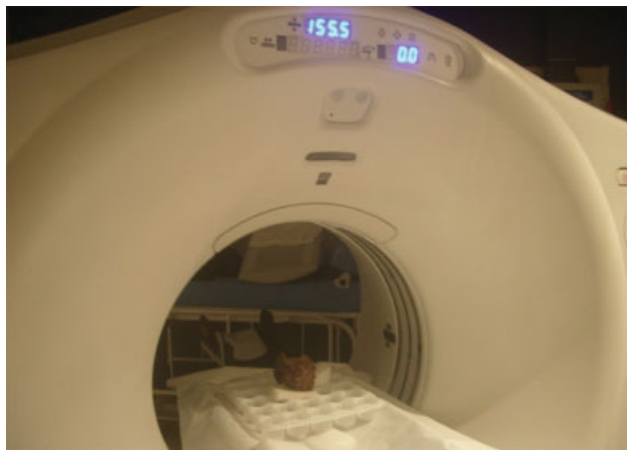


Fig. 2 Imaging acquisition of the temporal bones using a multislice CT scanner. Abbreviation: CT, computed tomography

dual-energy technology. An institutional CT protocol for temporal bone/mastoid imaging acquisition was used. The imaging acquisition session was guided and supervised by the previously mentioned staff radiologist from the tertiary hospital's imaging clinic and by a radiologist/researcher (both are authors of this current article). The following scanning parameters were used by the CT technologist who operated the equipment: multiple axial sections with slice thickness of 0.625 mm (millimeters) and interval of 0.3 mm; matrix of 512×512 pixels; field of view of 9.8–10 cm (centimeters); bone and soft tissues reconstruction algorithms; kV (kilovolts) = 120; mA (milliamperage) = 200. The images were postprocessed and reconstructed by the imaging clinic's staff radiologist using a dedicated GE workstation.

Temporal Bone Laboratory

The medical research laboratory where the course was held has 7 modern complete workstations equipped with microscopes, a computerized video system linked with monitors and all surgical material, including electric drills Shaver Mikro Macht (DMC Importação e Exportação de Equipamentos Ltda., São Carlos, SP, Brazil) and clinical aspirators Aspiramax MA520–60 (NS Medical Devices Industry Ltd., Waltham, MA, USA) – **Figs. 3** and **4**. For dissection procedures we used a OPMI VARIO S88™ (Carl Zeiss SMT GmbH, Oberkochen, Germany) microscope and 6 DF Vasconcellos MC-M22 (DF Vasconcellos S.A. [DFV], Valença, RJ, Brazil) microscopes ($f = 50$ mm). These workstations are for student use (workstations 1–6; – **Fig. 3**) and for course instructor's use (workstation 7; – **Fig. 4**).

The laboratory has 7 monitors (one Samsung 4k digital screen [Samsung Group, Seoul, South Korea]; considered the main laboratory monitor; six HP Compaq Elite 8300 [Hewlett-Packard Company, Palo Alto, CA, USA]). These last 6 monitors mentioned are part of an “all-in-one” personal computer (PC) system, allowing the CT images and temporal bone dissection to be viewed on their screens simultaneously. Photographs were taken using an Optio S57 (Pentax Corp., Tokyo, Japan) camera with 5.0 megapixels and 3.0 optical

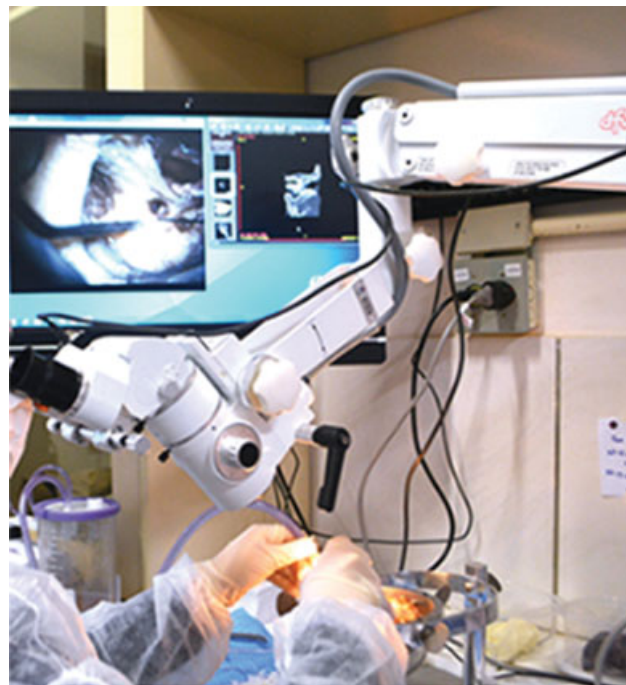

Fig. 3 Workstation with a MCM22 microscope (DF Vasconcellos Ltda.) and a computerized video system linked with a monitor. Screen shows simultaneously the video of dissection transmitted in real time from microscope next to a software window with CT images of the temporal bone being dissected. Abbreviation: CT, computed tomography



Fig. 4 Instructor's dissection workstation, equipped with a OPMI VARIO S88 microscope (Carl Zeiss SMT GmbH), surgical instruments, video system and a monitor (not shown).

zoom (5.8–14.0 mm). The laboratory also has a surgical simulator that is equipped with virtual reality (VR) 3D technology (Voxel-Man ENT Surgical Simulator 2011–2018 [Voxel-Man Group, University Medical Center Hamburg-Eppendorf, Hamburg, Germany]).

Temporal Bone Course

The first Image-Guided Temporal Bone Dissection Course took place between July 5th and 7th, 2017, at the Medical Research

Laboratory of the Department of Morphological Sciences, Institute of Basic Health Sciences, Federal University of Rio Grande do Sul (DCM/ICBS/UFRGS), in Porto Alegre, Brazil. The Fundação Otorrinolaringologia (FORL; Otolaryngology Foundation) supported the course. New editions of the course took place in 2018 and 2019, following the same methodology described. Currently, the event is in its sixth edition. Course participants were 12 otolaryngology residents (3rd year of training) from different medical residency programs of the state of Rio Grande do Sul. To be eligible to attend the course, the resident must have basic knowledge about temporal bone anatomy through CT scan images. For enrollment in the course, no fees were charged. Residents participating in the course were nominated by their respective otolaryngology training programs. Most otolaryngology residency programs have seminars on temporal bone imaging diagnosis (including radiology), and their residents have sufficient knowledge of temporal bone anatomy in computed tomography (CT) images.

The course instructors were three experienced temporal bone (otologic) surgeons. During the course, regarding techniques of temporal bone dissection, different approaches and steps were used. A printed temporal bone dissection manual,³ which includes colored images demonstrating various techniques and stages of dissection, was available. In total, there were 13 temporal bones, one for the teacher and 12 for the residents. As previously commented, there were 7 workstations, being one exclusive for the instructor and the other 6 for the students (residents). Since there were 12 students, each workstation received two residents. Simultaneously, on these same monitor screens where dissection procedure was being transmitted in real-time from microscopes, CT images of dissected temporal bones were available for visualization in a software (RadiAnt DICOM Viewer, v.4.0.2 for Windows, Medixant, Poznan, Poland). This software allows students to scroll through the CT images (axial slices) and also performs reformatting in multiple planes and other postprocessing techniques (such as 3D reconstruction, for example). At the beginning of the course, an additional monitor (another Samsung 4k digital screen) was installed in the laboratory. This extra monitor was placed adjacent to the main monitor (used to transmit the instructor's dissection in real time) and was dedicated exclusively to project CT images of the temporal bone that was being dissected by the course instructors. During the course, adjacent to this video monitor dedicated to projecting CT images, a workstation containing the above-mentioned 3D surgical simulator is positioned. This virtual reality (VR) simulator is available to students and teachers for training in temporal bone surgery.

Throughout the course, the previously mentioned radiologist/researcher was present in the laboratory and available to help students with CT imaging interpretation. The temporal bone CT images were viewed and, when necessary, once again reconstructed in 3D and reformatted in multiple planes using an OsiriX v.5.5.2; 32-bit (Pixmeo SARL, Geneva, Switzerland) software in a MacBook Pro Intel Core i5; 2.4 Ghz; 4 Gb RAM, 13" (Apple Inc., Cupertino, CA, USA) with OS X Yosemite v. 10.10.5 (Apple Inc.). Therefore, using this software during the course, the radiologist/researcher present was able to carry out

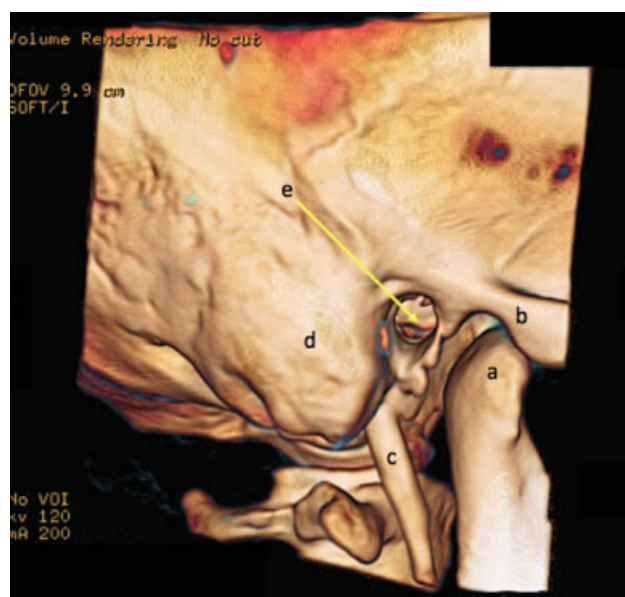


Fig. 5 CT imaging reconstruction (postprocessing) using 3D volume rendering technique; lateral view, demonstrating the mandibular condyle (a; also called condylar process of the mandible); zygomatic arch (b); styloid process (c); mastoid portion (part) of temporal bone (d); external auditory canal (e; yellow arrow; also called external auditory meatus or external acoustic meatus). Some data present in this reconstructed 3D image has been omitted (using black rectangles) to avoid any kind of identification. Abbreviations: CT, computed tomography; 3D, Three-dimensional.

imaging postprocessing techniques (► **Fig. 5**). At the end of the 3-day course, students responded to a satisfaction survey regarding this methodology (**table 1**). Some questions were part of the satisfaction survey, and students could answer either yes or no. Finally, participants were free to comment on the course and assign a score of 0 to 10 for course performance, being 0 (zero) for poor and 10 (ten) for best. The survey results analysis was performed using Microsoft Excel 2011, for Mac v.14.7.2 (Microsoft Corp., Redmond, WA, USA).

Results

The first image-guided temporal bone dissection course had 15 participants, 12 students and 3 instructors. Of the 13 temporal bones available, one was dissected by the instructors and the remaining 12 were dissected by the students. Among temporal bones utilized in the dissection course, 6 were right-sided and 7

Table 1 Satisfaction survey

Questions	Possible answers
Were the days and times of the course convenient?	Yes or No
Have your expectations regarding the course been met?	Yes or No
General opinions about the course	Free response

were left-sided. As previously mentioned, all the temporal bones available underwent a preparation process to be initially scanned on a CT equipment and later to be dissected.

Before starting dissection of the temporal bone cadaveric specimens, students received an initial training on surgical techniques by practicing on the simulator (Voxel-Man ENT Surgical Simulator). Prior to the beginning of the course, all acquired CT images of the temporal bones to be dissected were imported (loaded) into the system of the virtual reality (VR) 3D surgical simulator. Thus, before dissecting their temporal bone specimens in actual (real) practice, students can first train surgical techniques on virtual 3D models of these same temporal bones.

Temporal bone dissection (Fig. 6.1) was performed through the steps described next.³ Dissection started with antrotomy and aticotomy. After that, the sigmoid sinus, the endolymphatic sac, and the jugular bulb were identified. Next, posterior tympanotomy and cochleostomy were performed. Then, dissection of the middle ear, labyrinthectomy, and exposure of the internal auditory canal were done. All of these steps were taken during the 3-day course.

The dissecting process was guided by CT images in real time during the course (►Fig. 6). Students had the opportunity to view, on the same monitor screen of the workstation, the dissection video being reproduced and the respective CT images of their temporal bone specimen (►Fig. 3). There were no major difficulties in correlating the anatomical structures in the real temporal bone (cadaveric) with the anatomy shown in the radiological images (CT) of this bone.

Next, a postprocessed CT image of a cadaveric temporal bone was presented (►Fig. 7). The reformatted CT images, together with the originals raw axial sections (slices), aided guiding dissection during the course.

At the end of this first course, students responded to a satisfaction survey regarding this innovative methodology. In this way, it was possible to obtain indicators on overall course performance. In total, all 12 students (100%) answered the course satisfaction survey. When asked if their expectations about the course were met, all 12 students (100%) answered yes. When asked if the days and times at

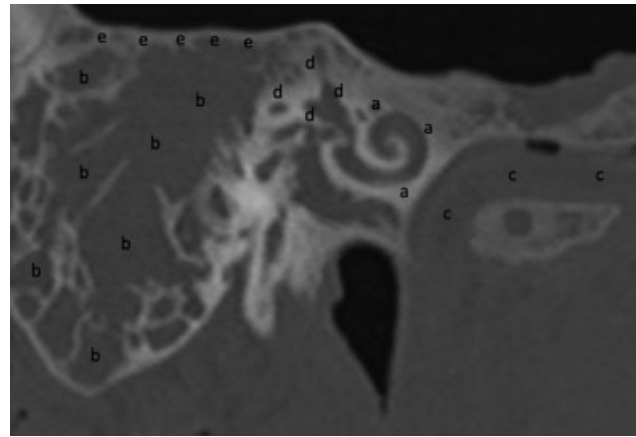


Fig. 7 : CT multiplanar reconstruction (MPR) in an oblique coronal plane demonstrating the cochlea (a); mastoid air cells (b); carotid canal (c); vestibule and semicircular canals (d); tegmen (e). Abbreviations: CT, computed tomography; MPR, multiplanar reconstruction or reformation.

which the course was held were convenient, all 12 students (100%) answered yes. Overall, 6 of 12 (50%) students stated that the course was excellent. One of these participants, who affirmed that course was excellent, also commented that “the use of CT images was the great differential of the course.”

One participant (1/12; 8.33%) assigned grade 9.5 for the course. Other 4 students (4/12; 33.33%) assigned grade 10 for the course. Of these four participants who assigned a maximum grade of 10 to the course, one of them stated that “the course had an excellent program and dissection steps; in addition, the lectures and instructors orientations were also excellent”; another one (of these participants mentioned above) stated that “the course was wonderful, very well taught and with very good materials (equipment), representing a great opportunity for residents”; another student (of these specific participants) stated that “the structure and organization were great, and the course was very helpful”; the last of these students stated that “it was a privilege to attend a course with the instructor team available and in a state-of-the-art laboratory with excellent material.”

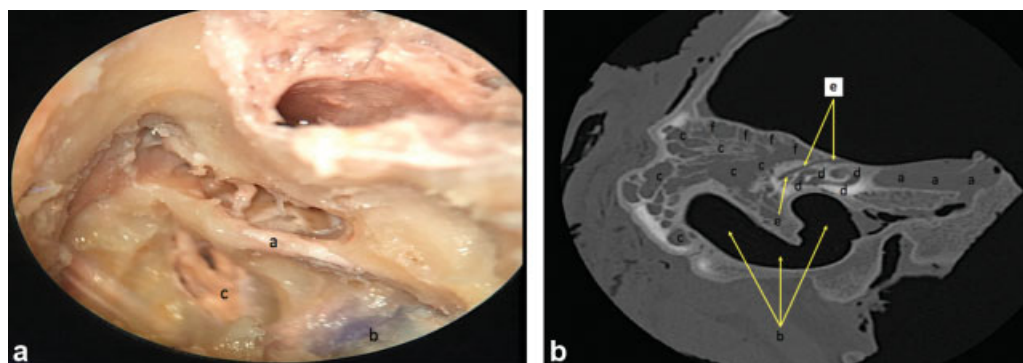


Fig. 6 Photograph of a dissected temporal bone and a CT image (postprocessed), showing some correlated anatomical structures. **6.a**: result of dissection of a cadaveric specimen of temporal bone during the course, demonstrating: facial nerve (a); jugular bulb (b); internal auditory canal (c; also called internal auditory meatus or internal acoustic meatus). **6.b**: CT MPR in an oblique axial plane, demonstrating the carotid canal (a; medially to the cochlea); sigmoid sinus/jugular bulb (b; yellow arrows; inferiorly and laterally to the cochlea); mastoid air cells (c); cochlea and vestibule (d); facial nerve (e; yellow arrows); tegmen (f). Abbreviations: CT, computed tomography; MPR, multiplanar reconstruction or reformation.

One of the students of the image-guided temporal bone dissection course who responded to the satisfaction survey had previously participated in a different temporal bone dissection course at another institution, which was coordinated by one of the instructors of the course currently described. The previous temporal bone dissection course in which this student participated was similar to the course reported in this article, except that this prior course was not associated with computed tomography imaging. As this specific student commented, “the first temporal bone dissection course attended, which was performed without the association of the computed tomography, was useful to acquire a solid anatomical base.” This aforementioned student also commented that “the current course of temporal bone dissection guided by CT images has the great differential of allowing residents to correlate the tomographic images with the temporal bone, ensuring the closest approximation to surgical reality.” This student continued by stating that “having the CT images next to the temporal bone during dissection, and the possibility of manipulating (explore and scroll) the axial tomographic slices as dissection progresses, provide the ideal scenario for both anatomy and otologic surgery learning.” Finally, this specific participant of the course described in the current article stated that “correlating the radiological anatomy with microscopic dissection not only brings the student closer to surgery, but also allows better planning of the steps to be taken during exploration of the temporal bone; however, the association of CT images during the course does not alter the dissection techniques used.”

Discussion

The unprecedented aspect of the described course was the innovative methodology utilized in the didactic process. Students had the temporal bones that they were dissecting previously scanned by multislice CT. It is relevant to highlight again that, to be eligible to attend the course, the resident must have basic knowledge about temporal bone radiology and the anatomy of this bone demonstrated in computed tomography (CT) images. It is also important to note that there were no financial costs for performing the temporal bone CT scans and acquiring the images for the course. This fact made it possible for the costs of course organization not to rise. Also, this detail made it possible for residents to enroll in the course free of charge.

As previously mentioned, all dissected temporal bones had their CT images postprocessed by two radiologists at different times (before and during the course) and through the use of various techniques (including reformatting in multiple planes and 3D reconstructions, among others). This allowed the dissecting process to be aided and guided by images in real time during the course. In other words, students had the opportunity to access and view on the same monitor screen, simultaneously (side by side), the live video reproduction of their surgical dissections and the display (presentation) of the CT images of their temporal bone specimens (→ **Fig. 3**). Likewise, while performing the dissec-

tions (as well as before and after these procedures), students could explore and scroll between the various series of CT images that were available, taking advantage of the fact that the images originated from their respective temporal bones. As described, temporal bone CT images were imported into a 3D (VR) surgical simulator, allowing students to train in virtual models of their cadaveric specimens before initiating the actual bone dissection. These aspects enabled correlating surgical and imaging characteristics in real time, a fact that improved anatomical understanding and spatial localization. This novel methodology used in the dissection course reinforces the extreme importance of the correlation between anatomy and imaging methods.

According to the literature, several types of neoplastic, congenital, inflammatory/infectious and vascular pathologies, as well as traumatic injuries, can affect the temporal bone.⁴ Understanding the normal temporal bone anatomy and its differential diagnoses, specific to each anatomical space of this bone, is primordial for surgery and also for imaging interpretation.⁴ In this context, CT and magnetic resonance imaging (MRI) are considered imaging methods that assist and complement the analysis of the temporal bone anatomy and of the abnormalities involving this bone.⁴

Radiologists (usually those who are specialists in head and neck imaging) and otologic surgeons use multislice CT for diagnosis, presurgical planning, and follow-up of patients with pathologies located in the neck, face, and skull (including the cranium).² Multislice CT is considered the gold standard imaging technique for studying and analyzing the temporal bone (including its anatomy and pathologies), due to the fact that CT has a superior image quality to demonstrate bony structures.² Additionally, this imaging method is capable of obtaining (acquiring) high-resolution millimetric axial sections (slices) of the body, being a valuable tool for anatomical evaluation of the temporal bone. In this way, CT imaging is able to accurately assess temporal bone structures, including the ossicular chain, bony labyrinth, external and internal auditory canals (meatuses), mastoid air cells, petrous apex, carotid canal, sigmoid sinus, and jugular bulb, among others. Moreover, CT is also useful in identification of temporal bone anatomical variants, assisting in preoperative planning as well as in the intraoperative, avoiding potential surgical complications. Therefore, correlation of CT images with temporal bone anatomy, especially during dissection, not only allows surgeons to learn anatomical peculiarities of temporal bone region and guide operative procedures, but it is also an interactive tool that helps medical training

Only through cadaveric dissections the beginner otologic surgeon can learn to go through the complex temporal bone anatomy, to avoid injury to several vital structures hidden in a very small surgical area.⁵ For example, a reduced operative field and the occurrence of anatomical variations make the facial nerve susceptible to injury during a surgical procedure.⁵ Kharat et al (2009)⁵ stated that a good 3D anatomical knowledge provides the basis for a careful and skilled dissection of the temporal bone, including an abnormal facial nerve.

Advances in the field of surgical simulation may represent the solution for training and acquiring more solid and

practical surgical skills.¹ Although not considered a substitute for real surgical experience, the virtual reality (VR) simulation system arose as a potential tool to be introduced in surgical practice and training.⁶ Simulators are getting increasingly relevant for surgical training, with temporal bone surgery representing a field in which simulation systems are likely to reach a prominent position.⁷ A study by Nash et al (2012),⁷ indicated that efficiency of the virtual dissection performed by novice surgeons improved as they became more competent and skilled in using a simulator for temporal bone surgery training. According to Sethia and Wiet (2015),⁶ the field of temporal bone simulation (TBS) focuses on developing and validating surgical simulators as training and assessment tools. Corroborating these studies cited above, in the course described in this article, a VR simulator was used for surgical pretraining in temporal bone dissection. This feature allowed students to practice their surgical skills and develop their perception of 3D anatomy through virtual reality imagery before starting the real surgical procedure. As technology evolves, researchers predict new clinical applications for simulators, which extend to preoperative planning.⁶ Most literature on the VR-based TBS provides evidence of validity of its application in otolaryngology resident training.⁶ However, there are still very limited data and experience on the use of simulation systems in preoperative preparation for otologic surgery.⁶

Results of the satisfaction survey conducted at the end of the first image-guided temporal bone dissection course demonstrated that, among students who answered, there was a great acceptance and contentment with the methodology of the course. Most participants rated the course as excellent or assigned high grades for course performance. A commentary of one student, in particular, drew attention, since it emphasized that use of temporal bone CT in conjunction with dissection was the aspect that differentiated and highlighted the course's didactic methodology. One student of the CT-guided temporal bone dissection course had previously participated in a different temporal bone dissection course without the association with multislice CT imaging. According to the comments made by this student in the satisfaction survey, it is possible to notice that both dissection courses, the first one without the association of CT, and the one currently described, which had the association with CT, were important in the training of otolaryngology residents. This student's opinion also demonstrates that the presence of CT images of the temporal bones in the course reported in this article was a novelty that aided anatomical learning. This aspect of the temporal bone dissection course assists in the process of transporting the anatomical knowledge to real surgery situation.

After interpreting the survey's results, it is possible to affirm that the course captivated students in relation to temporal bone anatomy and imaging learning. The implemented course design, according to which students had CT images available with real-time access on the monitor's screens to aid dissections, worked very well. Availability of a radiologist assisting all students with CT imaging interpre-

tation was a facilitating factor for anatomical learning. There were no major difficulties in correlating the anatomical structures in the temporal bone with the radiological (CT scan) images. This can be explained by the fact that participating residents have a basic knowledge of temporal bone imaging. Likewise, the presence of a radiologist in the laboratory, available for consultation, aided in the process of association and interaction between the temporal bone anatomy and the radiological images (CT)

Postprocessed CT images such as those reproduced above in this paper (→ **Figs. 5, 6 and 7**), which were obtained (taken) during the course, are useful to exemplify the innovative methodology designed and to illustrate how the activities were conducted, with close correlation between anatomy and imaging. This methodology clearly facilitated temporal bone dissection procedures. For future courses to come, these concepts will be maintained, combining the dissection procedures with the CT images of cadaveric temporal bones. To improve this described methodology, a seminar of temporal bone CT imaging and a session to discuss clinical cases will be added to the course. Similarly, updates will be made to the 3D surgical simulator of the temporal bone, which will bring new functions and add more training options in this virtual reality (VR) system.

Temporal bone surgery requires the use of accurate and refined techniques, since many noble anatomical structures are contained within this bone. Surgical interventions in which the operative field is located close to the inner ear, as in a neurectomy of the singular nerve, are good examples of the aspects mentioned above.⁸ Therefore, a correct comprehension of temporal bone anatomy, including the inner ear region, is paramount for the surgeon who works in this area.⁸ Ideal training options for otologic surgeons are dissection in cadaveric temporal bones and practice in simulators. The process of dissection in cadaveric specimens facilitates the surgeon's skill acquisition as well as anatomical and spatial learning. Imaging methods, especially multislice CT, have grown in recent years as an excellent tool for visualization of temporal bone anatomy with high accuracy and precision. Therefore, teaching temporal bone anatomy through a dissection course guided by CT imaging, as presented in the current work, is an innovative approach.

Conclusion

The process of acquiring surgical skills to approach the temporal bone has a fundamental role in otolaryngology training. Computerized imaging methods that allow scanning, mapping and reconstruction of temporal bone anatomy, such as CT scan, are important in assisting surgery and dissection. The temporal bone dissection course guided by computed tomography demonstrated a perfect integration between anatomy and imaging, facilitating the learning process of surgical skills.

Conflict of Interests

The authors have no conflict of interests to declare.

References

- 1 Wiet GJ, Stredney D, Kerwin T, et al. Virtual temporal bone dissection system: OSU virtual temporal bone system: development and testing. *Laryngoscope* 2012;122(Suppl 1):S1–S12
- 2 Erovic BM, Chan HH, Daly MJ, et al. Intraoperative cone-beam computed tomography and multi-slice computed tomography in temporal bone imaging for surgical treatment. *Otolaryngol Head Neck Surg* 2014;150(01):107–114
- 3 Bento RF, Pinna MH, Brito Neto RV, Tsuji RK. *Manual de Dissecção do Osso Temporal*. 3rd ed São Paulo: Fundação Otorrinolaringologia; 2011
- 4 Abele TA, Wiggins RH III. Imaging of the temporal bone. *Radiol Clin North Am* 2015;53(01):15–36
- 5 Kharat RD, Golhar SV, Patil CY. Study of intratemporal course of facial nerve and its variations - 25 temporal bones dissection. *Indian J Otolaryngol Head Neck Surg* 2009;61(01):39–42
- 6 Sethia R, Wiet GJ. Preoperative preparation for otologic surgery: temporal bone simulation. *Curr Opin Otolaryngol Head Neck Surg* 2015;23(05):355–359
- 7 Nash R, Sykes R, Majithia A, Arora A, Singh A, Khemani S. Objective assessment of learning curves for the Voxel-Man TempoSurg temporal bone surgery computer simulator. *J Laryngol Otol* 2012;126(07):663–669
- 8 Takahashi H, Sando I. Three-dimensional computer-aided reconstruction and measurement of the temporal bone for singular neurectomy. *Eur Arch Otorhinolaryngol* 1992;249(02):74–78