



## Original article

# Prolonged caffeine intake decreases alveolar bone damage induced by binge-like ethanol consumption in adolescent female rats



Cristiane Maia<sup>a,\*</sup>, Bruno Gonçalves Pinheiro<sup>a</sup>, Carla Cristiane Soares da Silva<sup>a</sup>, Rodrigo A. Cunha<sup>b</sup>, Deiweson Souza-Monteiro<sup>c</sup>, Maria Karolina Martins Ferreira<sup>c</sup>, Tuany Rafaeli Schmidt<sup>d</sup>, Gabriela de Souza Balbinot<sup>e</sup>, Fabrício Mezzomo Collares<sup>e</sup>, Manoela Domingues Martins<sup>d</sup>, Rafael Rodrigues Lima<sup>c</sup>

<sup>a</sup> Laboratory of Pharmacology of Inflammation and Behavior, Faculty of Pharmacy, Institute of Health Science, Federal University of Pará, Belém, Pará, Brazil

<sup>b</sup> CNC-Center for Neurosciences and Cell Biology, Faculty of Medicine, University of Coimbra, Portugal

<sup>c</sup> Laboratory of Functional and Structural Biology, Biological Science Institute, Federal University of Pará, Belém, Pará, Brazil

<sup>d</sup> Department of Oral Pathology, School of Dentistry, Federal University of Rio Grande do Sul, Porto Alegre, Brazil

<sup>e</sup> Department of Dental Materials, School of Dentistry, Universidade Federal do Rio Grande do Sul, Porto Alegre, Brazil

## ARTICLE INFO

## Keywords:

Binge drinking

Caffeine

Adenosine A<sub>2A</sub> receptor

Adolescence

Alveolar bone loss

Periodontitis

## ABSTRACT

Ethanol consumption has been reported to negatively impact on periodontal disease. In particular, oral cavity disorders occur upon ethanol exposure during adolescence, a life period associated with particular patterns of short and intense ('binge-like') ethanol consumption that is most deleterious to oral health. The hazardous central effects of ethanol have been linked to the overfunction of adenosine receptors, which are antagonized by caffeine, a bioactive substance present in numerous natural nutrients, which can also modify bone metabolism. The aim of this study was to investigate the effects of caffeine on alveolar bone damage induced by an ethanol binge drinking paradigm during adolescence. Female Wistar rats (35 days old; n = 30) were allocated to six groups: control (vehicle), ethanol (3 g/kg/day; 3 days On-4 days Off challenge), caffeine (10 mg/kg/day), caffeine plus ethanol, SCH58261 (0.1 mg/kg/day, an antagonist of A<sub>2A</sub> receptors), and SCH58261 plus ethanol. Bone micromorphology and vertical bone loss were analyzed by computed microtomography. Our data showed that ethanol binge drinking reduced alveolar bone quality, with repercussion on alveolar bone size. This ethanol-induced alveolar bone deterioration was abrogated upon treatment with caffeine, but not with SCH58261. This shows that caffeine prevented the periodontal disorder caused by ethanol binge drinking during adolescence, an effect that was not mediated by adenosine A<sub>2A</sub> receptor blockade.

## 1. Introduction

Alcohol consumption among adolescents affects 58 % of individuals between 17–18 years old [1]. In the United States, near 401,000 adolescents (12–17 years old) suffered from Alcohol Use Disorders (AUD) in 2018 [2]. Although female consume lower amounts of alcohol per occasion, young women consume increasing amounts of ethanol in some countries, with trends of drinking like men but with more medical problems than men [2–6]. High alcohol consumption is known to affect the neurobehavioral system [1], with repercussions on other body systems [7]. In particular, it has previously been proposed that alcohol consumption is a prominent factor impacting on alveolar bone health since the exposure to alcohol can trigger or aggravate periodontitis

[8,9]. The amplitude of the damaging effect of alcohol exposure on bones is dependent on the dose, the drinking pattern, and the age of the subjects [10,11]. Although little is known about the mechanisms underlying the effects of alcohol exposure on alveolar bone loss in the absence of other damaging factors [12,13], it is worth noting that an increased vulnerability to the harmful effects alcohol occurs during adolescence [14,15]; however, few studies have focused on the adolescence period.

Since 2015, our group has been studying the consequences of different patterns of alcohol exposure on the oral cavity during adolescence in animal models [14,16,17]. First, we employed a heavy drinking exposure paradigm in adolescent rats (6.5 g/kg/day from 35 days of age until 90 days) and observed that alcohol administration

\* Corresponding author at: Laboratório de Farmacologia da Inflamação e do Comportamento, Instituto de Ciências da Saúde, Universidade Federal do Pará, Rua Augusto Corrêa 1, Campus do Guamá, Belém, Pará, 66075-900, Brazil.

E-mail addresses: [crismaia@ufpa.br](mailto:crismaia@ufpa.br), [crismaia0301@hotmail.com](mailto:crismaia0301@hotmail.com) (C. Maia).

<https://doi.org/10.1016/j.bioph.2020.110608>

Received 31 May 2020; Received in revised form 16 July 2020; Accepted 2 August 2020

Available online 09 August 2020

0753-3322/ © 2020 The Authors. Published by Elsevier Masson SAS. This is an open access article under the CC BY-NC-ND license

(<http://creativecommons.org/licenses/by-nc-nd/4.0/>).

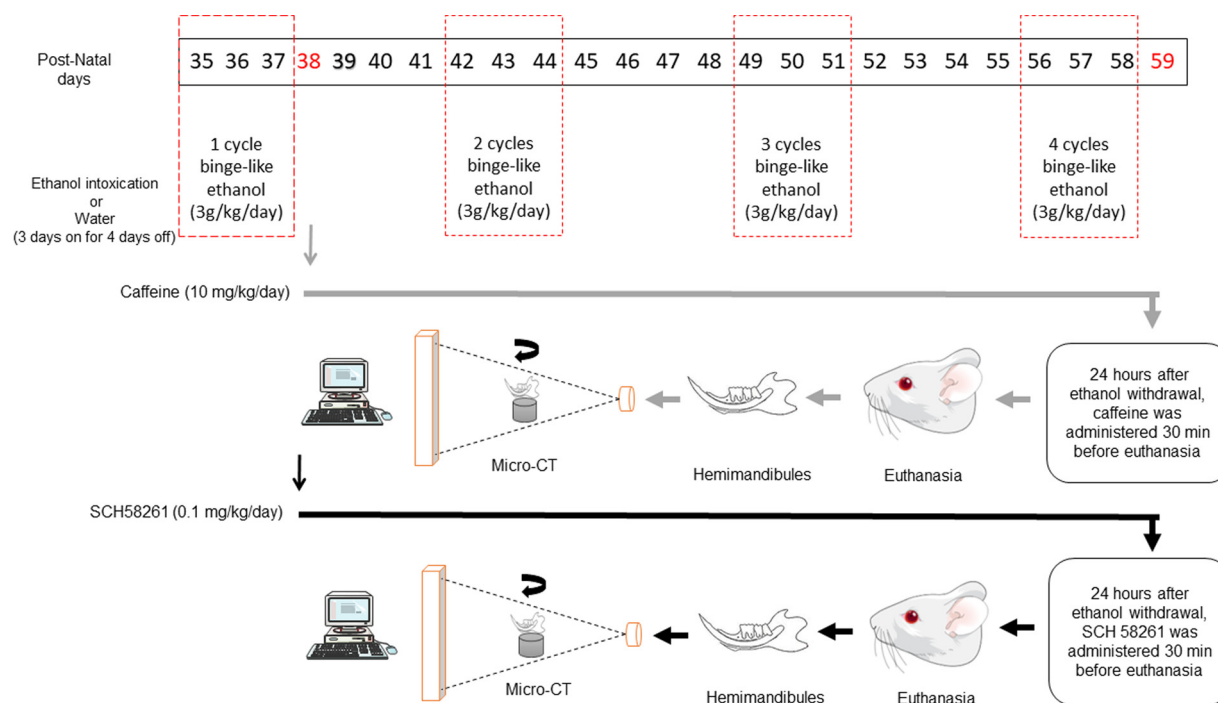


Fig. 1. Schematic experimental design.

induced alveolar bone loss even in the absence of experimentally-induced periodontitis [14]. Next, we tested a binge drinking protocol (3 days on- 4 days off), which models the pattern of alcohol exposure among adolescent female subjects, and we reproduced the previously described pattern of deterioration of salivary glands and alveolar bone health [17–19].

The exact mechanism that underlies the negative influences of alcohol intake on alveolar bone health is unclear. Pro-inflammatory effects, oxidative damage, as well as a negative action on bone remodeling have been proposed in the pathogenesis of the alveolar bone damage [9,10,20,21]. Among several pro-inflammatory pathways, inducible nitric oxide synthase (iNOS) overexpression and its final product nitric oxide (NO) have been observed in inflamed periodontal tissue [22]. One modulation system able to control the formation of NO is operated by adenosine, as reported in several cells [23–25]. Accordingly, adenosine can influence inflammatory processes in periodontal diseases [26–28]. Gingival tissues of humans have been found to possess different adenosine receptors, namely  $A_1R$ ,  $A_{2A}R$ , and  $A_{2B}R$  [28].  $A_{2A}R$  have been associated with apparently contradictory effects, triggering or reducing pro-inflammatory signaling [29,30]. In an experimental periodontitis study,  $A_{2A}R$  activation reduced periodontal inflammation processes, decreasing the release of pro-inflammatory mediators [31]. On the contrary, the activation of osteoblast  $A_{2A}R$  triggers osteoclastogenic cytokine production, associated with reduced bone turnover and reduced bone quality [32]. These paradoxical effects of adenosine receptors on inflammation probably result from the up-regulation of the adenosine pathways, which trigger pro-inflammatory cascades and tissue damage in chronic inflammation or upon injury [33]. Thus, the evidences suggest that the activation of adenosine receptors may play a pivotal role on epithelial tissues disorders, including chronic periodontitis [34].

Alcohol intake can also alter adenosine signaling in numerous tissues [35–37]. However, the involvement of adenosine receptors in ethanol-induced periodontitis has not been tested in spite of the known presence of adenosine signaling in the oral cavity.

One way to gauge the involvement of the adenosine modulation system is to study the effect of the bioactive compound caffeine (1,3,7-trimethylxanthine), which main mechanism of action is the antagonism

of adenosine receptors (for review see [38]). The effect of caffeine on bone metabolism has been described, with a negative impact observed at high doses (equivalent to 6 cups of coffee per day or more [39,40]);. Thus, high doses of caffeine aggravate alveolar bone loss in periodontal disease, but do not induce alveolar bone resorption in the absence of experimental periodontitis in adult or aged rats [41,42]. Importantly, an epidemiological study suggested that the dose of caffeine is a key variable that determines the positive *versus* negative effects of caffeine on periodontal health [43]. However, the impact of lower doses of caffeine, equivalent to the most common pattern of intake in humans (*i.e.* 2–3 cups of coffee/day) on oral health is still to be adequately characterized, a question of particular relevance, since it is these lower doses of caffeine (10 mg/kg/day in rodents) that afford a robust protection against different health threats (reviewed in [44]).

We now hypothesize that the daily intake of low doses of caffeine in female rats could dampen the alveolar bone loss caused by alcohol exposure during adolescence.

## 2. Material and methods

### 2.1. Animals

Adolescent female Wistar rats (28 days-old) from Evandro Chagas Institute (IEC/PA) animal facility, were randomly grouped and kept in polycarbonate cages ( $n = 3-4$  rats per cage) in a room under controlled environmental condition (temperature  $25 \pm 1$  °C and 12 h light/dark cycle, with lights on 6:00 a.m. Animals received food and water *ad libitum*. All procedures followed the *NIH Guide for the Care and Use of Laboratory Animal* and were approved by the Ethics Committee on Experimental Animals of the UFPA (license number 8324250716).

### 2.2. Experimental treatments

Experimental procedures started when rats were 35 days old. The binge drinking paradigm consisted of 4 sessions of ethanol binge-like exposure (3 days On-4 days Off; 20 % w/v) or distilled water (control group) by gavage [45,46]. Ethanol or distilled water was administered once a day in the morning. Twenty-four hours after the first binge

drinking session, the groups exposed to ethanol or distilled water were further divided into 3 subgroups. Two subgroups challenged with ethanol as well as the two subgroups exposed to distilled water received daily by oral route either caffeine (Sigma-Aldrich), at a low to moderate dose (10 mg/kg/day), or distilled water for 21 days (59-days old). The final subgroups derived from ethanol or distilled water groups received intraperitoneally the  $A_{2A}R$  antagonist SCH58261 (0.1 mg/kg/day) until they were 59-days old (30 min before euthanasia; Fig. 1). Body weight gain (%) was measured throughout the experimental treatments. This experimental design resulted in 6 groups of rats: control, ethanol, caffeine, ethanol plus caffeine, SCH58261, and ethanol plus SCH58261.

The dose of caffeine was based on the relationship established by [47], defining that a dose of 10 mg/kg in rats is equivalent to 250 mg/kg in humans (2–3 cups of a beverage). This limits the pharmacological action of caffeine to the non-selective antagonism of adenosine receptors [47]. The dose of SCH58261 (0.1 mg/kg) is defined as supra-maximal and selective to antagonize  $A_{2A}R$  [48], affording robust protective through  $A_{2A}R$  antagonism in different animal models (reviewed in [49]).

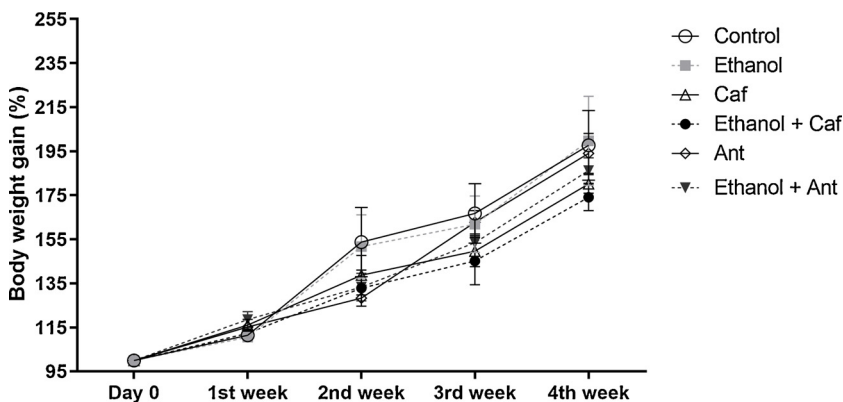
On the 59th postnatal day, rats were anesthetized by intraperitoneal injection of xylazine 2% (2 mg/mL) plus ketamine 10 % (10 mg/mL) and their jaws were collected. The left hemimandibles were maintained in 4% formol solution for micro-computed tomography (micro-CT) evaluation.

### 2.3. Micro-computed tomography (micro-CT) analysis

The left hemimandibles were submitted to x-ray micro-CT (MicroCT.SMX-90 CT; Shimadzu Corp., Kyoto, Japan). Each sample was positioned vertically on a rotatory device and the images were obtained under a rotation of 360° (intensity 70 kV; 100 mA) and reconstituted by inspeXio SMX-90CT software (Shimadzu Corp., Kyoto, Japan), from a total of 541 images per sample (voxel 10  $\mu$ m; resolution 1024  $\times$  1024; thickness 14  $\mu$ m).

Height evaluation of alveolar bone loss was analyzed using the RadiAnt DICOM Viewer 5.0.1 (Medixant, Poznan, Poland) software for 3D reconstruction. Tridimensional models were settled on a standard position (*i.e.*, lingual and vestibular tooth face visible). The vertical bone loss was measured by the distance between the cementum-enamel junction and the alveolar bone crest distance. Six points were evaluated on the first inferior molar, (*i.e.*, mesiolingual, midlingual, distolingual, mesiovestibular, midvestibular, distovestibular). The average values for each tooth were considered [50].

Alveolar bone tissue quality was analyzed by ImageJ® software (National Institutes of Health, Bethesda, MD, USA) on a series of 50 images from the inferior first molar alveolar bone region. The interdicular region of the inferior first molar with a mean length of 0.200 mm<sup>2</sup> from the cervical third until the middle third of the root, was



**Fig. 2.** Effects of caffeine or of the adenosine  $A_{2A}$  receptor ( $A_{2A}R$ ) antagonist (SCH58261) on adolescent binge-like ethanol challenge on the body weight gain of female Wistar rats (59-days-old,  $n = 5$  animals/group). Experimental groups consisted of Control group (distilled water; 3 days on-4 days off; 35th to 59th postnatal days); Ethanol group (3.0 g/kg/day; 3 days on-4 days off; 35th to 59th postnatal days);  $A_{2A}R$  antagonist group (SCH58261 0.1 mg/kg/day daily; 38th to 59th postnatal days; Ant);  $A_{2A}R$  antagonist plus ethanol group (SCH58261 0.1 mg/kg/day daily plus binge-like treatment; 38th to 59th postnatal days; Ant + Ethanol); Caffeine group (caffeine 10 mg/kg/day daily; 38th to 59th postnatal days; CAF); and Caffeine plus ethanol group (caffeine plus binge-like treatment; CAF + Ethanol). Values are expressed as the percentage of body weight gain from day 0 (100 %) until the 4th week of treatment. No statistical differences at  $p < 0.05$  using a two-way ANOVA repeated measure followed by Tukey's *post hoc* tests.

chosen as the region of interest (ROI). Segmentation was performed on the images with a gray scale threshold ranging from 120 to 250. Morphometric data was collected by measuring the trabecular number, trabecular thickness, trabecular separation, and bone volume fraction (bone volume/tissue volume) using the BoneJ plug-in [51].

### 2.4. Raman spectroscopy

To analyze the chemical structure of alveolar bone after the treatments, the  $PO_4^{3-}$  /AmideI ratio was calculated by Raman spectroscopy. The hemimandibles were sectioned perpendicularly to the bone at the center of the inferior first molar. A 1 mm-thick slice was placed on a Raman spectrometer (Senterra, Bruker Optics, Ettlingen, Germany). Analysis was performed with a 785 nm laser at 100 mW on a standardized area on the alveolar bone crest. Forty-five points were evaluated from the alveolar crest to the center of the alveolar bone with a standardized distance (100  $\mu$ m). The Raman spectra were obtained and the  $PO_4^{3-}$  peak at 960  $cm^{-1}$  as well as the amideI peak at 1660  $cm^{-1}$  were integrated and used to calculate the  $PO_4^{3-}$ :amideI ratio.

### 2.5. Statistical analyses

Data are shown as mean  $\pm$  S.E.M. ( $n = 5$  animals per group for micro-CT evaluation and  $n = 3$  for Raman analysis). A Shapiro-Wilk test was performed to verify normality of data distribution. The test power was calculated through the difference between two mean by OpenEpi (Version 2.3.1), with a type I error of 5% and a power of 80%. Statistical comparison was conducted by one-way ANOVA followed by Sidak's multiple comparisons *post hoc* test. The analyses of body weight gain (%) were carried out using a two-way ANOVA repeated measure followed by Tukey's *post hoc* test.  $P < 0.05$  was considered as statistically significant differences.

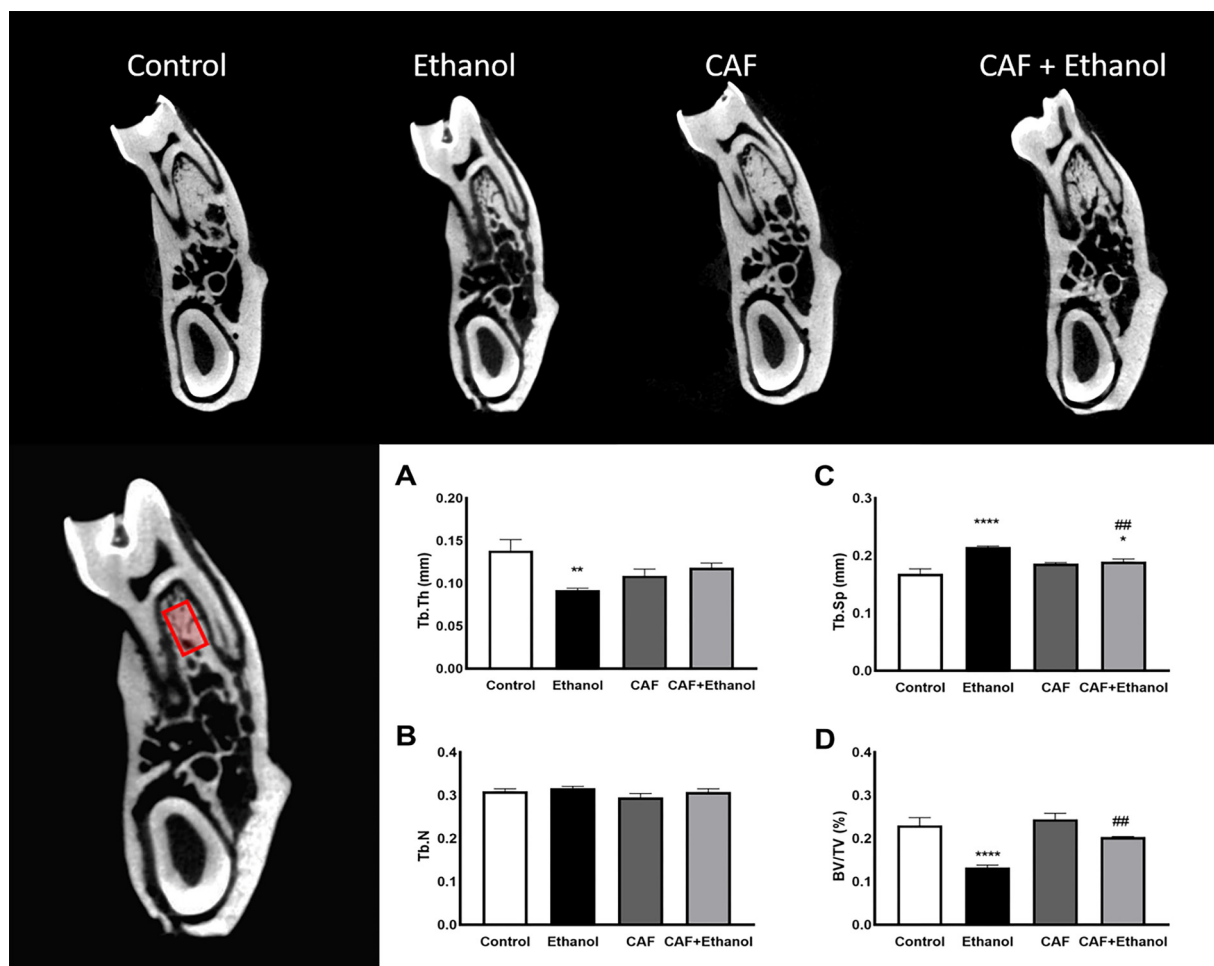
## 3. Results

### 3.1. Ethanol binge drinking and/or caffeine intake during adolescence do not modify body weight

The exposure to either ethanol binge-like without or with either caffeine or the  $A_{2A}R$  antagonist SCH58261, did not modify the average body weight gain of female rats during the treatment period (Fig. 2).

### 3.2. Long-term caffeine intake prevents the decrease of alveolar bone quality and density caused by ethanol binge drinking during adolescence

Initially, we explore the effects of caffeine on the alveolar bone detrimental consequences of adolescence binge drinking. Repeated exposure to ethanol binge intake during adolescence caused a reduction



**Fig. 3.** Effects of caffeine on the impact of adolescent binge-like ethanol challenge on the alveolar bone quality of female Wistar rats (59-days-old,  $n = 5$  animals/group). Experimental groups consisted of the Control group (distilled water; 3 days on-4 days off; 35th to 59th postnatal days); Ethanol group (3.0 g/kg/day; 3 days on-4 days off; 35th to 59th postnatal days); Caffeine group (caffeine 10 mg/kg/day daily; 38th to 59th postnatal days; CAF); and Caffeine plus ethanol group (caffeine plus binge-like treatment; CAF + Ethanol). The representative image of the interradicular region, close to the furcation area, was chosen as the standardized region of interest (ROI) for the analyses (left position). Above, representative ROI three-dimensional images of the analyzed groups. Values are mean  $\pm$  SEM for micro-CT parameters: (A) trabecular thickness (Tb.Th; mm); (B) mean number of trabeculae per unit length (Tb.N); (C) trabecular separation (Tb.Sp; mm); and (D) the percentage of bone volume in relation to the total measured area (BV/TV; %). \* $p < 0.05$  compared to control group; \*\* $p < 0.01$  compared to control group; \*\*\*\* $p < 0.0001$  compared to control group; ## $p < 0.01$  compared to ethanol group. One-way ANOVA followed by Sidak's *post hoc* test,  $p < 0.05$ . Scale bar: 1 mm.

of trabecular thickness compared to control rats ( $p = 0.0037$ ). Caffeine treatment mitigated this decreased trabecular thickness, which reached values equivalent to those of control animals (Fig. 3A). In addition, no statistically significant difference of trabecular thickness ( $p > 0.05$ ) was found for caffeine group when compared to the control subjects.

Trabecular separation was increased in rats subject to binge ethanol drinking ( $p < 0.0001$ ). Chronic administration of caffeine to ethanol-challenged rats ameliorated trabecular separation increment, but this parameter did not reach the values measured in the control group ( $p = 0.0086$ , ethanol vs. ethanol plus caffeine;  $p = 0.0279$ , control vs. ethanol plus caffeine; Fig. 3C). In addition, no statistically significant difference of trabecular separation ( $p > 0.05$ ) was found for caffeine group when compared to the control subjects.

The trabeculae number was not modified by either ethanol binge drinking or caffeine, since all tested groups presented values similar to the control group ( $p > 0.05$ ; Fig. 3B).

The percentage of bone volume fraction (BV/TV) was reduced by ethanol binge drinking ( $p < 0.0001$ ). Notably, caffeine intake by ethanol-challenged rats attenuated this bone loss caused by ethanol binge drinking during adolescence, resulting in bone density levels similar to control rats ( $p < 0.0001$ , control vs. ethanol;  $p = 0.0023$ , ethanol vs. ethanol plus caffeine; Fig. 3D). In addition, no statistically

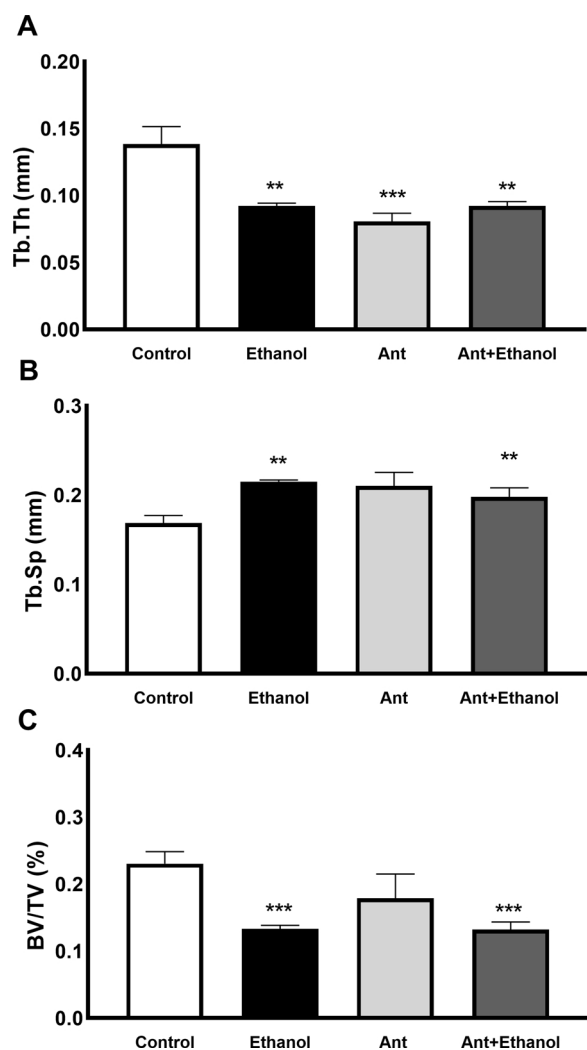
significant difference of bone density ( $p > 0.05$ ) was found for caffeine group when compared to the control subjects.

### 3.3. The selective antagonism of $A_{2A}R$ does not reproduce the positive effects of chronic caffeine treatment on binge ethanol drinking during adolescence

To test if  $A_{2A}R$  were mediating the benefits of caffeine on the negative effects on bone micromorphology caused by ethanol binge intake during adolescence, we tested the  $A_{2A}R$  antagonist SCH58261. Fig. 4 shows that all the parameters of bone quality that were deteriorated by ethanol binge-drinking (*i.e.*, trabecular thickness, trabecular separation, and bone density) were not recovered by treatment with the  $A_{2A}R$  antagonist, SCH58261. Interesting, SCH58261 *per se* (*i.e.* in the absence of ethanol challenge) reduced trabecular thickness ( $p = 0.0001$ ), but not trabecular separation and bone density (Fig. 4).

### 3.4. Caffeine recovers alveolar bone loss elicited by ethanol binge drinking during adolescence

Fig. 5(AE–) shows representative 3D reconstructions of hemi-mandibles from each experimental group, and also displays the



**Fig. 4.** Effects of the adenosine  $A_{2A}$  receptor antagonist (SCH58261) on the impact of adolescent binge-like ethanol challenge on the alveolar bone quality of female Wistar rats (59-days-old,  $n = 5$  animals/group). Experimental groups consisted of the Control group (distilled water; 3 days on-4 days off; 35th to 59th postnatal days); Ethanol group (3.0 g/kg/day; 3 days on-4 days off; 35th to 59th postnatal days);  $A_{2A}$ R antagonist group (SCH58261 0.1 mg/kg/day daily; 38th to 59th postnatal days; Ant); and  $A_{2A}$ R antagonist plus ethanol group (SCH58261 0.1 mg/kg/day daily plus binge-like treatment; 38th to 59th postnatal days; Ant + Ethanol). Values are mean  $\pm$  SEM for micro-CT parameters: (A) trabecular thickness (Tb.Th; mm); (B) trabecular separation (Tb.Sp; mm); and (C) the percentage of bone volume in relation to the total measured area (BV/TV; %). \*\* $p < 0.01$  compared to control group; \*\*\* $p < 0.001$  compared to control group. One-way ANOVA followed by Sidak's *post hoc* test,  $p < 0.05$ .

average quantifications of the distance between the cementum-enamel junction and the alveolar bone crest of the first inferior molar (Fig. 5F). The data show that ethanol binge drinking during adolescence reduced these quantified distances, implying that there was an alveolar bone loss ( $p = 0.0330$ ). Importantly, chronic administration of caffeine decreased this alveolar bone loss induced by binge-like ethanol drinking ( $p = 0.0272$ ), whereas there was no modification in the presence of the selective  $A_{2A}$ R antagonist SCH58261 ( $p > 0.005$ ).

### 3.5. Mineral content was influenced by the presence of ethanol

Fig. 6 shows the mineral:matrix ratio ( $PO_4^{3-}$ :amideI) obtained in the Raman measurements of the alveolar bone crest of treated animals (Fig. 6A). Regions with yellow/orange intensity indicate higher values of the mineral:matrix ratio, whereas regions with blue intensity

represent lower values. In the control group, higher values were more frequently observed in comparison to the other groups that presented mostly green/blue regions. However, no statistically significant difference was observed on the average mineral:matrix ratio between groups (Fig. 6B). The Raman spectroscopical mapping was used to probe potential differences in the mineral:matrix ratio at the alveolar crest (Fig. 6C).

## 4. Discussion

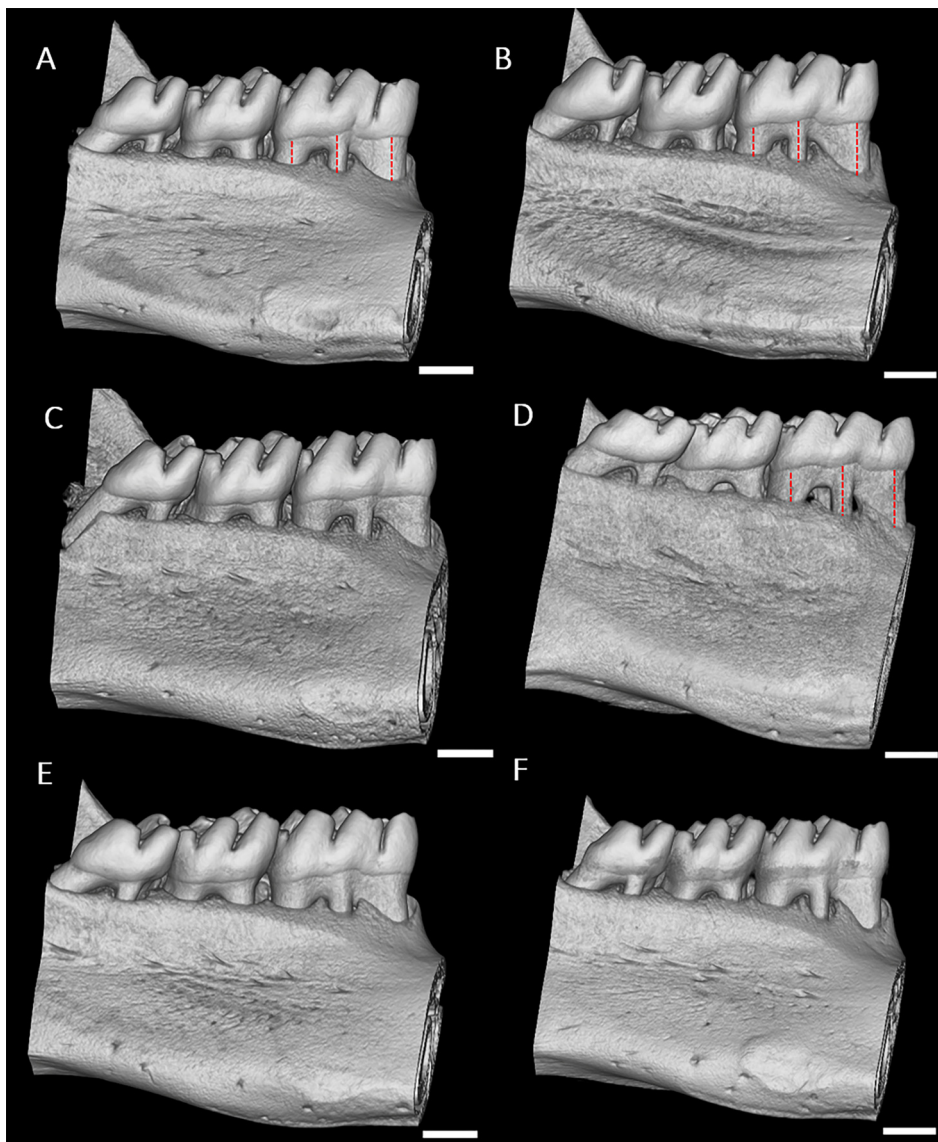
This study assessed the effects of low to moderate caffeine intake on alveolar bone damage induced by ethanol binge drinking in adolescent Wistar rats. Our results demonstrate, in an unprecedented way, that caffeine mitigates the negative effects on alveolar bone induced by ethanol exposure during adolescence. Our data also indicated that this beneficial effect of caffeine was unlikely to be mediated by the adenosine  $A_{2A}$  receptor pathway.

Although solely based on the analysis of an animal model, our findings highlight the possible damage of binge-like ethanol intake for the oral health of adolescents, certainly a problem of societal relevance. Firstly, the National Institute on Alcohol Abuse and Alcoholism has stressed the extent of ethanol exposure during adolescence and its negative repercussion on numerous tissues and organs [2]. In the United States, nearly 401,000 adolescents (12–17 years old) suffered from Alcohol Use Disorders (AUD) in 2018 [2]. The consequences of this overspread intoxication for the stomatognathic system is uncertain. On the other side, caffeine is present in several beverages consumed in numerous culturally different societies [52]. Its health benefits have been broadly reported, which implies that a nutritional style of life can counterbalance hazardous outcomes elicited by toxicants [52], eventually with the exception of pregnancy where caffeine intake has been reported to alter metabolism [53] and brain wiring [54] in animal models.

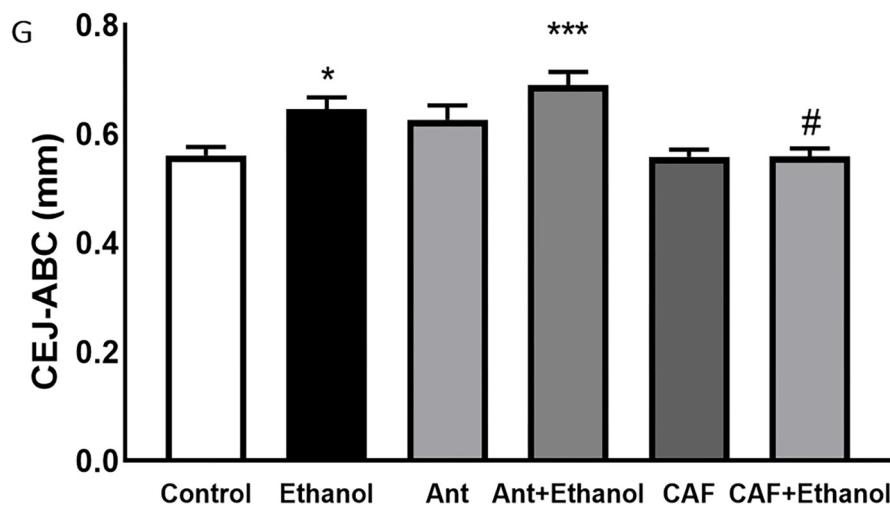
The ability of ethanol exposure to damage alveolar bone has previously been reported [8,9]. In fact, studies from our group have concluded that alcohol exposure causes damage and alveolar bone loss in the absence of additional damaging factors upon heavy or binge drinking paradigms, respectively in rats [14,19]. Our results corroborate these findings, demonstrating that four sessions, each of 3 days ON-4 days OFF, of ethanol intake during adolescence until adulthood, can trigger alveolar bone damage in female rats. In addition, the body weight gain was not modified by ethanol or adenosine receptor ligands administered in the present study, which excludes malnutrition as a contributing factor for the observed results.

Alveolar bone presents unique features with specific characteristics that distinguishes it from other bones, which are required to provide physiological support for tooth activity [55]. The analysis of micro-architectural parameters constitutes the main methodology to evaluate alveolar bone morphology and health [56]. Specifically, alveolar bone is a compact bone with large trabecular thickness, and reduced trabecular number and trabecular separation, which reflects an high bone mass and high mineralization [55]. In the present study, binge-like ethanol intake during adolescence reduced the trabecular thickness and increased the trabecular separation, which impacted on bone mass (bone fraction mass). Such alveolar bone alteration may generate negative reflexes on remodeling processes elicited by local and systemic stimuli [55].

It is well known that ethanol affects bone remodeling, leading to changes in the trabecular arrangement but little is known about its effect on the balance between organic and inorganic content [21]. Changes in the biochemical composition of bones may be explained by enhanced osteoclastogenesis and reduced osteoblast activity, and these activities are known to be affected by ethanol in different bone types (for review see [57]). The regulation of the activity of bone cells could lead to a lower mineralization of collagen fibrils on the newly formed bone when remodeling takes place [58]. Raman analysis was used in

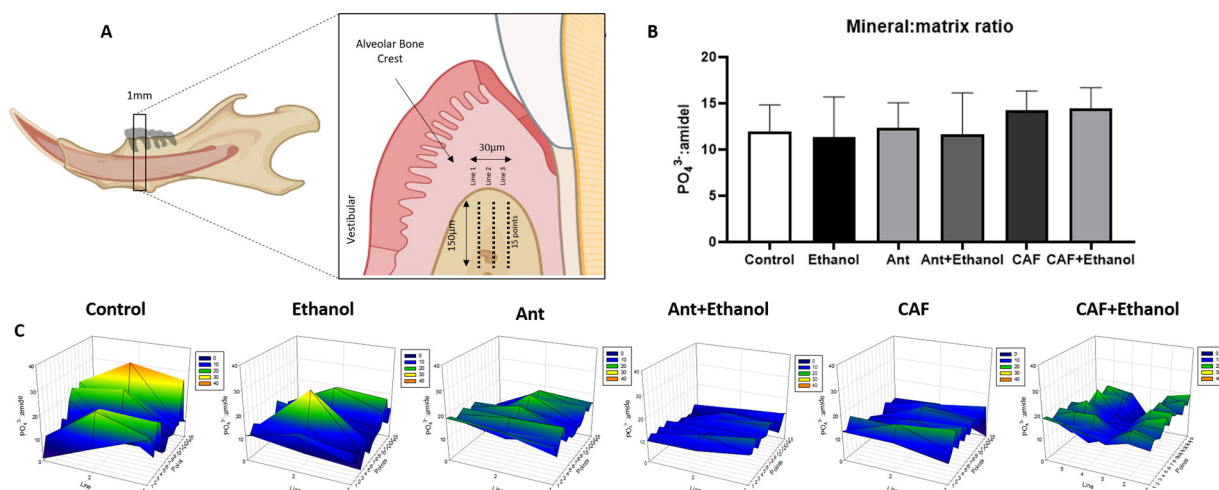


**Fig. 5.** Effects of caffeine and of the adenosine  $A_{2A}$  receptor antagonist (SCH58261) on adolescent binge-like ethanol challenge on the alveolar bone quality of female Wistar rats (59-days-old,  $n = 5$  animals/group). Representative three-dimensional images of hemimandibles of the (A) Control group (distilled water; 3 days on-4 days off; 35th to 59th postnatal days); (B) Ethanol group (3.0 g/kg/day; 3 days on-4 days off; 35th to 59th postnatal days); (C)  $A_{2A}$ R antagonist group (SCH58261 0.1 mg/kg/day daily; 38th to 59th postnatal days; Ant); (D)  $A_{2A}$ R antagonist plus ethanol group (SCH58261 0.1 mg/kg/day daily plus binge-like treatment; 38th to 59th postnatal days; Ant + Ethanol); (E) Caffeine group (caffeine 10 mg/kg/day daily; 38th to 59th postnatal days; CAF); and (F) Caffeine plus ethanol group (caffeine plus binge-like treatment; CAF + Ethanol). Panel (G) represents the distance between the cementum-enamel junction and alveolar bone crest (CEJ-ABC; mm). Red dotted lines highlight the differences between groups. Values are mean  $\pm$  SEM.  $^{***}p < 0.01$  compared to control group;  $^{##}p < 0.01$  compared to ethanol group. One-way ANOVA followed by Sidak's *post hoc* test,  $p < 0.05$ . Scale bar: 1 mm.



the present study to quantify the mineral content of bone tissue by the measurement of phosphate vibration on the bone samples, while the amide peak was used to quantify the organic content [59]. Although the microstructure of bone was modified by ethanol challenging, the

chemical analyses showed that the organic:inorganic content of the alveolar crest was not affected by the tested treatments. This leads to the conclusion that the presently used binge drinking protocol may not be sufficient to induce modifications of the activity of bone cells to



**Fig. 6.** Effects of caffeine and the adenosine  $A_{2A}$  receptor antagonist (SCH58261) on adolescent binge-like ethanol challenge on the alveolar bone chemical structure ( $PO_4^{3-}$  /Amidel) of female Wistar rats (59-days-old,  $n = 3$  animals/group). Raman spectroscopic analyzes of alveolar bone crest (panel A) in graphs (panel B) or colorimetric representative (panel C) of the Control group (distilled water; 3 days ON-4 days OFF; 35th to 59th postnatal days); Ethanol group (3.0 g/kg/day; 3 days on-4 days off; 35th to 59th postnatal days);  $A_{2A}R$  antagonist group (SCH58261 0.1 mg/kg/day daily; 38th to 59th postnatal days; Ant);  $A_{2A}R$  antagonist plus ethanol group (SCH58261 0.1 mg/kg/day daily plus binge-like treatment; 38th to 59th postnatal days; Ant + Ethanol); Caffeine group (caffeine 10 mg/kg/day daily; 38th to 59th postnatal days; CAF); and Caffeine plus ethanol group (caffeine plus binge-like treatment; CAF + Ethanol). Values are mean  $\pm$  SEM. No statistical differences at  $p < 0.05$  using a one-way ANOVA followed by Sidak's *post hoc* test.

modify bone composition.

We have already reported that the exposure to a 4-periods of binge drinking protocol in adulthood (starting at 90 days old) resulted in reduced alveolar bone quality, but not alveolar bone loss [19]. However, in contrast to what occurs during adulthood, we have now demonstrated that ethanol exposure during adolescence elicited alveolar bone loss. In other words, ethanol binge drinking decreases the quality of the alveolar bone microstructure both in adolescence and adulthood, but there is only an alveolar bone loss (*i.e.*, reduction of vertical dimension) in adolescent subjects. Here, we cannot infer that in the long-term, additional binge drinking exposure might further intensify alveolar bone loss, since bone quality is already affected at the onset of adulthood. Besides, this study cannot answer if the impairment of bone quality can spontaneously recover upon withdrawal of ethanol. It is important to stress that the tested ethanol consumption pattern, which consists of intense and episodic ethanol intake (*i.e.*, high doses during a few days and hours followed by an abstinence period) represents the most frequent consumption pattern by adolescents and younger people [3,60]. Therefore, we believe that alveolar bone microstructure damage resulting from binge-like ethanol exposure from mid-adolescence into adulthood is a valuable model to better comprehend the impact of ethanol intake by adolescents.

Contradictory findings have been reported with respect to the relationship between caffeine intake and bone health. A heavy intake of caffeine has been linked to hazardous effects on bone, including alveolar bone [40–42]. Interestingly, our results demonstrate that low to moderate doses of caffeine during adolescence not only did not cause any alveolar bone microstructure damage, but even avoided the reduction of alveolar bone quality induced by ethanol exposure in adolescent rats. Since moderate doses of caffeine act through the antagonism of adenosine receptors [43], this implies that the adenosine modulation system is not engaged in physiological conditions in the alveolar bone system of adolescent rats, but become active under stressful conditions, in accordance with the predominant allostatic rather than homeostatic role of the adenosine system [61]. Few studies have focused on the effects of caffeine on alveolar bone, and all studies tested caffeine at high doses [41,42]. The present study is the first study showing that at low to moderate doses, caffeine displays beneficial effects against an ethanol challenge (*i.e.*, systemic stimuli) concerning alveolar bone remodeling. In contrast to other skeletal bone that

originates in the mesoderm, alveolar bone is derived primarily from the neuroectoderm [62]. This embryologic difference confers to alveolar bone a dynamic metabolism and a different response to nutrition or bone toxic stimuli [63].

We also directed experimental efforts to investigate the most likely mechanism operated by caffeine to afford the observed protection of the integrity of alveolar bone upon exposure to ethanol. The principal mechanism of action of caffeine, especially at low doses, consists of the antagonism of adenosine receptors [38,47]. Furthermore, it is well documented that inflammatory processes underlie periodontal disease, which can be modulated by the purinergic system [22–24]. Among these adenosine receptors, adenosine  $A_{2A}$  receptors ( $A_{2A}R$ ) have been particularly involved in the control of inflammatory processes [64] and although the impact of ethanol on  $A_{2A}R$  expression in periodontal tissues remains unknown, the expression of  $A_{2A}R$  has been shown in chronic periodontitis [30]. Thus, we now hypothesized that caffeine intake could attenuate alveolar bone damage induced by ethanol binge drinking in adolescent rats through an antagonism of  $A_{2A}R$  controlling inflammation. To test if  $A_{2A}R$  were responsible for the effects of caffeine, we would expect that the selective blockade of  $A_{2A}R$  using a potent and selective antagonist, SCH58261, should afford the same beneficial effects of caffeine against ethanol-induced deterioration of alveolar bone. We failed to demonstrate this hypothesis, since a previously validated effective dose of SCH58261 (reviewed in [49]) did not mimic the protective effect of caffeine

It is noteworthy that the  $A_{2A}R$  antagonist did not increase the alveolar bone loss elicited by ethanol intake, which also speaks against a putative beneficial role of the  $A_{2A}R$  pathway on ethanol-induced periodontal disease during adolescence. In addition, SCH58261 *per se* administration reduced solely trabecular thickness, with no repercussion on alveolar bone mass.

Although the exact contribution of  $A_{2A}R$ -subtype on the pathophysiology of oral diseases is not yet well understood, the adenosine modulation system is still considered as an important target for oral health (for review see [65]), as best heralded by the benefits now reported for caffeine. Therefore, it can be speculated that other adenosine receptors, such as  $A_{2B}R$ , may play an important role in periodontal disease elicited by ethanol exposure during adolescence, a hypothesis that deserves to be further studied.

## 5. Conclusion

The present study revealed that ethanol binge drinking during adolescence causes alveolar bone damage, even in the absence of experimental periodontitis in rats. In addition, the daily intake of low to moderate doses of caffeine prevented the harmful effects on alveolar bone of ethanol binge drinking during adolescence. We also showed that the beneficial effects of caffeine do not involve adenosine A<sub>2A</sub>R antagonism.

## Declaration of Competing Interest

RAC is a scientific consultant for the Institute for Scientific Information on Coffee. All other authors declare no conflict of interests.

## Acknowledgments

This study was carried out with support from the Programa Nacional de Cooperação Acadêmica na Amazônia – PROCAD/Amazônia da Coordenação de Aperfeiçoamento de Pessoal de Nível Superior – CAPES/Brasil and by Coordenação de Aperfeiçoamento de Pessoal de Nível Superior - Brazil (CAPES) Finance Cod 001. This work was also supported by Research Pro-Rector of the Federal University of Pará (PROPESP, UFPA, Brazil). RAC was supported by La Caixa Foundation (LCF/PR/HP17/52190001), Centro 2020 (CENTRO-01-0145-FEDER-000008:BrainHealth 2020 and CENTRO-01-0246-FEDER-000010) and FCT (POCI-01-0145-FEDER-03127). CSFM, FMC, and MDM are supported by a research fellowship from CNPq.

## References

- [1] L.P. Spear, Effects of adolescent alcohol consumption on the brain and behaviour, *Nat. Rev. Neurosci.* 19 (2018) 197–214, <https://doi.org/10.1038/nrn.2018.10>.
- [2] (NIAAA), National Institute on Alcohol Abuse and Alcoholism, Alcohol Use Disorder, (2020) Available at: <https://www.niaaa.nih.gov/publications/brochures-and-fact-sheets/alcohol-facts-and-statistics#:~:text=Prevalence%20of%20drinking%3A%20According%20to,drank%20in%20the%20past%20month>.
- [3] (INPAD), Instituto Nacional de Ciência e Tecnologia para Políticas Públicas do álcool e outras drogas, II Levantamento nacional de álcool e drogas; Consumo de álcool no Brasil: Tendências entre 2006/2012, Available at: (2013) <https://inpad.org.br/wp-content/uploads/2014/03/Lenad-II-Relat%C3%B3rio.pdf>.
- [4] (WHO), World Health Organization, Global Status Report on Alcohol and Health 2018: Executive Summary, (2018) Accessed on: <file:///C:/Users/CrisMaia/Dropbox/posdoc/CAF/artigos/alcohol/OMS%202018.pdf>.
- [5] C.M. Chen, M.C. Dufour, H.-y. Yi, Alcohol consumption among young adults ages 18–24 in the United States: results from the 2001–2002 NESARC survey, *Alcohol Res. Health* 28 (2004) 269–280.
- [6] A. Erol, V.M. Karpyak, Sex and gender-related differences in alcohol use and its consequences: contemporary knowledge and future research considerations, *Drug Alcohol Depend.* 156 (2015) 1–13, <https://doi.org/10.1016/j.drugalcdep.2015.08.023>.
- [7] M. Pascual, J. Montesinos, C. Guerri, Role of the innate immune system in the neuropathological consequences induced by adolescent binge drinking, *J. Neurosci. Res.* 96 (2018) 765–780, <https://doi.org/10.1002/jnr.24203>.
- [8] W. Pitiphat, A.T. Merchant, E.B. Rimm, K.J. Joshipura, Alcohol consumption increases periodontitis risk, *J. Dent. Res.* 82 (2003) 509–513, <https://doi.org/10.1177/154405910308200704>.
- [9] E.J. Lages, F.O. Costa, S.C. Cortelli, J.R. Cortelli, L.O. Cota, R.M. Cyrino, E.M. Lages, G.C. Nobre-Franco, J.A. Brito, R.S. Gomez, Alcohol consumption and periodontitis: quantification of periodontal pathogens and cytokines, *J. Periodontol.* 86 (2015) 1058–1068, <https://doi.org/10.1902/jop.2015.150087>.
- [10] R. Dal-Fabbro, M. Marques-de-Almeida, L. Cosme-Silva, L.C. Capalbo, E. Ervolino, L.T.A. Cintra, J.E. Gomes-Filho, Effects of different alcohol concentrations on the development of apical periodontitis in rats, *Arch. Oral Biol.* 108 (2019) 104538, <https://doi.org/10.1016/j.archoralbio.2019.104538>.
- [11] J. Wang, J. Lv, W. Wang, X. Jiang, Alcohol consumption and risk of periodontitis: a meta-analysis, *J. Clin. Periodontol.* 43 (2016) 572–583, <https://doi.org/10.1111/jcpe.12556>.
- [12] N.P. Lang, P.M. Bartold, Periodontal health, *J. Clin. Periodontol.* 89 (2018) S9–S16, <https://doi.org/10.1111/jcpe.12936>.
- [13] P.N. Papananou, M. Sanz, N. Buduneli, T. Dietrich, M. Feres, D.H. Fine, T.F. Flemmig, R. Garcia, W.V. Giannobile, F. Graziani, H. Greenwell, D. Herrera, R.T. Kao, M. Kerschull, D.F. Kinane, K.L. Kirkwood, T. Kocher, K.S. Kornman, P.S. Kumar, B.G. Loos, E. Machtei, H. Meng, A. Mombelli, I. Needleman, S. Offenbacher, G.J. Seymour, R. Teles, M.S. Tonetti, Periodontitis: consensus report of workgroup 2 of the 2017 world workshop on the classification of periodontal and peri-implant diseases and conditions, *J. Clin. Periodontol.* 45 (2018) S162–S170, <https://doi.org/10.1002/JPER.17-0721>.
- [14] S.V. Bannach, F.B. Teixeira, L.M. Fernandes, R.O. Ferreira, L.N. Santana, E.A. Fontes-Júnior, G.B. Oliveira, R.D. Prediger, Alveolar bone loss induced by chronic ethanol consumption from adolescence to adulthood in Wistar rats, *Indian J. Exp. Biol.* 53 (2015) 93–97.
- [15] M.F. Bastos, G.L. Gaag, J.R. Romero, J.J. Gabrili, M.R. Marques, P.M. Duarte, Effects of cachaça, a typical Brazilian alcoholic beverage, on alveolar bone loss and density: a study in peripubertal rats, *Arch. Oral Biol.* 59 (2014) 82–91, <https://doi.org/10.1016/j.archoralbio.2013.10.002>.
- [16] L.M. Fernandes, F.B. Teixeira, S.M. Alves-Junior, J. Pinheiro Jde, C.S. Maia, R.R. Lima, Immunohistochemical changes and atrophy after chronic ethanol intoxication in rat salivary glands, *Histol. Histopathol.* 30 (2015), <https://doi.org/10.14670/HH-11-604>.
- [17] N.C. Fagundes, L.M. Fernandes, R.S. Paraense, P.M. de Farias-Junior, F.B. Teixeira, S.M. Alves-Junior, J. Pinheiro Jde, M.E. Crespo-López, C.S. Maia, R.R. Lima, Binge drinking of ethanol during adolescence induces oxidative damage and morphological changes in salivary glands of female rats, *Oxid. Med. Cell. Longev.* 2016 (2016) 7323627, <https://doi.org/10.1155/2016/7323627>.
- [18] Centro de informação sobre saúde e álcool (CISA), Relatório global sobre álcool e Saúde - 2018, Available at: (2018) <https://cisa.org.br/index.php/pesquisa/dados-oficiais/artigo/item/71-relatorio-global-sobre-alcool-e-saude-2018>.
- [19] Deborah Frazão Ribeiro, Cristiane Maia do Socorro Ferraz, Victória Chemelo dos Santos, Deiweson Monteiro, Railson Ferreira de Oliveira, Leonardo Bittencourt Oliveira, Gabriela Balbinot de Souza, Fabrício Colares Mezzomo, Cassiano Rosing Kuchenbecker, Manoela Martins Domingues, Rafael Lima Rodrigues, Ethanol binge drinking exposure affects alveolar bone quality and aggravates bone loss in experimentally-induced periodontitis, 7th 15, *Plos One*, 2020, p. e0236161.
- [20] K. Irie, T. Tomofuji, N. Tamaki, T. Sanbe, D. Ekuni, T. Azuma, T. Maruyama, T. Yamamoto, Effects of ethanol consumption on periodontal inflammation in rats, *J. Dent. Res.* 87 (2008) 456–460, <https://doi.org/10.1177/154405910808700511>.
- [21] D.M. de Souza, V.A. Rodrigues, A.A. Silva, V.S. Gonsalves, K.A. Pereira, R.S. Nishioka, C. de Carvalho, Influence of different alcohol intake frequencies on alveolar bone loss in adult rats: a sem study, *J. Clin. Exp. Dent.* 10 (2018) e852–e857, <https://doi.org/10.4317/jced.54647>.
- [22] H.K. Kendall, H.R. Haase, H. Li, Y. Xiao, P.M. Bartold, Nitric oxide synthase type-II is synthesized by human gingival tissue and cultured human gingival fibroblasts, *J. Periodontol. Res. Suppl.* 35 (2000) 194–200, <https://doi.org/10.1034/j.1600-0765.2000.035004194.x>.
- [23] J.B. Sousa, M.S. Vieira-Rocha, S.M. Arribas, M.C. González, P. Fresco, C. Diniz, Endothelial and neuronal nitric oxide activate distinct pathways on sympathetic neurotransmission in rat tail and mesenteric arteries, *PLoS One* 10 (2015) e0129224, <https://doi.org/10.1371/journal.pone.0129224>.
- [24] G. Haskó, C. Szabó, Z.H. Németh, V. Kvetan, S.M. Pastores, E.S. Vizi, Adenosine receptor agonists differentially regulate IL-10, TNF- $\alpha$ , and nitric oxide production in RAW 264.7 macrophages and in endotoxemic mice, *J. Immunol.* 157 (1996) 4634–4640.
- [25] C. Brodie, P.M. Blumberg, K.A. Jacobson, Activation of the A<sub>2A</sub> adenosine receptor inhibits nitric oxide production in glial cells, *FEBS Lett.* 429 (1998) 139–142, [https://doi.org/10.1016/S0014-5793\(98\)00556-0](https://doi.org/10.1016/S0014-5793(98)00556-0).
- [26] S. Murakami, M. Terakura, T. Kamatani, T. Hashikawa, T. Saho, Y. Shimabukuro, H. Okada, Adenosine regulates the production of interleukin-6 by human gingival fibroblasts via cyclic AMP/protein kinase a pathway, *J. Periodontol. Res. Suppl.* 35 (2000) 93–101, <https://doi.org/10.1034/j.1600-0765.2000.035002093.x>.
- [27] S. Murakami, T. Hashikawa, T. Saho, M. Takedachi, T. Nozaki, Y. Shimabukuro, H. Okada, Adenosine regulates the IL-1  $\beta$  beta-induced cellular functions of human gingival fibroblasts, *Int. Immunol.* 13 (2001) 1533–1540, <https://doi.org/10.1093/intimm/13.12.1533>.
- [28] S. Murakami, N. Yoshimura, H. Koide, J. Watanabe, M. Takedachi, M. Terakura, M. Yanagita, T. Hashikawa, T. Saho, Y. Shimabukuro, H. Okada, Activation of adenosine-receptor-enhanced iNOS mRNA expression by gingival epithelial cells, *J. Dent. Res.* 81 (2002) 236–240, <https://doi.org/10.1177/154405910208100403>.
- [29] F. Meng, Z. Guo, Y. Hu, W. Mai, Z. Zhang, B. Zhang, Q. Ge, H. Lou, F. Guo, J. Chen, S. Duan, Z. Gao, CD73-derived adenosine controls inflammation and neurodegeneration by modulating dopamine signalling, *Brain* 142 (2019) 700–718, <https://doi.org/10.1093/brain/awy351>.
- [30] Q. Liu, J. Li, J. Khoury, S.P. Colgan, J.C. Ibla, Adenosine signaling mediates SUMO-1 modification of IkappaBalpha during hypoxia and reoxygenation, *J. Biol. Chem.* 284 (2009) 13686–13695, <https://doi.org/10.1074/jbc.M809275200>.
- [31] A. Bitto, G. Oteri, M. Pisano, F. Polito, N. Irrera, L. Minutoli, F. Squadrito, D. Altavilla, Adenosine receptor stimulation by poly nucleotides (PDRN) reduces inflammation in experimental periodontitis, *J. Clin. Periodontol.* 40 (2013) 26–32, <https://doi.org/10.1111/jcpe.12010>.
- [32] S. Pal China, S. Pal, S. Chattopadhyay, K. Porwal, M. Mittal, S. Sanyal, N. Chattopadhyay, The wakefulness promoting drug Modafinil causes adenosine receptor-mediated upregulation of nuclear factor  $\kappa$ B ligand in osteoblasts: negative impact of the drug on peak bone accrual in rats, *Toxicol. Appl. Pharmacol.* 348 (2018) 22–31, <https://doi.org/10.1016/j.taap.2018.04.006>.
- [33] M.R. Blackburn, Too much of a good thing: adenosine overload in adenosine-deaminase-deficient mice, *Trends Pharmacol. Sci.* 24 (2003) 66–70, [https://doi.org/10.1016/S0165-6147\(02\)00045-7](https://doi.org/10.1016/S0165-6147(02)00045-7).
- [34] C.X. Sun, N.R. Wall, N. Angelov, C. Ririe, J.W. Chen, D.S. Boskovic, J.M. Henkin, Changes in mRNA expression of adenosine receptors in human chronic periodontitis, *Chin. J. Dent. Res.* 14 (2011) 113–120.
- [35] T.R. Butler, M.A. Prendergast, Neuroadaptations in adenosine receptor signaling following long-term ethanol exposure and withdrawal, *Alcohol. Clin. Exp. Res.* 36



- (2012) 4–13, <https://doi.org/10.1111/j.1530-0277.2011.01586.x>.
- [36] S.V. Raju, G. Wang, Suppression of adenosine-activated chloride transport by ethanol in airway epithelia, *PLoS One* 7 (2012) e32112, <https://doi.org/10.1371/journal.pone.0032112>.
- [37] V. Hughes, M.J.E. Richardson, M.J. Wall, Acute ethanol exposure has bidirectional actions on the endogenous neuromodulator adenosine in rat hippocampus, *Br. J. Pharmacol.* 175 (2018) 1471–1485, <https://doi.org/10.1111/bph.14152>.
- [38] A. Nehlig, J.-L. Daval, G.J.B.R.R. Debry, Caffeine and the central nervous system: mechanisms of action, biochemical, metabolic and psychostimulant effects, *Brain Res. Rev.* 17 (1992) 139–170, [https://doi.org/10.1016/0165-0173\(92\)90012-B](https://doi.org/10.1016/0165-0173(92)90012-B).
- [39] C. Cooper, E.J. Atkinson, H.W. Wahner, W.M. O'Fallon, B.L. Riggs, H.L. Judd, L.J. Melton, 3rd, Is caffeine consumption a risk factor for osteoporosis? *J. Bone Miner. Res.* 7 (1992) 465–471, <https://doi.org/10.1002/jbmr.5650070415>.
- [40] Y.H. Tsuang, J.S. Sun, L.T. Chen, S.C. Sun, S.C. Chen, Direct effects of caffeine on osteoblastic cells metabolism: the possible causal effect of caffeine on the formation of osteoporosis, *J. Orthop. Surg. Res.* 1 (2006) 7, <https://doi.org/10.1186/1749-799X-1-7>.
- [41] J.P. Bezerra, L.R. da Silva, V.A. de Alvarenga Lemos, P.M. Duarte, M.F. Bastos, Administration of high doses of caffeine increases alveolar bone loss in ligature-induced periodontitis in rats, *J. Periodontol.* 79 (2008) 2356–2360, <https://doi.org/10.1902/jop.2008.080204>.
- [42] J.P. Bezerra, A. de Siqueira, A.G. Pires, M.R. Marques, P.M. Duarte, M.F. Bastos, Effects of estrogen deficiency and/or caffeine intake on alveolar bone loss, density, and healing: a study in rats, *J. Periodontol.* 84 (2013) 839–849, <https://doi.org/10.1902/jop.2012.120192>.
- [43] N. Ng, E.K. Kaye, R.I. Garcia, Coffee consumption and periodontal disease in males, *J. Periodontol.* 85 (2014) 1042–1049, <https://doi.org/10.1902/jop.2013.130179>.
- [44] G. Grosso, J. Godos, F. Galvano, E.L. Giovannucci, Coffee, caffeine, and health outcomes: an umbrella review, *Annual Rev. Nutr.* 37 (2017) 131–156, <https://doi.org/10.1146/annurev-nutr-071816-064941>.
- [45] A. Bertola, S. Mathews, S.H. Ki, H. Wang, B. Gao, Mouse model of chronic and binge ethanol feeding (the NIAAA model), *Nat. Protoc.* 8 (2013) 627–637, <https://doi.org/10.1038/nprot.2013.032>.
- [46] L.M.P. Fernandes, S.C. Cartágenes, M.A. Barros, T. Carvalheiro, N.C.F. Castro, M.G. Schamne, R.R. Lima, R.D. Prediger, M.C. Monteiro, E.A. Fontes-Júnior, R.A. Cunha, C.S.F. Maia, Repeated cycles of binge-like ethanol exposure induce immediate and delayed neurobehavioral changes and hippocampal dysfunction in adolescent female rats, *Behav. Brain Res.* 350 (2018) 99–108, <https://doi.org/10.1016/j.bbr.2018.05.007>.
- [47] B.B. Fredholm, K. Bättig, J. Holmén, A. Nehlig, E.E. Zvartau, Actions of caffeine in the brain with special reference to factors that contribute to its widespread use, *Pharmacol. Rev.* 51 (1999) 83–133.
- [48] M. Yang, D. Soohoo, S. Soelaiman, R. Kalla, J. Zablocki, N. Chu, K. Leung, L. Yao, I. Diamond, L. Belardinelli, J.C. Shryock, Characterization of the potency, selectivity, and pharmacokinetic profile for six adenosine A2A receptor antagonists, *Naunyn Schmiedeberg's Arch. Pharmacol.* 375 (2007) 133–144, <https://doi.org/10.1007/s00210-007-0135-0>.
- [49] R.A. Cunha, How does adenosine control neuronal dysfunction and neurodegeneration? *J. Neurochem.* 139 (2016) 1019–1055, <https://doi.org/10.1111/jnc.13724>.
- [50] L. Virto, H.J. Haugen, P. Fernández-Mateos, P. Cano, J. González, V. Jiménez-Ortega, A.I. Esquifino, M. Sanz, Melatonin expression in periodontitis and obesity: an experimental in-vivo investigation, *J. Periodontol. Res. Suppl.* 53 (2018) 825–831, <https://doi.org/10.1111/jre.12571>.
- [51] M. Doube, M.M. Klosowski, I. Arganda-Carreras, F.P. Cordelières, R.P. Dougherty, J.S. Jackson, B. Schmid, J.R. Hutchinson, S.J. Shefelbine, BoneJ: Free and extensible bone image analysis in ImageJ, *Bone* 47 (2010) 1076–1079, <https://doi.org/10.1016/j.bone.2010.08.023>.
- [52] C.M. Reyes, M.C. Cornelis, Caffeine in the diet: country-level consumption and guidelines, *Nutrients* 10 (2018), <https://doi.org/10.3390/nu10111772>.
- [53] D. Xu, H.W. Luo, W. Hu, S.W. Hu, C. Yuan, G.H. Wang, L. Zhang, H. Yu, J. Magdalou, L.B. Chen, H. Wang, Intrauterine programming mechanism for hypercholesterolemia in prenatal caffeine-exposed female adult rat offspring, *FASEB J.* 32 (2018) 5563–5576, <https://doi.org/10.1096/fj.201701557R>.
- [54] C.G. Silva, C. Métin, W. Fazeli, N.J. Machado, S. Darmopil, P.S. Launay, A. Ghestem, M.P. Nesa, E. Bassot, E. Szabó, Y. Baqi, C.E. Müller, A.R. Tomé, A. Ivanov, D. Isbrandt, Y. Zilberter, R.A. Cunha, M. Esclapez, C. Bernard, Adenosine receptor antagonists including caffeine alter fetal brain development in mice, *Sci. Transl. Med.* 5 (2013) 197ra104, <https://doi.org/10.1126/scitranslmed.3006258>.
- [55] S. Zhou, Y. Yang, N. Ha, P. Zhang, X. Ma, X. Gong, Y. Hong, X. Yang, S. Yang, Q. Dai, L. Jiang, The specific morphological features of alveolar bone, *J. Craniofac. Surg.* 29 (2018) 1216–1219, <https://doi.org/10.1097/SCS.00000000000004395>.
- [56] Q.G. Dai, P. Zhang, Y.Q. Wu, X.H. Ma, J. Pang, L.Y. Jiang, B. Fang, Ovariectomy induces osteoporosis in the maxillary alveolar bone: an in vivo Micro-CT and histomorphometric analysis in rats, *Oral Dis.* 20 (2014) 514–520, <https://doi.org/10.1111/odi.12166>.
- [57] Z. Luo, Y. Liu, Y. Liu, H. Chen, S. Shi, Y. Liu, Cellular and molecular mechanisms of alcohol-induced osteopenia, *Cell. Mol. Life Sci.* 74 (2017) 4443–4453, <https://doi.org/10.1007/s00018-017-2585-y>.
- [58] R.T. Turner, L.S. Kidder, A. Kennedy, G.L. Evans, J.D. Sibonga, Moderate alcohol consumption suppresses bone turnover in adult female rats, *J. Bone Miner. Res.* 16 (2001) 589–594, <https://doi.org/10.1359/jbmr.2001.16.3.589>.
- [59] J.R. Beattie, A. Sophocleous, M.C. Caraher, O. O'Driscoll, N.M. Cummins, S.E.J. Bell, M. Towler, A. Rahimnejad Yazdi, S.H. Ralston, A.I. Idris, Raman spectroscopy as a predictive tool for monitoring osteoporosis therapy in a rat model of postmenopausal osteoporosis, *J. Mater. Sci. Mater. Med.* 30 (2019) 25, <https://doi.org/10.1007/s10856-019-6226-x>.
- [60] (WHO), World Health Organization, Global Status Report on Alcohol and health-2014, Available at: World Health Organization, J Geneva, Switzerland, 2014 [https://apps.who.int/iris/bitstream/handle/10665/112736/9789240692763\\_eng.pdf;jsessionid=419FFF0E428176893BC758E448D13BB1?sequence=1](https://apps.who.int/iris/bitstream/handle/10665/112736/9789240692763_eng.pdf;jsessionid=419FFF0E428176893BC758E448D13BB1?sequence=1).
- [61] R.A. Cunha, Signaling by adenosine receptors-homeostatic or allostatic control? *PLoS Biol.* 17 (2019) e3000213, <https://doi.org/10.1371/journal.pbio.3000213>.
- [62] T.L. Aghaloo, T. Chaichanasakul, O. Bezouglaia, B. Kang, R. Franco, S.M. Dry, E. Atti, S. Tetradis, Osteogenic potential of mandibular vs. long-bone marrow stromal cells, *J. Dent. Res.* 89 (2010) 1293–1298, <https://doi.org/10.1177/0022034510378427>.
- [63] A. Mavropoulos, R. Rizzoli, P. Ammann, Different responsiveness of alveolar and tibial bone to bone loss stimuli, *J. Bone Miner. Res.* 22 (2007) 403–410, <https://doi.org/10.1359/jbmr.061208>.
- [64] M.V. Sitkovsky, D. Lukashov, S. Apasov, H. Kojima, M. Koshiba, C. Caldwell, A. Ohta, M. Thiel, Physiological control of immune response and inflammatory tissue damage by hypoxia-inducible factors and adenosine A2A receptors, *Annu. Rev. Immunol.* 22 (2004) 657–682, <https://doi.org/10.1146/annurev.immunol.22.012703.104731>.
- [65] J.C. Lim, C.H. Mitchell, Inflammation, pain, and pressure-purinergeric signaling in oral tissues, *J. Dent. Res.* 91 (2012) 1103–1109, <https://doi.org/10.1177/0022034512463239>.