

## Histoplasmosis presenting as addisonian crisis in an immunocompetent host

### Histoplasmose apresentando-se como crise addisoniana em hospedeiro imunocompetente

Marcio Fernandes Chedid<sup>1</sup>, Aljamir Duarte Chedid<sup>2</sup>, Geraldo Resin Geyer<sup>3</sup>,  
Maria Bernadete Fernandes Chedid<sup>4</sup> and Luiz Carlos Severo<sup>5</sup>

#### ABSTRACT

*A 71-year-old man with presumptively treated pulmonary tuberculosis ten years earlier and previous alcoholism presented with adrenal insufficiency. HIV serology was negative. A computerized tomography scan of the abdomen showed enlarged right adrenal. He recovered after emergency treatment with hydrocortisone IV. Right adrenalectomy was performed. Histoplasmosis was diagnosed and the patient was treated with itraconazole, corticosteroid replacement, and discharged with good health.*

*Key-words: Histoplasmosis. Histoplasma capsulatum. Adrenal gland.*

#### RESUMO

*Homem de 71 anos de idade com tratamento presuntivo de tuberculose pulmonar 10 anos antes e de alcoolismo prévio apresentou-se com insuficiência de supra-renal. HIV soro-negativo. A tomografia computadorizada abdominal mostrou aumento da glândula supra-renal direita. Ele melhorou após tratamento de emergência com hidrocortisona EV. Supra-renalectomia direita forneceu diagnóstico de histoplasmose. O paciente foi tratado com itraconazol, reposição hormonal e teve alta em boas condições.*

*Palavras-chaves: Histoplasmose. Histoplasma capsulatum. Glândula supra-renal.*

Histoplasmosis is a fungal infection caused by *Histoplasma capsulatum*. The majority of cases are from areas considered as highly endemic for the infection. In disseminated histoplasmosis, which most commonly affects immunocompromised hosts, asymptomatic infection of the adrenal glands is a common event<sup>10</sup>. In contrast, in the normal individual both disseminated histoplasmosis and symptomatic adrenal histoplasmosis are exceedingly rare<sup>10</sup>.

In the State of Rio Grande do Sul, southern Brazil, in the last 21 years we have seen all clinical courses of histoplasmosis<sup>6</sup>. However, this is the first case of chronic disseminated histoplasmosis presenting as addisonian crisis in an immunocompetent patient in Rio Grande do Sul.

#### CASE REPORT

A 71-year-old man with a history of treatment for presumptive pulmonary tuberculosis diagnosed ten years earlier, arterial

hypertension and previous alcoholism was in clinical investigation for arterial hypotension. He presented at the Emergency Unit with anorexia, prostration, diarrhea and nausea, in May 2001. He reported a weight loss of 6kg in the last month. On examination, he appeared chronically ill and he was lean and his skin was dark and dry. Blood pressure was 100/50mmHg with postural hypotension, pulse 120 bpm, axillary temperature 36.5°C, respiration rate 20. He presented cold extremities and had neither lymphadenomegaly nor hepatosplenomegaly. No other changes were seen in the physical examination. Hematocrit 35.2%, hemoglobin 11.6g/dl, WBC 9,900 (band forms 4%, segs 78%, lymph 15%, monocytes 3%). Blood tests revealed hyponatremia ( $\text{Na}^+ = 131$  mEq/L, normal range 135-144 mEq/L) and serum  $\text{K}^+$  in the upper limit (4.9 mEq/L, normal range 3.5-5 mEq/L). Fourteen days previously, he had a WBC count that showed 7.100/mL (band forms 14%, segs 20.9%, lymph 32.5%, monocytes 8.7%, eosinophils 22.3%, basophils 1.6%). The other blood tests were normal, including a negative HIV serology, hepatic

1. Bolsista da Fundação de Pesquisa do Rio Grande do Sul, Porto Alegre, RS. 2. Serviço de Transplante Hepático Adulto do Hospital de Clínicas de Porto Alegre da Universidade Federal do Rio Grande do Sul, Porto Alegre, RS. 3. Serviço de Patologia do Hospital Ernesto Dornelles, Porto Alegre, RS. 4. Programa de Pós-Graduação em Pneumologia da Universidade Federal do Rio Grande do Sul. 5. Pesquisador do CNPq, Universidade Federal do Rio Grande do Sul, Porto Alegre, RS.

Address to: Dr. Aljamir D. Chedid. R. Marechal Andréa 300/201, Boa Vista, 91340-400 Porto Alegre, RS.

Telefax: 55 51 3328-2472

e-mail: Aljamir@terra.com.br

Recebido para publicação em 20/12/2002

Aceito em 4/12/2003

transaminases and hepatic function tests. Abdominal computerized tomography (CT) scan showed a normal-sized left adrenal gland, a lesion (4 x 2.4 cm) in the right adrenal gland, and a calcified hepatic lesion (Figure 1). Chest X-rays showed micronodules disseminated in both lungs and a nodule of 2.5 x 2 cm in the apex of the left lung. Thorax CT showed one nodule in posterior segment of the superior right lobe and other nodule located in the superior segment of the inferior left lobe, the last impregnated by the contrast. Upper digestive tract endoscopy showed white lesion in the upper third of the esophagus biopsy of which revealed *Candida* spp, and retractions in the stomach, which biopsy revealed to be caused by *Helicobacter pylori*.

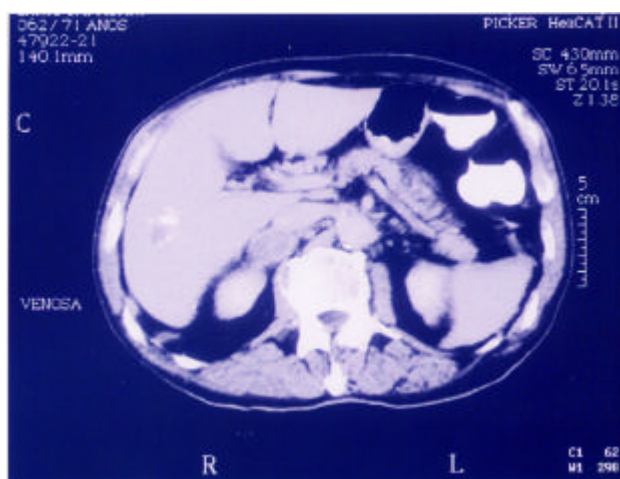


Figure 1-The abdominal CT scan showing the lesion (4 x 2.4cm) in the right adrenal gland and the calcified hepatic lesion (2.9 x 2.6cm).

In the emergency room, the diagnosis of Addisonian crisis was presumed, the patient immediately improved after emergency treatment with hydrocortisone IV 100 mg every 6 hours. On day 10 of hospitalization, the patient was submitted to a right adrenalectomy. The anatomicopathological investigation revealed parenchyma replacement by extensive caseous necrosis and incomplete granulomatous reaction. Tissue section stained by Gomori's methenamine-silver demonstrated numerous budding yeast cells of *Histoplasma capsulatum*. Staining for acid-fast bacilli and for malignant cells was negative. A course of itraconazole was started. Four days after the procedure the patient was discharged in good health conditions. Itraconazole and hydrocortisone were maintained. The patient returned one, three and six months later without symptoms.

## DISCUSSION

Although an uncommon disease, histoplasmosis is endemic in southern Brazil<sup>6</sup>. Chronic disseminated histoplasmosis is a mild form of the disease spectrum of disseminated histoplasmosis and it is the characteristic form of disseminated histoplasmosis in the adult<sup>3</sup>. It tends to be manifested by focal lesions with no constitutional symptoms<sup>3</sup>. Adrenal involvement in disseminated histoplasmosis is not uncommon, especially in the immunodepressed patients such as HIV positive, diabetic, and corticosteroid-treated patients<sup>12</sup>.

Although involvement of the adrenal glands by *H. capsulatum* was found in three patients in Rio Grande do Sul<sup>6</sup> this is the first case of chronic disseminated histoplasmosis presenting symptomatic adrenal insufficiency in an immunocompetent host. Histoplasmosis presenting as Addisonian crisis was previously found in Brazil, but the diagnosis was made only after death<sup>7</sup>. The clinical presentation is compatible with Addisonian crisis, because the patient felt fatigue, muscle weakness, abdominal pain and behavioral changes (prostration)<sup>9</sup>. Physical signs were totally compatible with Addisonian crisis, because we found postural hypotension, weight loss and darkened skin<sup>9</sup>. It should be stated that the diagnosis of Addisonian crisis was only clinically confirmed. The laboratorial tests showing previous eosinophilia, hyponatremia and the K<sup>+</sup> in the upper limit strongly suggested the diagnosis of Addison's disease. Facing a patient presenting these symptoms we promptly instituted the appropriate treatment with hydrocortisone IV (100mg every 6 hours) with marked improvement. We began to treat the patient without first having a complete laboratorial diagnosis of adrenal insufficiency, which would be obtained by the blood cortisol level and by the low ACTH stimulated cortisol responses. Although not providing definitive evidence of Addisonian crisis, the clinical picture associated to the anatomicopathological results was clear. Although normal in size, left adrenal involvement could not be excluded, considering the clinical picture and pulmonary and hepatic lesions attributable to histoplasmosis.

It is worth commenting that the patient had a presumptive diagnostic and pharmacological treatment of pulmonary tuberculosis ten years earlier. A case has been reported of tuberculosis together with histoplasmosis in an immunocompromised patient in Rio Grande do Sul<sup>5</sup>. The association between disseminated histoplasmosis and tuberculosis in an immunocompetent host has been described elsewhere<sup>4</sup>. It seems to be unlikely that in our case the patient would have had both diseases. It is most probable that the infection presumptively treated as pulmonary tuberculosis was the first symptomatic episode of histoplasmosis infection, since the patients may be infected by *H. capsulatum* for a considerable time without symptoms<sup>3</sup>.

In conclusion, adrenal infection by *H. capsulatum*, especially in endemic areas, has to be suspected as a cause of an Addisonian crisis, even in an immunocompetent host. Histoplasmosis should be included in the differential diagnosis of unilateral adrenal enlargement<sup>8</sup>.

## ACKNOWLEDGEMENTS

The authors thanks to Dr. Adelar Magnabosco Cosner, Dr Maitê de Mello Villwock and Dr. Marcio Lucas from Hospital Ernesto Dornelles.

## REFERENCES

1. Dismukes WE, Royal SA, Tynes BS. Disseminated histoplasmosis in corticosteroid-treated patients. Report of five cases. *Journal of the American Medical Association* 240:1495-1498, 1978.
2. Giacaglia LR, Lin CJ, Lucon AM, Goldman J. Disseminated histoplasmosis presenting as bilateral adrenal masses. *Revista do Hospital das Clínicas da Faculdade de Medicina de São Paulo* 53:254-256, 1998.

3. Goodwin RA, Shapiro JL, Thurman GH, Thurman SS, Des Prez RM. Disseminated histoplasmosis: clinical and pathologic correlations. *Medicine* 59:1-33, 1980.
4. Leibowitz MC, Berson SD, Martin PMD. Disseminated histoplasmosis associated with disseminated tuberculosis. A case report. *South African Medical Journal* 51:315-317, 1977.
5. Pinotti AFF, Severo LC, Randon M, Rigatto M, Haase HB. Histoplasmoze disseminada associada à tuberculose em pacientes imunodeprimidos. *Revista da Associação Médica Brasileira* 29: 68-70, 1983.
6. Severo LC, Oliveira FM, Irion K, Porto NS, Londero AT. Histoplasmosis in Rio Grande do Sul, Brazil: a 21-year experience. *Revista do Instituto de Medicina Tropical de São Paulo* 43:183-187, 2001.
7. Silva MA, Faria JL. Histoplasmoze da supra-renal. Apresentação de um caso. *Revista da Associação Médica Brasileira* 18: 207- 210, 1972.
8. Swartz MA, Scofield RS, Dickey WD, Kirk JL, Wilson DA, Pitha JV, Muchmore HG. Unilateral adrenal enlargement due to *Histoplasma capsulatum*. *Clinical Infectious Diseases* 23:813-815, 1996.
9. Ten S, New M, Maclaren N. Clinical review 130: Addison's disease 2001. *Journal Clinical Endocrinology & Metabolism* 86:2909-2922, 2001.
10. Wheat J. Histoplasmosis. Experience during outbreaks in Indianapolis and review of the literature. *Medicine* 76:339-354, 1997.