

# Mid-Ventricular Hypertrophic Obstructive Cardiomyopathy

Fernando Pivatto Jr.<sup>1</sup>, Márcio Mossmann<sup>1</sup>, Ana Maria Krepsky<sup>1</sup>, Alexandre do Canto Zago<sup>2</sup>

## ABSTRACT

Mid-ventricular hypertrophic obstructive cardiomyopathy is a rare variant form (1%) of hypertrophic obstructive cardiomyopathy. In this case, we report a patient referred for elective cardiac catheterization due to angina and dyspnea on moderate exertion, with no significant coronary obstruction, and left ventriculography indicating the presence of mid-ventricular hypertrophic obstructive cardiomyopathy with an intraventricular pressure gradient of 130 mmHg.

**DESCRIPTORS:** Cardiomyopathy, hypertrophic. Cardiac catheterization. Ventricular outflow obstruction, left.

## RESUMO

### Cardiomiopatia Hipertrófica Obstrutiva Médio-Ventricular

A cardiomiopatia hipertrófica obstrutiva médio-ventricular é uma variante rara (1%) da miocardiopatia hipertrófica obstrutiva. Neste relato de caso, apresentamos uma paciente encaminhada para realização de cateterismo cardíaco eletivo por angina e dispnéia aos moderados esforços, sem obstrução coronariana significativa e com ventriculografia esquerda, demonstrando cardiomiopatia hipertrófica obstrutiva médio-ventricular com um gradiente pressórico intraventricular de 130 mmHg.

**DESCRIPTORES:** Miocardiopatia hipertrófica. Cateterismo cardíaco. Obstrução do fluxo ventricular esquerdo.

**M**id-ventricular hypertrophic obstructive cardiomyopathy, first described by Falicov et al.<sup>1</sup> in 1976, is a rare type (1%) of hypertrophic obstructive cardiomyopathy.<sup>2</sup> In this variant, there is a significant mid-ventricular hypertrophy associated with a mid-ventricular stenosis, which confers the aspect of a dumbbell to the left ventricle,<sup>3</sup> with generation of a pressure gradient between the apical and basal chambers, as well as an absence of obstruction of outflow.<sup>2</sup>

## CASE REPORT

A female patient, 80 years, was referred for elective cardiac catheterization due to angina and dyspnea on moderate exertion. Physical examination revealed mid-systolic murmur without other significant findings. An electrocardiogram showed criteria for left ventricular

hypertrophy and secondary changes in ventricular repolarization (Figure 1). The coronary angiography showed no significant coronary stenoses; however, a left ventriculography in the right anterior oblique projection (30°) revealed mid-ventricular hypertrophic obstructive cardiomyopathy (Figure 2); after analysis of intracavitary pressures, a gradient of 130 mmHg was calculated (Figure 3).

## DISCUSSION

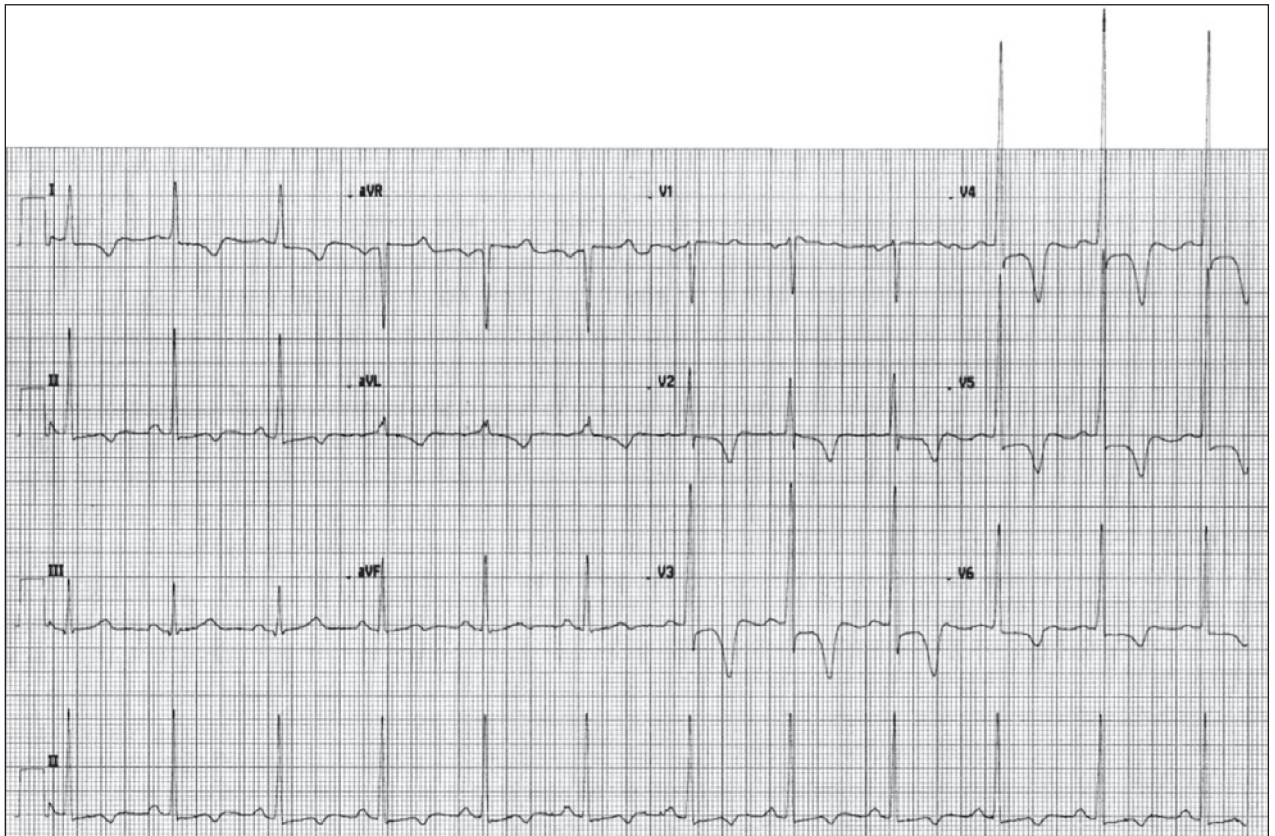
Midventricular hypertrophic obstructive cardiomyopathy is a phenotype distinct of hypertrophic obstructive cardiomyopathy, associated with an unfavorable prognosis. Efthimiadis et al.,<sup>4</sup> in a study comparing clinical characteristics and natural history of patients with hypertrophic cardiomyopathy, with

<sup>1</sup> Hospital de Clínicas de Porto Alegre, Porto Alegre, RS, Brazil.

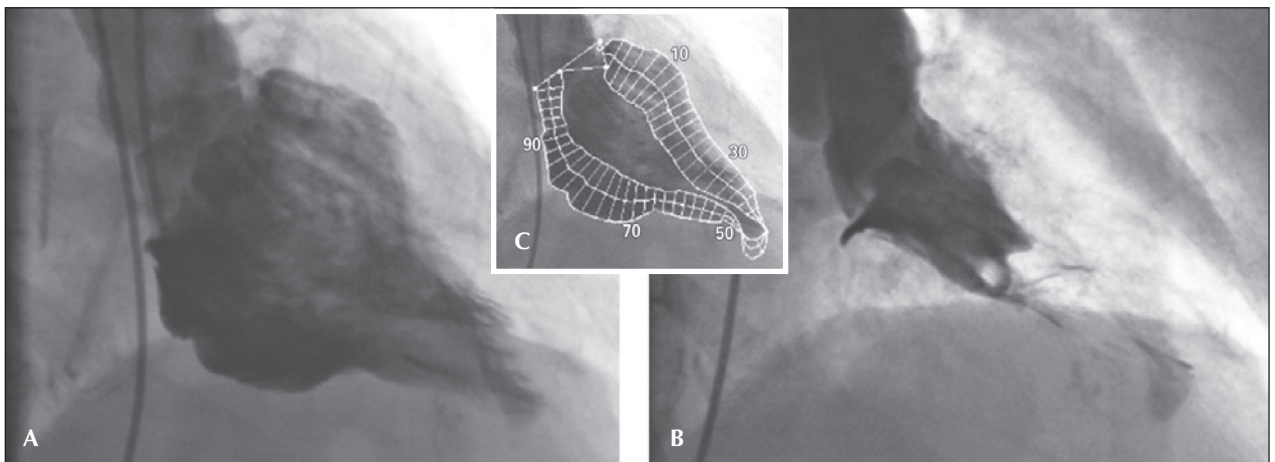
<sup>2</sup> Universidade Federal do Rio Grande do Sul, Porto Alegre, RS, Brazil.

**Correspondence to:** Fernando Pivatto Jr. Serviço de Cardiologia do Hospital de Clínicas de Porto Alegre – Rua Ramiro Barcelos, 2.350 – Rio Branco – CEP: 90035-903 – Porto Alegre, RS, Brazil  
E-mail: fpivatto@gmail.com

Received: 02/25/2014 • Accepted: 05/06/2014



**Figure 1** – Electrocardiogram with voltage criteria for left ventricular hypertrophy, secondary changes in ventricular repolarization, and deep inversion of T waves.



**Figure 2** – Left ventriculography showing severe mid-ventricular hypertrophy, with almost complete mid-ventricular obstruction and apical dilation during diastole (A) and systole (B); these findings are best observed in Figure 2C.

and without mid-ventricular obstruction, observed that its presence is a strong and independent predictor of sudden death, as well as a determinant of progression to end-stage hypertrophic obstructive cardiomyopathy and to heart failure-related death.

Apical aneurysms were observed in approximately 25% of patients with mid-ventricular obstructive hypertrophic cardiomyopathy, and were almost unique to this group. Their presence served as a marker of an even worse clinical course.

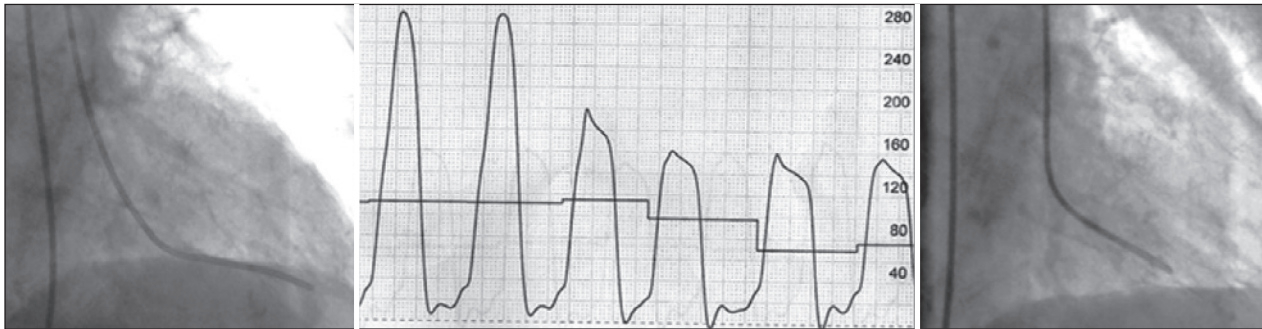


Figure 3 – Left ventricular pressures (center) in the apical (left) and basal (right) chambers, with pressure gradient of 130 mmHg.

Apical dilation may occur in cases of severe narrowing and of progression to a “burned out apex”, with apical aneurysm formation in approximately 10% of patients.<sup>3</sup> The pathogenesis of myocardial necrosis remains unknown. It has been suggested that the apical aneurysm may be secondary to after-load and to an increase of apical pressure, as a result of a mid-ventricular obstruction seen in the degenerative process of hypertrophic cardiomyopathy. Other possible causes of aneurysm formation are small vessel disease with decreased coronary flow reserve, coronary stenosis due to an increased wall stress in the hypertrophied myocardial segment, decreased coronary perfusion pressure due to the mid-ventricular obstruction, coronary spasm, and decreased capillary/myocardial fiber ratio.<sup>5</sup>

If left untreated, the midventricular obstructive hypertrophic cardiomyopathy can cause fatal ventricular arrhythmias and sudden death. Beta-blockers are the first therapeutic choice for hypertrophic obstructive cardiomyopathy, but the treatment of mid-ventricular obstructive hypertrophic cardiomyopathy remains unclear. Dual-chamber pacemaker<sup>6</sup> and percutaneous myocardial ablation<sup>7,8</sup> have been proposed as non-surgical treatments, but the long-term benefits and safety of these therapeutic options require further study.<sup>5</sup> The surgical treatment of midventricular hypertrophic obstructive cardiomyopathy is poorly described in the literature, mostly in the form of case reports.<sup>9</sup> Kunkala et al.,<sup>9</sup> in a recent study involving 56 patients, described the results of a transapical approach, noting that this option allows an excellent approach for myectomy, as well as for the relief of the intraventricular gradient and associated symptoms without any complications related to the apical incision were observed with a five-year survival similar to that expected in the general population (95% vs. 97%).

## CONFLICTS OF INTEREST

The authors declare no conflicts of interest.

## FUNDING SOURCE

None.

## REFERENCES

1. Falicov RE, Renekov L, Bharaki S, Lev M. Mid-ventricular obstruction: a variant of obstructive cardiomyopathy. *Am J Cardiol.* 1976;37(3):432-7.
2. Song H, Zhao C, Jinfa J, Yang L, Chen Y. Mid-ventricular hypertrophic obstructive cardiomyopathy (MVHOCM) complicated with coronary artery disease: a case report. *J Geriatr Cardiol.* 2008;5(3):190-2.
3. Noureldin RA, Liu S, Nacif MS, Judge DP, Halushka MK, Abraham TP, et al. The diagnosis of hypertrophic cardiomyopathy by cardiovascular magnetic resonance. *J Cardiovasc Magn Reson.* 2012;14:17.
4. Efthimiadis GK, Pagourelis ED, Parcharidou D, Gossios T, Kamperidis V, Theofilogiannakos EK, et al. Clinical characteristics and natural history of hypertrophic cardiomyopathy with midventricular obstruction. *Circ J.* 2013;77(9):2366-74.
5. Sato Y, Matsumoto N, Matsuo S, Yoda S, Kunitomo S, Saito S. Mid-ventricular hypertrophic obstructive cardiomyopathy presenting with acute myocardial infarction. *Tex Heart Inst J.* 2007;34(4):475-8.
6. Watanabe H, Kibira S, Saito T, Shimizu H, Abe T, Nakajima I, et al. Beneficial effect of dual-chamber pacing for a left midventricular obstruction with apical aneurysm. *Circ J.* 2002;66(10):981-4.
7. Tengiz I, Ercan E, Turk UO. Percutaneous myocardial ablation for left mid-ventricular obstructive hypertrophic cardiomyopathy. *Int J Cardiovasc Imaging.* 2006;22(1):13-8.
8. Seggewiss H, Faber L. Percutaneous septal ablation for hypertrophic cardiomyopathy and mid-ventricular obstruction. *Eur J Echocardiogr.* 2000;1(4):277-80.
9. Kunkala MR, Schaff HV, Nishimura RA, Abel MD, Sorajja P, Dearani JA, et al. Transapical approach to myectomy for midventricular obstruction in hypertrophic cardiomyopathy. *Ann Thorac Surg.* 2013;96(2):564-70.