

# Mobility of the *Septum Primum* Does Not Depend on the Foramen Ovale Diameter in Normal Fetuses

Paulo Zielinsky, Marcelo Sallum, Fabíola Satler, Eduardo Ioschpe Gus, Luiz Henrique Nicoloso, João Luiz Mânica, Antônio Luiz Piccoli Jr  
Porto Alegre, RS - Brazil

## Objective

To test the hypothesis that a correlation exists between the maximum foramen ovale diastolic diameter and the excursion index (EI) of the septum primum in normal fetuses.

## Methods

One hundred and two normal fetuses with gestational ages ranging from 20 to 40 weeks were submitted to echocardiography. The foramen ovale diameter and the "maximal excursion" of the septum primum were measured in a 4-chamber view. The data were analyzed by Pearson's correlation coefficient.

## Results

The mean foramen ovale (FO) diameter was  $5.06 \pm 1.29$  mm; the maximal excursion of the septum primum was  $5.42 \pm 1.41$  mm; the left atrium diameter  $11.47 \pm 2.76$  mm; the septum primum "excursion index" was  $0.48 \pm 0.09$ . Mean FO/EI ratio was  $11.35 \pm 3.94$  mm. No FO/EI correlation ( $r = -0.03$ ) existed, and a weak foramen ovale/left atrium correlation ( $r = 0.31$ ) was observed, as well as a weak foramen ovale/excursion of septum primum correlation ( $r = 0.21$ ).

## Conclusion

Septum primum mobility does not depend on the foramen ovale diameter in normal fetuses, suggesting that the modifications of its diastolic displacement is not influenced by the size of the interatrial opening.

## Key words

fetal echocardiography, foramen ovale, septum primum, ventricular diastolic function

In fetal life, the *septum primum* acts as a valve to close the foramen ovale when atrial contraction occurs. In diastole, it protrudes within the left atrium, enabling maximal opening and flow from right to left. This protrusion is used as a reference to identify the left atrium (LA) in fetal echocardiography<sup>1,2</sup>.

In previous studies, the mobility of the *septum primum*, its involvement during intrauterine life<sup>3</sup>, and its correlation with the presence of atrial extrasystoles<sup>4,5</sup> were assessed. To quantify the excursion of the *septum primum* during the cardiac cycle, an index that correlates its maximal excursion with the left atrium diameter was created, the so-called "excursion index" (EI).

A previous study<sup>6</sup> showed that the excursion index is decreased in fetuses with ventricular septal hypertrophy secondary to maternal diabetes after 32 weeks of gestational age. An inverse correlation was present between the excursion index and interventricular septal thickness, suggesting that the excursion index could be used as a more suitable index for ventricular diastolic function than those usually accepted, since it was shown a more accurate inverse correlation with interventricular septal hypertrophy than the atrio-ventricular flows.

Another previous study has already demonstrated that, during fetal breathing, the excursion index of the *septum primum* is significantly increased; this finding was explained by an increase in left ventricular distensibility due to respiratory movements<sup>7</sup>.

Therefore, excursion of the *septum primum* depends on multiple factors, and its correlation with the foramen ovale size has not been studied. The present study was designed to test the hypothesis that a correlation exists between the foramen ovale diameter and the maximal excursion of the *septum primum* in normal fetuses.

## Methods

This was a noncontrolled, transversal study, assessing 102 fetuses without structural or functional abnormalities of the heart; mothers had no risk factors for heart disease. Fetal echocardiography being performed sequentially from 20 weeks of gestation through term, in a specialized center of Fetal Cardiology.

We excluded from the study fetuses with anatomical or functional abnormalities of the heart or any other organs and systems; fetuses whose mothers had systemic disease or risk factors for fetal heart disease; those in which it was impossible to obtain a suitable echocardiographic window; and gestational age below 20 weeks.

Instituto de Cardiologia do Rio Grande do Sul/Fundação Universitária de Cardiologia

Mailing address: Paulo Zielinsky – IC/FUC - Av. Princesa Isabel, 395 – 90620-001- Porto Alegre, RS – Brazil

e-mail: pesquisa@cardnet.tche.br

Received for publication: 8/11/2003

Accepted for publication: 1/26/2004

Fetal echocardiographic examinations were obtained following the segmental sequential approach<sup>8,9</sup>, starting at the maternal umbilical region, and using the fetal dorsal spine, liver, and *septum primum* as anatomic references. Atrial *situs* was determined, together with heart position in the chest, type and mode of atrio-ventricular and ventriculoarterial connections, aortic arch, and associated defects.

ACUSON models XP-10 and ASPEN echocardiographic equipments were used for two-dimensional images, with a 4 to 7 MHz convex transducer or a 2.25 to 5 MHz *phased array* transducer.

The excursion index (EI) of the *septum primum* was determined from the following measures obtained at a 4-chamber view: A) maximal excursion of the *septum primum* towards the interior of the LA; B) maximum LA diastolic diameter. The ratio between A and B expresses EI (fig. 1).

The foramen ovale diameter was measured in a 4-chamber view, at the end of diastole. This parameter was obtained using the electronic cursor of the equipment, and the largest distance between the free edges of the interatrial septum was considered (fig. 2).

Pearson's correlation coefficient was established between the

foramen ovale diameter and the "excursion index" of the *septum primum*. The correlation coefficient between the foramen ovale and the maximum excursion of the *septum primum*, as well as left atrial diameter, were calculated as well.

This research was approved by the Ethical Committee in Medical Research of the institution, and all the patients gave their written informed consent. The standard Research Unit form was used to ensure data confidentiality.

## Results

Mean maternal age was  $26.26 \pm 6.18$  years. Gestational age ranged from 20 to 40 weeks (mean  $29.45 \pm 4.15$  weeks).

Figure 3A shows the variation in the foramen ovale diameter among the 102 fetuses studied. The mean diameter was  $5.06 \pm 1.29$  mm.

Values of the maximal excursion of the *septum primum* are displayed in figure 3B. The mean value obtained was  $5.42 \pm 1.41$  mm.

Figure 3C represents the maximal left atrium diastolic diameter of fetuses. The mean value obtained was 11.47 mm, with a 2.76 mm standard deviation.

The mean value of the excursion index of the *septum primum* in the 102 fetuses was  $0.48 \pm 0.09$ , according to figure 3D.

The Pearson's correlation coefficient between the foramen ovale diameter and the excursion index of the *septum primum* was  $-0.03$  (fig. 4A).

The correlation coefficient between the foramen ovale size and the maximal left atrium diameter was 0.31. The correlation between the foramen ovale diameter and the excursion of the *septum primum* was 0.21 (fig. 4B and 4C).

## Discussion

In human embryology, the development of the cardiac septum represents a continuous system of protrusions together with the development of the external forms of cardiac walls. The free edges grow toward each other until they merge<sup>10</sup>. Septation of the two atria starts when the *septum primum* begins to grow from the posterior/superior portion of the common cavity of the wall, towards the atrioventricular junctions, where the developing endocardial cushions are separating atria and ventricles<sup>11</sup>. The *septum primum* is a thin structure with fenestrations in its medium portion, which partially separates the two atria. The low portion of the *septum primum* merges with the tissue from the endocardial cushions<sup>12</sup>. Later, *septum secundum* is developed, parallel and towards the right of the anterior. It starts in the posterior/superior region of the atrial wall and grows toward the atrioventricular junction. It has a semilunar edge with a hollow anterior/inferior portion, and it only partially covers the central hole of the *septum primum*. This edge forms the *crista dividens* of the fetal heart. The space between the *crista dividens* and the free edges of the *septum primum* is called the foramen ovale. This hole will only close after birth, through apposition of these two structures<sup>13</sup>.

The foramen ovale is important because of the decreased intrauterine pulmonary blood circulation. Most of the blood flow reaching the fetal heart comes from the right atrium, and then

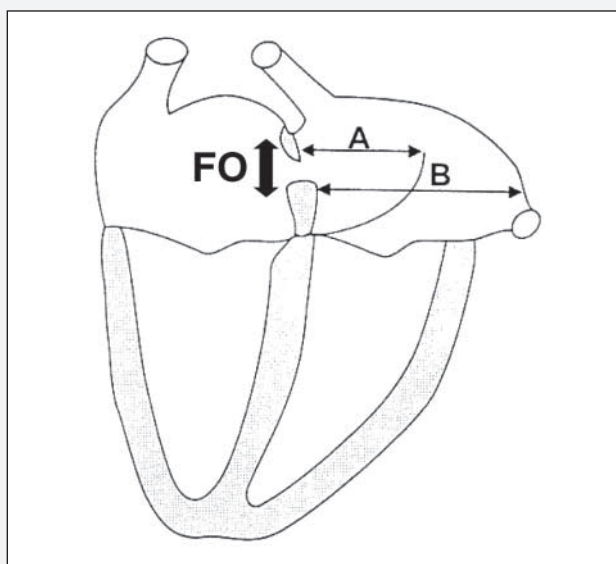


Fig. 1 – Picture of a 4-chamber view. FO- foramen ovale diameter; A- maximal excursion of the *septum primum*. B- maximal diameter of the left atrium.

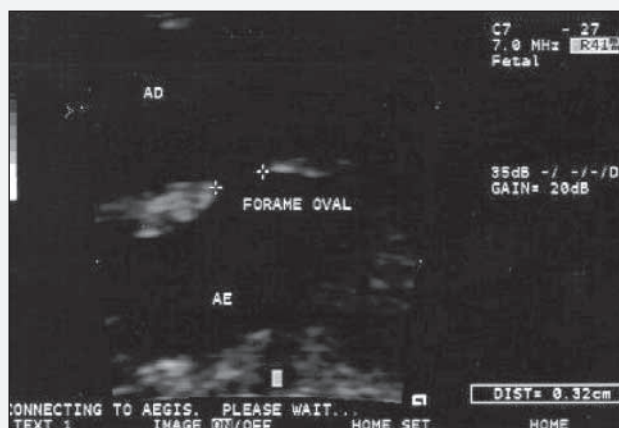


Fig. 2 - Echocardiographic image of a 4-chamber view, demonstrating how to obtain foramen ovale diameter and locate the *septum primum*.

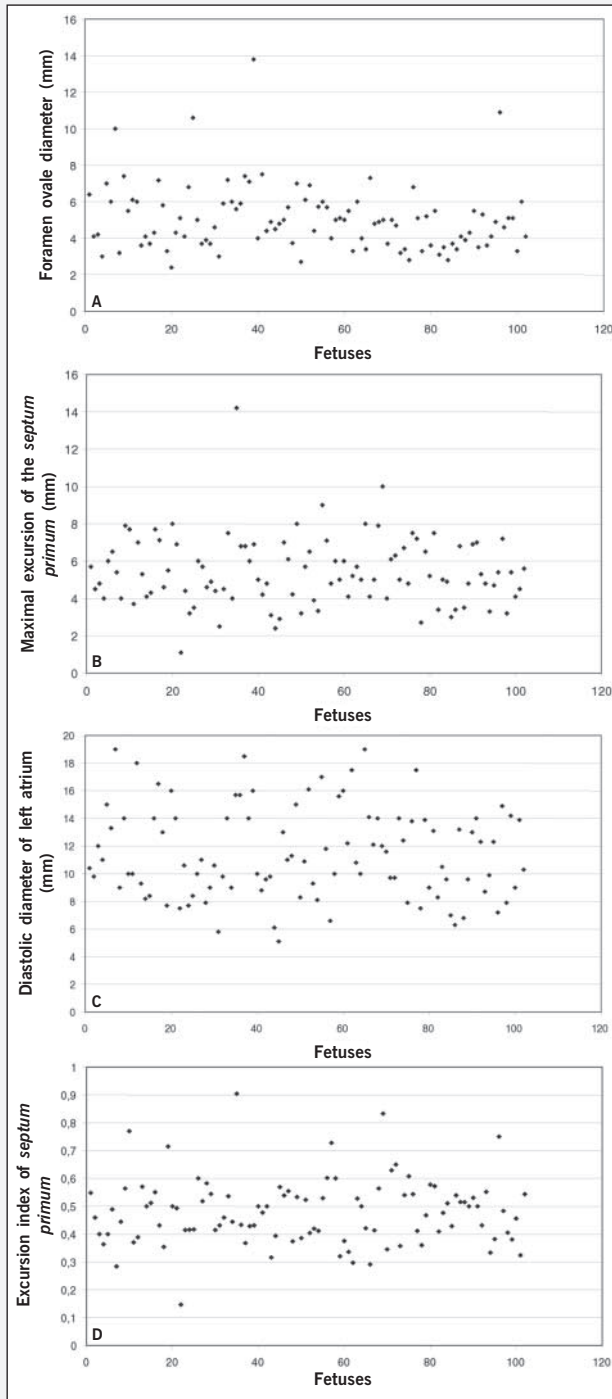


Fig. 3 – Echocardiographic fetuses of the sample. A) foramen ovale diameter; B) maximal excursion of the *septum primum*; C) diastolic diameter of left atrium; D) excursion index of *septum primum*.

from this structure part of the blood reaches the left atrium, joining the blood flow that returns through the pulmonary veins.

The literature has already studied the foramen ovale diameter, and suggests that it is approximately equal to the aortic diameter<sup>14</sup> or slightly smaller<sup>15,16</sup>. A restrictive foramen ovale (diameter < 2mm of maximum opening)<sup>17,18</sup> has been associated with left ventricular hypoplasia, interatrial septum congenital aneurysms, supraventricular fetal tachycardia, and intrauterine heart failure<sup>19,20</sup>.

Knowledge of the fetal cardiac circulatory dynamics has improved in recent years, with constant addition of new concepts. This study has tested the hypothesis that changes in the excursion of

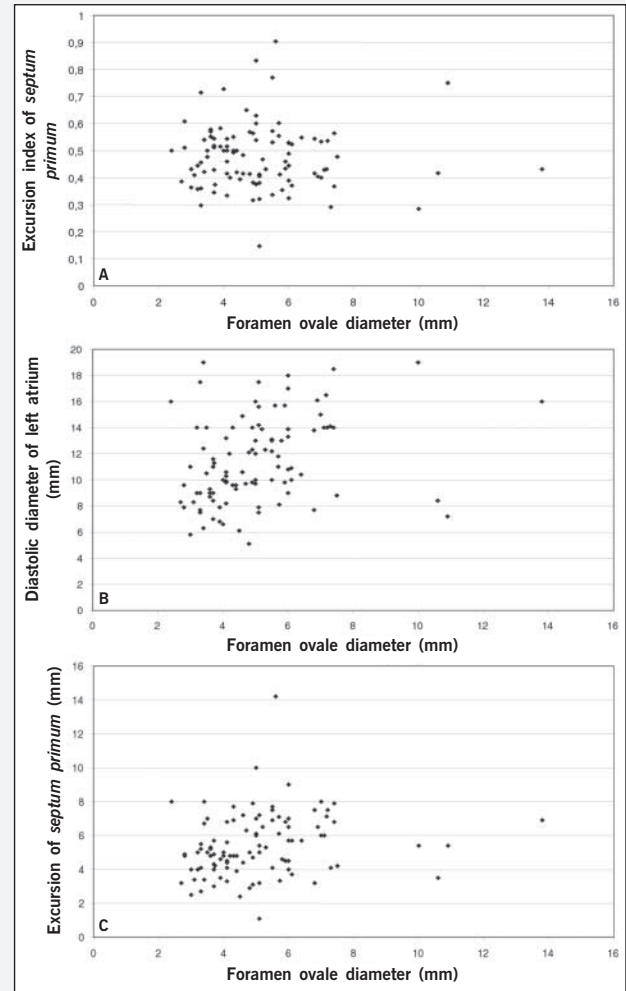


Fig. 4 – Correlation of foramen ovale diameter, and other echocardiographic parameters: A) FO/EI ratio; B) FO/LA ratio; C) FO/excursion ratio.

the *septum primum*, which correlates with alterations in left ventricle compliance and/or relaxation, could also be influenced by the foramen ovale diameter, which is the link between the two sides of the heart.

However, the results obtained in the present study demonstrated that no correlation exists between foramen ovale diameter and the excursion index of the *septum primum*. A weak correlation between the foramen ovale diameter and the maximal left atrium diameter, as well as the foramen ovale diameter and the excursion of the *septum primum* was observed, although not clinically significant.

Previous studies have demonstrated that *septum primum* mobility is influenced by left ventricle diastolic function, both in a model with a decrease in compliance (left myocardial hypertrophy)<sup>6</sup> and in a model with an increase in ventricular compliance (fetal breathing)<sup>3</sup>. A possible confusion bias could be represented by the foramen ovale diameter, thus prompting the present investigation. Positioning of the foramen ovale edges observed in the same moment of the cardiac cycle, according to measures described in the literature<sup>14-16</sup>, should minimize the possible limitations of measuring the foramen ovale in the cross-sectional echocardiographic image.

This study is a step in the research line aiming at studying left ventricle diastolic function in fetuses. Studies performed with flow



velocity through the foramen ovale, already under way and not part of this study, have proven to be useful to quantify left ventricular compliance in fetuses with myocardial hypertrophy.

In conclusion, data from the present study suggest that alterations in diastolic excursion of the septum primum do not depend on the level of interatrial opening in normal fetuses.

## References

- Friedman AH, Copel JA, Kleinman CS. Fetal echocardiography and fetal cardiology: indications, diagnosis and management. *Semin Perinatal* 1993; 17: 76-88.
- Kachalia P, Bowie JD, Adams DB, Carrol BA. In utero sonographic appearance of the atrial septum primum and septum secundum. *J Ultrasound Med* 1991; 10: 423-6.
- Firpo C, Zielinsky P. Mobility of the flap valve of the primary atrial septum in the developing human fetus. *Cardiol Young* 1998; 8: 67-70.
- Zielinsky P, Firpo C, Martha VF, Silva ES. Estudo ecocardiográfico pré-natal da redundância do septum primum e sua relação com a gênese de extra-sístoles atriais no feto. *Arq Bras Cardiol* 1995; 65: 153-7.
- Zielinsky P, Firpo C, Martha VF, Silva ES. Papel da membrana da fossa oval no desencadeamento de arritmias cardíacas fetais. *Revista Brasileira de Ginecologia e Obstetria* 1995; 17: 711-9.
- Firpo C. Medidas ecocardiográficas, fluxos atrioventriculares e mobilidade do septum primum: modificações evolutivas e implicações funcionais em fetos normais e de mães diabéticas [Tese de doutorado]. UFRGS, Departamento de Pediatria: Porto Alegre, 2000.
- Miyague NI, Ghidini A, Miyague LLT. Fetal breathing movements are associated with changes in compliance of the left ventricle. *Fetal Diagn Ther* 1997; 12: 72-5.
- Zielinsky P. Abordagem diagnóstica e terapêutica pré-natal das anormalidades cardíacas fetais. *Revista Brasileira de Ecocardiografia* 1992; 17: 10-25.
- Zielinsky P, Haertel JC, Lucchese F. Abordagem seqüencial das cardiopatias congênitas: um enfoque ecocardiográfico bidimensional. *Arq Bras Cardiol* 1985; 45: 129-44.
- Steding G, Seidl W. Contribution to the development of the heart. Part I: normal development. *Thorac Cardiovasc Surg* 1980; 28: 386-409.
- Rudolph AJ. *Congenital Heart Disease of the Heart*. Chicago: Year Book Medical Publishers Inc; 1974.
- Fonollá AJP, Llorca FO. Origin and development of the septum primum. *Acta Anat* 1978; 100: 250-7.
- Wenink ACG. Embryology of the heart. In: Anderson RH, Macartney FJ, Shinebourne EA, Thynan M. *Paediatric Cardiology*. Edinburgh: Churchill Livingstone, 1987; 4: 83-107.
- Wilson AD, Rao PS, Aeschlimann S. Normal fetal foramen flap and transatrial Doppler velocity pattern. *J Am Soc Echo* 1990; 3: 491-4.
- Walther FJ, Benders MJ, Leighton JO. Early changes in the neonatal circulatory transition. *J Pediatr* 1993; 123: 625-32.
- Phillipps EZ, Robertson MA, Still KD. The echocardiographic assessment of the human fetal foramen ovale. *J Am Soc Echocardiogr* 1994; 7: 257-63.
- Buis-Liem TN, Ottenkamp J, Meerman RH, Verwey R. The concurrence of fetal supraventricular tachycardia and obstruction of the foramen ovale. *Prenat Diagn* 1987; 7: 425-31.
- Sahn DJ. Doppler echocardiographic and flow-mapping studies in the human fetus. *Echocardiography* 1989; 6: 119-23.
- Naeye RL, Blanc WA. Prenatal narrowing or closure of the foramen ovale. *Circulation* 1964; 30: 736-42.
- Zielinsky P, Dillenburger RF, Zimmer LP. Forame oval restritivo: uma causa de insuficiência cardíaca fetal. *Revista Brasileira de Ecocardiografia* 1996; 25: 12-5.

**Citalor®** (atorvastatina cálcica) é um agente hipolipemiante que diminui os níveis plasmáticos de colesterol e lipoproteínas através da inibição da HMG-CoA redutase e da síntese de colesterol no fígado, ampliando o número de receptores de LDL hepáticos na superfície da célula, o que aumenta a absorção e o catabolismo do LDL. **Indicações:** para a redução de níveis elevados de colesterol total, LDL-colesterol, apolipoproteína B e triglicérides em pacientes com hipercolesterolemia primária e hiperlipidemia combinada (mista); para o tratamento de pacientes com níveis elevados de triglicérides séricos e de pacientes com disbetilipoproteinemia que não respondem de forma adequada à dieta; também é indicado para a redução do colesterol total e do LDL-colesterol em pacientes com hipercolesterolemia familiar homozigótica, quando a resposta à dieta e outras medidas não-farmacológicas forem inadequadas; em paciente com doença cardiovascular e/ou dislipidemia, está indicado na Síndrome Coronária Aguda, para a prevenção secundária do risco combinado de morte, infarto do miocárdio não-fatal, parada cardíaca e re-hospitalização de paciente com angina do peito (estudo MIRACL – *Myocardial Ischemia Reduction with Aggressive Cholesterol Lowering*). **Contra-indicações:** hipersensibilidade a qualquer componente de sua fórmula; doença hepática ativa ou elevações persistentes inesperadas das transaminases séricas que excedam em 3 vezes o limite superior da normalidade; durante a gravidez ou a lactação; mulheres em idade fértil que não estejam utilizando medidas contraceptivas eficazes. **Advertências e precauções:** os pacientes devem ser aconselhados a relatar imediatamente a ocorrência inexplicável de dor muscular, alterações da sensibilidade ou fraqueza muscular, principalmente se forem acompanhadas de mal-estar ou febre. Testes de função hepática devem ser realizados antes do início do tratamento e, periodicamente, durante o tratamento. Pacientes que desenvolverem quaisquer sinais ou sintomas sugestivos de danos hepáticos devem ser monitorados até que a anormalidade se resolva. Se um aumento de AST e ALT (TGO e TGP) maior que 3 vezes o limite superior da normalidade persistir, recomenda-se a redução da dose ou a descontinuação do tratamento. Citalor® deve ser utilizado com precaução por pacientes que consomem quantidades apreciáveis de álcool e/ou apresentam história de doença hepática. O tratamento deve ser descontinuado no caso de ocorrência de níveis consideravelmente elevados de CPK ou de diagnóstico ou suspeita de miopatia. O tratamento deve ser interrompido temporariamente ou descontinuado em qualquer paciente com uma condição séria e aguda sugestiva de miopatia ou que apresente um fator de risco que o predisponha ao desenvolvimento de insuficiência renal secundária à rhabdomiólise. **Interações medicamentosas:** antiácidos (com hidróxido de magnésio e de alumínio), colestipol, digoxina, eritromicina/claritromicina, contraceptivos orais e inibidores da protease. **Reações adversas:** constipação, flatulência, dispepsia, dor abdominal, cefaléia, náusea, mialgia, astenia, diarreia e insônia. **Posologia:** as doses podem variar de 10 a 80 mg, em dose única diária, que pode ser administrada a qualquer hora do dia, com ou sem alimentos. As doses inicial e de manutenção devem ser individualizadas de acordo com os níveis basais de LDL-colesterol, o objetivo do tratamento e a resposta do paciente. Após o início do tratamento e/ou durante o ajuste de dose de atorvastatina, os níveis lipídicos devem ser analisados dentro de 2 a 4 semanas e a dose deve ser ajustada adequadamente. **Hipercolesterolemia primária e hiperlipidemia combinada (mista):** a maioria dos pacientes é controlada com 10 mg de atorvastatina em dose única diária. **Hipercolesterolemia familiar homozigótica:** a maioria dos pacientes respondeu a 80 mg de atorvastatina com uma redução maior que 15% no LDL-colesterol (18%-45%). A experiência no tratamento de pacientes pediátricos (com doses de atorvastatina de até 80 mg/dia) é limitada. **Superdosagem:** o paciente deve receber tratamento sintomático e, conforme a necessidade, devem ser instituídas medidas de suporte. Devido à alta ligação às proteínas plasmáticas, a hemodiálise não deve aumentar a depuração da atorvastatina significativamente. **Apresentações:** comprimidos revestidos de 10 mg, 20 mg, 40 mg e 80 mg em embalagens com 30 unidades. **USO ADULTO. VENDA SOB PRESCRIÇÃO MÉDICA.** Para maiores informações, consulte a bula completa do produto (cit08a). Documentação científica e informações adicionais estão à disposição da classe médica mediante solicitação. Laboratórios Pfizer Ltda., Rua Alexandre Dumas, 1860 – Chácara Santo Antônio, São Paulo, SP – CEP 04717-904. Tel.: 0800-16-7575 – Internet: www.pfizer.com.br. **Citalor® Reg. MS - 1. 0216.0062**