

UNIVERSIDADE FEDERAL DO RIO GRANDE DO SUL  
FACULDADE DE ODONTOLOGIA  
PROGRAMA DE PÓS-GRADUAÇÃO EM ODONTOLOGIA

LUIS ERNESTO ARRIOLA GUILLÉN

**ESTUDO LONGITUDINAL RETROSPECTIVO SOBRE A REABSORÇÃO  
RADICULAR DE INCISIVOS MAXILARES APÓS A TRAÇÃO DE CANINOS  
IMPACTADOS COM MOLAS HELICOIDAIS**

Porto Alegre

2019

LUIS ERNESTO ARRIOLA GUILLÉN

**ESTUDO LONGITUDINAL RETROSPECTIVO SOBRE A REABSORÇÃO  
RADICULAR DE INCISIVOS MAXILARES APÓS A TRAÇÃO DE CANINOS  
IMPACTADOS COM MOLAS HELICOIDAIS**

Tese apresentada ao Programa de Pós-Graduação em Odontologia, linha de pesquisa Diagnóstico das Afecções Buco- Faciais, da Universidade Federal do Rio Grande do Sul, como parte dos pré-requisitos necessários para a obtenção do título de Doutor em Clínica Odontológica.

Orientador: Prof. Dr. Heraldo Luís Dias da Silveira

Porto Alegre

2019

### CIP - Catalogação na Publicação

Arriola Guillén, Luis Ernesto  
Estudo longitudinal retrospectivo sobre a  
reabsorção radicular de incisivos maxilares após a  
tração de caninos impactados com molas helicoidais /  
Luis Ernesto Arriola Guillén. -- 2019.  
61 f.  
Orientador: Heraldo Luis Dias da Silveira.

Tese (Doutorado) -- Universidade Federal do Rio  
Grande do Sul, Faculdade de Odontologia, Programa de  
Pós-Graduação em Odontologia, Porto Alegre, BR-RS,  
2019.

1. Reabsorção da raiz. 2. Dente impactado. 3. Dente  
canino. 4. Tomografia computadorizada de feixe cônico.  
I. Silveira, Heraldo Luis Dias da, orient. II.  
Título.

Elaborada pelo Sistema de Geração Automática de Ficha Catalográfica da UFRGS com os  
dados fornecidos pelo(a) autor(a).

*“Por seus frutos você os conhecerá”.*

*“Pois não há nada oculto que não seja revelado, e não há nada oculto que permaneça não descoberto”.*

*“Acumule tesouros no céu onde as coisas não perdem valor. Pois, onde está seu tesouro, aí também estará seu coração”.*

*Jesús de Nazaret*

## Agradecimentos

---

A **Deus**, por ser meu pai e meu apoio nos momentos mais difíceis da minha vida.

À minha esposa **Claudia** por me apoiar em alcançar todos os meus sonhos.

Aos meus pais, **Pio Luis e María Haydeé** por me ensinarem a ser perseverante e porque a minha alegria é a deles.

Aos meus filhos, **Luis Eduardo e Nicolás Alejandro** por existirem e iluminarem minha vida.

Ao meu orientador, Prof Dr **Heraldo Luis Dias da Silveira**, por sua amizade, respeito e ensinamentos.

Para **Gustavo e Yalil** por serem meus grandes amigos e irmãos.

À coordenação e professores do **Programa de Pós-Graduação da FO-UFRGS**.

## Resumo

---

**Introdução:** O tratamento de caninos superiores impactados (CSI) deveria ser realizado visando sua manutenção, permitindo o desenvolvimento adequado da bossa canina. Entretanto, a reabsorção radicular, como um efeito colateral do tratamento ortodôntico, pode ser maior nessa situação. Os objetivos desse trabalho foram: 1. Comparar a reabsorção radicular de incisivos superiores após tração ortodôntica unilateral e bilateral de CSI com molas helicoidais; 2. Determinar a influência da complexidade do tratamento de tração do CSI na reabsorção radicular de incisivos superiores; e 3. Avaliar, por meio de sobreposição volumétrica, a reabsorção radicular de incisivos superiores, antes e após a tração de CSI bicorticalmente. **Metodologia:** Foi realizado um estudo longitudinal e retrospectivo, com amostra constituída de 60 exames de tomografia computadorizada de feixe cônico (TCFC) de pacientes com CSI, 30 antes e 30 depois da tração dos caninos com molas helicoidais. Para o primeiro objetivo, os exames foram divididos em dois grupos, 15 com impacção unilateral e 15 bilateral. Para o segundo objetivo, foram formados dois grupos, de acordo com a complexidade do tratamento ortodôntico, sendo 20 casos não-complexos e 25 complexos. Foram obtidos história clínica, modelos de estudo e radiografias para cada paciente. Um ortodontista treinado e calibrado realizou as mensurações. Variáveis demográficas, características oclusais, padrão esquelético e medidas relacionadas aos CSI foram obtidas tridimensionalmente. Para o terceiro objetivo, foram selecionados três casos em que foram avaliados as raízes dos incisivos superiores por meio da sobreposição volumétrica tridimensional usando um mapa de cores. **Conclusões:** Reabsorção radicular de incisivos superiores após tração de CSI com molas helicoidais foi semelhante, independente de condição uni ou bilateral ou complexidade da localização do CSI e principalmente esteve localizado no terço radicular apical.

**Palavras-chave:** Reabsorção da raiz; dente impactado; dente canino; tomografia computadorizada de feixe cônico.

## Abstract

---

**Introduction:** Maxillary canine impaction (MIC) treatment should always maintain this tooth and allowing the development of canine eminence. However, the root resorption as a side effect of orthodontic treatment may be increased in this condition. The aims of this thesis were 1. To compare the root resorption of maxillary incisors after traction with coil springs of unilateral versus bilateral MIC. 2. To determine the influence of the complexity of the orthodontic treatment of MIC on the root resorption of incisors. 3. To evaluate, through of volumetric superimposition, the root resorption of maxillary incisors before and after traction of bicortically MIC located in a complex position.

**Methods:** This study was longitudinal and retrospective, the sample included 60 Cone Beam Computed Tomographies (CBCTs) of patients with MIC, 30 before and 30 after traction of canines with coil springs. For the first objective two groups were conformed according to impaction condition, 15 with unilateral and 15 with bilateral MIC. For the second objective also two groups were conformed according to complexity of the orthodontic treatment, 20 non-complex cases and 25 complex cases. For the third objective 5 bicortically MIC were evaluated before and after treatment as a series of three cases. For the three objectives clinical histories, plasters and radiographs were obtained of each patient. A trained and calibrated orthodontist made the measurements. Demographic variables, occlusal characteristics, skeletal pattern and measures related to MIC were measured three-dimensionally; specifically, the root resorption (millimeters and area) in each maxillary incisor and for the third objective a volumetric 3D superimposition was used.

**Conclusions:** Root resorption of maxillary incisors after traction of MIC with coil springs was similar between unilateral or bilateral cases or located in a complex or non-complex position and mainly was located in the radicular apex.

**Keywords:** Root resorptions; impacted tooth; canine tooth; cone beam CT

## Lista de Abreviaturas e Siglas

---

<b>CSI</b>	Caninos superiores impactados
<b>TCFC</b>	Tomografia computadorizada de feixe cônico
<b>MIC</b>	<i>Maxillary impacted canine</i>
<b>CBCT</b>	<i>Cone Beam Computed Tomography</i>
<b>ANB</b>	<i>Angle ANB (A point, Nasion point, B point)</i>
<b>APDI</b>	<i>Antero Posterior Dysplasia Indicator</i>
<b>SNA</b>	<i>Angle SNA (Sella point, Nasion point, A point)</i>
<b>PNS-ANS</b>	<i>Posterior Nasal Spine – Anterior Nasal Spine</i>
<b>ULLI</b>	<i>Upper Left Lateral Incisor</i>
<b>ULCI</b>	<i>Upper Left Central Incisor</i>
<b>URCI</b>	<i>Upper Right Central Incisor</i>
<b>URLI</b>	<i>Upper Right Lateral Incisor</i>
<b>T<sub>0</sub></b>	<i>Initial time, Before canine traction</i>
<b>T<sub>1</sub></b>	<i>After canine traction</i>
<b>SPSS</b>	<i>Statistical Package for Social Sciences</i>



## Sumário

---

Introdução	09
Objetivos	12
Artigo 1	13
Artigo 2	26
Artigo 3	39
Considerações Finais	54
Referências	55
Anexo 1	58
Anexo 2	59
Anexo 3	60
Anexo 4	61

## Introdução

---

O tratamento dos caninos superiores impactados é um dos procedimentos mais complexos e laboriosos a serem realizados na prática ortodôntica [1,2], pois podem estar localizados em diferentes posições de impactação até mesmo junto aos incisivos centrais [3]. O mesmo em relação à sua angulação varia da verticalidade à horizontalidade [3-5].

A etiologia dos caninos impactados por palatino está relacionada a duas teorias, uma genética e outra relacionada à alteração no guia de erupção dos incisivos laterais permanentes, incluindo uma variante anatômica relacionada ao pequeno tamanho delas ou mesmo à sua agenesia [6-16]. Embora também uma retenção prolongada do canino decíduo pudesse gerar impacto [6,11]. Em relação aos caninos com impactação vestibular, as investigações relatam uma associação com um comprimento deficiente do arco maxilar [17,18].

O tratamento dos caninos superiores impactados envolve a aplicação específica da biomecânica ortodôntica, que poderia aumentar a reabsorção radicular dos dentes vizinhos. A posição da impactação determinará a complexidade do tratamento, o tempo total de tratamento e a possibilidade de reabsorção apical dos incisivos superiores produzidos pelos movimentos ortodônticos [1]. Para puxar um canino maxilar impactado em direção ao plano de oclusão, ou com molas de níquel-titânio [19], cadeias de poder ou alguma modificação de fios para tração [20], é necessário aplicar forças maiores que as aplicadas nos dentes não impactados [3]; Além disso, essas forças de tração geralmente são suportadas por um arco de aço de grande calibre localizado nos suportes dos dentes superiores, que às vezes servem como ancoragem de elásticos intermaxilares, tentando evitar os efeitos secundários

da tração, como a intrusão dos dentes vizinhos, ou também, métodos que incluem uma grande âncora com um pesado botão de ATP e Nance e projeções de fios para puxar o canino são empregados. Em geral, o tratamento ortodôntico de caninos impactados dura aproximadamente 6 meses a mais do que o tratamento convencional em dentes sem impactação [1, 21], mas apenas o movimento de tração envolve forças que poderiam gerar a possibilidade de maior reabsorção apical principalmente dos incisivos superiores.

Evidências sugerem que o tratamento ortodôntico exaustivo causa um aumento na incidência e gravidade da reabsorção radicular, e que forças pesadas podem ser particularmente prejudiciais [22-26]. Os incisivos laterais são os dentes mais expostos ao produto de reabsorção apical de um tratamento ortodôntico, devido à sua fina raiz cônica que frequentemente apresenta algum dilaceramento [22,23,27]. É relatada uma reabsorção apical leve de incisivos laterais (<1mm) em aproximadamente 56% dos casos, e reabsorções graves (mais de 4mm) em 2% dos casos após da realização de um tratamento ortodôntico convencional que não inclui trações dentárias impactadas [27,28]. Esses números podem aumentar em tratamentos que envolvem a desimpactação de caninos superiores. O objetivo deste trabalho foi comparar longitudinalmente a reabsorção radicular dos incisivos superiores após a tração de caninos impactados com molas helicoidais e uma ancoragem pesada.

Este artigo tenta testar três hipóteses nulas: 1, que não há diferença significativa no comprimento e área de reabsorção radicular dos incisivos superiores após a tração ortodôntica dos caninos bilaterais versus unilaterais. 2, que não há diferença significativa no comprimento e área de reabsorção radicular dos incisivos superiores após a tração ortodôntica dos caninos retidos com diferentes níveis de complexidade. 3, que não há diferença significativa na sobreposição volumétrica da reabsorção

radicular dos incisivos superiores antes e após a tração dos caninos com impactação bicortical, localizados em uma posição complexa.

## Objetivos

---

### **Geral**

Comparar longitudinalmente a reabsorção radicular dos incisivos superiores após a tração de caninos impactados com molas helicoidais e uma ancoragem pesada.

### **Específicos**

- a. Comparar a quantidade de reabsorção radicular em milímetros e área dos incisivos superiores após tração ortodôntica de caninos unilaterais versus bilaterais com molas helicoidais, por meio de TCFC (Artigo 1).
- b. Determinar a influência da complexidade do tratamento ortodôntico dos caninos superiores impactados na reabsorção radicular dos incisivos (mm e mm<sup>2</sup>) por meio de TCFC (Artigo 2).
- c. Avaliar, por meio da sobreposição volumétrica, a reabsorção radicular dos incisivos superiores antes e após a tração dos caninos impactados bicorticamente e localizados em uma posição complexa (Artigo 3).

## Root resorption of maxillary incisors after traction of unilateral vs bilateral impacted canines with reinforced anchorage

Luis Ernesto Arriola-Guillén, Gustavo Armando Ruíz-Mora, Yalil Augusto Rodríguez-Cardenas, Aron Aliaga-Del Castillo, and Heraldo Luis Dias-Da Silveira

Publicado no ***American Journal of Orthodontics & Dentofacial Orthopedics***

*November 2018. Vol 154. Issue 5*

DOI: <https://doi.org/10.1016/j.ajodo.2018.01.015>

# Root resorption of maxillary incisors after traction of unilateral vs bilateral impacted canines with reinforced anchorage

Luis Ernesto Arriola-Guillén,<sup>a</sup> Gustavo Armando Ruíz-Mora,<sup>b</sup> Yalil Augusto Rodríguez-Cárdenas,<sup>c,d</sup> Aron Aliaga-Del Castillo,<sup>e</sup> and Heraldo Luis Dias-Da Silveira<sup>f</sup>  
*Lima, Perú Bogotá, Colombia, and Bauru, São Paulo, and Porto Alegre, Rio Grande do Sul, Brazil*

**Introduction:** The aim of this study was to compare the root resorption (RR) of maxillary incisors after traction of unilateral vs bilateral impacted canines with reinforced anchorage. **Methods:** This retrospective longitudinal study included 60 cone-beam computed tomography scans of patients with maxillary impacted canines: 30 scans taken before and 30 taken after orthodontic traction with nickel-titanium coil springs. Two groups were formed according to the impaction condition: 15 with unilateral maxillary impacted canines and 15 with bilateral maxillary impacted canines. Three trained orthodontists made the measurements. Demographic variables, occlusal characteristics, skeletal class, and measurements related to canine impaction were collected from the clinical history, dental models, and radiographs of each patient. RR (mm and mm<sup>2</sup>) for each maxillary incisor was measured in 3 dimensions. Independent *t* or Mann-Whitney U tests were used, depending on data normality. Multiple linear regression analyses were used to evaluate the influence of all variables (predictors) on RR ( $\alpha$  5 0.05). **Results:** RR did not show significant differences between groups in any section ( $P$ . 0.05). No subject had RR greater than 2 mm or 5 mm<sup>2</sup>. The specific influence of some predictor variables varied depending on the type of maxillary incisor. **Conclusions:** RR of maxillary incisors after traction of unilateral vs bilateral impacted canines with reinforced anchorage was similar and is not a risk to the integrity of the maxillary incisor root. (*Am J Orthod Dentofacial Orthop* 2018;154:645-56)

**T**reatment of maxillary impacted canines (MIC) is one of the most complex procedures in orthodontics,<sup>1,2</sup> because they may have different impaction

positions—palatal, buccal, or bicortically centered in the alveolar bone.<sup>3-5</sup> They may migrate mesially over the central incisors near the middle raphe, and their angle of impaction varies from vertical to horizontal.<sup>6,7</sup> Likewise, the impaction may be either unilateral or bilateral; this latter condition increases the complexity of orthodontic treatment, its total time, and therefore the possibility of root resorption (RR) of the maxillary incisors.<sup>1</sup> Bilateral impaction is present in 19% to 45% of all patients with impaction.<sup>3,6,7</sup>

Conventional treatment of MIC involves special orthodontic biomechanics, which can increase the RR of neighboring teeth, mainly in patients with bilateral canine impaction, because traction is supported on both sides of the teeth as opposed to unilateral impaction. However, a comparison between unilateral and bilateral impacted canines has not been made. To pull a MIC, several intra-arch and interarch mechanisms are used,<sup>8-11</sup> including nickel-titanium springs,<sup>12</sup> power chains, or wire modifications.<sup>13</sup> In addition, conventional tensile forces are supported on large-caliber

<sup>a</sup>Divisions of Orthodontics and Oral and Maxillofacial Radiology, School of Dentistry, Universidad Científica del Sur, Lima, Perú

<sup>b</sup>Division of Oral and Maxillofacial Radiology, School of Dentistry, Universidad Científica del Sur, Lima, Perú; Division of Orthodontics, Faculty of Dentistry, Universidad Nacional de Colombia, Bogotá, Colombia.

<sup>c</sup>Division of Oral and Maxillofacial Radiology, School of Dentistry, Universidad Científica del Sur, Lima, Perú

<sup>d</sup>Division of Oral and Maxillofacial Radiology, Faculty of Dentistry, Universidad Nacional de Colombia, Bogotá, Colombia.

<sup>e</sup>Department of Orthodontics, Bauru Dental School, University of São Paulo, Bauru, São Paulo, Brazil.

<sup>f</sup>Division of Oral Radiology, Faculty of Dentistry, Federal University of Rio Grande do Sul, Porto Alegre, Rio Grande do Sul, Brazil.

All authors have completed and submitted the ICMJE Form for Disclosure of Potential Conflicts of Interest, and none were reported.

Address correspondence to: Luis Ernesto Arriola-Guillén, Calle Los Girasoles # 194, Dpto. # 302, Urb. Residencial Los Ingenieros de Valle Hermoso, Santiago de Surco, Lima, Perú; e-mail, [luchuarriola@gmail.com](mailto:luchuarriola@gmail.com).

Submitted, July 2017; revised and accepted, January 2018.

0889-5406/\$36.00

© 2018 by the American Association of Orthodontists. All rights reserved.

<https://doi.org/10.1016/j.ajodo.2018.01.015>

archwires in the brackets of the maxillary teeth; which even serves as anchorage for intermaxillary elastics to prevent the side effects of traction. One clinical alternative to prevent further RR is to distance the impacted canine from the roots of the maxillary incisors and then continue with conventional orthodontic treatment.<sup>14</sup> Another possibility to treat MIC that could prevent the side effects of traction is reinforced anchorage, using a heavy buccal archwire with bracket slots (0.019 3 0.025-in stainless steel) with heavy palatal anchorage in the maxillary arch.

The current evidence suggests that orthodontic treatment with uncontrolled forces causes an increase in the incidence and severity of RR, and that heavy forces may be particularly damaging.<sup>15-18</sup> However, there are few studies in the literature comparing the apical resorption of maxillary incisors resulting from traction of impacted canines, and these studies have been performed with periapical or panoramic radiographs.<sup>19-23</sup> Their main objectives were different, although they compared apical resorption of maxillary incisors in patients treated with orthodontics, including a small sample with traction of impacted canines. These studies showed a significant increase (approximately 0.6 mm) of apical resorption in the control group,<sup>19</sup> or approximately 1.33 mm from the contralateral side without impaction,<sup>20</sup> or considered it a risk factor for apical resorption of the maxillary incisors.<sup>21,22</sup> Nevertheless, few studies that were directly performed to evaluate the apical resorption of incisors after orthodontic treatment, including the traction of MIC, found different results from those reported.<sup>1,14,23</sup> One of the studies, performed, by Brusveen et al,<sup>23</sup> in patients with unilateral impaction, concluded that there is no significant difference in the apical resorption of incisors between both sides with and without impaction. Lempesi et al,<sup>1</sup> with most subjects in their sample having unilateral impacted canines, concluded the same, but the subjects were compared with a control group without impaction. There are only 2 studies using cone-beam computed tomography (CBCT), by Heravi et al<sup>14</sup> and Silva et al,<sup>24</sup> who concluded that the previous canine disimpaction produces minimal effects of RR, but they only evaluated subjects with palatally displaced canines or unilaterally impacted canines, respectively.

To our knowledge, no studies have compared the RR of maxillary incisors after orthodontic traction of impacted unilateral vs bilateral canines, knowing that this second condition involves different biomechanics, with greater complexity of the treatment and probably greater risk of RR.<sup>8,13</sup> Likewise, to achieve the traction of a MIC, usually it is necessary to use heavy anchorage and a rigid archwire in the maxillary arch to

prevent the undesirable effects of traction. Also, to obtain the canine disimpaction, an ideal force that allows its movement through the bone is needed. This force increases its magnitude in the anchorage and in the archwire when bilateral canines are pulled compared with unilateral impacted canines; therefore, the incisors could have a greater risk of RR in these patients. CBCT is the most accurate, reliable, and nonmagnifying current tool that allows us to know the exact amount of RR of the maxillary incisors, not only apical resorption, but also after orthodontic treatment of MIC.<sup>25,26</sup> For this reason, the purpose of this study was to compare the 3 dimensional (3D) amount of RR of maxillary incisors after orthodontic traction of impacted canines using reinforced anchorage and coil springs in patients with unilateral vs bilateral impaction. We sought to test the null hypothesis that there is no significant difference in the amount and area of RR of maxillary incisors after orthodontic traction of bilateral vs unilateral impacted canines.

#### MATERIAL AND METHODS

The design of this study was retrospective and longitudinal, specifically a before-and-after study, approved by the Ethics and Research Committee of the Universidad Científica del Sur in Lima, Perú (protocol number 00006). The sample consisted of 30 patients diagnosed and treated in a private orthodontic office (G.A.R.M.), with 60 CBCT images—30 before and 30 after their orthodontic treatment that included traction with coil springs of at least 1 MIC. Two groups were formed according to the type of impaction, unilateral (n = 15) and bilateral (n = 15), in which RR of the maxillary incisors was evaluated (total of 240 incisors). A minimum sample size of 15 participants per group was necessary to provide 80% test power at a significance level of 0.05 to detect an intergroup difference of 0.76 mm in RR of the maxillary incisors, with a standard deviation of 0.85 mm (from a previous pilot study).

Inclusion criteria were patients older than 12 years, with canines unilaterally and bilaterally impacted: palatal, buccal, or bicortically centered. Patients with craniofacial deformities or syndromes, periapical lesions in the maxillary incisors before orthodontic treatment, brackets or maxillary surgeries before the study, or agenesis of a maxillary tooth were excluded.

Full patient records—clinical histories, study models, extraoral and intraoral photographs, panoramic and profile x-rays, and CBCT images before (T0) and after canine traction, exceeding the limits of the alveolar crest to the occlusal plane (T1)—were obtained. Demographic and clinical variables of each patient, including sex, age, Angle classification, skeletal relationship (ANB<sup>27</sup> and



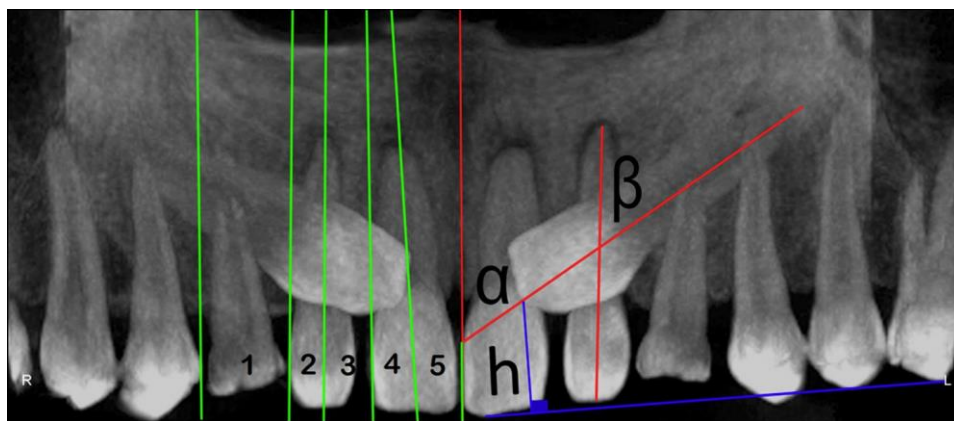


Fig 1. Right side: anteroposterior assessment of canine position (impaction sectors coded from 1 to 5), based on the study of Ericson and Kuroi.<sup>2</sup> Left side: assessment of canine position, including angle  $\alpha$ , angle  $\beta$ , and height  $h$ .

APDI<sup>28</sup>), and characteristics of the impacted canines (condition, sector, angle  $\alpha$ , angle  $\beta$ , height, and duration of the traction treatment) were recorded.<sup>1</sup>

Three orthodontists (L.E.A.G., G.A.R.M., Y.A.R.C.) trained in the diagnosis of impacted unilateral and bilateral canines evaluated each tomographic and panoramic radiograph to detail the characteristics of impaction. They had to agree on the diagnosis of impaction sector and position; in case of any discrepancy, the final diagnosis was obtained by consensus. Interobserver calibration was assessed with kappa coefficients. The kappa coefficient values were greater than 0.9. For the quantitative variables, all CBCT measurements were repeated by the same evaluator (L.E.A.G.) after a 30-day interval. Intraobserver calibration was evaluated with the intraclass correlation coefficient until values greater than 0.9 were obtained. Random error of reproducibility was calculated according to Dahlberg's formula,<sup>29</sup> giving values smaller than 1 mm or 1 mm<sup>2</sup>.

CBCT scans were required to complement the diagnosis of MIC type. The patients were classified according to the number of impactions in unilateral or bilateral cases. Additionally, they were grouped according to their location (palatal, buccal, or bicortical form),<sup>3-5</sup> defined in axial cuts in which 4 criteria were evaluated: (1) visualization of the MIC and its interpretation, (2) position of the impacted canine crown in relation to a midline drawn between the 2 bone cortical (buccal and palatal), (3) its location in relation to the neighboring lateral incisor, and (4) the surgical approach. CBCT scans of all patients were taken using PaX-Uni 3D (Vatech, Hwaseong, South Korea) set at 4.7 mA, 89 kV(p), voxel size of 0.125, and exposure time of 15 seconds. Each field-of-view mode was 8 3 8 cm<sup>2</sup>. DICOM images were analyzed with 3D software (version 11.7; Dolphin

Imaging, Chatsworth, Calif), using multiplanar and 3D reconstructions.

Measurements for this study were made on images synthesized from the CBCT scans. Reconstructed panoramic images were obtained from the computed tomography scans. To determine the impaction sector, we used the classification suggested by Ericson and Kuroi.<sup>2,6</sup> The cusp tip of the canine was localized in 1 of 5 sectors (Fig 1).

Sector 1: the cusp tip of the MIC is between the mesial aspect of the first premolar to the distal aspect of the lateral incisor.

Sector 2: the cusp tip of the MIC is between the distal aspect of the lateral incisor and the long axis of the lateral incisor.

Sector 3: the cusp tip of the MIC is between the long axis of the lateral incisor and the mesial aspect of the lateral incisor.

Sector 4: the cusp tip of the MIC is between the mesial aspect of the lateral incisor and the long axis of the central incisor.

Sector 5: the cusp tip of the MIC is between the long axis of the central incisor and the interincisor median line.

To determine the canine position, Ericson and Kuroi<sup>2,6</sup> used angle  $\alpha$  to represent the angle between the interincisor midline and the long axis of canine. We measured angle  $\beta$  between the long axis of the canine and the long axis of the lateral incisor (Fig 1).<sup>3</sup> Canine vertical height was evaluated using the perpendicular distance of the peak of the impacted canine to the occlusal plane formed by a tangent to the incisal edge of the maxillary central incisor and the occlusal surface of the maxillary first molar (Fig 1).<sup>3</sup>

The initial lateral cephalometric radiographs of each patient were obtained with digital cephalometric

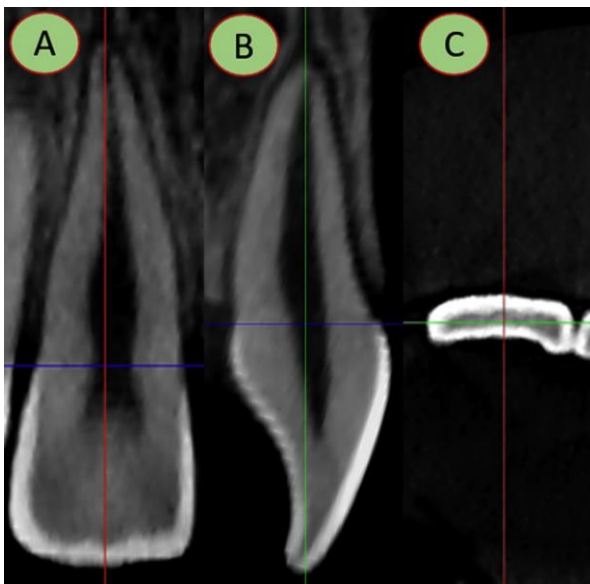


Fig 2. Procedures for measurements: A, coronal plane; B, sagittal plane; C, axial plane.

panoramic equipment (Pax 400C; Vatech). The settings were 90 kV, 10 mA, and 13 to 15 seconds. All cephalometric measurements were performed digitally with the 3D software (version 11.7; Dolphin Imaging), without magnification, at a scale of 1:1. Skeletal relationship measurements were expressed by the ANB and APDI angles, the maxillary sagittal position was determined in the sagittal direction using the SNA angle, and the maxillary length was measured as the distance of from posterior nasal spine to anterior nasal spine.

DICOM images were processed with the same software (version 11.7; Dolphin Imaging). Sagittal, coronal, and axial sections of the maxillary incisors were obtained. For the measurements, the tomographic section was aligned with the longitudinal tooth axis in the coronal and sagittal planes, positioning the incisal edge parallel to the coronal plane in the axial section (Fig 2). Then the root lengths measured in millimeters on the same longitudinal axis from a perpendicular projection to the vestibular cemento-enamel junction in the sagittal section or mesial cemento-enamel junction in the coronal section up to the vertex of the radicular apex of each incisor were evaluated. The root areas of the incisors, in square millimeters, were then evaluated starting from the buccal or mesial cemento-enamel junction, continuing along the contour of the entire root to the palatine or distal cemento-enamel junction. (Fig 3, A and B). In the axial sections, the areas of RR were measured at the level of 2 sectors. To define the sectors, the root length of the sagittal

section was divided into thirds, and the areas of the cervical and middle thirds in the axial sections were measured (Fig 3, C).

All patients were treated with a strict orthodontic and surgical protocol. A segmental alignment and leveling phase was performed with 0.016  $\pm$  0.022-in copper-titanium (Ormco, Glendora, Calif) archwire on metal brackets with a slot size of 0.022  $\pm$  0.028 in (Synergy; Rocky Mountain Orthodontics, Denver, Colo) in the incisors and in the premolar and molar regions, always ensuring the permanence of the deciduous canine, if present. The space was prepared with 0.012  $\pm$  0.045-in open-coil springs (Rocky Mountain Orthodontics) between the lateral incisor and first premolar on 0.017  $\pm$  0.025-in nickel-titanium archwires. Both were indispensable requirements before surgery. Subsequently, a rigid temporary anchor was placed on bands in the permanent first molars with a rigid palatal acrylic button and an archwire over all palatal surfaces of all maxillary teeth in 1.1-mm (0.043 in) or 1.2-mm (0.047 in) stainless steel wire (Dentaureum, Ispringen, Germany) with multiple palatal and occlusal vestibular hooks in 0.028-in wire proximal to the molars and premolars, and distal to the lateral incisors. This anchorage was cemented at least 4 weeks before surgery. Vestibular hooks and extensions of the anchor allowed fastening of the buckles of the nickel-titanium closed-coil springs, 0.010  $\pm$  0.036 in, 8 and 13 mm long, with 100 or 150 g of force (Dentos, Daegu, Korea), to perform intraosseous traction trans-alveolarly, and to prevent the springs from becoming immersed in the attached gingiva and the mucoperiosteum limiting its activation (Fig 4). A passive 0.017  $\pm$  0.025-in stainless steel archwire on the brackets of the already aligned and levelled teeth was cinched distally to the last molar involved in the anchorage before traction.

A closed surgical technique in all impacted tooth was used.<sup>30</sup> Exceptionally, an open technique was necessary with surgical window by palatal.<sup>31</sup> A rigorous process of isolation and transsurgical adhesion of the button or buttons with springs fixed to the closed-coil nickel-titanium spring on the vestibular face of each retained canine was performed, and immediately activated from 4 to 5 mm every 4 to 8 weeks until the buccal hooks welded to the anchorage (Fig 5). The deciduous canines, cysts, and supernumerary teeth, among others, were removed in the same surgical procedure. Exceptionally, a premolar was removed. After obtaining traction of the canines, the palatal anchorage was removed; it had protected and stabilized the incisors and premolars. At this time, all necessary procedures to complete the orthodontic treatment were performed. CBCT scans were

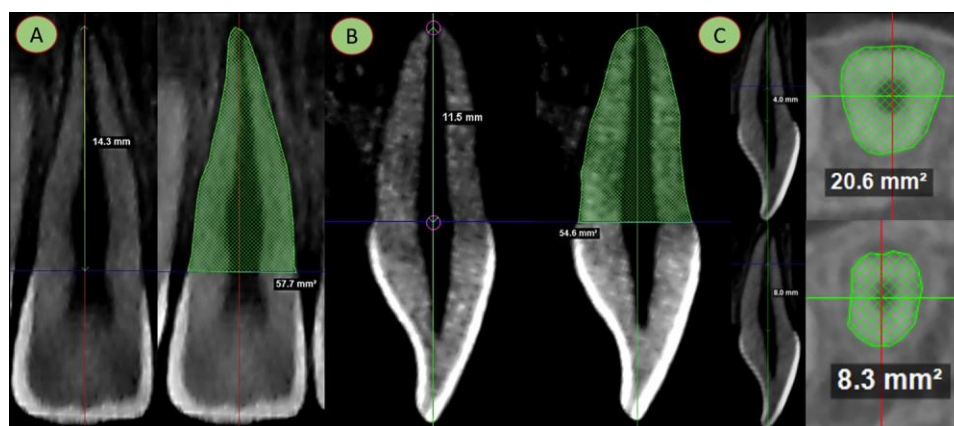


Fig 3. Assessment of the root length in millimeters and area in square millimeters in the 3 planes: A, coronal plane; B, sagittal plane; C, axial plane.

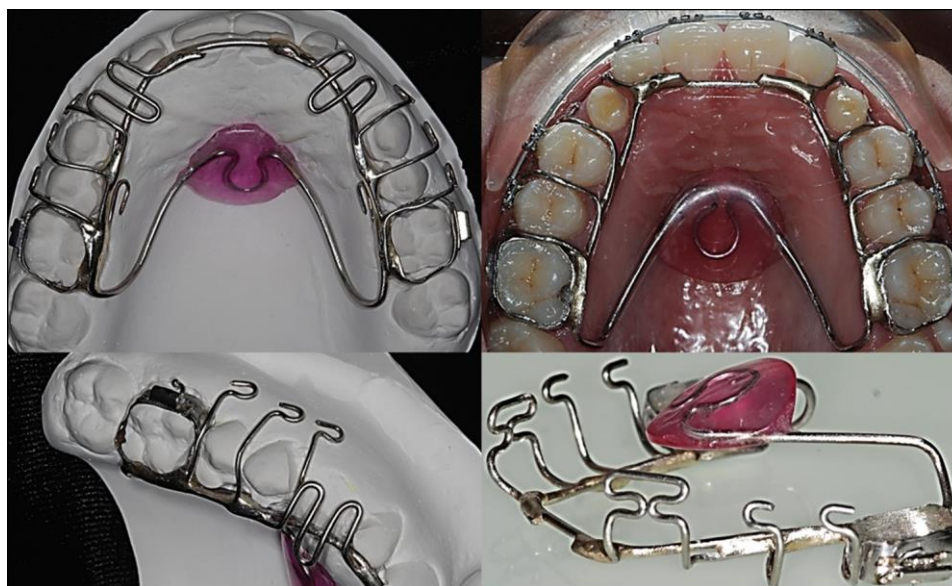

Fig 4. Rigid temporary anchorage device used for traction of impacted canines.

taken to control the treatment, and the finalization phase was started.

A second CBCT (T1), with the same technical characteristics as the initial one (T0), was requested during orthodontic treatment (end of canine traction) to complete the orthodontic treatment that included canine traction. In the same CBCT, measurements were made of the lengths and root areas of the maxillary incisors in the same sagittal, coronal, and axial sections (Figs 2 and 3). To measure the RR in each incisor, the initial value was subtracted from the final value, and the results were obtained in millimeters and square millimeters in the 3 sections evaluated.

#### Statistical analysis

The statistical analyses were performed using SPSS software for Windows (version 19.0; IBM, Armonk, NY). Descriptive statistics of RR in millimeters and square millimeters of each maxillary incisor were calculated for both canine groups, unilaterally and bilaterally impacted. Data normality in both groups was determined with Shapiro-Wilk tests. Independent *t* or Mann-Whitney U tests were used, depending on data normality. Finally, multiple linear regression models to evaluate the influence of each variable on RR of all predictors were used. An initial regression analysis with all predictors followed by a second regression analysis

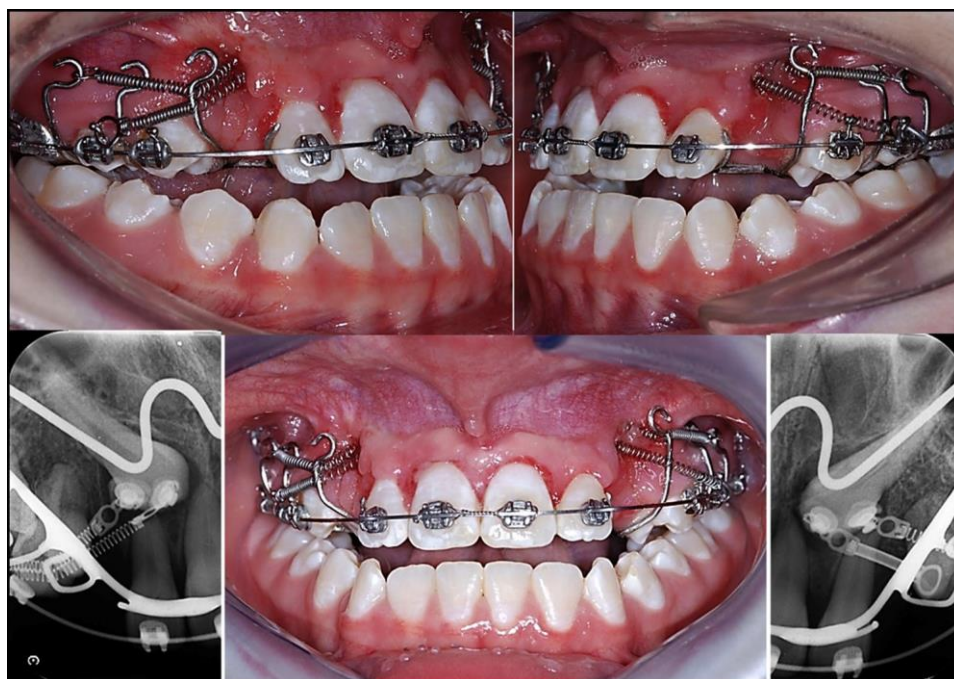


Fig 5. Treatment protocol used for traction of impacted canines.

with only predictor variables showing  $P$  values smaller than 0.25 was performed for each tooth (overfit method).<sup>32</sup> Statistical significance was set at  $P \leq 0.05$  for all tests.

## RESULTS

The initial characteristics of the sample are shown in [Tables I and II](#). There were no significant differences in most of the variables evaluated between the 2 impaction groups, except for the canine impaction sector ( $P = 0.026$ ), with greater difficulty for the subjects in the bilateral impaction group ([Table I](#)). Canine traction required a longer treatment time (3.4 months) in the bilateral group ( $P = 0.002$ ) ([Table II](#)).

No significant differences were found when the amounts and areas of RR of maxillary incisors were compared between the unilateral and bilateral groups at any section evaluated. No subject had RR greater than 2 mm or 5 mm<sup>2</sup> ([Tables III-V](#)), except for the RR of the maxillary right central incisor that was significantly greater (0.86 mm) in the unilateral group ( $P = 0.023$ ; [Table IV](#)).

Linear regression tests for all quantities and areas of resorption were applied only for predictor variables that could have an effect on the outcome variables and mainly did not show any influence ( $P > 0.05$ ). When there was an influence, it varied depending on each

incisor ( $P < 0.05$ ), and mainly the sex variable influenced the RR ([Tables VI and VII](#)).

## DISCUSSION

The purpose of this study was to compare the amount of RR of maxillary incisors after traction of unilateral vs bilateral impacted canines with reinforced anchorage and nickel-titanium closed-coil springs. Studies in the literature have reported the comparison of apical resorption of maxillary incisors in orthodontically treated patients, including traction of impacted canines,<sup>1,14,23</sup> but no studies have compared groups according to the number of impacted sides: ie, they did not compare unilateral vs bilateral impacted canines after traction. These authors evaluated both conditions in 1 group because of a small sample size, mainly due to difficulty in obtaining subjects with bilateral impactions. This grouping could lead to a generalization of the results that is not accurate, since the treatment of patients with bilateral canine impaction is more complex and has a greater resorptive risk because of the exerted load on the incisors.

In this study, small field-of-view CBCT scans of the jaws were obtained before and after canine traction, due to the ectopic complex position of the sample and the advanced initial resorption, which required tomographic control of the canine traction. The amount of exposure to the radiation was not a risk for the patients

**Table I. Initial characteristics of the sample according to impaction condition: qualitative variables**

Variable	Condition	Unilateral	Bilateral	Total	P, chi square
Sex	Male	5	6	11	0.705
	Female	10	9	19	
Angle malocclusion	Class I	10	10	20	0.819
	Class II Division 1	0	0	0	
	Class II Division 2	3	2	5	
	Class III	2	3	5	
Location of impacted canine (in the unilateral group, the right side was evaluated)	Palatal	6	6	12	0.198
	Buccal	4	5	9	
	Bicortical	0	4	4	
Location of impacted canine (in the unilateral group, the left side was evaluated)	Palatal	3	5	8	0.427
	Buccal	2	7	9	
	Bicortical	0	3	3	
Impaction sector (in the unilateral group, the right side was evaluated)	Sector 1	4	3	7	0.026*
	Sector 2	0	5	5	
	Sector 3	5	1	6	
	Sector 4	1	4	5	
	Sector 5	0	2	2	
Impaction sector (in the unilateral group, the left side was evaluated)	Sector 1	0	3	3	0.663
	Sector 2	1	3	4	
	Sector 3	1	4	5	
	Sector 4	2	2	4	
	Sector 5	1	3	4	

\*Statistically significant at  $P \leq 0.05$ .

**Table II. Initial characteristics of the sample according to impaction condition: quantitative variables**

Measurement	Unilateral		Bilateral		Mean difference	Lower limit, 95% CI	Upper limit, 95% CI	P, t test
	Mean	SD	Mean	SD				
Age (y)	20.67	8.75	16.8	6.41	3.86	-1.87	9.6	0.179
Duration of traction (mo)	6.13	1.76	9.53	1.31	-3.40	-5.39	-1.41	0.002*
ANB (°)	2.94	2.51	4.16	2.31	-1.21	-3.02	0.59	0.179
APDI (°)	82.96	4.55	81.10	6.91	1.86	-2.52	6.24	0.391
SNA (°)	85.21	4.38	84.73	5.52	0.47	-3.26	4.20	0.797
Maxillary length, ANS-PNS (mm)	47.89	3.13	47.96	5.27	-0.08	-3.32	3.17	0.961
Height of impacted canine, right side (mm)	9.93	2.53	11.32	4.19	-1.39	-4.46	1.68	0.358
Height of impacted canine, left side (mm)	11.66	2.27	12.29	5.16	-0.63	-5.70	4.45	0.798
Angle a of impacted canine, right side (°)	38.24	16.17	44.76	15.41	-6.52	-19.79	6.75	0.320
Angle a of impacted canine, left side (°)	47.94	20.38	49.43	20.87	-1.49	-24.02	21.03	0.891
Angle b of impacted canine, right side (°)	33.80	13.17	43.96	18.55	-10.16	-24.23	3.90	0.149
Angle b of impacted canine, left side (°)	43.76	26.94	50.17	24.40	-6.41	-33.51	20.70	0.625

\*Statistically significant at  $P \leq 0.05$ .

because the procedures were done according to ALARA principles; on the contrary, the benefits of the follow-ups were important and explained to them.<sup>33,34</sup> In our study, the second CBCT scan was obtained after traction of the impacted canines, at the final, detailed stage, close to removal of the brackets, so a definitive conclusion of how much more this RR of the incisors could advance until the end of the treatment could

not be specified. The ending phase generally lasts for up to 6 months, so no further RR was expected, but this should be evaluated in future studies. However, authors will not be able to use CBCT scans because they are contraindicated after orthodontic treatment based on the ALARA principle.<sup>33,34</sup>

In this study, we used CBCT images to guarantee the accuracy of the RR measurements in millimeters and

**Table III. Comparison of root resorption of maxillary incisors and area between both canine impaction groups: sagittal section**

Tooth	Measurement	Unilateral (n 5 15)		Bilateral (n 5 15)		Mean difference	95% CI		P
		Mean	SD	Mean	SD		Lower limit	Upper limit	
Maxillary left lateral incisor	Root resorption (mm)	1.19	1.06	1.55	1.00	-0.36	-1.13	0.41	0.348
	Resorption area (mm <sup>2</sup> )	3.43	3.29	3.37	2.36	0.06	-2.08	2.20	0.955
Maxillary left central incisor	Root resorption (mm)	1.53	0.84	1.47	1.05	0.06	-0.65	0.77	0.865
	Resorption area (mm <sup>2</sup> )	4.13	3.14	3.36	3.04	0.77	-1.54	3.09	0.499
Maxillary right central incisor	Root resorption (mm)	1.54	1.15	1.22	0.88	0.32	-0.45	1.09	0.402
	Resorption area (mm <sup>2</sup> )	3.54	3.09	2.49	2.49	1.05	-1.05	3.15	0.314
Maxillary right lateral incisor	Root resorption (mm)	1.39	1.16	0.73	0.70	0.66	-0.05	1.37	0.070
	Resorption area (mm <sup>2</sup> )	3.40	3.42	1.71	1.74	1.68	-0.34	3.71	0.100

Independent *t* test.

**Table IV. Comparison of root resorption of maxillary incisors and area between both canine impaction groups: coronal section**

Tooth	Measurement	Unilateral (n 5 15)		Bilateral (n 5 15)		Mean difference	95% CI		P
		Mean	SD	Mean	SD		Lower limit	Upper limit	
Maxillary left lateral incisor	Root resorption (mm)	1.18	0.90	1.71	1.19	-0.53	-1.32	0.25	0.179
	Resorption area (mm <sup>2</sup> )	1.83	1.84	3.07	1.93	-1.24	-2.65	0.17	0.083
Maxillary left central incisor	Root resorption (mm)	1.37	1.03	1.33	1.01	0.04	-0.71	0.81	0.902
	Resorption area (mm <sup>2</sup> )	3.15	3.76	3.19	2.65	-0.04	-2.47	2.39	0.973
Maxillary right central incisor	Root resorption (mm)	1.88	1.17	1.01	0.75	0.86	0.13	1.60	0.023*
	Resorption area (mm <sup>2</sup> )	4.79	3.82	2.99	2.73	1.80	-0.68	4.28	0.149
Maxillary right lateral incisor	Root resorption (mm)	1.35	0.99	1.13	1.08	0.22	-0.55	0.99	0.566
	Resorption area (mm <sup>2</sup> )	3.43	3.27	2.22	2.05	1.20	-0.83	3.25	0.237

Independent *t* test.

\*Significant.

square millimeters in the 3 planes of space. This form of accurate evaluation cannot be achieved with panoramic radiographs, because RR is not only apical, but the entire root area involved in the treatment should be evaluated.

We compared RR between both impaction groups but did not include a control group without impaction. In our view, the best control group from the methodologic point of view would be the contralateral side without impaction, but this would involve a split-mouth design: ie, investigations only in patients with unilateral impaction. The results of these investigations cannot be extrapolated to patients with bilateral impaction who require more complex therapeutic management. Some studies have compared the resorption of maxillary incisors with matched control groups, orthodontically treated without including subjects with impacted canines.<sup>1,23</sup> However, true pairing is difficult to achieve due to the genetic and biologic characteristics of each patient. Also, the biomechanics used in orthodontic treatment are not quite comparable from 1 patient to another, due to

variables related to the severity of malocclusion, the technique used, the possibility of extractions, the clinician's experience, and so on. Therefore, we considered that the main clinical contributions of this study for an orthodontist are to know that the roots of maxillary incisors before and after orthodontic treatment involving the traction of a unilateral or bilateral MIC show no significant differences, and also to demonstrate that the resorption in both groups did not exceed 2 mm, which is clinically not relevant. Thus, the treatment does not jeopardize the integrity of the roots of the incisors or the patients' oral health.

The likelihood of finding different amounts of RR in several treated patients is related to the technique used by the orthodontist to pull impacted canines. In this investigation, this possibility was controlled using I technique performed entirely by an expert (G.A.R.M.) in the management of impacted canines; this technique involved removal of the dental follicle, the use of nickel-titanium closed-coil springs to exert a continuous force

**Table V. Comparison of the area (mm<sup>2</sup>) of root resorption of maxillary incisors at the level of the cervical and middle thirds: axial section**

Tooth	Measurement	Unilateral (n 5 15)		Bilateral (n 5 15)		Mean difference	95% CI		P
		Mean	SD	Mean	SD		Lower limit	Upper limit	
Maxillary left lateral incisor	Cervical third	0.43	0.58	1.11	1.62	-0.68	-1.59	0.23	0.095
	Middle third	0.52	0.70	1.12	1.39	-0.60	-1.42	0.22	0.256
Maxillary left central incisor	Cervical third	1.31	2.05	0.91	1.24	0.40	-0.87	1.67	0.735
	Middle third	1.48	2.50	1.53	1.97	-0.05	-1.73	1.63	0.612
Maxillary right central incisor	Cervical third	1.12	2.14	0.87	0.94	0.25	-0.98	1.49	0.829
	Middle third	1.32	2.02	1.40	2.29	-0.08	-1.69	1.53	0.848
Maxillary right lateral incisor	Cervical third	0.61	0.86	0.53	0.73	0.08	-0.51	0.67	0.949
	Middle third	1.12	1.58	1.45	1.63	-0.32	-1.53	0.87	0.580

Mann-Whitney U test.

**Table VI. Multiple linear regression analysis of root resorption and area of maxillary incisors: sagittal section**

Predictor variable	ULLI		ULCI		URCI		URLI	
	b	P	B	P	b	P	b	P
Root resorption (mm)								
Constant		0.194		0.312		0.052		0.489
Sex	0.862	0.069	-0.653	0.528	-0.494	0.074	-0.276	0.325
Duration of traction (mo)	-0.509	0.166	0.806	0.061	-0.286	0.327	0.061	0.847
Type of impaction	-0.058	0.854	-0.640	0.088	-0.125	0.649	-0.280	0.392
Location of impacted canine	0.808	0.185	-0.428	0.609	-0.440	0.290	-0.089	0.836
Canine impaction sector	0.914	0.055	-0.442	0.383	0.081	0.837	-0.047	0.911
Angle a of impacted canine	-1.867	0.023*	0.250	0.790	-0.191	0.709	0.308	0.568
Angle b of impacted canine	2.242	0.026*	-0.662	0.606	-0.219	0.567	-0.067	0.854
Height of impacted canine	0.007	0.989	-0.011	0.989	0.445	0.245	-0.184	0.605
Initial root length	0.842	0.135	-0.365	0.673	-0.660	0.156	0.186	0.617
r <sup>2</sup>	0.549		0.412		0.332		0.259	
Area of root resorption (mm <sup>2</sup> )								
Constant		0.300		0.063		0.004*		0.044*
Sex	0.610	0.135	-0.761	0.070	-0.560	0.017*	-0.414	0.139
Duration of traction (mo)	-0.284	0.366	0.662	0.058	-0.371	0.125	-0.006	0.984
Type of impaction	-0.121	0.653	-0.667	0.033*	-0.064	0.773	-0.351	0.242
Location of impacted canine	0.419	0.332	-0.710	0.189	-0.472	0.108	-0.140	0.692
Canine impaction sector	0.756	0.040*	-0.226	0.511	-0.182	0.576	0.118	0.771
Angle a of impacted canine	-1.532	0.017*	-0.033	0.955	-0.146	0.723	-0.176	0.736
Angle b of impacted canine	1.910	0.013*	-0.333	0.670	-0.332	0.286	-0.029	0.934
Height of impacted canine	-0.197	0.670	-0.217	0.693	0.457	0.114	-0.055	0.872
Initial root length	0.633	0.094	-0.291	0.536	-0.644	0.050	-0.237	0.441
r <sup>2</sup>	0.642		0.621		0.557		0.306	

ULLI, Maxillary left lateral incisor; ULCI, maxillary left central incisor; URCI, maxillary right central incisor; URLI, maxillary right lateral incisor.

\*Statistically significant at  $P \leq 0.05$ .

that first distanced the impacted canines from the roots of the maxillary incisors and then pulled them to the occlusal plane. A fundamental objective of this technique was to prevent the premature emergence of the canine through the periosteum, having the cusp as close as possible to the alveolar crest limits between the first premolar and lateral incisor, to favor the osteogenic process. In the treated sample, the cusp of the canine emerged in the attached gingival margin, reaching the occlusal plane after treatments averaging 6.13 months

in the unilateral subjects and 9.53 months in the bilateral subjects ( $P = 0.002$ ). Despite the significant difference, this did not cause greater RR in the patients with bilateral impactions. In general, orthodontic treatment of a MIC lasts approximately 6 months longer than conventional treatment, with a tendency to increased time when bilateral canine impactions are treated, because impacted canines usually do not appear at the same time.<sup>1,35</sup> Additionally, to prevent undesired effects, the technique used in this study was a reinforced

Table VII. Multiple linear regression analysis of root resorption and area of maxillary incisors: coronal section

Predictor variable	ULLI		ULCI		URCI		URLI	
	b	P	b	P	b	P	b	P
<b>Root resorption (mm)</b>								
Constant		0.116		0.152		0.019*		0.572
Sex	0.705	0.175	-0.197	0.609	-0.780	0.003*	-0.444	0.099
Duration of traction (mo)	0.111	0.782	0.108	0.752	0.149	0.501	0.314	0.273
Type of impaction	-0.068	0.819	-0.311	0.310	-0.415	0.064	-0.018	0.947
Location of impacted canine	1.162	0.051	-1.139	0.177	-0.536	0.102	-0.206	0.586
Canine impaction sector	0.483	0.311	-0.539	0.191	0.184	0.553	-0.071	0.850
Angle a of impacted canine	-1.370	0.118	0.386	0.567	-0.180	0.649	0.012	0.979
Angle b of impacted canine	1.672	0.127	-0.633	0.512	-0.580	0.066	-0.196	0.556
Height of impacted canine	-0.533	0.281	0.780	0.333	0.517	0.077	0.020	0.951
Initial root length	1.247	0.040*	-0.675	0.379	-0.475	0.153	0.259	0.430
r <sup>2</sup>	0.588		0.579		0.597		0.399	
<b>Area of root resorption (mm<sup>2</sup>)</b>								
Constant		0.141		0.025*		0.006*		0.031*
Sex	0.629	0.304	-1.105	0.037*	-0.828	0.002*	-0.611	0.018*
Duration of traction (mo)	-0.281	0.442	0.442	0.202	0.089	0.678	0.330	0.179
Type of impaction	0.438	0.185	-0.741	0.025*	-0.262	0.219	-0.205	0.414
Location of impacted canine	0.512	0.270	-0.784	0.150	-0.091	0.721	-0.339	0.228
Canine impaction sector	0.714	0.089	-0.613	0.100	0.066	0.828	-0.265	0.435
Angle a of impacted canine	-1.124	0.091	0.754	0.162	0.181	0.642	0.212	0.616
Angle b of impacted canine	1.246	0.199	-1.213	0.108	-0.781	0.013*	-0.539	0.092
Height of impacted canine	-0.168	0.749	0.155	0.807	0.230	0.371	-0.065	0.806
Initial root length	1.221	0.025*	-0.632	0.179	-0.486	0.055	-0.172	0.527
r <sup>2</sup>	0.572		0.580		0.609		0.531	

ULLI, Maxillary left lateral incisor; ULCI, maxillary left central incisor; URCI, maxillary right central incisor; URLI, maxillary right lateral incisor.

\*Statistically significant at  $P \leq 0.05$ .

anchorage, using a heavy buccal archwire within bracket slots (0.019 3 0.025-in stainless steel) with heavy palatal anchorage in the maxillary arch. This anchorage was based on a large palatal arc of heavy wire, including hooks that were welded for pulling the canines, thus preventing immersion of the coil spring on the attached gingiva and favoring the remote fixation of the activated springs (Fig 4).

Other authors have evaluated apical resorption in periapical or panoramic radiographs in treatments of impacted canines, mainly unilateral, indicating that there are significant differences for nonpaired treatments, but this difference was approximately 0.6 mm<sup>19</sup> to 1.3 mm,<sup>20</sup> which clinically constitutes mild RR. Other studies<sup>1,23</sup> that directly evaluated apical resorption after canine disimpaction and orthodontics, by panoramic radiographs or tomography<sup>14</sup> in exclusive samples of impacted canines, found no significant difference compared with the contralateral side or with paired control groups. However, these studies included mainly subjects with unilateral impaction with few subjects with bilateral impaction, although when they compared the unilateral subjects with the few bilateral ones, they found greater resorption in the bilateral

subjects. In our study, no significant differences were observed for RR between the 2 groups (unilateral vs bilateral), and the mean differences between these groups were less than 1 mm and 2 mm<sup>2</sup>, even with higher values for the unilateral group that in some comparisons became significant, but this difference was not clinically relevant. Although it was likely that the bilateral subjects, due to greater complications for the orthodontic treatment, have a greater risk of RR, this situation did not appear. We included a significant number of bilateral patients of high complexity and some with severe initial resorption (Fig 6) and did not find greater amounts or areas of RR than in the unilateral patients. There was 1 patient (Fig 6, lower images) with great resorption at the beginning and end of the traction; the treatment was successfully completed, and the follow-ups have shown adequate stability and will continue for more years.

One factor that could increase the risk of RR is the canine impaction sector. We included cases of high complexity in sectors 4 and 5, mainly in the bilateral group (Fig 7) that could have generated greater RR.<sup>2,6</sup> However, this situation was probably not a problem because of the technique used to treat these patients,



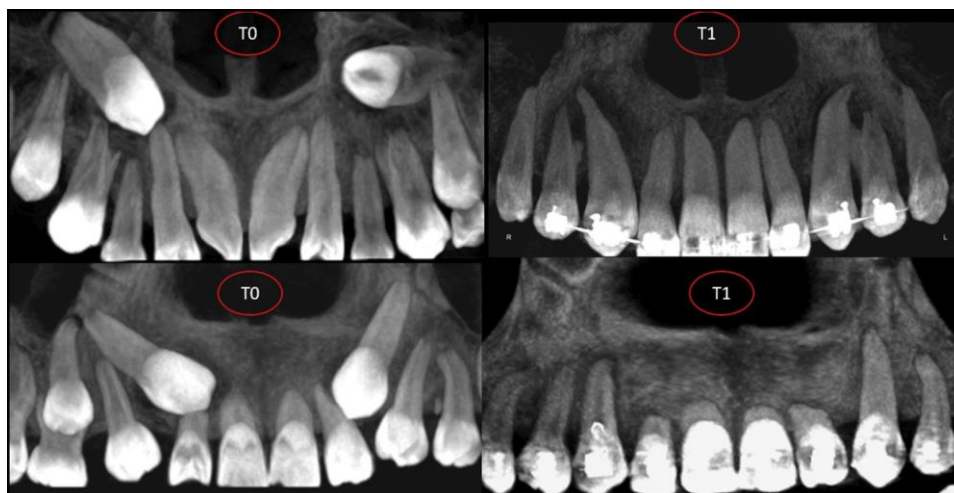


Fig 6. Bilateral cases of high complexity and some with severe initial resorption.

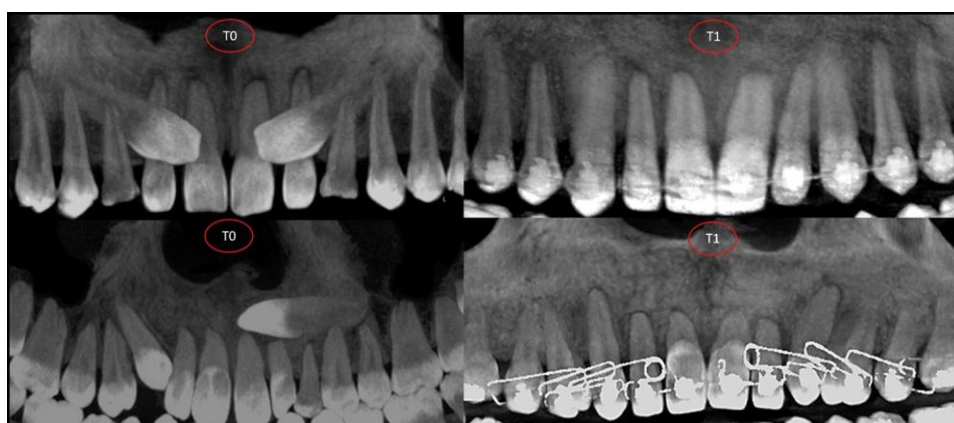


Fig 7. Canine impaction sectors; we included cases of high complexity in sectors 4 and 5.<sup>2</sup>

keeping more distance between the impacted canine and the roots of the incisors and using heavy anchorage to relieve the direct dental support. These 2 conditions probably reduced the risk of RR.

RR before and after orthodontic treatment in subjects with canine impaction showed statistically significant changes in the 3 sections evaluated, but in both groups the changes were less than 2 mm, and the radicular area was smaller than 5 mm<sup>2</sup>. These resorptions from the clinical point of view are acceptable and do not constitute damage to the periodontium or to the patient's dental health, and really make viable the most important teeth in the functional occlusion. Likewise, the multivariate analysis did not show a specific influence of a predictive variable on RR of the maxillary incisors, and when there was influence of a predictive variable, it was not constant in the 4 incisors. To

consider that a predictor variable has influence to produce RR of the maxillary incisors, after impacted canine traction, its effect not only must be shown in a tomographic section of a specific incisor, but also should be noted on both sides of the face. For this reason, although we found some significant differences in some predictor variables, these were not clinically relevant; we only identified the influence in most regressions for the sex variable, with a higher risk of resorption after traction of impacted canines in men, but this finding is necessary to contrast in future studies because of few studies in the literature.

Finally, the results of this study agree with the null hypothesis that there are no significant differences in the amount and area of RR of the maxillary incisors after orthodontic traction of impacted bilateral vs unilateral canines.

## CONCLUSIONS

1. The RR of the maxillary incisors after traction with reinforced anchorage of unilateral vs bilateral impacted canines was similar and is not a risk to the integrity of the maxillary incisor root.
2. The amount and area of RR after orthodontic traction, independently of the group, were smaller than 2 mm and 5 mm<sup>2</sup>, respectively.

## REFERENCES

1. Lempesi E, Pandis N, Fleming PS, Mavragani M. A comparison of apical root resorption after orthodontic treatment with surgical exposure and traction of maxillary impacted canines versus that without impactions. *Eur J Orthod* 2014;36:690-7.
2. Ericson S, Kuroi J. Early treatment of palatally erupting maxillary canines by extraction of the primary canines. *Eur J Orthod* 1988; 10:283-95.
3. Kumar S, Mehrotra P, Bhagchandani J, Singh A, Garg A, Kumar S, et al. Localization of impacted canines. *J Clin Diagn Res* 2015;9: ZE11-4.
4. Yan B, Sun Z, Fields H, Wang L. Maxillary canine impaction increases root resorption risk of adjacent teeth: a problem of physical proximity. *Orthod Fr* 2015;86:169-79.
5. Chaushu S, Kaczor-Urbanowicz K, Zadurska M, Becker A. Predisposing factors for severe incisor root resorption associated with impacted maxillary canines. *Am J Orthod Dentofacial Orthop* 2015;147:52-60.
6. Ericson S, Kuroi J. Radiographic examination of ectopically erupting maxillary canines. *Am J Orthod Dentofacial Orthop* 1987;91: 483-92.
7. Mercuri E, Cassetta M, Cavallini C, Vicari D, Leonardi R, Barbato E. Dental anomalies and clinical features in patients with maxillary canine impaction. *Angle Orthod* 2013;83:22-8.
8. Yadav S, Chen J, Upadhyay M, Jiang F, Roberts WE. Comparison of the force systems of 3 appliances on palatally impacted canines. *Am J Orthod Dentofacial Orthop* 2011;139:206-13.
9. Oppenhuizen G. An extrusion spring for palatally impacted cuspids. *J Clin Orthod* 2003;37:434-6.
10. Jacoby H. The "ballista spring" system for impacted teeth. *Am J Orthod* 1979;75:143-51.
11. Bowman SJ, Carano A. The Kilroy spring for impacted teeth. *J Clin Orthod* 2003;37:683-8.
12. Thebault B, Dutertre E. Disimpaction of maxillary canines using temporary bone anchorage and cantilever springs. *Int Orthod* 2015;13:61-80.
13. Chang NY, Park JH, Lee MY, Cho JW, Cho JH, An KY, et al. Orthodontic treatment of maxillary incisors with severe root resorption caused by bilateral canine impaction in a Class II Division I patient. *J Clin Pediatr Dent* 2016;40:161-8.
14. Heravi F, Shafaei H, Forouzanfar A, Zarch SH, Merati M. The effect of canine disimpaction performed with temporary anchorage devices (TADs) before comprehensive orthodontic treatment to avoid root resorption of adjacent teeth. *Dental Press J Orthod* 2016;21: 65-72.
15. Weltman B, Vig KW, Fields HW, Shanker S, Kaizar EE. Root resorption associated with orthodontic tooth movement: a systematic review. *Am J Orthod Dentofacial Orthop* 2010;137:462-76.
16. Brezniak N, Wasserstein A. Orthodontically induced inflammatory root resorption. Part I: the basic science aspects. *Angle Orthod* 2002;72:175-9.
17. Killiany DM. Root resorption caused by orthodontic treatment: an evidence-based review of literature. *Semin Orthod* 1999;5:128-33.
18. Huang Y, Wang XX, Zhang J, Liu C. Root shortening in patients treated with two-step and en masse space closure procedures with sliding mechanics. *Angle Orthod* 2010;80:492-7.
19. Linge BO, Linge L. Apical root resorption in upper anterior teeth. *Eur J Orthod* 1983;5:173-83.
20. Woloshyn H, Årtun J, Kennedy DB, Joondeph DR. Pulpal and periodontal reactions to orthodontic alignment of palatally impacted canines. *Angle Orthod* 1994;64:257-64.
21. Linge L, Linge BO. Patient characteristics and treatment variables associated with apical root resorption during orthodontic treatment. *Am J Orthod Dentofacial Orthop* 1991;99:35-43.
22. Schmidt AD, Kokich VG. Periodontal response to early uncovering, autonomous eruption, and orthodontic alignment of palatally impacted maxillary canines. *Am J Orthod Dentofacial Orthop* 2007;131:449-55.
23. Brusveen EM, Brudvik P, Boe OE, Mavragani M. Apical root resorption of incisors after orthodontic treatment of impacted maxillary canines: a radiographic study. *Am J Orthod Dentofacial Orthop* 2012;141:427-35.
24. Silva AC, Capistrano A, Almeida-Pedrin RR, Cardoso MA, Conti AC, Capelozza LF. Root length and alveolar bone level of impacted canines and adjacent teeth after orthodontic traction: a long-term evaluation. *J Appl Oral Sci* 2017;25:75-81.
25. Madsen DP. The impacted canine—an orthodontic perspective. *Ann R Australas Coll Dent Surg* 2012;21:111-2.
26. Lund H, Grondahl K, Hansen K, Grondahl HG. Apical root resorption during orthodontic treatment. A prospective study using cone beam CT. *Angle Orthod* 2012;82:480-7.
27. Steiner C. Cephalometrics for you and me. *Am J Orthod* 1953;39: 729-55.
28. Kim YH, Vietas JJ. Anteroposterior dysplasia indicator: an adjunct to cephalometric differential diagnosis. *Am J Orthod* 1978;73: 619-33.
29. Dahlberg G. Statistical methods for medical and biological students. New York: Interscience Publications; 1940.
30. Crescini A, Clauser C, Giorgetti R, Cortellini P, Pini Prato GP. Tunnel traction of infraosseous impacted maxillary canines. A three-year periodontal follow-up. *Am J Orthod Dentofacial Orthop* 1994;105:61-72.
31. McDonald F, Yap WL. The surgical exposure and application of direct traction of unerupted teeth. *Am J Orthod* 1986;89:331-40.
32. Hosmer DW, Lemeshow S, Sturdivant RX. Applied logistic regression. 3rd ed. Hoboken, NJ: John Wiley & Sons; 2013.
33. American Academy of Oral and Maxillofacial Radiology. Clinical recommendations regarding use of cone beam computed tomography in orthodontics. Position statement by the American Academy of Oral and Maxillofacial Radiology. *Oral Surg Oral Med Oral Pathol Oral Radiol* 2013;116:238-57.
34. American Dental Association. The use of cone-beam computed tomography in dentistry: an advisory statement from the American Dental Association Council on Scientific Affairs. *J Am Dent Assoc* 2012;143:899-902.
35. Stewart JA, Heo G, Glover KE, Williamson PC, Lam EW, Major PW. Factors that relate to treatment duration for patients with palatally impacted maxillary canines. *Am J Orthod Dentofacial Orthop* 2001;119:216-25.

## Influence of impacted maxillary canine orthodontic traction complexity on root resorption of incisors: A retrospective longitudinal study

Luis Ernesto Arriola-Guillén, Gustavo Armando Ruíz-Mora, Yalil Augusto Rodríguez-Cardenas, Aron Aliaga-Del Castillo, Mariana Boessio-Vizzotto, and Heraldo Luis Dias-Da Silveira

Publicado no ***American Journal of Orthodontics & Dentofacial Orthopedics***

*January 2019. Vol 155. Issue 1*

DOI: <https://doi.org/10.1016/j.ajodo.2018.02.011>

# Influence of impacted maxillary canine orthodontic traction complexity on root resorption of incisors: A retrospective longitudinal study

Luis Ernesto Arriola-Guillén,<sup>a</sup> Gustavo Armando Ruíz-Mora,<sup>b</sup> Yalil Augusto Rodríguez-Cárdenas,<sup>c</sup> Aron Aliaga-Del Castillo,<sup>d</sup> Mariana Boessio-Vizzotto,<sup>e</sup> and Herald Luis Dias-Da Silveira<sup>e</sup>  
*Lima, Perú* *Bogotá, Colombia*, *Bauru, São Paulo*, and *Porto Alegre, Rio Grande do Sul, Brazil*

**Introduction:** The orthodontic traction of impacted canines is a procedure of variable complexity. The objective of this study was to determine the influence of this complexity on the root resorption (RR) of adjacent incisors, using cone-beam computed tomography. **Methods:** This longitudinal retrospective study included 45 patients (19 female, 11 male; ages, 18.1667.3 years) with maxillary impacted canines, classified into 2 groups according to the level of orthodontic traction complexity: low complexity group (n = 20) and high complexity group (n = 25). The amounts of RR of 45 maxillary central and 45 lateral incisors were evaluated before and after treatment. Complexity was defined considering impaction sector, eruption inclination angle, and canine position (palatal, buccal, or bicortical). Three orthodontists measured RR in each maxillary incisor. Independent *t* tests or Mann-Whitney U tests were used to compare resorption between groups depending on the normality of the data. A multiple linear regression was calculated to evaluate the influence of all variables on RR ( $\alpha = 0.05$ ). **Results:** RR of maxillary incisors in the sagittal, coronal, and axial sections showed no significant differences between groups ( $P > 0.05$ ). Independently of the groups, RR ranged approximately from 1 to 1.5 mm and from 3 to 4 mm<sup>2</sup>. RR was less than 2 mm<sup>2</sup> in the axial sections. Multiple linear regression indicated no significant influence of orthodontic treatment complexity on RR. Male patients had more RR, specifically in the maxillary central incisors than female patients ( $P < 0.05$ ). **Conclusions:** The complexity of orthodontic traction of impacted maxillary canines is not a risk factor for greater RR of maxillary incisors close to the impaction area. (*Am J Orthod Dentofacial Orthop* 2019;155:28-39)

One undesired side effect after orthodontic treatment is root resorption (RR), mainly of the maxillary incisors.<sup>1-3</sup> RR has been reported in

approximately 60% of treated patients but usually is less than 1 mm.<sup>4</sup> However, in some patients, RR may be severe (more than 4 mm) and could be related to various factors, including root shape and length, long orthodontic treatment, or heavy orthodontic forces.<sup>5</sup> Lateral incisors are usually the most exposed.<sup>1,2</sup> The orthodontic treatment of impacted canines requires special biomechanics,<sup>6</sup> which include forces with different traction vectors supported on the neighboring teeth using large-caliber arches to prevent side effects.<sup>7-10</sup> This situation could increase the risk of RR compared with a conventional orthodontic treatment approach.<sup>11</sup>

The reported prevalences of impacted maxillary canines range from 0.92%<sup>12</sup> to 6.04%<sup>12-14</sup>; this is considered a clinical challenge for orthodontists. The treatment should try to maintain the unerupted teeth to allow the development of the canine eminence, which is important for facial esthetics, and to establish a canine guide that leads to a functional

<sup>a</sup>Divisions of Orthodontics and Oral and Maxillofacial Radiology, School of Dentistry, Universidad Científica del Sur, Lima, Perú

<sup>b</sup>Division of Oral and Maxillofacial Radiology, School of Dentistry, Universidad Científica del Sur, Lima, Perú; Division of Orthodontics, Faculty of Dentistry, Universidad Nacional de Colombia, Bogotá, Colombia; Division of Oral and Maxillofacial Radiology, Faculty of Dentistry, Universidad Nacional de Colombia, Bogotá, Colombia.

<sup>c</sup>Division of Oral and Maxillofacial Radiology, School of Dentistry, Universidad Científica del Sur, Lima, Perú

<sup>d</sup>Department of Orthodontics, Bauru Dental School, University of São Paulo, Bauru, São Paulo, Brazil.

<sup>e</sup>Division of Oral Radiology, Faculty of Dentistry, Federal University of Rio Grande do Sul, Porto Alegre, Rio Grande do Sul, Brazil.

All authors have completed and submitted the ICMJE Form for Disclosure of Potential Conflicts of Interest, and none were reported.

Address correspondence to: Luis Ernesto Arriola-Guillén, Calle Los Girasoles #194, Dpto. #302, Urb. Residencial Los Ingenieros de Valle Hermoso, Santiago de Surco, Lima, Perú; e-mail, [luchoarriola@gmail.com](mailto:luchoarriola@gmail.com).

Submitted, December 2017; revised and accepted, February 2018.  
0889-5406/\$36.00

© 2018 by the American Association of Orthodontists. All rights reserved.  
<https://doi.org/10.1016/j.ajodo.2018.02.011>

occlusion.<sup>15,16</sup> The place of impaction is considered a risk factor for RR, mainly the maxillary incisors. Bicortically impacted canines in the middle of the 2 cortical bones could generate greater RR of the incisors as a result of their eruption.<sup>17,18</sup> Likewise, this condition could be a greater risk for resorption after traction.

The location of impacted canines (palatal, buccal, or bicortical) and the distance to the roots of the maxillary incisors increase the risk of RR by direct contact with them during traction.<sup>17,19</sup> To quantify the severity of canine impaction, several classifications have been made, allowing the orthodontist to estimate how complex the treatment of a specific canine impaction could be.<sup>20-23</sup>

Any orthodontic treatment including canine disimpaction is considered complex.<sup>24,25</sup> However, this complexity varies depending on location, sector, and angle of impaction. Impacted canines closer to the midline have greater complications during treatment. If an impacted canine crosses the midline toward the opposite side, the difficulty of the treatment will be high.<sup>26</sup> The sectors of impaction 4 and 5 (close to the midline) according to the classification proposed by Ericson and Kuroi<sup>23</sup> are the most complex to treat because they require special biomechanics for orthodontic traction. Likewise, the impacting angle clearly compromises the prognosis of the treatment; horizontally impacted canines are more challenging for orthodontists than vertically impacted canines, which have the best prognosis.

It has been reported that there are no significant differences in RR after orthodontic traction in patients with unilateral vs bilateral impacted canines.<sup>27</sup> However, bilateral impaction does not necessarily demand a complex treatment because it could involve 2 vertically impacted canines or could be located between a lateral incisor and a first premolar, with a good prognosis. Otherwise, a unilateral impaction is not always simplified treatment. If it is close to the midline or horizontal, the treatment may be more complex. This is why it was considered important to demonstrate whether a complex canine impaction treatment has a greater risk for RR of the incisors adjacent to the canine impaction. The purpose of this study was to determine the influence of orthodontic traction complexity of impacted maxillary canines on the RR of adjacent incisors.

The null hypothesis was that there is no significant difference in the amount and area of RR of the maxillary incisors after orthodontic traction of impacted canines with different levels of complexity.

## MATERIAL AND METHODS

This retrospective longitudinal study was approved by the ethics and research committee of the Universidad Científica del Sur in Lima, Peru (number 00008). The sample included 45 patients (11 male; 19 female; age, 18.2  $\pm$  6.73 years) with maxillary impacted canines treated in a private orthodontic clinic (G.A.R.M.). Two groups were established according to the level of orthodontic traction treatment complexity: low complexity group (n = 20) and high complexity group (n = 25). In both groups, the RR of the 45 maxillary central and 45 maxillary lateral incisors adjacent to the impacted canines were evaluated before and after traction (90 incisors) using cone-beam computed tomography (CBCT) images. The minimum sample size required was 20 impacted canines per group, determined by a formula to compare 2 means, with a 95% confidence level and 80% test power, when the average difference of RR between groups was 0.5 mm (data from a previous pilot test), and with a standard deviation of 0.64 mm.

The sectors of impaction according to the classification of Ericson and Kuroi<sup>23,28</sup> are presented in [Table I](#). The inclusion criteria were male or female patient with at least 1 impacted canine, with complete records including clinical histories, study models, extraoral and intraoral photographs, panoramic and lateral head films, and CBCT images before treatment and after canine traction.

Patients with periapical lesions circumscribed to the maxillary incisors before orthodontic treatment, with brackets or maxillary surgeries before the study, and with agenesis of a maxillary tooth were excluded.

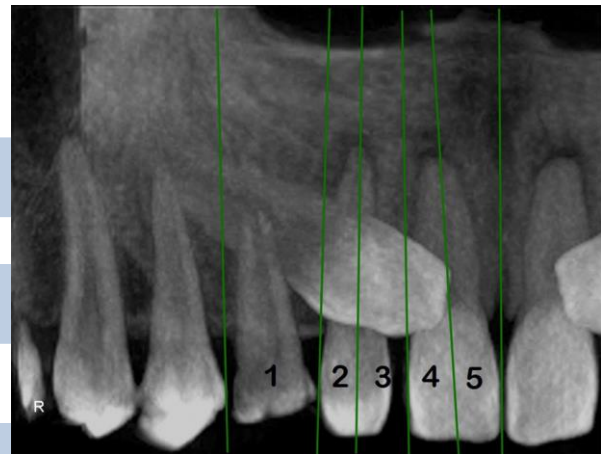
The demographic and occlusal characteristics of the sample are described in [Table II](#).

The low complexity group included patients with impacted maxillary canines in impaction sectors 1, 2, or 3 according to the classification of Ericson and Kuroi<sup>23,28</sup> ([Table I](#), [Fig 1](#)). In the case of sector 3, the angle (angle between the interincisor midline and the long axis of the impacted canine) was 40° or less. Buccally or palatally maxillary impacted canines were included.<sup>23</sup> RR before orthodontic treatment was measured ([Tables III and IV](#)).

The high complexity group included patients with impacted maxillary canines in impaction sectors 3, 4, or 5 according to the classification of Ericson and Kuroi.<sup>23,28</sup> In the case of sector 3, the angle  $\alpha$  was greater than 40°. Buccally, palatally, and bicortically maxillary impacted canines (at the level of the occlusion line or exactly in the middle of the 2 cortical bones) were included ([Tables III and IV](#)).<sup>17,18</sup>

**Table I. Classification of impacted canines of Ericson and Kuroi<sup>28</sup>**

Sector	Definition
1	The cusp tip of the canine is between the mesial aspect of the first premolar and the distal aspect of the lateral incisor
2	The cusp tip of the canine is between the distal aspect of the lateral incisor and the long axis of the lateral incisor
3	The cusp tip of the canine is between the long axis of the lateral incisor and the mesial aspect of the lateral incisor
4	The cusp tip of the canine is between the mesial aspect of the lateral incisor and the long axis of the central incisor
5	The cusp tip of the canine is between the long axis of the central incisor and the interincisor median line



**Fig 1. Sectors of canine impaction, based on the study of Ericson and Kuroi.<sup>28</sup>**

**Table II. Initial characteristics of the sample**

Variable	Condition	Total
Sex	Male	11
	Female	19
Angle malocclusion	Class I	20
	Class II Division 1	0
	Class II Division 2	5
Age (y)	Mean	18.16
	SD	1.32

The angle  $\alpha$ , formed between the long axis of the canine and the long axis of the lateral incisor, was also measured. The canine vertical height was evaluated, measuring the distance as the perpendicular distance from the peak of the impacted canine to the occlusal plane formed by a tangent to the incisal edge of the maxillary central incisor and the occlusal surface of the maxillary first molar (Fig 2).<sup>23,29</sup>

Three trained orthodontists (L.E.A.G., G.A.R.M., and Y.A.R.C.) evaluated the impaction sector and position of the impacted canine in each CBCT image. Interobserver concordance was assessed with the kappa test, with perfect agreement (1.0). For continuous variables, 1 investigator (L.E.A.G.) performed all measurements twice, with a month interval. The intraobserver concordance was evaluated with the intraclass correlation coefficient. Values higher than 0.9 (95% CI, 0.80-0.97) were obtained. Additionally, random errors were calculated with Dahlberg's formula.<sup>30</sup> Dahlberg coefficients were smaller than 1 mm or 1 mm<sup>2</sup> for all variables.

CBCT scans of all patients were taken (PaX-Uni 3D; Vatech, Hwaseong, South Korea) set at 4.7 mA, 89 kV(p), voxel size of 0.125, and exposure time of 15 seconds. Each field of view mode was 8 3 8 cm.<sup>2</sup>

**Table III. Characteristics of the impacted canines according to orthodontic traction complexity**

Measurement Condition	Localization of impaction	Palatal	Buccal	Bicortical	Low complexity	High complexity	Total	P, chi square
					group	group		
Impaction sector	1	10	0	10	10	0	10	<0.001*
	2	9	0	9	9	0	9	
	3	1	10	11	1	10	11	
	4	0	9	9	0	9	9	
	5	0	6	6	0	6	6	
Initial RR	Present	3	15	18	3	15	18	0.002*
	Absent	17	10	27	17	10	27	

\*Statistically significant at  $P \leq 0.05$ .

The DICOM files were imported into 3-dimensional software (version 11.7; Dolphin Imaging, Chatsworth, Calif) to obtain and evaluate multiplanar and 3-dimensional reconstructions.

Root lengths were measured in millimeters on the same longitudinal axis from a perpendicular projection to the vestibular cemento-enamel junction in the sagittal section or mesial cemento-enamel junction in the coronal section up to the vertex of the radicular apices of the central and lateral incisors adjacent to the impacted canine (Figs 3 and 4). Incisor root areas in square millimeters were measured as well. In the sagittal section, the area was measured from the buccal cemento-enamel limit to the palatal cemento-enamel limit (Fig 5). In the coronal section, the area included

Table IV. Measurements of the impacted canines according to orthodontic traction complexity

Measurement	Complexity	n	Mean	SD	P	Mean difference	95% CI	
							Lower	Upper
a angle (°)	Low	20	33.30	17.93	\0.001*	-21.49	-30.29	-12.69
	High	25	54.79	11.15			-21.27	3.74
b angle (°)	Low	20	38.88	19.46	0.165	-8.77	-21.27	3.74
	High	25	47.64	21.58			-3.13	1.85
Height (mm)	Low	20	11.02	5.00	0.606	-0.64	-3.13	1.85
	High	25	11.66	3.24				

\*Statistically significant at  $P \leq 0.05$ . Independent *t* test.

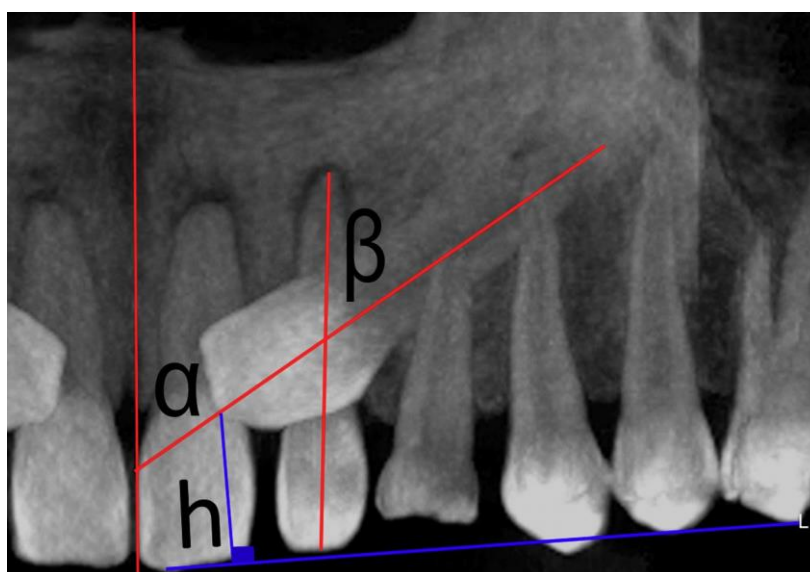


Fig 2. Measurement of angle a, angle b, and height h.

the path from the mesial to the distal cemento-enamel limits (Fig 6). In the axial sections, the area of RR was measured at the level of 2 sectors. The root length on the sagittal section was divided into thirds, and the areas of the cervical and middle thirds in the axial sections were measured.

One rigid temporary anchorage device was installed. The appliance included a palatal acrylic button soldered on the bands in the permanent first molars and a modified palatal arch around the palatal surfaces of all maxillary teeth in 1.1-mm (0.043 in) or 1.2-mm (0.047 in) stainless steel wire (Dentaurum, Ispringen, Germany) with multiple palatal-occlusal-vestibular soldered hooks in 0.028-in wire between the first molar and second premolar, and the second and first premolars, mesial to the first premolar and distal to the lateral incisors (Figs 7 and 8). Vestibular hooks and device extensions allowed regulation of the buckles of closed helicoidal nickel-titanium coil springs, 0.010 3 0.036

in, 8 and 13 mm long, and 100 or 150 g of force (Dentos, Daegu, Korea), to perform intraosseous transalveolar traction. Activations of 4 to 5 mm were performed every 4 to 8 weeks (Fig 9). A passive 0.017 3 0.025-in stainless steel archwire placed on the previously aligned and leveled teeth was cinched distally of the last molar in the anchorage, before the traction. After traction, CBCT images were taken to control the treatment. Then, the final phase was started. All necessary procedures were performed to complete the orthodontic treatment.

RR in each incisor was measured by subtracting the initial value from the final value of length in millimeters and area in square millimeters in the 3 sections evaluated.

#### Statistical analyses

All statistical analyses were performed using SPSS software for Windows (version 19.0; IBM, Armonk,

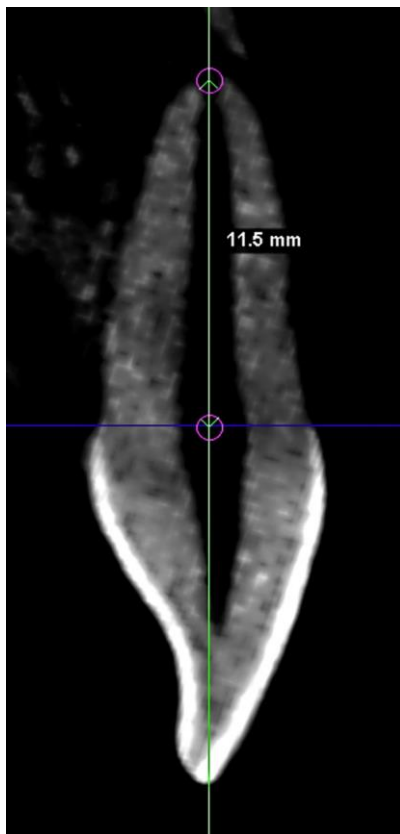


Fig 3. Assessment of the root length in the sagittal plane.

NY). The data distribution was determined by Shapiro-Wilk tests. When the distribution was not normal, comparisons of RR between groups were evaluated with Mann-Whitney U tests; otherwise, we used *t* tests. Finally, a multiple linear regression model to determine the influence of each variable on RR was applied. The significance level was set at  $P \leq 0.05$  for all tests.

## RESULTS

The RR of maxillary incisors in the sagittal and coronal sections showed no significant differences between groups. Altogether, the root length range of RR was 1 to 1.5 mm, and the area range was 3 to 4 mm<sup>2</sup> in both groups (Tables V and VI). No significant differences were found in the axial sections between groups; likewise, the RR area was less than 2 mm<sup>2</sup> in both groups (Table VII).

Multivariate analysis using multiple linear regression with RR as the outcome variable did not show a significant influence on the complexity of orthodontic treatment ( $P = 0.05$ ). However, the variable sex had an influence, specifically on the RR of the maxillary central

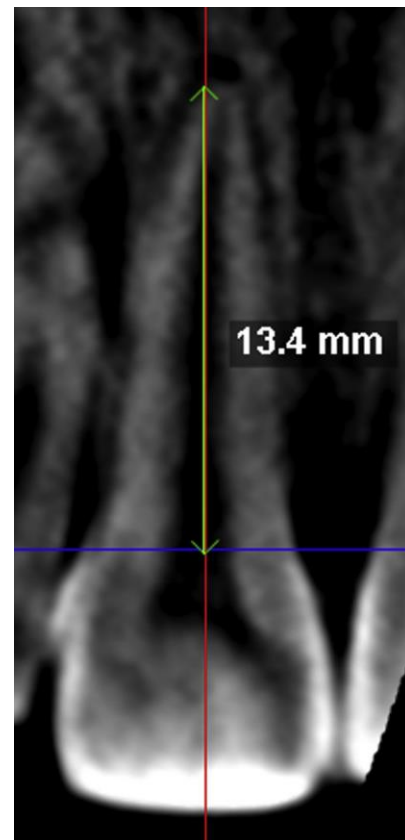


Fig 4. Assessment of the root length in the coronal plane.

incisors, and the location of the impacted canine (palatally displaced) had a significant influence on the RR area of the maxillary central incisor in the coronal section. The impaction height was significant as well ( $P \leq 0.05$ ), and the initial RR was also significant ( $P = 0.003$ ) regarding RR in the maxillary lateral incisor (sagittal section). To further evaluate the specific influence of canine impaction location, this variable was categorized into 2 dummy variables: the first comparing bicortically impacted canines vs palatally and buccally displaced canines ( $P = 0.05$ ), and the second comparing palatally displaced vs bicortically and buccally impacted canines ( $P = 0.012$ , for RR area of central incisors in the sagittal sections) (Tables VIII and IX).

## DISCUSSION

Orthodontists face a great challenge when treating patients with highly complex impacted maxillary canines,<sup>18</sup> particularly when the treatment includes impacted canines close to or in contact with the roots of anterior teeth and when they are horizontally positioned,<sup>25</sup> because the risk for RR of incisors is higher.<sup>31</sup> For these reasons, the aim of this study was to determine



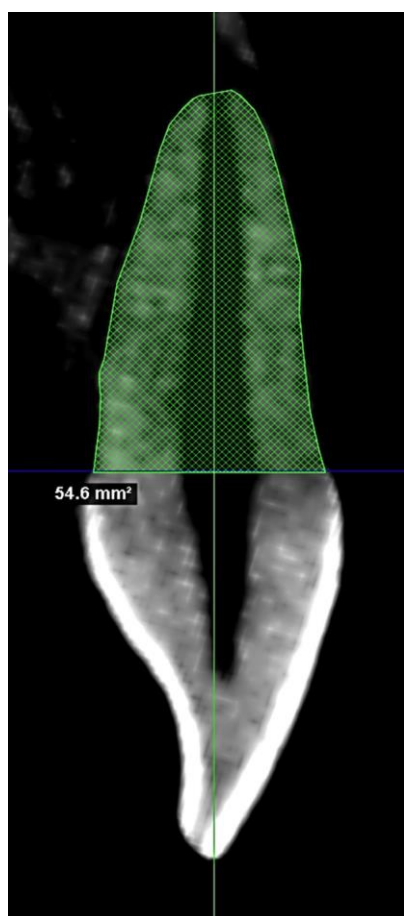


Fig 5. Assessment of the root area in the sagittal plane.

the influence of the orthodontic traction complexity of impacted maxillary canines on the RR of incisors.

The use of CBCT for patients with impacted canines before and during orthodontic treatment, specifically after traction, is based on the ALARA principle.<sup>32</sup> The application of the same technique of traction, with nickel-titanium coil springs and reinforced anchorage ensures that the results can be compared between groups, although the direction of traction changes for each patient.<sup>27</sup> In addition, all patients were treated by 1 expert orthodontist (G.A.R.M.), with more than 20 years of experience with this type of impaction, reducing the possibility of operator bias in the study.

There are few methods that classify the complexity of orthodontic traction of impacted canines,<sup>23,28</sup> and even fewer using CBCT.<sup>21</sup> Moderate concordance has been reported when these methods have been compared with the clinical criteria of experts in this area.<sup>21</sup> The criteria to evaluate computed tomography scans to define the complexity of a patient with impacted canines in the sagittal sections are frequently based on the

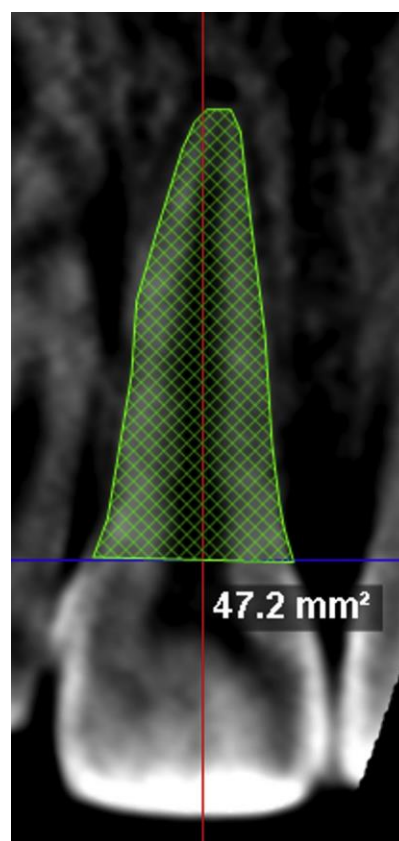


Fig 6. Assessment of the root area in the coronal plane.

classification of Ericson and Kuroi<sup>23,28</sup> or a modifications of it.<sup>29</sup> In sagittal sections, the classifications take into account the height of canine impaction, having as a reference the cusp tip or its root apex; additionally, in the axial section, some classifications evaluate the position of the impacted canine in relation to the line of occlusion to classify it as palatally, buccally, or bicortically centered. In our study, the classification of treatment complexity was made on the sagittal plane based on the impaction sector, classifying as most complex the impactions in sectors 3, 4, and 5 according to the method of Ericson and Kuroi<sup>23,28</sup> due to their proximity to the midline. Regarding sector 3, we also included the measurement of an angle as a classification factor and defined as complex cases those with the highest horizontal tendency: ie, when the angle was greater than 40°. The location in the axial and coronal sections was considered as well, classifying the cases as palatally, buccally, or bicortically impacted, depending on the position of the crown of the impacted canine in relation to the incisor radius: ie, the occlusion line and based on a clear tomographic examination in both cuts, which was

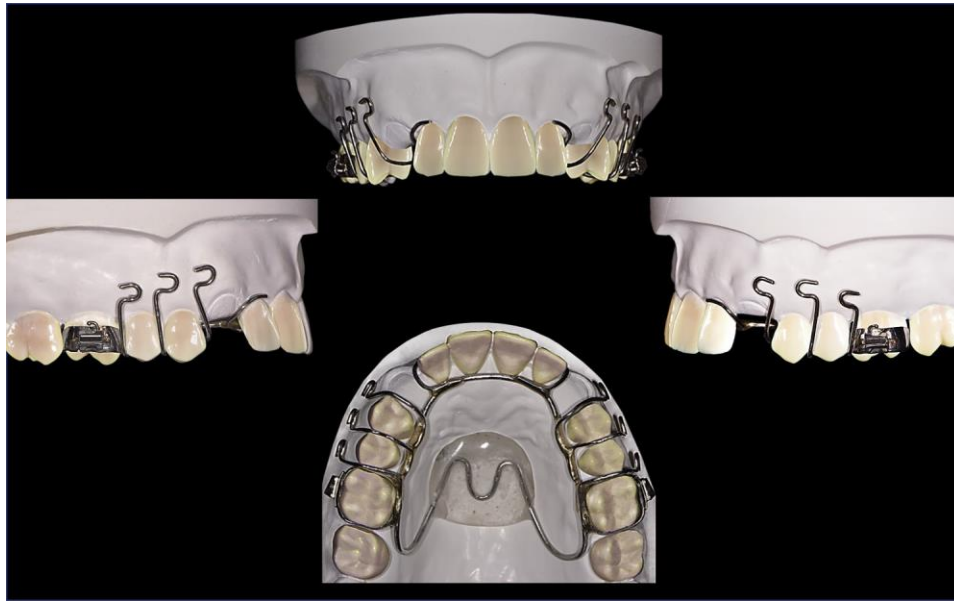

Fig 7. Graphic representation of the anchor including buccal extensions to favor the traction of impacted canines.

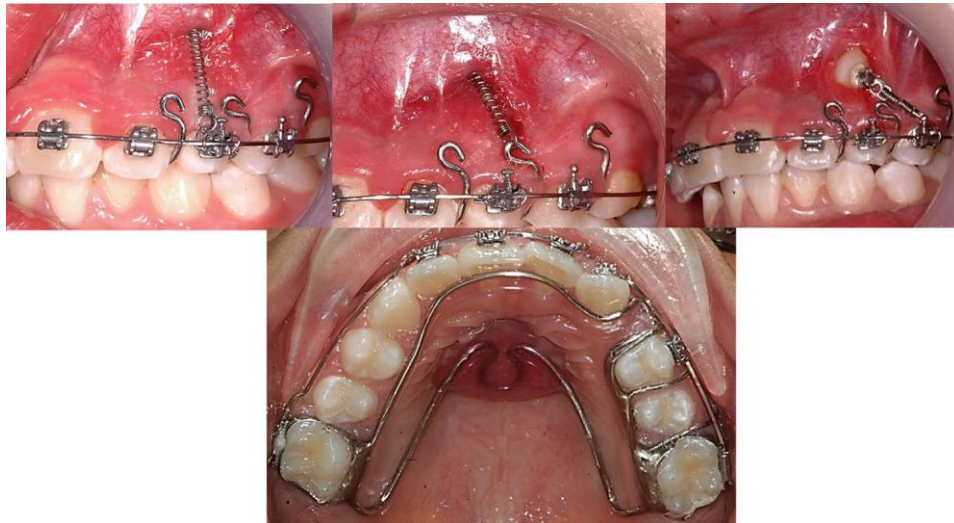


Fig 8. Example of impacted canine traction and rigid temporary anchorage device placed on permanent first molars with rigid palatal acrylic button.

reliable as shown by perfect interobserver agreement using the kappa test. Patients with bicortically impacted canines (in the middle of the 2 cortical bones)<sup>17,18</sup> (Fig 10) were defined as more complex, due to their proximity to the incisor roots (close to the midline, sectors 4 and 5)<sup>23,28</sup> before orthodontic treatment. Although buccally and palatally impacted canines were included in both groups, bicortically

impacted canines were included only in the high complexity group. Additionally, in all cases of close proximity or physical contact, RR was observed before starting canine traction. However, after finishing traction, this RR did not increase significantly and did not show differences compared with the RR after traction in the low complexity group. Nevertheless, future studies including only subjects with bicortical

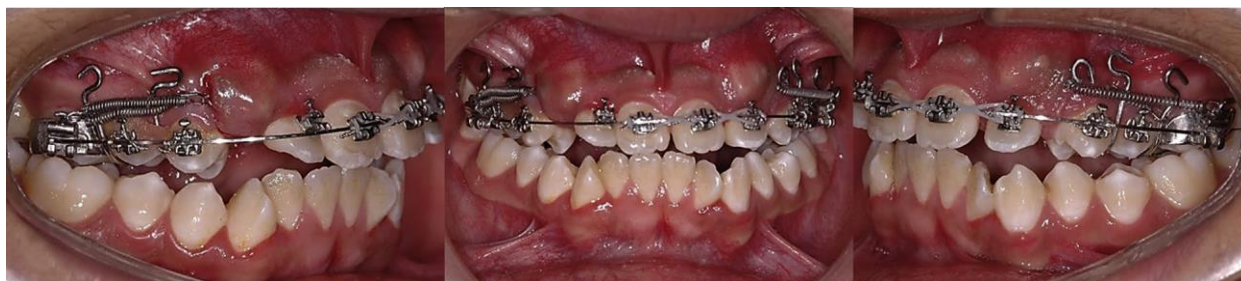

Fig 9. Example of bilateral impacted canine traction.

Table V. Comparison of RR of maxillary incisors and area according to orthodontic traction complexity, sagittal section

Tooth	Measurements	Low complexity (n 5 20)		High complexity (n 5 25)		Mean difference	95% CI		P
		Mean	SD	Mean	SD		Lower limit	Upper limit	
Maxillary lateral incisor	Root resorption (mm)	1.27	1.09	1.28	0.95	-0.01	-0.63	0.60	0.964
	Resorption area (mm <sup>2</sup> )	2.93	3.09	3.15	2.52	-0.22	-1.91	1.46	0.791
Maxillary central incisor	Root resorption (mm)	1.45	1.18	1.56	1.03	-0.11	-0.78	0.55	0.731
	Resorption area (mm <sup>2</sup> )	3.62	3.14	3.44	3.18	0.17	-1.74	2.09	0.858

Independent t test.

Table VI. Comparison of RR of maxillary incisors and area according to orthodontic traction complexity, coronal section

Tooth	Measurement	Low complexity (n 5 20)		High complexity (n 5 25)		Mean difference	95% CI		P
		Mean	SD	Mean	SD		Lower limit	Upper limit	
Maxillary lateral incisor	Root resorption (mm)	1.58	1.03	1.28	1.13	0.30	-0.35	0.96	0.355
	Resorption area (mm <sup>2</sup> )	3.26	2.37	2.45	1.85	0.81	-0.46	2.07	0.205
Maxillary central incisor	Root resorption (mm)	1.55	1.05	1.32	1.02	0.23	-0.39	0.86	0.454
	Resorption area (mm <sup>2</sup> )	3.47	3.41	4.08	3.09	-0.61	-2.57	1.35	0.532

Independent t test.

Table VII. Comparison of the area (mm<sup>2</sup>) of RR of maxillary incisors at the cervical and middle thirds according to orthodontic traction complexity, axial section

Tooth	Measurement	Low complexity (n 5 20)		High complexity (n 5 25)		Mean difference	95% CI		P
		Mean	SD	Mean	SD		Lower limit	Upper limit	
Maxillary lateral incisor	Cervical third	0.43	0.53	0.99	1.42	-0.57	-1.24	0.11	0.166
	Middle third	0.81	0.94	1.48	1.80	-0.67	-1.57	0.23	0.534
Maxillary central incisor	Cervical third	0.69	1.00	1.15	1.62	-0.46	-1.30	0.37	0.341
	Middle third	1.36	1.91	1.67	2.70	-0.31	-1.75	1.13	0.768

Mann-Whitney U test.

impaction should be carried out to confirm our results. Canine impaction height is not an exclusive complexity criterion, since an impaction with low height but close to the midline would be difficult to treat, whereas a patient with a higher canine impaction in sector I

would not have an increased risk of RR of the anterior teeth because the canine has no contact with their roots. Orthodontists frequently treat impacted canines with RR in the maxillary incisors.<sup>33</sup> This condition is only a caution factor, demanding the use of efficient

Table VIII. Multiple linear regression analysis of RR (mm) and area of maxillary incisors, sagittal section

Predictor variable	Maxillary lateral incisor		Maxillary central incisor	
	b	P	b	P
Root resorption (mm)				
Constant		0.298		0.206
Orthodontic traction complexity	-0.01	0.970	0.68	0.085
Sex	0.03	0.867	-0.29	0.173
Age	-0.07	0.698	-0.02	0.901
Duration of traction	-0.18	0.366	0.11	0.589
Dummy 1 (palatine and buccal vs bicortical)	-0.33	0.200	0.07	0.796
Dummy 2 (palatine vs buccal and bicortical)	0.24	0.357	-0.39	0.170
Sector of impacted canine	0.43	0.218	-0.33	0.364
Initial root resorption	0.78	0.003*	0.03	0.896
Angle a of impacted canine	-0.45	0.303	-0.63	0.165
Angle b of impacted canine	0.58	0.062	-0.09	0.805
Height of impacted canine	-0.23	0.486	0.58	0.107
Initial root length	0.15	0.535	-0.07	0.822
$r^2$		0.197		0.155
Area of root resorption (mm <sup>2</sup> )				
Constant		0.082		0.029*
Orthodontic traction complexity	0.10	0.784	0.70	0.056
Sex	-0.14	0.489	-0.49	0.010*
Age	0.06	0.747	0.01	0.925
Duration of traction	-0.15	0.442	0.06	0.727
Dummy 1 (Palatine and Buccal vs Bicortical)	-0.30	0.219	-0.19	0.385
Dummy 2 (Palatine vs Buccal and Bicortical)	-0.01	0.982	-0.59	0.012*
Sector of impacted canine	0.42	0.219	-0.29	0.340
Initial root resorption	0.34	0.168	0.27	0.249
Angle a of impacted canine	-0.71	0.094	-0.76	0.053
Angle b of impacted canine	0.53	0.084	-0.05	0.864
Height of impacted canine	-0.05	0.882	0.69	0.024*
Initial root length	-0.04	0.870	-0.25	0.308
$r^2$		0.242		0.380

Dummy 1, location of impacted canine (palatine and buccal vs bicortical).

Dummy 2, location of impacted canine (palatine vs buccal and bicortical).

\*Statistically significant at  $P \leq 0.05$ .

biomechanics with optimal forces to prevent greater radicular resorption. In the high complexity treatment group, 60% of the patients had initial RR, making treatment even more difficult, compared with 15% of the patients with this condition in the low complexity group. We considered that the initial RR of adjacent permanent teeth during maxillary canine eruption could be, according to the literature, more an effect of the physical contacts between the erupting canine and the adjacent tooth than the action of the dental follicle size.<sup>34,35</sup> Likewise, although in the high complexity group the RR condition was more frequent at the beginning of treatment, the RR after traction was similar in both groups; therefore, it is not apparently a risk factor. However, more studies evaluating this condition must be carried out.

The amount of RR in both groups (high complexity vs low complexity) was similar and smaller than 2 mm. This amount of RR does not depict risk for oral or tooth

health that could lead to tooth loss. The RR was approximately 1 to 1.5 mm and was smaller than 4 mm<sup>2</sup> in the sagittal and coronal sections; for the axial section, no significant differences were found.

The multivariate analysis did not identify a common risk factor, including the influence of the orthodontic traction complexity. We only detected the influence of sex, indicated by a higher risk of resorption in male patients. The effect of sex is controversial and considered in few studies evaluating RR after traction of impacted canines.<sup>36-38</sup> One study found no significant differences regarding sex.<sup>36</sup> Recent studies have concluded that after conventional orthodontic treatment without treating impacted canines, sex does not influence RR of the incisors.<sup>39,40</sup> Nevertheless, this information cannot be extrapolated to treatments with canine impaction. In our study, the influence of sex was seen only for some comparisons: specifically, the maxillary central incisor. However, an explanation that supports the appearance

Table IX. Multiple linear regression analysis of RR and area of maxillary incisors, coronal section

Predictor variable	Maxillary lateral incisor		Maxillary central incisor	
	b	P	b	P
<b>Root resorption (mm)</b>				
Constant		0.939		0.047*
Orthodontic traction complexity	0.34	0.330	0.52	0.120
Sex	-0.18	0.334	-0.45	0.020*
Age	-0.20	0.211	-0.06	0.704
Duration of traction	0.37	0.054	0.02	0.914
Dummy 1 (palatine and buccal vs bicortical)	0.18	0.424	-0.54	0.053
Dummy 2 (palatine vs buccal and bicortical)	0.03	0.888	-0.29	0.207
Sector of impacted canine	-0.11	0.719	-0.31	0.305
Initial root resorption	0.30	0.290	0.17	0.449
Angle a of impacted canine	-0.40	0.321	-0.30	0.427
Angle b of impacted canine	-0.07	0.827	-0.24	0.417
Height of impacted canine	-0.05	0.862	0.53	0.078
Initial root length	0.53	0.022*	-0.26	0.384
$r^2$		0.338		0.387
<b>Area of root resorption (mm<sup>2</sup>)</b>				
Constant		0.083		0.034*
Orthodontic traction complexity	0.14	0.665	0.40	0.255
Sex	-0.50	0.014*	-0.63	0.003*
Age	-0.22	0.155	0.19	0.236
Duration of traction	0.22	0.200	0.04	0.815
Dummy 1 (palatine and buccal vs bicortical)	-0.14	0.513	-0.28	0.228
Dummy 2 (palatine vs buccal and bicortical)	-0.05	0.815	-0.23	0.329
Sector of impacted canine	-0.01	0.980	-0.23	0.470
Initial root resorption	0.16	0.435	-0.10	0.627
Angle a of impacted canine	-0.09	0.811	-0.02	0.959
Angle b of impacted canine	-0.42	0.139	-0.49	0.086
Height of impacted canine	-0.10	0.731	0.43	0.164
Initial root length	0.26	0.225	-0.31	0.171
$r^2$		0.412		0.332

Dummy 1, location of impacted canine (palatine and buccal vs bicortical).

Dummy 2, location of impacted canine (palatine vs buccal and bicortical).

\*Statistically significant at  $P \leq 0.05$ .

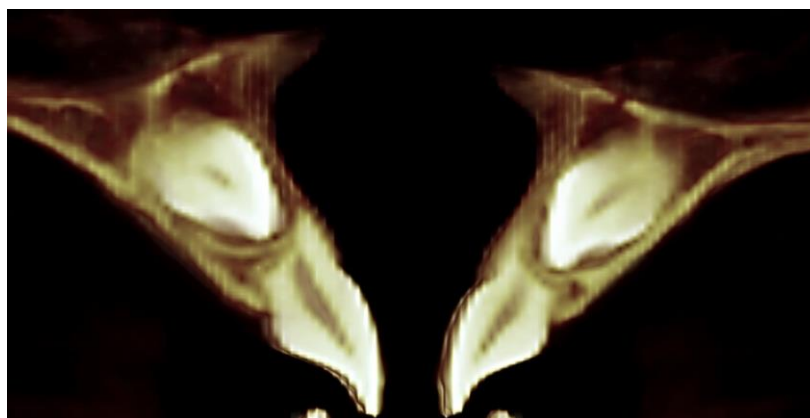


Fig 10. Example of maxillary impacted canine in intermediate position or centered bicortically.

of the RR in this tooth can only be based on future studies with larger samples of both sexes. If any predictor variable is truly a risk factor for RR, its

influence should have been consistent across all CBCT scans analyzed and could be present in both incisors and not only one.

In this study, the null hypothesis was accepted: there is no significant difference in the amount and area of RR of the maxillary incisors after orthodontic traction of impacted canines with different levels of complexity. This RR behavior could allow the orthodontist to treat patients with impacted canines in complex positions, since there is not a greater risk of RR.

## CONCLUSIONS

The orthodontic traction complexity of impacted maxillary canines is not a risk factor for greater RR of the maxillary incisors.

## REFERENCES

1. Weltman B, Vig KW, Fields HW, Shanker S, Kaizar EE. Root resorption associated with orthodontic tooth movement: a systematic review. *Am J Orthod Dentofacial Orthop* 2010;137:462-76: discussion, 412A.
2. Brezniak N, Wasserstein A. Orthodontically induced inflammatory root resorption. Part I: the basic science aspects. *Angle Orthod* 2002;72:175-9.
3. Killiany DM. Root resorption caused by orthodontic treatment: an evidence-based review of literature. *Semin Orthod* 1999;5:128-33.
4. Lund H, Grondahl K, Hansen K, Grondahl HG. Apical root resorption during orthodontic treatment. A prospective study using cone beam CT. *Angle Orthod* 2012;82:480-7.
5. Makedonas D, Lund H, Grondahl K, Hansen K. Root resorption diagnosed with cone beam computed tomography after 6 months of orthodontic treatment with fixed appliance and the relation to risk factors. *Angle Orthod* 2012;82:196-201.
6. Yadav S, Chen J, Upadhyay M, Jiang F, Roberts WE. Comparison of the force systems of 3 appliances on palatally impacted canines. *Am J Orthod Dentofacial Orthop* 2011;139:206-13.
7. Oppenhuizen G. An extrusion spring for palatally impacted cuspids. *J Clin Orthod* 2003;37:434-6.
8. Thebault B, Dutertre E. Disimpaction of maxillary canines using temporary bone anchorage and cantilever springs. *Int Orthod* 2015;13:61-80.
9. Bowman SJ, Carano A. The Kilroy spring for impacted teeth. *J Clin Orthod* 2003;37:683-8.
10. Jacoby H. The "ballista spring" system for impacted teeth. *Am J Orthod* 1979;75:143-51.
11. Woloshyn H, Årtun J, Kennedy DB, Joondeph DR. Pulpal and periodontal reactions to orthodontic alignment of palatally impacted canines. *Angle Orthod* 1994;64:257-64.
12. Grover PS, Lorton L. The incidence of unerupted permanent teeth and related clinical cases. *Oral Surg Oral Med Oral Pathol* 1985;59:420-5.
13. Herrera-Atoche JR, Aguayo-de-Pau MD, Escoffie-Ramirez M, Aguilar-Ayala FJ, Carrillo-Avila BA, Rejon-Peraza ME. Impacted maxillary canine prevalence and its association with other dental anomalies in a Mexican population. *Int J Dent* 2017;2017:7326061.
14. D'Oleo-Aracena MF, Arriola-Guillén LE, Rodríguez-Cardenas YA, Ruíz-Mora GA. Skeletal and dentoalveolar bilateral dimensions in unilateral palatally impacted canine using cone beam computed tomography. *Prog Orthod* 2017;18:7.
15. Abduo J, Tennant M. Impact of lateral occlusion schemes: a systematic review. *J Prosthet Dent* 2015;114:193-204.
16. Miralles R. Canine-guide occlusion and group function occlusion are equally acceptable when restoring the dentition. *J Evid Based Dent Pract* 2016;16:41-3.
17. Chaushu S, Kaczor-Urbanowicz K, Zadurska M, Becker A. Predisposing factors for severe incisor root resorption associated with impacted maxillary canines. *Am J Orthod Dentofacial Orthop* 2015;147:52-60.
18. Cuminetti F, Boutin F, Frapier L. Predictive factors for resorption of teeth adjacent to impacted maxillary canines. *Int Orthod* 2017;15:54-68.
19. Yan B, Sun Z, Fields H, Wang L. Maxillary canine impaction increases root resorption risk of adjacent teeth: a problem of physical proximity. *Orthod Fr* 2015;86:169-79.
20. Al-Zoubi H, Alharbi AA, Ferguson DJ, Zafar MS. Frequency of impacted teeth and categorization of impacted canines: a retrospective radiographic study using orthopantomograms. *Eur J Dent* 2017;11:117-21.
21. Kau CH, Lee JJ, Souccar NM. The validation of a novel index assessing canine impactions. *Eur J Dent* 2013;7:399-404.
22. Dalessandri D, Migliorati M, Rubiano R, Visconti L, Contardo L, Di Lenarda R, et al. Reliability of a novel CBCT-based 3D classification system for maxillary canine impactions in orthodontics: the KPG index. *ScientificWorldJournal* 2013;2013:921234.
23. Ericson S, Kuroi J. Radiographic examination of ectopically erupting maxillary canines. *Am J Orthod Dentofacial Orthop* 1987;91:483-92.
24. Nakandakari C, Goncalves JR, Cassano DS, Raveli TB, Bianchi J, Raveli DB. Orthodontic traction of impacted canine using cantilever. *Case Rep Dent* 2016;2016:4386464.
25. Bayram M, Ozer M, Sener I. Maxillary canine impactions related to impacted central incisors: two case reports. *J Contemp Dent Pract* 2007;8:72-81.
26. Farronato G, Giannini L, Folegatti C, Brotto E, Galbiati G, Maspero C. Impacted maxillary canine on the position of the central incisor: surgical-orthodontic repositioning. *Minerva Stomatol* 2013;62:117-25.
27. Arriola-Guillén LE, Ruíz-Mora GA, Rodríguez-Cardenas YA, Aliaga-Del Castillo A, Dias-Da Silveira HL. Root resorption of maxillary incisors after traction of unilateral vs bilateral impacted canine with a reinforced anchorage. *Am J Orthod Dentofacial Orthop* 2018: (in press).
28. Ericson S, Kuroi J. Early treatment of palatally erupting maxillary canines by extraction of the primary canines. *Eur J Orthod* 1988;10:283-95.
29. Kumar S, Mehrotra P, Bhagchandani J, Singh A, Garg A, Kumar S, et al. Localization of impacted canines. *J Clin Diagn Res* 2015;9:ZE11-4.
30. Dahlberg G. Statistical methods for medical and biological students. New York: Interscience Publications; 1940.
31. Abbott PV. Prevention and management of external inflammatory resorption following trauma to teeth. *Aust Dent J* 2016;61(Suppl 1):82-94.
32. American Academy of Oral and Maxillofacial Radiology. Clinical recommendations regarding use of cone beam computed tomography in orthodontics [corrected]. Position statement by the American Academy of Oral and Maxillofacial Radiology. *Oral Surg Oral Med Oral Pathol Oral Radiol* 2013;116:238-57.
33. Ucar FI, Celebi AA, Tan E, Topcuoglu T, Sekerci AE. Effects of impacted maxillary canines on root resorption of lateral incisors: a cone beam computed tomography study. *J Orofac Orthop* 2017;78:233-40.
34. Ericson S, Bjerklín K, Falahat B. Does the canine dental follicle cause resorption of permanent incisor roots? A computed

- tomographic study of erupting maxillary canines. *Angle Orthod* 2002;72:95-104.
35. Ericson S, Bjerklín K. The dental follicle in normally and ectopically erupting maxillary canines: a computed tomography study. *Angle Orthod* 2001;71:333-42.
  36. Lempesi E, Pandis N, Fleming PS, Mavragani M. A comparison of apical root resorption after orthodontic treatment with surgical exposure and traction of maxillary impacted canines versus that without impactions. *Eur J Orthod* 2014;36:690-7.
  37. Heravi F, Shafae H, Forouzanfar A, Zarch SH, Merati M. The effect of canine disimpaction performed with temporary anchorage devices (TADs) before comprehensive orthodontic treatment to avoid root resorption of adjacent teeth. *Dental Press J Orthod* 2016;21:65-72.
  38. Brusveen EM, Brudvik P, Boe OE, Mavragani M. Apical root resorption of incisors after orthodontic treatment of impacted maxillary canines: a radiographic study. *Am J Orthod Dentofacial Orthop* 2012;141:427-35.
  39. Tieu LD, Saltaji H, Normando D, Flores-Mir C. Radiologically determined orthodontically induced external apical root resorption in incisors after non-surgical orthodontic treatment of class II division I malocclusion: a systematic review. *Prog Orthod* 2014;15:48.
  40. Elhaddaoui R, Qoraich HS, Bahije L, Zaoui F. Orthodontic aligners and root resorption: a systematic review. *Int Orthod* 2017;15:1-12.

## 3-Dimensional Evaluation of Root Resorption of Maxillary Incisors After Orthodontic Traction of Bi-Cortically Impacted Canines

Luis Ernesto Arriola-Guillén, Gustavo Armando Ruíz-Mora, Yalil Augusto Rodríguez-Cardenas, Aron Aliaga-Del Castillo, Schilling Juan, and Heraldo Luis Dias-Da Silveira

Aceito no ***Progress in Orthodontics***

*March 2019.*



## ABSTRACT

**Background:** Root resorption of maxillary incisors after orthodontic traction of impacted canines is a concern for clinicians. The aim of this study was to evaluate, through 3-dimensional superimposition, the root resorption of maxillary incisors after traction until the occlusal plane of bi-cortically impacted canines located in a complex position.

**Methods:** This case series study describes the root resorption of maxillary incisors after orthodontic traction with Ni-Ti closed coil springs and a heavy anchorage appliance used in three cases with bilateral impacted canines located in a complex position (bi-cortically) and near to midline. Cone-beam computed tomographies (CBCTs) were obtained before and after traction. Root resorption of maxillary incisors was evaluated with color-coded maps using ITK-SNAP and 3D Slicer software.

**Results:** The radicular changes mainly occurred in the apical third of the root of maxillary incisors and did not exceed 2mm.

**Conclusions:** Root resorption of maxillary incisors after traction of bi-cortically impacted canines located in a complex position was observed mainly in the apex region and the amount of root resorption was smaller than 2 mm in all radicular surfaces.

**Key words:** Root resorptions, Canine tooth, Cone-beam CT

## Background

The location of impacted canines has been typically classified into two alternatives, i.e. buccal or palatal impacted canine [1-6]. However, in a smaller percentage (approximately 6.6%), the canines may be impacted in the middle of the alveolar process [7], or exactly between the two cortical bones (bi-cortical) and cannot be classified as buccal or palatal [8,9]. These bi-cortically impacted canines, when located in sector 4 or 5 according to Ericson and Kuroi classification [10], i.e. near the midline, constitute a greater risk factor for root resorption of maxillary incisors due to the direct contact that they present.

Orthodontic traction of bi-cortically impacted canines is considered a highly complex orthodontic treatment, due to their direct contact with the root surfaces of the maxillary incisors. Root resorption of maxillary incisors prior to orthodontic treatment could be observed in some cases with impacted canines [11], but is more frequent in this type of impaction because its unfavorable eruption trajectory compared to buccal or palatal impaction [7]. This could increase the risk of root resorption when orthodontic disimpaction is performed due to the contact between the maxillary incisor root and the crown of the impacted canine [12]. Although the prognosis of these maxillary incisors is reserved, keeping them in mouth could be preferred to preserve alveolar bone ridge, especially in younger patients.

Root resorption of maxillary incisors has been mainly evaluated by length, area and with score systems [13,14]. Nevertheless, this information has not been presented yet using 3-dimensional superimposition and it would be interesting to estimate and visualize the 3-dimensional changes produced by canine traction and detect their location, specially, in complex impacted canines. The American Academy of Oral and Maxillofacial Radiology, based on ALARA principle supports the use of Cone-Beam Computed Tomography (CBCT) to evaluate impacted canines before and during orthodontic treatment and control some negative effects that could be observed [15]. Also, it is possible to know what is happening with the structures surrounding the impacted canine, including the resorption produced in the incisor root.

Methods that allow 3-dimensional superimpositions of craniofacial structures have been widely studied [16-21], and their use have increased in the last years since it permits a quantitative and qualitative evaluation of the changes produced by growth or by different treatment approaches [18-22]. Among the different analyses that could be performed with 3-dimensional superimpositions, the color-coded maps permit an

interactive visual analytic evaluation of surface displacements [16,18,21-23]. In this way, it could be applied to evaluate root resorption after orthodontic traction of impacted canines. Thus, the purpose of this case series study was to evaluate the root resorption of maxillary incisors after traction of bi-cortically impacted canines located in a complex position, through 3-dimensional superimposition and using color-coded surface maps.

### **Materials and methods**

This case series study was approved by the Ethics and Research Committee of the Universidad Científica del Sur (N ° 00012). All patients and their parents, when necessary, provided informed consent before treatment. Three patients with bilateral canine impaction, that had in total 5 bi-cortically maxillary impacted canines and 1 buccal impacted canine, were treated by one well trained orthodontist (G.A.R.M) in his private practice (Bogotá, Colombia).

The impacted canines were initially diagnosed in the panoramic radiographs. Then, CBCTs were used to deeply study the cases. The characteristics of the impacted canines in the three patients were described in Table 1.

Case 1 was a 19-year-old female, with Angle Class I malocclusion and Class I Skeletal relationship (Table 1). The impaction sector in both sides was defined as sector 5 according to Ericson and Kurol classification [10], and both impacted canines were bicortically located (Fig. 1). Case 2 was a 36-year-old male with Angle Class I malocclusion and Class I Skeletal relationship (Table 1). The impaction sector in the left side was defined as sector 5 and in the right side as sector 4 according to Ericson and Kurol classification [10], and the location for both impacted canines was bicortical (Fig. 2). Finally, Case 3 was a 13-year-old female with Angle Class I malocclusion, and Class I Skeletal relationship (Table 1). The impaction sector in the right side was classified as sector 3 and in the left side was defined as sector 2 according to Ericson and Kurol classification [10], the right impacted canine was bicortically located and the left impacted canine was located by buccal (Fig. 3).

In the three cases the main objective was to traction all maxillary impacted canines to the occlusal plane, avoiding greater root resorption of the maxillary incisors to ensure an acceptable dental health status in the three cases. Deciduous canines were extracted when present (Case 1 and 2). All impacted canines were orthodontically

tractioned with the same orthodontic mechanics. NiTi closed coil springs and a single rigid heavy reinforced anchorage were used (Fig. 4). The treatment plan for three cases included fixed orthodontic appliances with 0.022" x 0.028" slot metal brackets (Synergy RMO, Inc. Rocky Mountain Orthodontics Denver, Colorado, USA) and traction of both impacted canines was obtained using NiTi closed coil springs 0,010"x 0,036" 8mm and 13mm long and 150g force (Dentos Inc. Daegu, Korea) fastened to vestibular hooks in 0.028" stainless steel wire. These vestibular hooks were welded to the anchorage appliance that included a rigid palatal acrylic button and an arch over the palatal surfaces of all maxillary teeth present in 1.2mm (0.047") stainless steel wire (Dentaurum, GmbH & Co., Ispringen, Germany). All parts of the anchorage appliance were welded in bands that were cemented in first permanent molars (Fig. 4). The activations were of 4mm to 5mm every 4 weeks. The canines were tractioned until they reached the occlusal plane.

CBCT records were obtained at pretreatment ( $T_0$ ) and after orthodontic traction of maxillary impacted canines, when the treated canine reached the occlusal plane ( $T_1$ ), to evaluate any undesirable effect of traction mechanics on maxillary teeth. All CBCT scans were obtained using PaX-Uni 3D (Vatech Co., Ltd., Hwaseong, South Korea) with the following parameters: 4.7 mA, 89 KVP and exposure time 15 seconds. Each field of view mode was 8cm x 8cm, with a voxel size of 0.2 mm.

For the evaluation of root resorption of maxillary incisors, 3-dimensional superimposition of  $T_1$  on  $T_0$  CBCT scans followed by color-coded maps evaluation were performed as follows:

First, the maxillary anterior teeth were segmented for the  $T_0$  and  $T_1$  CBCT scans to create volumetric label maps by using ITK- SNAP version 2.4 (open source software; [www.itksnap.org](http://www.itksnap.org)). Then, the virtual 3-dimensional surface models were created from the  $T_0$  and  $T_1$  volumetric label maps using the 3D Slicer CMF software (open source software; version 4.0; <http://www.slicer.org>).

For the 3-dimensional superimposition (registration), the  $T_1$  scan was registered on the  $T_0$  scan, and using the root region at the enamel-cement junction level as best fit reference, a fully automated voxel-based registration was performed by the 3D Slicer CMF software [17,22].

After the registration phase, color-coded maps were used to visually analyze the 3D surface displacement (distance) between the two models [24,25], using the same software. The 3D distances in mm between the two surface models at any point of the

radicular surfaces, above the root region used for the registration phase, could be evaluated [17,21,22].

For this specific study, the color-coded surface distance maps showed the root displacements between  $T_0$  and  $T_1$  models ranging from  $-2\text{mm}$  to  $+2\text{mm}$ . The red color indicates structure loss.

## Results

The duration of traction in case 1 was 14 months (Fig. 5). In case 2, the duration of traction was 8 months (Fig. 6). Finally; in case 3, the duration of traction was 7 months (Fig. 7). In all three patients, both maxillary impacted canines were tractioned.

The entire procedure of 3-dimensional superimpositions was performed by a calibrated oral radiologist (J.S) who performed all procedures twice with an interval of one month between both evaluations.

The color-coded surface distance maps showed changes (resorption) mainly in the apical third of the root of maxillary incisors and these changes did not exceed 2mm (Fig. 8). The red color indicated structure loss and the blue or green colors indicate a little or no change, respectively.

## Discussion

The purpose of this case series study was to visually quantify the amount of root resorption that occurs after orthodontic traction of impacted canines until the occlusal plane, specifically evaluating cases with bicortical canine impaction and very close to the midline. For this analysis, color-coded surface distance maps obtained by 3-dimensional superimpositions of initial CBCTs and those taken after canine disimpaction were used. This method of evaluation was used in previous research [16-23]. Even though this method has been widely used to evaluate the changes produced by growth or different treatments [18-22], it has not been used to evaluate root resorption after canine disimpaction, yet. Therefore, this study makes an effort in using this type of 3-dimensional analysis in root resorption evaluation field. The strength of this method is that allows to easily identify the regions and quantify the amount of root resorption by visual examination.

The voxel-based image registration method was used to perform the 3-dimensional superimposition. This has been reported as an accurate and reproducible semi-

automated technique for 3D CBCT superimposition and its use has been increased in the last years [16-24,26-29]. Because the method requires skill and expertise to handle the specific software, all 3-dimensional superimpositions were performed by an expert and calibrated radiologist (J.S.), which ensured the reliability of the results.

Bi-cortically impacted canines, which are close to midline, are considered a risk factor for root resorption of maxillary incisors, due to the proximity or direct contact with their roots [7-9]. Therefore, its orthodontic traction may have some complexity because canine traction could increase the contact between the canine and incisors root. For this reason, special orthodontic biomechanics should be considered. In this study, the orthodontic traction was performed exclusively by one expert orthodontist, with more than 20 years of experience in the treatment of impacted canines (G.A.R.M), ensuring a single traction technique and the efficiency of treatments.

The cases presented in this study had complex impacted canines, characterized by their location, type of impaction and great amount of initial root resorption in at least one maxillary incisor. Based on these reasons a special method for its traction was necessary. The orthodontic treatment included three specific characteristics: the use of a heavy orthodontic reinforced anchorage (1.2" stainless steel wire) [14]; the use of continuous tensile forces produced by the NiTi closed coil springs; and the use of wire extensions (hooks) derived from the anchor unit, that allowed the control of the traction direction and further prevented the contact of coil springs with the gingiva. The idea with this treatment protocol was to avoid any undesirable effect on the maxillary incisors.

Despite the difficulty of the orthodontic traction of maxillary impacted canines, the amount of root resorption of maxillary incisors found in these cases was clinically acceptable. Root resorption was mainly located in the apical region and no incisor showed root resorption greater than 2 mm. An important characteristic observed in these patients was the irregular morphology of the maxillary incisor roots at pretreatment, with some regions showing considerable root resorption. These regions were the ones where root resorption was evident after traction. Again, these root resorptions were mainly observed at the apical third. Likewise, no root resorption was observed in the middle or cervical thirds, as showed in the color-coded maps of all 3-dimensional superimpositions.

This study aimed to evaluate the root resorption of incisors after completing the traction of impacted canines to the occlusal plane, which is a critical phase of

orthodontic treatment in this type of malocclusions due to the greater risk of contacting the canine with the roots of the incisors, as mentioned above. Although root resorption could be expected to increase until the end of the comprehensive orthodontic treatment, this increase may not be clinically relevant due to the short remaining time of treatment. However, this should be further evaluated in future studies. Nevertheless, the acquisition of a control CBCT after treatment should be well justified [15].

This is the first study using this method to evaluate the root changes after canine traction including patients with complex canine impactions. However, more researches with follow-up designs should be performed. Another important consideration is that the majority of the patients presented alveolar bone around the roots of incisors. This was observed in the CBCT scans after orthodontic traction. This condition was favorable and generated a good prognosis.

Despite the cases presented root resorption before treatment, this was not a contraindication for canine traction. It could be argued that with the initial resorption condition that maxillary incisor showed, they should not be including in the treatment. However, they presented good alveolar bone condition and since the majority of the patients were young, keeping the incisors in mouth was considered important to preserve alveolar bone ridge in the anterior region. Nevertheless, stability of these maxillary incisors should be further evaluated with long-term follow-up records.

## **Conclusion**

For this case series, the color-coded surface distance maps obtained by 3-dimensional superimpositions showed that the amount of root resorption of maxillary incisors after traction of bi-cortically impacted canines was situated mainly in the apex region and it was smaller than 2mm in all radicular surfaces.

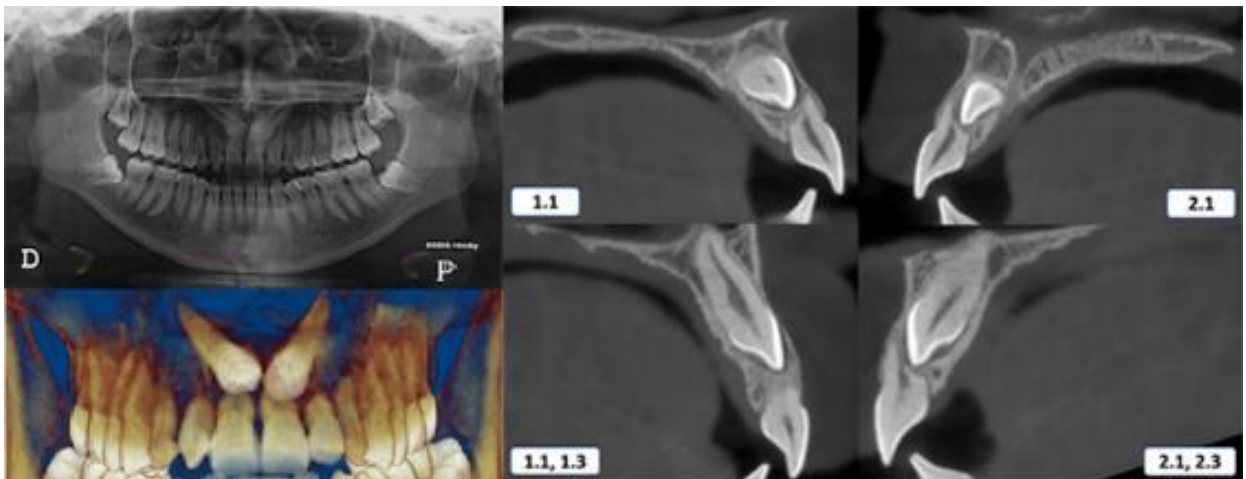
## TABLE

**Table 1**  
**Initial Characteristics of the patients**

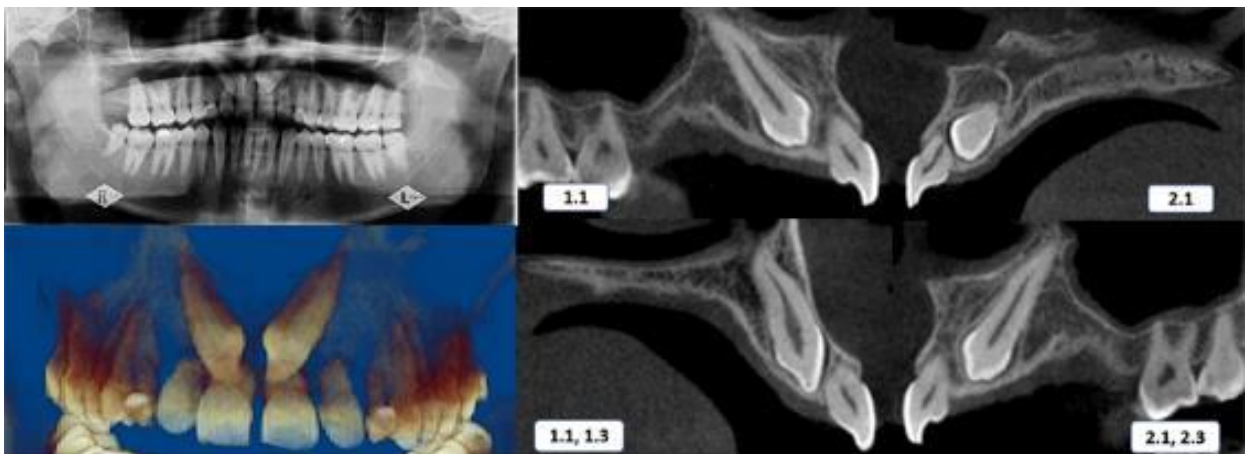
Patients Characteristics				Impacted Canine Characteristics					Skeletal Characteristics																																	
Cases	Gender	Age (years)	Angle Malocclusion	Impacted Side	Impaction sector	Angle $\alpha$	Angle $\beta$	Height of impaction	ANB	APDI	SNA	SNB	PNS-ANS																													
Case 1	Female	19.1	Class I	Right	Sector 5	62.20	40.30	14.30	3.69	83.89	90.81	87.12	54.20																													
				Left	Sector 5	52.10	28.50	12.60						Case 2	Male	36.4	Class I	Right	Sector 4	44.80	48.30	9.30	1.88	93.63	91.15	89.27	56.12	Left	Sector 5	46.90	40.50	10.40	Case 3	Female	13.3	Class I	Right	Sector 3	48.90	53.40	10.90	3.84
Case 2	Male	36.4	Class I	Right	Sector 4	44.80	48.30	9.30	1.88	93.63	91.15	89.27	56.12																													
				Left	Sector 5	46.90	40.50	10.40						Case 3	Female	13.3	Class I	Right	Sector 3	48.90	53.40	10.90	3.84	76.27	79.08	75.24	41.68	Left	Sector 2	22.00	41.20	9.00										
Case 3	Female	13.3	Class I	Right	Sector 3	48.90	53.40	10.90	3.84	76.27	79.08	75.24	41.68																													
				Left	Sector 2	22.00	41.20	9.00																																		



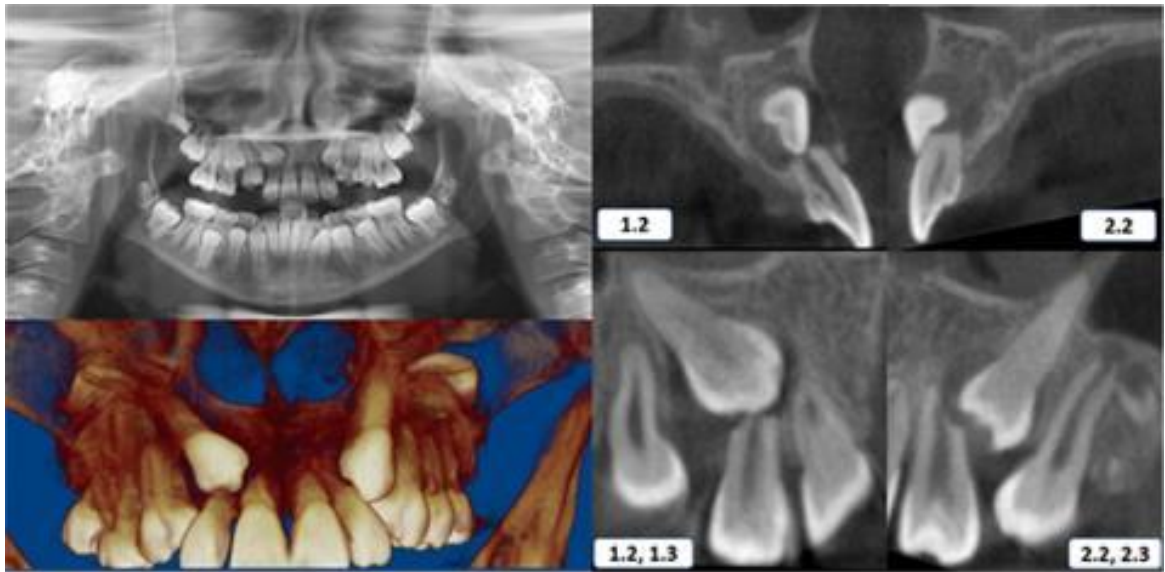
## FIGURES



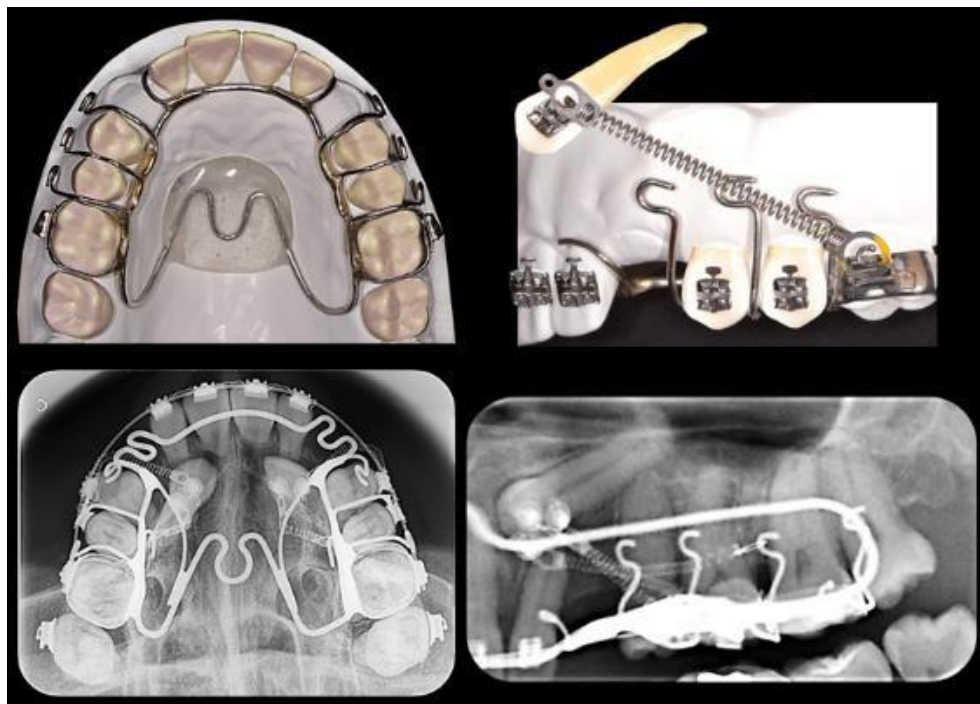
**Fig. 1.** Initial panoramic radiography and CBCT scans - Case 1. 1.1, maxillary right central incisor. 1.3, maxillary right canine. 2.1, maxillary left central incisor. 2.3, maxillary left canine.



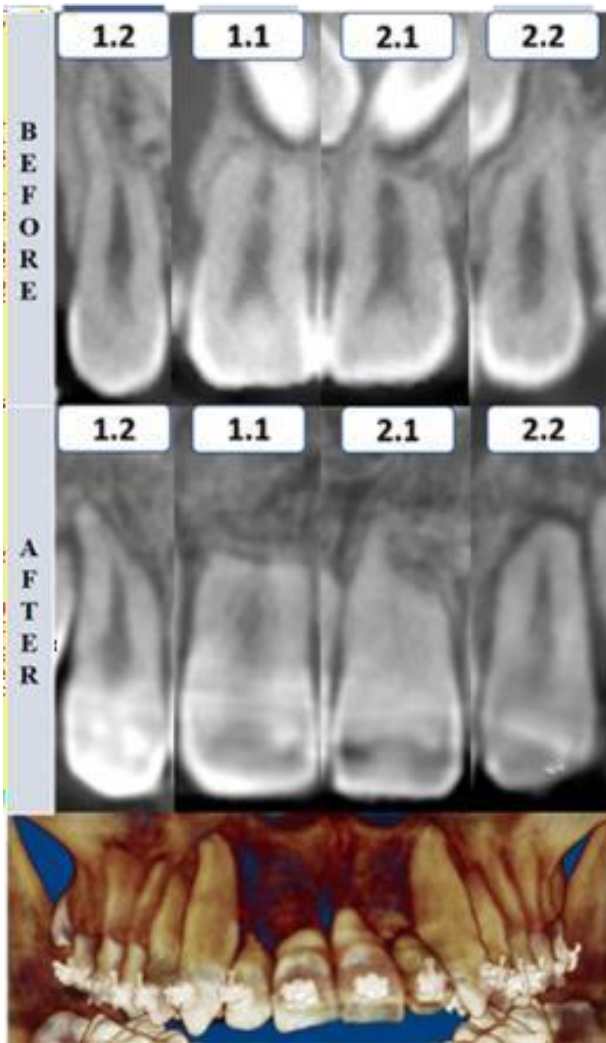
**Fig. 2.** Initial panoramic radiography and CBCT scans - Case 2. 1.1, maxillary right central incisor. 1.3, maxillary right canine. 2.1, maxillary left central incisor. 2.3, maxillary left canine.



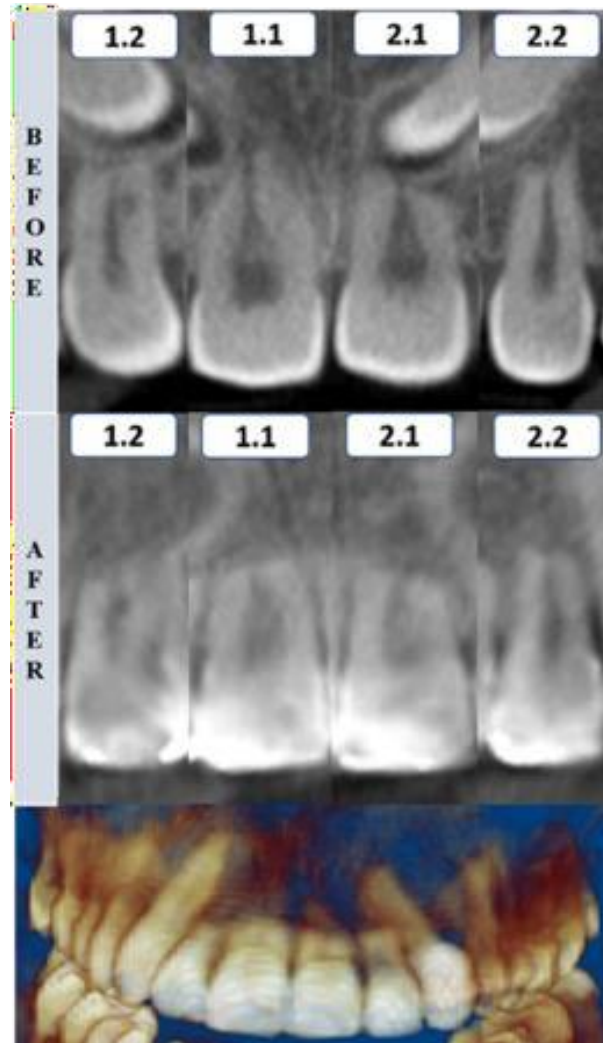
**Fig. 3.** Initial panoramic radiography and CBCT scans – Case 3. 1.1, maxillary right central incisor. 1.3, maxillary right canine. 2.1, maxillary left central incisor. 2.3, maxillary left canine.



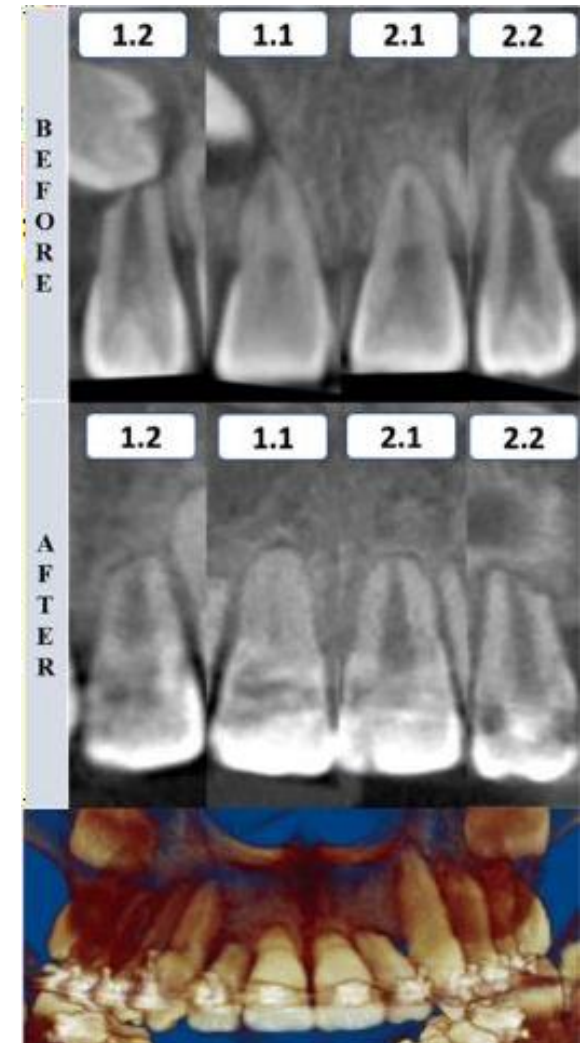
**Fig. 4.** Graphic design and radiographic images of canine traction method.



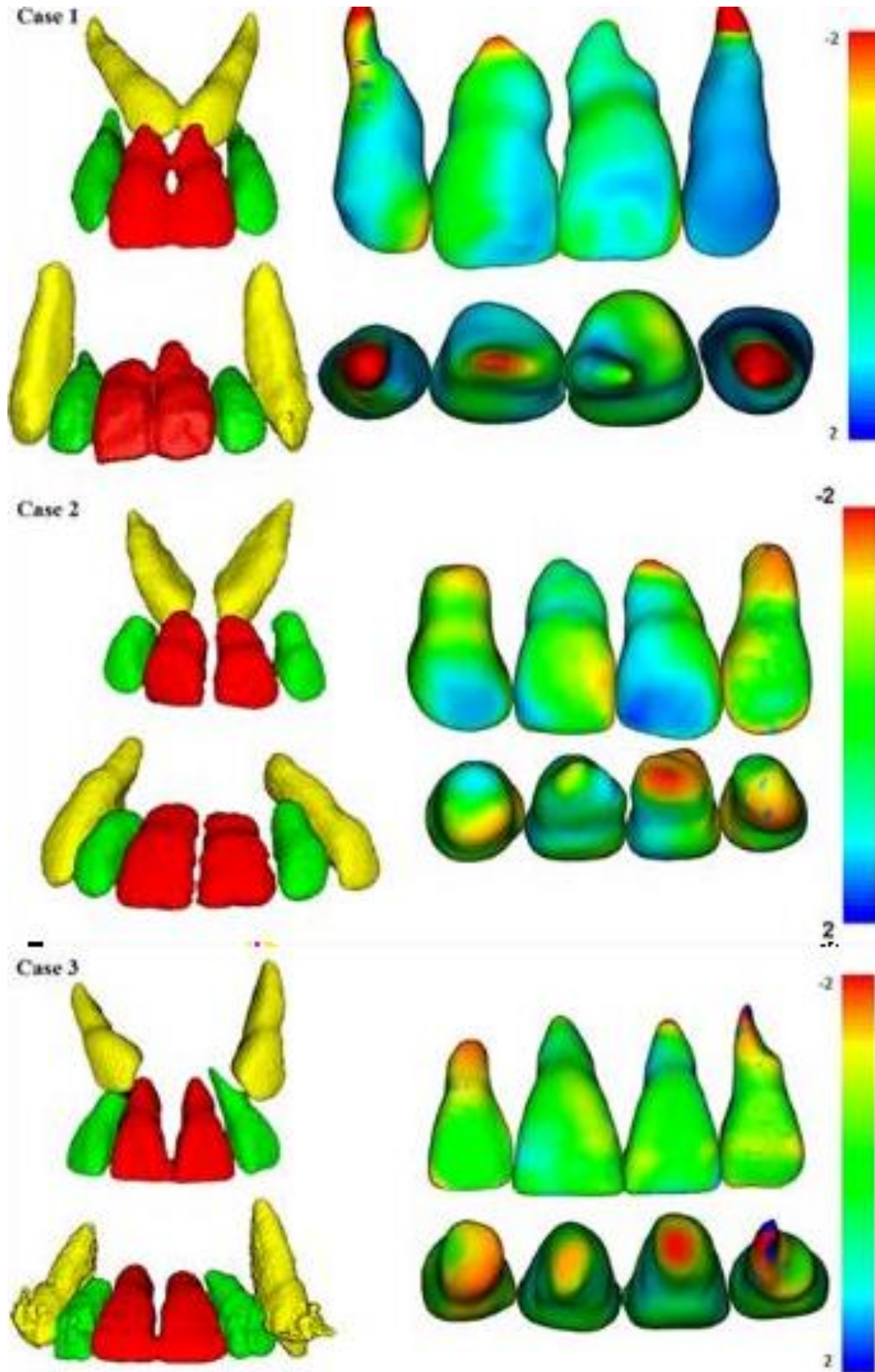
**Fig. 5.** Rendering tomographic after canine traction and CBCT scan to compare the coronal section of upper incisors before and after traction of impacted canine. Case 1.



**Fig. 6.** Rendering tomographic after canine traction and CBCT scan to compare the coronal section of upper incisors before and after traction of impacted canine. Case 2.



**Fig. 7.** Rendering tomographic after canine traction and CBCT scan to compare the coronal section of upper incisors before and after traction of impacted canine. Case 3.



**Fig. 8.** 3D Superimposition of maxillary incisors: Upper figure - Case 1 (before and after traction), middle figure - Case 2 (before and after traction) and lower figure - Case 3 (before and after traction).

## REFERENCES

1. Mittal M, Murray A, Sandler J. Impacted maxillary canines--a perennial problem. *Dent Update* 2012;39:487-488, 491-482, 495-487.
2. Bedoya MM, Park JH. A review of the diagnosis and management of impacted maxillary canines. *J Am Dent Assoc* 2009;140:1485-1493.
3. Park JH, Srisurapol T, Tai K. Impacted maxillary canines: diagnosis and management. *Dent Today* 2012;31:62, 64-66; quiz 68-69.
4. Richardson G, Russell KA. A review of impacted permanent maxillary cuspids--diagnosis and prevention. *J Can Dent Assoc* 2000;66:497-501.
5. Walker L, Enciso R, Mah J. Three-dimensional localization of maxillary canines with cone-beam computed tomography. *Am J Orthod Dentofacial Orthop* 2005;128:418-423.
6. Kumar S, Mehrotra P, Bhagchandani J, Singh A, Garg A, Kumar S et al. Localization of impacted canines. *J Clin Diagn Res* 2015;9:ZE11-14.
7. Cuminetti F, Boutin F, Frapier L. Predictive factors for resorption of teeth adjacent to impacted maxillary canines. *Int Orthod* 2017;15:54-68.
8. Chaushu S, Kaczor-Urbanowicz K, Zadurska M, Becker A. Predisposing factors for severe incisor root resorption associated with impacted maxillary canines. *Am J Orthod Dentofacial Orthop* 2015;147:52-60.
9. Lai CS, Bornstein MM, Mock L, Heuberger BM, Dietrich T, Katsaros C. Impacted maxillary canines and root resorptions of neighbouring teeth: a radiographic analysis using cone-beam computed tomography. *Eur J Orthod* 2013;35:529-538.
10. Ericson S, Kurol J. Early treatment of palatally erupting maxillary canines by extraction of the primary canines. *Eur J Orthod* 1988;10:283-295.
11. Ericson S, Kurol PJ. Resorption of incisors after ectopic eruption of maxillary canines: a CT study. *Angle Orthod* 2000;70:415-423.
12. Chang NY, Park JH, Lee MY, Cho JW, Cho JH, An KY et al. Orthodontic Treatment of Maxillary Incisors with Severe Root Resorption Caused by Bilateral Canine Impaction in a Class II Division 1 Patient. *J Clin Pediatr Dent* 2016;40:161-168.
13. Arriola-Guillén LE, Ruíz-Mora GA, Rodríguez-Cárdenas YA, Aliaga-Del Castillo A, Dias-Da Silveira HL. Root resorption of maxillary incisors after traction of unilateral vs bilateral impacted canine with a reinforced anchorage. *Am J Orthod Dentofacial Orthop* 2018;154:645-56.
14. Heravi F, Shafae H, Forouzanfar A, Zarch SH, Merati M. The effect of canine disimpaction performed with temporary anchorage devices (TADs) before comprehensive orthodontic treatment to avoid root resorption of adjacent teeth. *Dental Press J Orthod* 2016;21:65-72.
15. American Academy of O, Maxillofacial R. Clinical recommendations regarding use of cone beam computed tomography in orthodontics. [corrected]. Position statement by the American Academy of Oral and Maxillofacial Radiology. *Oral Surg Oral Med Oral Pathol Oral Radiol* 2013;116:238-257.
16. Cevidanes LH, Bailey LJ, Tucker GR, Jr., Styner MA, Mol A, Phillips CL et al. Superimposition of 3D cone-beam CT models of orthognathic surgery patients. *Dentomaxillofac Radiol* 2005;34:369-375.

17. Cevidanes LH, Styner MA, Proffit WR. Image analysis and superimposition of 3-dimensional cone-beam computed tomography models. *Am J Orthod Dentofacial Orthop* 2006;129:611-618.
18. Cevidanes LH, Heymann G, Cornelis MA, DeClerck HJ, Tulloch JF. Superimposition of 3-dimensional cone-beam computed tomography models of growing patients. *Am J Orthod Dentofacial Orthop* 2009;136:94-99.
19. Schilling J, Gomes LC, Benavides E, Nguyen T, Paniagua B, Styner M et al. Regional 3D superimposition to assess temporomandibular joint condylar morphology. *Dentomaxillofac Radiol* 2014;43:20130273.
20. Ruellas AC, Yatabe MS, Souki BQ, Benavides E, Nguyen T, Luiz RR et al. 3D Mandibular Superimposition: Comparison of Regions of Reference for Voxel-Based Registration. *PLoS One* 2016;11:e0157625.
21. Ruellas AC, Huanca Ghislazoni LT, Gomes MR, Danesi C, Lione R, Nguyen T et al. Comparison and reproducibility of 2 regions of reference for maxillary regional registration with cone-beam computed tomography. *Am J Orthod Dentofacial Orthop* 2016;149:533-542.
22. Yatabe M, Garib DG, Facó RAS, de Clerck H, Janson G, Nguyen T et al. Bone-anchored maxillary protraction therapy in patients with unilateral complete cleft lip and palate: 3-dimensional assessment of maxillary effects. *Am J Orthod Dentofacial Orthop* 2017;152:327-335.
23. Garib D, Yatabe M, Facó RAS, Gregório L, Cevidanes L, de Clerck H. Bone-anchored maxillary protraction in a patient with complete cleft lip and palate: A case report. *Am J Orthod Dentofacial Orthop* 2018;153:290-297.
24. Heymann GC, Cevidanes L, Cornelis M, De Clerck HJ, Tulloch JF. Three-dimensional analysis of maxillary protraction with intermaxillary elastics to miniplates. *Am J Orthod Dentofacial Orthop* 2010;137:274-284.
25. Swennen GR, Mollemans W, De Clercq C, Abeloos J, Lamoral P, Lippens F et al. A cone-beam computed tomography triple scan procedure to obtain a three-dimensional augmented virtual skull model appropriate for orthognathic surgery planning. *J Craniofac Surg* 2009;20:297-307.
26. Heon J. Three-dimensional superimposition. *PCSO Bull* 2010;82:23-26.
27. Cevidanes LH, Gomes LR, Jung BT, Gomes MR, Ruellas AC, Goncalves JR et al. 3D superimposition and understanding temporomandibular joint arthritis. *Orthod Craniofac Res* 2015;18 Suppl 1:18-28.
28. Nguyen T, Cevidanes L, Cornelis MA, Heymann G, de Paula LK, De Clerck H. Three-dimensional assessment of maxillary changes associated with bone anchored maxillary protraction. *Am J Orthod Dentofacial Orthop* 2011;140:790-798.
29. Cevidanes LH, Motta A, Proffit WR, Ackerman JL, Styner M. Cranial base superimposition for 3-dimensional evaluation of soft-tissue changes. *Am J Orthod Dentofacial Orthop* 2010;137:S120-129.

## Considerações Finais

---

O tratamento ortodôntico que inclui a desimpactação dos caninos superiores por si só representa um desafio para os ortodontistas [29-30], portanto, o conhecimento de que, independentemente do tipo de impactação do canino superior (unilateral ou bilateral) ou da complexidade de sua tração (casos de baixo ou alta complexidade), o risco de reabsorção radicular nos incisivos superiores é semelhante entre eles. Assim, essa informação pode ser útil e encorajadora para os especialistas, pois poderão realizar seus tratamentos sem a preocupação de aumentar o risco de reabsorção radicular inerente aos tratamentos ortodônticos [31-37].

No caso da impactação bicortical dos caninos superiores, casos muito complexos para o tratamento, também foi demonstrado que a reabsorção radicular dos casos avaliados está localizada principalmente na ponta da raiz dos incisivos e não excede a quantidade considerada clinicamente relevante. No entanto, essa linha de pesquisa ainda precisa ser ampliada e mais pesquisas devem ser feitas para corroborar e aprofundar os resultados encontrados na pesquisa.

Finalmente, este estudo conclui que a reabsorção radicular de incisivos superiores após tração de canino superiores impactados com molas helicoidais foi semelhante, independente da condição uni ou bilateral, complexidade da localização e, no caso de impactação bicortical esteve localizado predominantemente no terço radicular apical.

## Referências

---

1. Lempesi E, Pandis N, Fleming PS, Mavragani M. A comparison of apical root resorption after orthodontic treatment with surgical exposure and traction of maxillary impacted canines versus that without impactions. *Eur J Orthod* 2014;36:690-697.
2. Ericson S, Kurol J. Early treatment of palatally erupting maxillary canines by extraction of the primary canines. *Eur J Orthod* 1988;10:283-295.
3. Kumar S, Mehrotra P, Bhagchandani J, Singh A, Garg A, Kumar S et al. Localization of impacted canines. *J Clin Diagn Res* 2015;9:ZE11-14.
4. Yan B, Sun Z, Fields H, Wang L. [Maxillary canine impaction increases root resorption risk of adjacent teeth: A problem of physical proximity]. *Orthod Fr* 2015;86:169-179.
5. Chaushu S, Kaczor-Urbanowicz K, Zadurska M, Becker A. Predisposing factors for severe incisor root resorption associated with impacted maxillary canines. *Am J Orthod Dentofacial Orthop* 2015;147:52-60.
6. Ericson S, Kurol J. Radiographic examination of ectopically erupting maxillary canines. *Am J Orthod Dentofacial Orthop* 1987;91:483-492.
7. Mercuri E, Cassetta M, Cavallini C, Vicari D, Leonardi R, Barbato E. Dental anomalies and clinical features in patients with maxillary canine impaction. *Angle Orthod* 2013;83:22-28.
8. Jacoby H. The etiology of maxillary canine impactions. *Am J Orthod* 1983;84:125-132.
9. Hartsfield JK, Jr., Everett ET, Al-Qawasmi RA. Genetic Factors in External Apical Root Resorption and Orthodontic Treatment. *Crit Rev Oral Biol Med* 2004;15:115-122.
10. Peck S, Peck L, Kataja M. The palatally displaced canine as a dental anomaly of genetic origin. *Angle Orthod* 1994;64:249-256.
11. Pirinen S, Arte S, Apajalahti S. Palatal displacement of canine is genetic and related to congenital absence of teeth. *J Dent Res* 1996;75:1742-1746.
12. Thilander B, Jakobsson SO. Local factors in impaction of maxillary canines. *Acta Odontol Scand* 1968;26:145-168.
13. Kanavakis G, Curran KM, Wiseman KC, Barone NP, Finkelman MD, Srinivasan S et al. Evaluation of crown-root angulation of lateral incisors adjacent to palatally impacted canines. *Prog Orthod* 2015;16:4.
14. Becker A, Sharabi S, Chaushu S. Maxillary tooth size variation in dentitions with palatal canine displacement. *Eur J Orthod* 2002;24:313-318.



15. Sacerdoti R, Baccetti T. Dentoskeletal features associated with unilateral or bilateral palatal displacement of maxillary canines. *Angle Orthod* 2004;74:725-732.
16. Anic-Milosevic S, Varga S, Mestrovic S, Lapter-Varga M, Slaj M. Dental and occlusal features in patients with palatally displaced maxillary canines. *Eur J Orthod* 2009;31:367-373.
17. Liuk IW, Olive RJ, Griffin M, Monsour P. Maxillary lateral incisor morphology and palatally displaced canines: a case-controlled cone-beam volumetric tomography study. *Am J Orthod Dentofacial Orthop* 2013;143:522-526.
18. Stellzig A, Basdra EK, Komposch G. [The etiology of canine tooth impaction--a space analysis]. *Fortschr Kieferorthop* 1994;55:97-103.
19. Jacobs SG. The impacted maxillary canine. Further observations on aetiology, radiographic localization, prevention/interception of impaction, and when to suspect impaction. *Aust Dent J* 1996;41:310-316.
20. Yadav S, Chen J, Upadhyay M, Jiang F, Roberts WE. Comparison of the force systems of 3 appliances on palatally impacted canines. *Am J Orthod Dentofacial Orthop* 2011;139:206-213.
21. Oppenhuizen G. An extrusion spring for palatally impacted cuspids. *J Clin Orthod* 2003;37:434-436.
22. Jacoby H. The "ballista spring" system for impacted teeth. *Am J Orthod* 1979;75:143-151.
23. Bowman SJ, Carano A. The Kilroy Spring for impacted teeth. *J Clin Orthod* 2003;37:683-688.
24. Thebault B, Dutertre E. Disimpaction of maxillary canines using temporary bone anchorage and cantilever springs. *Int Orthod* 2015;13:61-80.
25. Chang NY, Park JH, Lee MY, Cho JW, Cho JH, An KY et al. Orthodontic Treatment of Maxillary Incisors with Severe Root Resorption Caused by Bilateral Canine Impaction in a Class II Division 1 Patient. *J Clin Pediatr Dent* 2016;40:161-168.
26. Heravi F, Shafae H, Forouzanfar A, Zarch SH, Merati M. The effect of canine disimpaction performed with temporary anchorage devices (TADs) before comprehensive orthodontic treatment to avoid root resorption of adjacent teeth. *Dental Press J Orthod* 2016;21:65-72.
27. Stewart JA, Heo G, Glover KE, Williamson PC, Lam EW, Major PW. Factors that relate to treatment duration for patients with palatally impacted maxillary canines. *Am J Orthod Dentofacial Orthop* 2001;119:216-225.

28. Weltman B, Vig KW, Fields HW, Shanker S, Kaizar EE. Root resorption associated with orthodontic tooth movement: a systematic review. *Am J Orthod Dentofacial Orthop* 2010;137:462-476; discussion 412A.
29. Schmidt AD, Kokich VG. Periodontal response to early uncovering, autonomous eruption, and orthodontic alignment of palatally impacted maxillary canines. *Am J Orthod Dentofacial Orthop* 2007;131:449-455.
30. Brusveen EM, Brudvik P, Boe OE, Mavragani M. Apical root resorption of incisors after orthodontic treatment of impacted maxillary canines: a radiographic study. *Am J Orthod Dentofacial Orthop* 2012;141:427-435.
31. Brezniak N, Wasserstein A. Orthodontically induced inflammatory root resorption. Part I: The basic science aspects. *Angle Orthod* 2002;72:175-179.
32. Killiany DM. Root resorption caused by orthodontic treatment: an evidence-based review of literature. *Semin Orthod* 1999;5:128-133.
33. Huang Y, Wang XX, Zhang J, Liu C. Root shortening in patients treated with two-step and en masse space closure procedures with sliding mechanics. *Angle Orthod* 2010;80:492-497.
34. Lund H, Grondahl K, Hansen K, Grondahl HG. Apical root resorption during orthodontic treatment. A prospective study using cone beam CT. *Angle Orthod* 2012;82:480-487.
35. Linge BO, Linge L. Apical root resorption in upper anterior teeth. *Eur J Orthod* 1983;5:173-183.
36. Woloshyn H, Artun J, Kennedy DB, Joondeph DR. Pulpal and periodontal reactions to orthodontic alignment of palatally impacted canines. *Angle Orthod* 1994;64:257-264.
37. Linge L, Linge BO. Patient characteristics and treatment variables associated with apical root resorption during orthodontic treatment. *Am J Orthod Dentofacial Orthop* 1991;99:35-43.

## Anexo 1

## Aprovação no Comissão de Pesquisa – FO-UFRGS

https://www1.ufrgs.br/PortalServidor/Pesquisa/Pesquisador/forms/form\_index.php

<b>Projeto Nº:</b>	33610	<b>Título:</b>	RETROSPECTIVE LONGITUDINAL STUDY ABOUT ROOT RESORPTION OF MAXILLARY INCISORS AFTER IMPACTED CANINES TRACTION WITH COIL SPRINGS
<b>Área de conhecimento:</b>	Radiologia Odontológica	<b>Início:</b>	06/09/2017
<b>Situação:</b>	Projeto em Andamento	<b>Previsão de conclusão:</b>	06/09/2019
<b>Origem:</b>	Faculdade de Odontologia Programa de Pós-Graduação em Odontologia	<b>Projeto da linha de pesquisa:</b> DIAGNÓSTICO DE AFECÇÕES BUCO-FACIAIS	
<b>Local de Realização:</b>	não informado		
<b>Não apresenta relação com Patrimônio Genético ou Conhecimento Tradicional Associado.</b>			
<b>Objetivo:</b>	<p>Introduction: Canine impaction represents a clinical challenge for orthodontists, its treatment should always seek to maintain this tooth and thus allow the development of canine eminence, however, root resorption as a side effect of orthodontic treatment may be increased in cases of impacted canines. The aims of this project will be 1. To compare the root resorption of maxillary incisors after traction with coil springs of unilateral versus bilateral impacted canines. 2. To determine the influence of the complexity of the orthodontic treatment of impacted maxillary canines on the root</p>		
<b>Palavras Chave:</b>	ROOT RESORPTIONS; IMPACTED TOOTH; CBCT		
<b>Equipe UFRGS:</b>	<p><b>Nome:</b> HERALDO LUIS DIAS DA SILVEIRA  <b>Coordenador</b> - Início: 06/09/2017 Previsão de término: 06/09/2019  <b>Nome:</b> Gustavo Armando Ruiz Mora  <b>Outra:</b> Aluno de Doutorado - Início: 06/09/2017 Previsão de término: 06/09/2019  <b>Nome:</b> Luis Ernesto Arriola Guillén  <b>Outra:</b> Aluno de Doutorado - Início: 06/09/2017 Previsão de término: 06/09/2019  <b>Nome:</b> MARIANA BOESSIO VIZZOTTO  <b>Pesquisador</b> - Início: 06/09/2017 Previsão de término: 06/09/2019  <b>Nome:</b> NADIA ASSEIN ARUS  <b>Pesquisador</b> - Início: 06/09/2017 Previsão de término: 06/09/2019  <b>Nome:</b> Yaili Augusto Rodríguez Cárdenas  <b>Outra:</b> Aluno de Doutorado - Início: 06/09/2017 Previsão de término: 06/09/2019</p>		
<b>Avaliações:</b>	Comissão de Pesquisa de Odontologia - <b>Aprovado</b> em 20/09/2017 <a href="#">Clique aqui para visualizar o parecer</a>		

## Anexo 2

## Aprovação na Comissão de Ética e Pesquisa – FO-UCSUR



CARTA N° 057-EE-FCS-U.CIENTIFICA/2017

Miraflores, 10 de mayo del 2017

Mg. Esp.  
Luis Arriola Guillén  
Presente.-

ASUNTO: Constancia de inscripción y aprobación ética de trabajos de investigación.

De mi consideración:

Por medio del presente documento lo saludo cordialmente y en atención al asunto de la referencia la comisión de ética e investigación para trabajos de investigación de la Escuela de Estomatología de la Universidad Científica del Sur, Lima-Perú, señala que el trabajo de investigación titulado: **"Retrospective Longitudinal study about root resorption of maxillary incisors after impacted canines traction with coil springs"**, ha sido inscrito en nuestra Escuela y ha sido aprobado en los aspectos éticos que involucra la aplicación del mismo, con el número de aprobación **00006**.

Agradeciendo la atención brindada a la presente, quedo de usted.

Atentamente,



ESCUELA DE ESTOMATOLOGIA  
COORDINACION DE INVESTIGACION  
**Dr. Fernando Ortiz Culea**  
Coordinador de Investigación  
Escuela de Estomatología  
Universidad Científica del Sur

## Anexo 3

Termo de compromiso para uso de datos


**COMMITMENT TERM FOR DATA USE**

**Title of research project**

**Retrospective longitudinal study about root resorption of maxillary incisors after impacted canines traction with coil springs.**

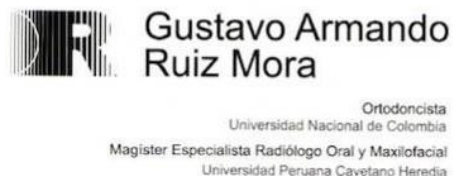The researchers of the present project commit themselves to preserve the privacy of patients whose data will be collected in medical records and databases of Dr. Gustavo Ruíz's Clinic, (Bogotá, Colombia). They also agree that this information will be used solely and exclusively for the execution of this project. The information may only be disclosed anonymously.

Porto Alegre, July 1, 2015.

Principal Author	Signature
Luis Ernesto Arriola Guillén	

## Anexo 4

## Autorização para o uso de informação tomografica



Porto Alegre, July 19 2007

I, **GUSTAVO ARMANDO RUIZ MORA** with ID. # PE130267, authorize and consent to **LUIS ERNESTO ARRIOLA GUILLÉN**, with ID # 40990364 to use tomographic records of my database related to treatment of maxillary impacted canines.

These files must be kept confidential, and should only be used by the researcher only and exclusively to execute the project namely: "**RETROSPECTIVE LONGITUDINAL STUDY ABOUT ROOT RESORPTION OF MAXILLARY INCISORS AFTER IMPACTED CANINES TRACTION WITH COIL SPRINGS**".

All information may be used strictly of form anonymous.

  
**GUSTAVO ARMANDO RUIZ MORA**

Bogotá: Calle 62 N°7-16 Consultorio 201 B Teléfonos : 249 24 98 - 255 04 23235 65 38 - 235 66 08 Fax: 235 65 98  
Tunja: Medicentro Calle 21 A N° 10 - 57 Consultorio 104 Teléfonos: 742 29 07 - 743 94 37 Fax: 743 06 74  
Celular: 313 453 26 69 E-mail: garruiz@gmail.com