

---

## MONOARTICULAR HISTOPLASMOSIS: CASE REPORT OF GRANULOMATOUS SYNOVITIS

---

*Cecília Bittencourt Severo<sup>1</sup>, Flávio de Mattos Oliveira<sup>1</sup>, Bruno Hochhegger<sup>2</sup>, Candido A. Silva<sup>3</sup>, Maritza Cantarelli<sup>3</sup> and Luiz Carlos Severo<sup>1 e 4</sup>.*

### ABSTRACT

We report a case of sub acute granulomatous synovitis of the knee due to *Histoplasma capsulatum* in a patient with a past history of intra-articular corticosteroid injections for right knee pain. The diagnosis of histoplasmosis was made on microscopical examination of the surgical specimen. Subsequent cultures from the synovial fluid grew *H. capsulatum*. This is an unusual case of focal histoplasmosis. This diagnosis should be considered in endemic areas.

KEY WORDS: Histoplasmosis; *Histoplasma capsulatum*; synovitis; Knee.

### RESUMO

Histoplasmose articular: relato de caso de sinovite granulomatosa

Apresentamos um caso de sinovite granulomatosa subaguda do joelho, causada por *Histoplasma capsulatum*, em um paciente com histórico de injeções de corticoide intra-articulares para dor no joelho direito. O diagnóstico da histoplasmose foi feito por meio de exame da peça cirúrgica em microscópio. O *H. capsulatum* foi também isolado no líquido sinovial. Este é um caso raro de histoplasmose focal que deve ser considerado em áreas endêmicas.

DESCRIPTORIOS: Histoplasmose; *Histoplasma capsulatum*; sinovite; joelho.

- 
- 1 Mycology Laboratory, Hospital Santa Rita, Irmandade Santa Casa de Misericórdia Porto Alegre (ISCOMPA), RS, Brazil.
  - 2 Universidade Federal de Ciências Médicas de Porto Alegre, RS, Brazil.
  - 3 IEP-Hospital Moinhos de Vento, Porto Alegre, RS, Brazil.
  - 4 Department of Internal Medicine, Faculty of Medicine, UFRGS, Porto Alegre, RS, Brazil.

Corresponding author: Dr. Luiz Carlos Severo, Laboratório de Micologia, Hospital Santa Rita, Irmandade Santa Casa de Misericórdia Porto Alegre, Annes Dias, 285, 90020-090. Porto Alegre, RS, Brazil. E-mail: severo@santacasa.tche.br; severo@pesquisador.cnpq.br

Received for publication: 11/4/2013. Reviewed in: 30/8/2013. Accepted: 23/9/2013.

## INTRODUCTION

Fungal infections of the musculoskeletal system are uncommon and a challenging clinical problem, especially in patients without overt immunodeficiency with an isolated focus of disease (1 e 7).

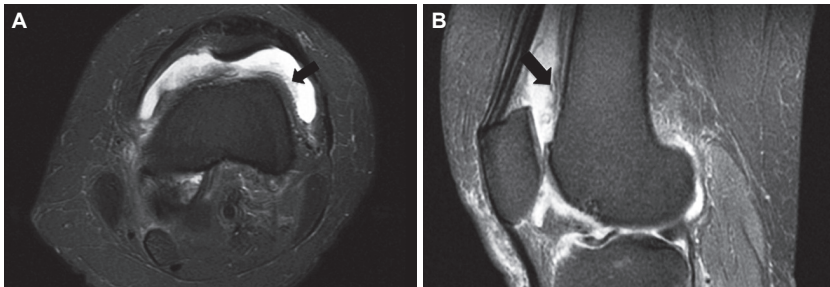
Although *H. capsulatum* var. *dubuoisii* produces osteolytic bone lesions in up to 50% of cases, this disease site due to *Histoplasma capsulatum* var. *capsulatum* (*H. capsulatum*) is rare (2). However, bone marrow involvement frequently occurs in cases of severe disseminated disease, but radiographic evidence of lytic lesions of true osteomyelitis is absent (6). Only rarely is histoplasmosis arthritis observed as a focal manifestation of dissemination. We report here a case in which a monoarticular histoplasmosis was diagnosed by arthroscopy-guided biopsy. Our patient had synovial tissue involvement by *H. capsulatum*, as a single manifestation of histoplasmosis, which is exceedingly rare.

## CASE REPORT

A 65-year-old white woman with a history of meniscal injury nine years ago, presented with pain and swelling of the right knee. Due to her continuous pain at the right knee, the patient underwent three arthroscopies, in August 2009, March 2011 and November 2011. In the meantime, she also received three intra-articular glucocorticoid injections (methylprednisolone - 40 mg), at intervals of 30 days each.

At presentation, her physical examination was unremarkable except for swelling, marked tenderness, warmth, and limited painful motion of her right knee. Testing for human immunodeficiency virus (HIV) was negative.

Roentgenograms of the right knee did not show signs of osteomyelitis. A magnetic resonance image of the right knee revealed soft-tissue edema, a huge joint effusion and well-circumscribed material showing low signal intensity on the T2-weighted fast spin-echo image, which represents synovitis (Fig. 1)



*Figure 1.* Magnetic resonance imaging of the knee in axial (A) and sagittal (B) views showing synovial inflammation (arrows) with intra-articular fluid in T2 weighted sequences.

The joint space was visualized with arthroscopy of the infected knee joint, showing proliferative synovitis and tissue extending into the joint space. A biopsy of synovial tissue was done; hematoxylin-eosin (H&E) staining showed chronic granulomatous synovitis and Gomori methenamine silver (GMS) staining demonstrated the yeast cells of *H. capsulatum* (Fig. 2). *H. capsulatum* was also isolated from synovial fluid and identified by dimorphism. *H. capsulatum* in culture displayed the suggestive conidial forms (micro and plural macroconidia) as well as conversion of mold to yeast phase at 37°C.

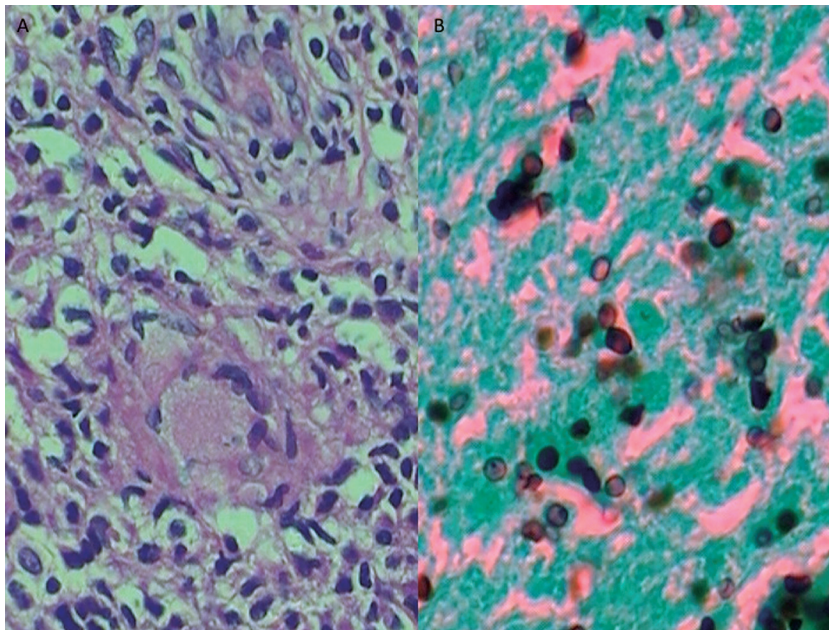


Figure 2. a) Synovial tissue showing chronic granulomatous inflammation (H&E, x400), b) *H. capsulatum* yeast cells (GMS, x1000).

The patient was treated with oral itraconazole 200 mg daily for 18 months. She remains asymptomatic three months after cessation of therapy.

## DISCUSSION

In the normal host, acute infection with *H. capsulatum* results in an influenza-like respiratory illness in up to 5% of those infected, but most infections remain subclinical. Primary pulmonary infections are often accompanied by spread of the organisms beyond the lungs and transient fungemia has been recorded. Histoplasmosis can involve every organ system during the course of dissemination.

In some instances patients have obvious systemic infections with widespread dissemination, while in other instances focal disease in a single organ is the only manifestation of dissemination. This musculoskeletal involvement reflects hematogenous spread of *H. capsulatum*, as in this case of reactivation of a latent infection, here specifically because the patient, on presentation, had no pulmonary symptoms and had normal results of chest roentgenography and computed tomography (CT) (3, 4, 5).

Focal histoplasmosis, seen in both adults and infants, generally lasts for months. Sufferers are likely to have Addison's disease, meningitis, and endocarditis (3). Histoplasmosis presented initially as an isolated arthritis involving the knee joint was first reported by Key and Large, in 1942. Osteoarticular infection can primarily involve tendons, presenting as carpal tunnel syndrome (1) or occurring in a patient with acquired immunodeficiency syndrome (AIDS) (7).

In conclusion, we believe this case demonstrates a rare manifestation of focal histoplasmosis, accounting for the delay in diagnosis. It must be emphasized that other diagnostic procedures, such as culture of specimens obtained with arthrocentesis, should be performed for early diagnosis.

## REFERENCES

1. Cucurull E, Sarwar H, Williams CS, Espinoza LR. Localized tenosynovitis caused by *Histoplasma capsulatum*: case report and review of the literature. *Arthritis Rheum* 53:129-132, 2005.
2. Deepe GS. *Histoplasma capsulatum*. In: Mandell GL; Bennett JE & Dolin, editors. R Mandell, Douglas, and Bennett's. *Principles and practice of Infectious Diseases*. 7th ed. Philadelphia: Churchill Livingstone Elsevier; 2010.
3. Goodwin RA, Shapiro JL, Thurman GH, Thurman SS, Des Prez RM. Disseminated histoplasmosis: clinical and pathologic correlations. *Medicine (Baltimore)* 59: 1-33, 1980.
4. Kauffman CA. Histoplasmosis: a clinical and laboratory update. *Clin Microbiol Rev* 20: 115-132, 2007.
5. Paya CV, Roberts GD, Cockerill III FR. transient fungemia in acute pulmonary histoplasmosis detection by a new blood-culturing technique. *J Infect Dis* 156: 313-15, 1987.
6. Salzman SH, Smith RL, Aranda CP. Histoplasmosis in patients at risk for the acquired immunodeficiency syndrome in a nonendemic setting. *Chest* 93: 916-921, 1988.
7. Weinberg JM, Ali R, Badve S, Pelker RR. Musculoskeletal histoplasmosis. A case report and review of the literature. *J Bone Joint Surg Am* 83: 1718-1722, 2001.