FLÁVIO DE MATTOS OLIVEIRA

AVALIAÇÃO CLÍNICA DA FUNGEMIA DETECTADA PELO SISTEMA DE HEMOCULTIVO POR LISE-CENTRIFUGAÇÃO (Isolator®). TREZE ANOS DE EXPERIÊNCIA,1994-2007.

Tese apresentada ao Programa de Pós-Graduação em Ciências Pneumológicas da Universidade Federal do Rio Grande do Sul, para obtenção do grau de Doutor.

Porto Alegre

2007

FLÁVIO DE MATTOS OLIVEIRA

AVALIAÇÃO CLÍNICA DA FUNGEMIA DETECTADA PELO SISTEMA DE HEMOCULTIVO POR LISE-CENTRIFUGAÇÃO (Isolator®). TREZE ANOS DE EXPERIÊNCIA,1994-2007.

Tese apresentada ao Programa de Pós-Graduação em Ciências Pneumológicas da Universidade Federal do Rio Grande do Sul, para obtenção do grau de Doutor.

Orientador:
Profº. Dr. LUIZ CARLOS SEVERO

Porto Alegre

2007

FICHA CATALOGRÁFICA

Oliveira, Flávio de Mattos
AVALIAÇAO CLINICA DA FUNGEMIA DETECTADA PELO SISTEMA DE HEMOCÚLTIVO POR LISE-CENTRIFUGAÇAO (Isolator®). TREZE ANOS DE EXPERIENCIA,1994-2007 / Flávio de Mattos Oliveira. --Porto Alegre, 2007.
xv, 50f.

Tese (doutorado) – Universidade Federal do Rio Grande do Sul. Faculdade de Medicina. Programa de Pós-graduação em Ciências Pneumológicas.

Título em inglês: Clinical evaluation of fungemia detected by the hemocultivation system by lyse-centrifugation (Isolator®). Thirteen years of experience, 1994 – 2007.

1. Fungemia. 2. Lise-centrifugação. 3. *Histoplasma capsulatum.* 4. *Cryptococcus* spp. 5. *Rhodotorula* spp. 6. *Trichosporon* spp. 7. *Saccharomyces cerevisiae*.

UNIVERSIDADE FEDERAL DO RIO GRANDE DO SUL

PÓS-GRADUAÇÃO EM CIÊNCIAS PNEUMOLÓGICAS

Coordenador do Curso de Pós-Graduação: Prof. Dr. José da Silva Moreira

Saber organizar a vida com bom senso

Não confusamente, no tumulto dos eventos,
mas com percepção e bom senso.
A vida sem descanso é dolorosa,
assim como um longo dia de viagem sem pouso.
O que torna a vida agradável é uma variedade de aprendizado.
Para um vida bela, gaste a primeira jornada conversando com os mortos:
nascemos para conhecer e conhecer a nós mesmos,
e os livros nos transformam fielmente em pessoas.
Passe a segunda jornada com os vivos:
contemple tudo o que há de bom no mundo.
Nem todas as coisas podem ser encontradas numa região.
Ao discutir o dote, o Pai universal às vezes deu riqueza à filha mais feia.
A terceira jornada pertence inteiramente a você:
filosofar é o prazer mais elevado de todos.

Baltasar Gracián

A arte da sabedoria mundana

Agradecimentos

Ao amigo, Luiz Carlos Severo,
por ter me dado o privilégio de ser meu mestre.

À minha mãe, Zaira, pelo incentivo e amor.

Ao bolsita Sérgio Sônego Fernandes pelo, auxílio
na revisão dos prontuários.

À Cláudia Bica e Melissa Orzechowski Xavier,
pelas sugestões.

Às amigas do Laboratório de Micologia
Santa Casa-Complexo Hospitalar, Porto Alegre:
Ilva Lúcia Carnetti, Inajara Silveira dos Santos,
Luciana Silva Guazzeli e Cecília Bittencourt Severo

Sumário

Resumo

Foram incluídos no estudo 525 casos de fungemia causadas por *Candida* spp, *Cryptocossus* spp, *Trichosporon* spp, *Rhodotorula* spp, *Histoplasma capsulatum*, *Saccharomyces cerevisiae* e *Pseudozyma aphidis*, que constam nos arquivos do Laboratório de Micologia, Santa Casa-Complexo Hospitalar, Porto Alegre (RS) num período de 13 anos (1994-2007). Aspectos demográficos, doenças de base e fatores associadas aos episódios de fungemia foram estudados. Assim como, os agentes etiológicos e a mortalidade global entre os pacientes com fungemia.

Os 525 casos foram classificados da seguinte maneira: candidemia (413/78,6%), subdivididos em: *Candida albicans* (151/36,5%), *C. parapsilosis* (91/22%), *C. tropicalis* (65/15,7%), *C. glabrata* (27/6,5%), *C. pelliculosa* (18/4,3%), *C. guilliermondii* (18/4,3%), *C. humicola* (7/1,7%), *C. krusei* (7/1,7%), *C. famata* (5/1,2%), *C. lusitaniae* (4/0,9%), *C. sake* (4/0,9%), *C. lipolytica* (3/0,7%), *C. globosa* (3/0,7%), *C. intermedia* (2/0,5%), *C. kefyr* (1/0,24%), *C. colliculosa* (1/0,24%) e *Candida* sp (8/1,9%); criptococococemia (77/14,6%), subdivididos em: *Cryptococcus neoformans* (72/93,5%), *C. gattii* (3/3,9%), *C. laurentii* (1/1,3%), *Cryptococcus* sp (1/1,3%); *Histoplasma capsulatum* (21/4%);*Trichosporon* spp (9/1,5%) subdivididos em: *T. asahii* (8/89%), *T. mucoides* (1/11%); *Rhodotorula* spp (5/0,9%) subdivididos, *Rhodotorula* sp (4/80%), *R. mucilaginosa* (1/20%); *Saccharomyces cerevisiae* (1/0,2%); *Pseudozyma aphidis* (1/0,2%)

O sexo masculino foi o mais prevalente (288/55%), porém sem significância estatística, a idade variou de 12 dias à 97 anos, com uma mediana de 39,64 anos. A mortalidade nestes pacientes variou entre 22% e 52%. As doenças de base mais frequente foram câncer e Aids. Febre foi o sinal mais frequente.

Neste contexto, a fungemia deve ser incluída no diagnóstico diferencial destes pacientes com febre de origem desconhecida e prolongada. Utilizando-se de técnicas laboratoriais específicas para o diagnóstico etiológico.

Abstract

We reviewd 525 cases of fungemia caused by *Candida* spp, *Cryptocossus* spp, *Trichosporon* spp, *Rhodotorula* spp, *Histoplasma capsulatum*, *Saccharomyces cerevisiae* and *Pseudozyma aphidis*. They have all been part of the files of the Mycology Laboratory at Santa Casa Hospital Complex in Porto Alegre (RS), during a thirteen-year period (1994 - 2007). Demographic aspects, underlying diseases and factors associated with the fungemia episodes were studied, as well as the etiologic agents and the global mortality among the patients having fungemia.

The 525 cases included in the study were classified according to the following: candidemia (413/78,6%), subdivided in: *Candida albicans* (151/36,5%), *C. parapsilosis* (91/22%), *C. tropicalis* (65/15,7%), *C glabrata* (27/6,5%), *C. pelliculosa* (18/4,3%), *C.guilliermondii* (18/4,3%), *C. humicola* (7/1,7%), *C. krusei* (7/1,7%), *C. famata* (5/1,2%), *C. lusitaniae* (4/0,9%), *C. sake* (4/0,9%), *C. lipolytica* (3/0,7%), *C. globosa* (3/0,7%), *C. intermedia* (2/0,5%), *C. kefyr* (1/0,24%), *C. colliculosa* (1/0,24%) e *Candida* sp (8/1,9%); criptococcemia (77/14,6%), subdivided in: *Cryptococcus neoformans* (72/93,5%), *C. gattii* (3/3,9%), *C. laurentii* (1/1,3%), *Cryptococcus* sp (1/1,3%); *Histoplasma capsulatum* (21/4%);*Trichosporon* spp (9/1,5%) subdivided in: *T. asahii* (8/89%), *T. mucoides* (1/11%); *Rhodotorula* spp (5/0,9%) subdivided, *Rhodotorula* sp (4/80%), *R. mucilaginosa* (1/20%); *Saccharomyces cerevisiae* (1/0,2%); *Pseudozyma aphidis* (1/0,2%)

The male gender was the most prevalent (288/55%), although no significance difference was observed. The age ranged from 12 days to 97 years old, with an average of 39,64 years. The mortality among these patients ranged between 22% and 52%. The most frequent underlying diseases were cancer and Aids. Fever was the most frequent sign.

Within this context, fungemia must be included in the differential diagnosis of these patients presenting long-term fever with unknown cause. Making use of specific laboratorial techniques for the etiologic diagnosis.

Lista de figuras

Artigo 5.3

Artigo – Anexo III

Lista de tabelas

Artigo 5.1

Artigo 5.2

Artigo – Anexo III

Listas de abreviaturas e siglas

Aids - Síndrome da imunodeficiência adiquirda

BHI - Infusão de cérebro-coração

CGB - Canavanina-glicina-azul de bromotimol

°C - graus Celsius

°GL - graus Gay-Lussac

HIV - vírus da imunodeficiência humana

h - horas

McF - MacFarland

MGG - May-Grunwald Giemsa

min - minutos

ml - mililitros

μl - microlitro

NPT- Nutrição parenteral total

PVPI - Polivinilpirroldina-iodo

R.P.M. - Rotações por minuto

SAB - ágar Sabouraud

1 INTRODUÇÃO

Infecções fúngicas sistêmicas são vistas com frequência crescente nos pacientes imunocomprometidos. Os principais fatores de risco incluem a administração de antibióticos de amplo espectro, corticóides, drogas citotóxicas, cateter intravascular, nutrição parenteral total (NPT), cirurgia de grande porte, transplantes de medula óssea e de órgãos sólidos, infecção pelo vírus da imunodeficiência humana (HIV) (Bille, 1984; Creger, 1998; Rosas , 2003).

O isolamento de fungo do sangue é um marcador pouco sensível de doença fúngica disseminada. Contudo, nos últimos vinte anos surgiram novas técnicas, cujo uso reduz o tempo e aumenta, consideravelmente, a taxa de isolamento fúngico. No entanto, grande número de infecções fúngicas disseminadas ainda continuam não diagnosticadas ou são detectadas tardiamente prejudicando o tratamento do paciente (Kiehn *et al.*, 1983; Bille *et al.*, 1984; Kiehn, 1989).

A lise-centrifugação é uma dessas técnicas, está disponível comercialmente (Isolator® System, Wampole Laboratories, Division of Carter-Wallace, Incorporated, Cranbury, N.J., USA) e tornou-se o método de escolha para o isolamento de leveduras e fungos dimórficos do sangue periférico (Bille *et al.*, 1983; Kellog *et al.*, 1984; Alexander, 2002).

A presença de microrganismos viáveis na corrente sanguínea sugere infecção ativa nos tecidos e a recuperação do paciente poderá depender de um isolamento e identificação precoce do agente etiológico.

As fungemias são causadas principalmente por leveduras dos gêneros *Candida* e *Cryptococcus*, fungos dimórficos como o *Histoplasma capsulatum* e mais raramente fungos filamentosos, especialmente espécies de *Fusarium*.

2 **OBJETIVOS**

2.1 Objetivo geral

Definir os dados demográficos, as doenças de base e os fatores associadas aos episódios de fungemia ocorridos na Santa Casa Complexo-Hospitalar nos últimos treze anos.

2.2 Objetivo específico

Identificar os agentes etiológicos das fungemias.

Determinar a mortalidade global entre os pacientes com fungemia.

3 **MATERIAL**

Há treze anos, desde janeiro de 1994 a técnica do Isolator® está na rotina do Laboratório de Micologia (Santa Casa-Complexo Hospitalar). De cada paciente com suspeita de fungemia foi colhido assepticamente sangue de veia periférica com o sistema vacutainer nos tubos de Isolator®: 1,5 ml (infantil) e 10 ml (adulto). No período máximo de 16h após a colheita os tubos de Isolator® (adulto) foram centrifugados a 5.100 r.p.m por 30 min e processados conforme as instruções do fabricante e o sedimento (cerca de 1,5 ml) foi igualmente inoculado em tubos contendo meio sólido, ágar Sabouraud (SAB) e infusão de cérebro-coração (BHI) que foram incubados aerobicamente a temperatura de 25º e 35ºC, respectivamente. Este processamento foi realizado em capela de fluxo lamelar classe IIB. Os meios inoculados foram examinados visualmente em dias alternados por três semanas (Tarrand *et al.*, 1991; Morrel *et al.*, 1996). Os cultivos positivos foram separados em leveduras, fungo dimórfico e fungo filamentoso para identificação etiológica.

3.1 Identificação etiológica

A identificação etiológica foi feita a partir do isolamento em meios de cultivos (SAB e BHI), separados e identificados do seguinte modo (ver anexo I):

a) leveduras

Candida: micromorfologia, técnica do tubo germinativo e método automatizado (ID 32C, ATB Expression, bioMérieux)

Saccharomyces, *Rhodotorula* e *Trichosporon*: micromorfologia e método automatizado (ID 32C, ATB Expression, bioMérieux)

Cryptococcus sp: micromorfologia, meio bioquímico (ágar Uréia, ágar Niger, canavanina-glicina-azul de bromotimol – CGB) (Kwon-Chung *et al.*, 1982)

b) fungos dimórficos

micromorfologia , viragem no BHI e SAB

c) fungos filamentosos

micromorfologia

Cada isolado foi classificado como contaminante ou como patógeno (Thomson *et al.*, 1984; Creger *et al.*, 1998). O significado clínico foi estabelecido pela revisão do prontuário clínico:

1. Patógeno verdadeiro: o mesmo microrganismo foi isolado de e/ou visualizado em biópsia de tecido ou identificado em múltiplos espécimes estéreis; o fungo isolado é patógeno primário.
2. Contaminante: o microrganismo não é patógeno primário, o isolamento foi único, não houve correlação clínica, nem fator predisponente.

Para cada paciente com fungemia as seguintes informações foram obtidas: idade, sexo, tempo de hospitalização, presença e tipo de doença(s) predisponente(s), grau de imunodepressão, cirurgia prévia ou profilaxia antifúngica, episódio(s) prévio(s) de sepse bacteriana, presença de NPT e cateter intravascular (ver anexo II) (Creger *et al.*, 1998).

Para avaliar o significado clínico de cada episódio de fungemia consideramos os seguintes parâmetros: número de episódios de hemocultivos positivos, número de dias consecutivos após a documentação de fungemia, isolamento do mesmo microrganismo de outros sítios que não o sangue, presença de febre, calafrios e lesões disseminadas (cutâneas ou retina); deterioração clínica sem outra explicação; resposta terapêutica e evolução (ver anexo II).

3.2 Isolator® - etapas da colheita e processamento

3.2.1 Isolator® adulto

1º Desinfetar a rolha com Polivinilpirroldina-iodo (PVPI) 10% - deixar secar por 1 min;

2º Desinfetar a região da punção com álcool 70°GL;

3º Usar o sistema vacutainer para a colheita, a quantidade mínima de sangue deve ser de 8 ml e máxima de 10 ml; Não deve forçar a entrada do sangue no tubo, pois a rolha poderá ser deslocada;

4º Inverter o tubo 4 a 5 vezes para homogeneizar.

Transporte

1º Manter à temperatura ambiente;

2º Processar imediatamente, ou deixar em repouso por no máximo 16h;

3º Quantidade de sangue inferior a 10 ml é obrigatório processar imediatamente.

Centrifugação

1º Centrifugar a 5.100 r.p.m. por 30 min em rotor de ângulo fixo (45°);

2º Os tubos podem ficar em repouso por até 2h, após devem ser centrifugados novamente por mais 30 min. Esta perda de tempo não pode ultrapassar as 16h permitidas entre a colheita e o processamento.

Processamento

1º Transferência para o Isostat rack (estante redonda): fazer pequena quebra na inserção da rolha. Manusear os tubos cuidadosamente para não misturar. Se isto ocorrer centrifugar novamente por 30 min.

2º Desinfecção da rolha: usar algodão embebido em PVPI 10%, deixar secar e colocar na base Isostat press;

3º Remoção do Isostat Cap (cápsula que permite a entrada da pipeta) do pacote: retirar a tampa empurrando a base da mesma através do papel, segurando pelos lados - não tocar na parte de cima, ou na ponta “em prego” - e colocar a tampa sobre a rolha de cada tubo;

4º Pressão na tampa: pressionar a tampa de modo que o “prego” penetre na rolha e a tampa fique firme;

5º Remoção da pipeta “sobrenadante” e preparo: remover uma pipeta, tocando apenas no bulbo apertando antes de inserir no tubo;

6º Drenagem do fluido sobrenadante: inserir a pipeta rapidamente através da membrana na tampa, mantendo o bulbo pressionado até a inserção (caso se formem bolhas centrifugar novamente);

7º Homogeneização: utilizar o vortex por 20 segundos;

8º Remoção do concentrado com pipeta “concentrate”: pegar a pipeta pelo bulbo apertando até inserir no tubo através da tampa, após soltar gradualmente o bulbo, drenando o concentrado;

9º Inoculação em meio de cultivo: SAB, a 25ºC e BHI, a 35ºC;

3.2.2 Isolator® infantil

1º Desinfetar a rolha com PVPI 10% - deixar secar 1 min;

2º Desinfetar o local da punção com álcool 70°GL;

3º Usar o sistema vacutainer para a colheita, a quantidade mínima de sangue deve ser de 1 ml e máxima de 1,5 ml. Não forçar a entrada, a rolha poderá ser deslocada;

4º Inverter o tubo 4 a 5 vezes para homogeneizar.

Transporte

1º Manter à temperatura ambiente;

2º Processar imediatamente, ou deixar em repouso por no máximo 16h;

Processamento

1º Proceder antissepsia da tampa do tubo do isolator®;

2º Homogenizar o tubo do isolator® em vortex por 30”;

3º Inocular em meios de cultivos, SAB e BHI, com seringa, colocando-os a temperaturas de 25°C e 35°C, respectivamente.

4 **MÉTODOS**

4.1 Delineamento e período do estudo

Estudo de coorte retrospectivo e observacional, janeiro de 1994 a janeiro de 2007.

4.2 População do estudo

A população do estudo foram incluídos todos os casos consecutivos de fungemia diagnosticados na Santa Casa-Complexo Hospitalar no período de janeiro de 1994 a janeiro de 2007.

4.3 Instituição

A Santa Casa de Porto Alegre é um complexo hospitalar de atendimento terciário composto por sete hospitais, que ao todo somam mais de 1.076 leitos, 132 dos quais são de terapia intensiva. Ocorrem na Instituição 45.237 internações e 749.387 consultas ambulatoriais por ano. É uma Instituição com mais de 200 anos de existência, servindo como hospital-escola as Faculdade de Medicina da Fundação Faculdade Federal de Ciências Médicas de Porto Alegre e da Universidade Federal do Rio Grande do Sul. Cerca de 60% dos leitos do hospital são destinados a pacientes do Sistema Único de Saúde, e 40% a pacientes particulares ou conveniados.
(fonte: http://www.santacasa.org.br/santacasa/desempenho_assistencial.asp, acesso 23/08/2007).

4.4 Aspectos éticos

O projeto de pesquisa é uma continuidade do projeto "Estudo de caso-controle sobre fatores de risco e preditores de mortalidade em pacientes com candidemia nosocomial" do Dr. Alessandro Comarú Pasqualotto com orientação do Dr. Luiz Carlos Severo, onde o mesmo foi previamente avaliado e aprovado pelo Comitê de Ética em Pesquisa da Santa Casa-Complexo Hospitalar (protocolo número 547/02), através do

parecer número 254/02, de 03 de dezembro de 2002. Sendo que este estudo foi ampliado para fungemia causada por outras leveduras (*Cryptococcus*, *Saccharomyces Rhodotorula* e *Trichosporon*), fungos dimórficos e fungos filamentosos. Este projeto foi previamente avaliado e aprovado pelo Comite de Ética da Santa Casa-Complexo Hospitalar de Porto Alegre (protocolo número 1149/05), através do parecer número 798/05, de 8 de novembro de 2005. O projeto garantiu o anonimato dos pacientes incluídos na pesquisa. No anexo III consta declaração referente a aspectos de ética enviado ao Comitê de Ética.

4.5 Fundamentação teórica

O sistema de lise-centrifugação é uma técnica com excelentes resultados no isolamento de leveduras e fungos dimórficos térmicos, especialmente o *Histoplasma capsulatum* de amostras de sangue (Wheat & Bartlett, 1984; Corti *et al.*, 2000). Este sistema está composto fundamentalmente por polianetol sulfato de sódio, polipropilenoglicol e saponina.

Na técnica de lise-centrifugação o sangue obtido por punção venosa estéril é inoculado em um tubo que contém polianetol sulfato de sódio, polipropilenoglicol e saponina. Após o sangue é mesclado com estas três substâncias no tubo, centrifugado (5.100 r.p.m.) e o sedimento obtido é semeado em meio de cultivo para fungos (SAB, a 25ºC e BHI, a 35ºC), que são observados por três semanas (Murray, 1991).

O polianetol sulfato de sódio funciona como anticoagulante, polipropilenoglicol como substância antiespumante. A saponina é o componente mais importante do Isolator®, pois lisa glóbulos brancos e hemácias além de inativar complemento e outros antimicrobianos do plasma, permitindo a liberação intracelular dos fungos, aumentando a taxa de crescimento e abreviando o tempo de cultivo (2-10d), tanto para fungos leveduriformes como para filamentosos. Tem sensibilidade superior a outras técnicas para hemocultivo ($p < .0001$) (Lyon & Woods, 1995).

5 **ARTIGOS**

5.1. Infección nosocomial por *Trichosporon asahii* : revisión clínica de 22 casos

Infección nosocomial por *Trichosporon asahii:* revisión clínica de 22 casos

Gustavo da Silva Rodrigues[1], Rodrigo Rosa Ubatuba de Faria[2], Luciana Silva Guazzelli[3], Flávio de Mattos Oliveira[3] y Luiz Carlos Severo[4]

[1]Laboratório SANI, Passo Fundo, [2]Biólogo-Biopatologia, Universidade Luterana do Brasil, [3]Laboratório de Micologia, Santa Casa-Complexo Hospitalar, Porto Alegre, [4]Pesquisador 1C do CNPq, Universidade Federal do Rio Grande do Sul (UFRGS), Brasil

Resumen

Presentamos una serie de 22 casos de infección nosocomial por *Trichosporon asahii,* detectados en un periodo de seis años (1999-2005). Los pacientes presentaron edades entre 6 y 72 años, con un promedio de 47,3 años y con leve predominio de hombres. Las enfermedades subyacentes, fueron insuficiencia respiratoria, cáncer, diabetes, insuficiencia renal crónica, cirrosis y sida. Las condiciones predisponentes fueron antibioticoterapia, ventilación mecánica, sonda vesical, catéter, corticoides, trasplantes, inmunosupresores, quimioterapia, granulocitopenia, procedimiento quirúrgico y diálisis peritoneal ambulatoria continua. Los antifúngicos más utilizados fueron el fluconazol y la anfotericina B. Algunos pacientes recibieron varios antifúngicos. Cinco pacientes no fueron tratados con antifúngicos y un paciente recibió factor de estimulación de colonias granulocíticas (G-CSF). De los 22 pacientes, nueve presentaron mejoría clínica, otros nueve pacientes fallecieron y de cuatro pacientes se desconoce su evolución.
T. asahii es un patógeno emergente en pacientes inmunodeficientes y su presencia en las muestras clínicas de éstos no debe ser considerada una colonización por el importante riesgo de infección invasora. En aquellos pacientes susceptibles de padecer una trichosporonosis se debe mantener alto grado de sospecha y vigilancia clínica para el diagnóstico de esta infección.

Palabras clave

Trichosporon asahii, Trichosporonosis, Infección nosocomial, Patógeno emergente

Nosocomial infection due to *Trichosporon asahii:* Clinical revision of 22 cases

Summary

Twenty two cases of nosocomial infection caused by *Trichosporon asahii*, detected during a period of six years (1999-2005) is described. The patients were predominantly males with an average age of 47.3 years-old. The predominant diseases in the study group were respiratory insufficiency, cancer, diabetes, chronic renal insufficiency, cirrhosis and AIDS. The main predisposing conditions were antibiotic therapy, mechanical ventilation, urethral catheterization, catheter, corticoids, transplant, immunosuppressive therapy, chemotherapy, granulocytopenia, surgical procedures and continuous ambulatory peritoneal dialysis. The most used antifungal drugs were fluconazol and amphotericin B. In some cases several antifungals were administered. Five patients did not receive antifungal treatment, and one patient received granulocyte colony stimulating factor (G-CSF). Nine patients showed clinical improvement, nine died and the progress of four patients is unknown.
T. asahii is an emergent pathogen in patients with immunodeficiency and its presence in these type hosts can not be considered colonization, as there is an important risk of invasive infection. So, in susceptible patients to develop trichosporonosis it is advisable to take into consideration this disease especially in intensive clinical care units.

Key words

Trichosporon asahii, Trichosporonosis, Nosocomial infection, Emergent pathogen

Dirección para correspondencia:
Dr. Luiz Carlos Severo
Laboratório de Micologia
Hospital Santa Rita
Santa Casa - Complexo Hospitalar
Annes Dias 285
90.020-090, Porto Alegre, RS, Brasil
Fax: +55 51 3214 8435
E-mail: severo@santacasa.tche.br

Aceptado para publicación el 28 de febrero de 2006

Las infecciones hospitalarias por hongos oportunistas son cada vez más frecuentes. Aunque *Candida* sea el agente responsable de la mayoría de estas micosis, en los últimos años otras levaduras han sido descritas como agentes patógenos en ascensión. El género *Trichosporon* provoca infecciones localizadas o sistémicas en pacientes inmunodeficientes [22].

Las enfermedades por *Trichosporon* en los seres humanos han sido atribuidas a *Trichosporon beigelii* durante mucho tiempo. Sin embargo, en 1992 fue revisada la taxonomía de esta especie [8] y dividida en seis especies distintas con diferentes manifestaciones clínicas [9]. *Trichosporon asahii y Trichosporon mucoides* están involucradas en infecciones profundas, mientras *Trichosporon asteroides, Trichosporon ovoides y Trichosporon cutaneum* son responsables de la piedra blanca y de infecciones cutáneas. *Trichosporon inkin* es agente causal tanto de infecciones cutáneas como diseminadas [22,24]. Recientemente, *Trichosporon pullulans* ha sido considerado como un patógeno emergente y se ha asociado a infecciones sistémicas [15]. *T. asahii* es el agente etiológico más frecuente de trichosporonosis, siendo responsable de aproximadamente un 90% de los casos de infección por *Trichosporon* en pacientes inmunodeficientes [5,12,22].

En este trabajo presentamos 22 casos de infección nosocomial por *T. asahii y* comentamos las presentaciones clínicas, las condiciones predisponentes, la terapéutica utilizada y la evolución de la enfermedad.

Pacientes y métodos

Fueron revisados retrospectivamente los casos de trichosporonosis por *T. asahii* existentes en los archivos del Laboratorio de Micología, Santa Casa-Complejo Hospitalario, Porto Alegre, Rio Grande do Sul, Brasil. Se revisaron las historias clínicas de 22 pacientes en los cuales fue aislado *T. asahii* de 30 muestras clínicas (23 de orina, tres de sangre, dos de líquido ascítico, una de líquido de diálisis y una de líquido pleural) entre agosto de 1999 y junio de 2005.

Tabla 1. Características de los pacientes con infección nosocomial por *T. asahii*.

Paciente	Sexo / edad (años)	Enfermedad(es) asociada(s)	Condiciones predisponentes	Manifestaciones clínicas	Tratamiento	Evolución
1	F / 31	Ninguna	Trasplante hepático, catéter, inmunosupresores, ventilación mecánica y antibióticos	Ninguna	FLC	Mejoría
2	M / 39	Sida	Sonda vesical, catéter, ventilación mecánica y antibióticos	Fiebre	AMB	Mejoría
3	M / 51	Insuficiencia renal crónica	Trasplante renal, sonda vesical, inmunosupresores, ventilación y antibióticos	Fiebre, lesiones cutáneas	AMB	Mejoría
4	M / 84	Insuficiencia respiratoria aguda	Sonda vesical, catéter, corticosteroides, ventilación mecánica y antibióticos	Ninguna	FLC	Fallecimiento
5	F / 45	Ninguna	Procedimiento quirúrgico, drenaje pleural, sonda vesical, catéter, ventilación mecánica y antibióticos	Ninguna	FLC, AMB e ITC	Mejoría
6	F / 32	Cáncer de cuello de útero	Quimioterapia, granulocitopenia y antibióticos	Fiebre	FLC y AMB	Mejoría
7	F / 22	Ninguna	Procedimiento quirúrgico, sonda vesical, ventilación mecánica, corticosteroides y antibióticos	Ninguna	No realizado	Desconocida
8	M / 06	Insuficiencia renal crónica	Catéter de Tenckoff, CAPD, DVP, ventilación mecánica y antibióticos	Peritonitis purulenta, fiebre	AMB	Mejoría
9	M / 40	Fibrosis pulmonar idiopática	Sonda vesical, catéter, ventilación mecánica, corticosteroides, antibióticos	Lesiones cutáneas	FLC	Mejoría
10	M / 61	Insuficiencia renal crónica y cirrosis	Procedimiento quirúrgico, sonda vesical, catéter, ventilación mecánica, corticosteroides y antibióticos	Fiebre	AMB	Fallecimiento
11	M / 72	EPOC y enfisema pulmonar	Trasplante pulmonar, inmunosupresores, drenaje torácico, sonda vesical, catéter, ventilación, corticosteroides y antibióticos	Fiebre y sepsis	FLC	Fallecimiento
12	M / 53	PBE y cirrosis	Ventilación mecánica y antibióticos	Lesiones cutáneas	No realizado	Desconocida
13	M / 58	Cirrosis	Sonda vesical, catéter, ventilación mecánica, corticosteroides y antibióticos	Ninguna	No realizado	Fallecimiento
14	F / 70	Diabetes mellitus	Sonda vesical y antibióticos	Lesiones cutáneas	FLC	Mejoría
15	M / 59	Diabetes mellitus, LMA, aspergilosis pulmonar invasora	Quimioterapia, granulocitopenia, catéter, ventilación mecánica, corticosteroides y antibióticos	Fiebre, fungemia e infiltrados pulmonares	FLC, AMB, ITC, AMBL y CAS	Fallecimiento
16	F / 01	Neuroblastoma	Quimioterapia, granulocitopenia, catéter, ventilación mecánica y antibióticos	Lesiones cutáneas	AMB	Mejoría
17	F / 68	Cáncer de pulmón	Quimioterapia, granulocitopenia, sonda vesical, catéter, ventilación mecánica, corticosteroides y antibióticos	Ninguna	AMB	Fallecimiento
18	M / 54	Diabetes mellitus	Trasplante pulmonar, inmunosupresores, sonda vesical, ventilación mecánica, corticosteroides y antibióticos	Ninguna	FLC y ITC	Fallecimiento
19	M / 71	Insuficiencia respiratoria crónica	Sonda vesical, catéter, drenaje torácico, ventilación mecánica, corticosteroides y antibióticos	Fiebre, lesiones cutáneas y sepsis	FLC y AMB	Fallecimiento
20	M / 48	Cáncer de vejiga	Quimioterapia, granulocitopenia, catéter, ventilación mecánica y antibióticos	Fiebre	FLC	Fallecimiento
21	M / 29	Ninguna	Trasplante conjugado de riñón y páncreas, inmunosupresores, sonda vesical y antibióticos	Ninguna	No realizado	Desconocida
22	F / 48	Fibrosis pulmonar	Corticosteroides	Ninguna	No realizado	Desconocida

F, femenino; M, masculino; LMA, leucemia mieloide aguda; EPOC, enfermedad pulmonar obstructiva crónica; PBE, peritonitis bacteriana espontánea; DVP, derivación ventrículo-peritoneal; CAPD, diálisis peritoneal ambulatoria continua; FLC, fluconazol; AMB, anfotericina B; ITC, itraconazol; AMBL, anfotericina B liposomal; CAS, caspofungina.

El diagnóstico microbiológico se efectuó mediante examen microscópico directo y cultivo del sedimento obtenido tras la centrifugación de las muestras clínicas.

Los sedimentos de orina fueron sembrados en agar glucosado de Sabouraud (SGA, Difco) con cloranfenicol (Unión Química, Brasil) e incubados a 25 °C. Las demás muestras clínicas fueron sembradas en SGA y en agar infusión cerebro y corazón (BHI, Biobrás, Brasil) e incubados a 25 °C y 37 °C, respectivamente. Antes de la siembra, se realizó una concentración de la muestra de sangre utilizando un sistema de lisis-centrifugación (Isolator System, Wampole Labs., EE.UU.), considerado como método de referencia para el aislamiento de hongos a partir de sangre [1].

En los cultivos positivos, las colonias desarrolladas se estudiaron microscópicamente y se identificaron utilizando el método automatizado ATB Expression (bioMérieux, Francia). Para ello, a partir de colonias jóvenes (24 h) se prepararon suspensiones estandarizadas (Mac Farland 2) en un densitómetro (ATB 1550, bioMérieux). Enseguida fueron transferidas a un medio sintético semi-sólido (C Medium) e inoculadas en las galerías (ID 32C, bioMérieux) de 32 cúpulas cada una con substrato deshidratado. Después de 24, 48 o 72 h de incubación a 30 °C, el crecimiento fue interpretado en el ATB Expression.

Resultados

Los pacientes presentaron edades entre 6 y 72 años, con un promedio de 47,3 años, existiendo un leve predominio de hombres (14 de 22) (Tabla 1). Entre las enfermedades predisponentes, destacaron la disfunción o sintomatología respiratoria, el cáncer de órgano sólido o la leucemia (seis pacientes), la diabetes (tres pacientes), la insuficiencia renal crónica (tres pacientes), la cirrosis (tres pacientes), la aspergilosis (un paciente) y el sida (un paciente). Las condiciones predisponentes en los 22 casos fueron: antibioticoterapia (21 pacientes), ventilación mecánica (18 pacientes), sonda vesical (14 pacientes), catéter venoso central (13 pacientes), corticosteroides (10 pacientes), trasplantes (cinco pacientes), inmunosupresores (cinco pacientes), quimioterapia (cinco pacientes), granulocitopenia (cinco pacientes), procedimiento quirúrgico (tres pacientes), catéter de Tenckoff (un paciente) y diálisis peritoneal ambulatoria continua (un paciente). En catorce de las veintitrés muestras de orina el hongo fue observado en el examen microscópico directo. En el paciente 20, ocho muestras, recogidas en un período de 36 días (del 9 de septiembre al 15 de octubre de 2004), fueron positivas en cultivo y seis en el examen directo (Tabla 2).

Las colonias aisladas entre tres a cinco días en los medios SGA y BHI fueron siempre cremosas, de textura rugosa a cerebriforme y de color blanco a crema. El color del reverso fue similar al del anverso de la colonia. Microscópicamente, en los cultivos se observaron hifas fragmentadas, blasto-artroconidios y ausencia de apresorios. Las pruebas bioquímicas interpretadas en el ATB Expression identificaron *T. asahii* en todos los casos. El porcentaje de seguridad diagnóstica y valores "T" fueron mayores que 90% y 0,3, respectivamente (Tabla 2).

El fluconazol y la anfotericina B fueron los antifúngicos más utilizados en el tratamiento de las infecciones (seis pacientes cada uno). Se combinaron antifúngicos en cinco pacientes; en tres de ellos (pacientes 5, 6 y 19) fueron administrados uno o más triazoles combinados con anfotericina B. En el paciente 18 se cambió fluconazol por itraconazol y en el paciente 15 el régimen terapéutico fue establecido en función de la existencia de una coinfección por *Aspergillus flavus* (aspergilosis invasora) (Tabla 1). Cinco pacientes no fueron tratados con antifúngicos. El paciente 16 recibió factor de estimulación de colonias de granulocitos (G-CSF). Al paciente 8 hubo que retirarle el catéter de Tenckoff. Nueve de los 22 pacientes presentaron mejoría clínica, nueve fallecieron y en cuatro se desconoce la evolución.

Tabla 2. Diagnóstico microbiológico mediante examen directo e identificación automatizada.

Paciente	Fecha	Muestra(s) clínica(s)	Examen directo	ATB Expression	
				Seguridad diagnóstica (%)	Valor T
1	12/08/99	Orina	Positivo	98,40	0,69
2	17/03/00	Orina	Negativo	ND	ND
3	30/06/00	Orina	Negativo	99,90	0,75
4	30/06/00	Orina	Positivo	99,70	0,47
5	23/10/00	Líquido pleural	Negativo	94,70	0,44
6	15/03/01	Orina	Negativo	99,90	0,37
7	30/08/01	Orina	Positivo	99,90	0,38
8	24/12/01	Líquido de diálisis	Negativo	99,29	0,53
9	17/01/02	Orina	Negativo	99,90	0,57
10	17/05/02	Líquido de ascitis	Negativo	99,90	0,87
11	13/06/02	Orina	Negativo	99,90	0,72
		Sangre	NA	99,90	0,72
12	13/09/02	Líquido de ascitis	Negativo	99,70	0,42
13	27/09/02	Orina	Positivo	99,60	0,61
14	14/10/02	Orina	Negativo	91,00	0,59
15	22/10/02	Sangre	NA	99,80	0,59
16	12/12/02	Sangre	NA	99,60	0,58
17	10/02/03	Orina	Negativo	99,60	0,61
18	09/05/03	Orina	Positivo	ND	ND
19	17/09/03	Orina	Positivo	96,00	0,61
20	09/09/04	Orina*	Positivo	99,90	0,73
21	13/05/05	Orina	Negativo	99,70	0,83
22	08/06/05	Orina	Negativo	99,70	0,57

ND, no disponible; NA, no aplicable; (*), ocho muestras

Discusión

T. asahii es un hongo ubicuo que se encuentra, sobre todo, en el suelo y el agua. Es considerado como parte de la microbiota humana, especialmente de la región perigenital. Sin embargo, en pacientes con condiciones predisponentes (sonda vesical, catéteres venosos centrales y de Tenckoff, drenajes pleural y torácicos, procedimientos quirúrgicos, etc.) y enfermedades inmunosupresoras (neoplasias hematológicas, otros cánceres y sida) puede ser causa de infección sistémica [23,24]. Otros factores asociados incluyen el uso de agentes quimioterápicos, fármacos por vía intravenosa, fármacos inmunosupresores y trasplantes; así como el uso crónico de corticoides, antibioticoterapia de amplio espectro y ventilación mecánica [22,25].

La trichosporonosis puede limitarse a un órgano o diseminarse hematógenamente a otros tejidos. Los pacientes con granulocitopenia prolongada son los más susceptibles a sufrir una diseminación de la infección [5,24]. Por otra parte, la trichosporonosis en niños o neonatos es infrecuente [18].

Las infecciones profundas por *T. asahii* están asociadas a un amplio espectro de manifestaciones clínicas siendo la fiebre, las lesiones pulmonares, cutáneas y el shock séptico las más importantes [5,22]. Las lesiones en la piel son papulares, eritematosas o purpúreas [10]. Las infecciones pulmonares pueden estar asociadas a otros patógenos como *Aspergillus* [5].

No están bien definidos los criterios microbiológicos para infección del tracto urinario por levaduras [20]. Así, el aislamiento de *Trichosporon* en orina puede ser indicativo de infección [20] o de colonización y su presencia debe valorarse junto con el cuadro clínico del paciente. El aislamiento de este hongo en más de una muestra clínica requiere realizar un estudio más completo para descartar una infección diseminada pues la presencia de *T. asahii* en estas localizaciones puede preceder a una infección invasora. La presencia de este patógeno en sitios habitualmente estériles como sangre [3-5,24,25], líquido pleural, líquido ascítico y líquido de diálisis es clínicamente relevante, salvo que se trate de una contaminación de la muestra.

El tratamiento de la trichosporonosis es controvertido sobre todo el de las formas clínicas diseminadas, donde los resultados del tratamiento antifúngico suelen ser muy desfavorables y la mortalidad de los pacientes con granulocitopenia persistente es elevada (70%) [5]. *T. asahii* es relativamente resistente a la anfotericina B [21]. En cambio, los agentes triazólicos (fluconazol, itraconazol y voriconazol) se muestran más efectivos tanto *in vitro* [18] como *in vivo* [2], siendo el fluconazol el fármaco preferido y el voriconazol el más activo [6,7,17]. Dependiendo del curso de la infección, puede ser necesario el uso de dos antifúngicos asociados [3-5,25]. La caspofungina tiene una baja actividad *in vitro* frente a *T. asahii* [16], pero su efecto es mayor cuando combinado con anfotericina B [19] y/o anfotericina B liposomal [3].

Las medidas de apoyo pueden ser importantes en el control de la infección. Cabe destacar la administración de G-CSF en pacientes granulocitopénicos [16] y la remoción de catéteres y otros equipamientos implantables [14].

En lo referente a la evolución clínica de estas trichosporonosis, se observó que los casos fatales representaron el 40%. En la forma diseminada la tasa de mortalidad fue del 66%, una tasa semejante a la reportada en otros estudios. En nueve pacientes la respuesta clínica fue favorable y en cuatro la evolución se desconoce. En la mayoría de los casos fatales (pacientes 4, 10, 13, 17-20) no se pudo establecer si el óbito fue consecuencia de la infección, siendo más probable que ocurriese debido a la evolución de sus respectivas enfermedades de base. Únicamente en los pacientes 11 y 15 la causa de la muerte fue atribuida a la infección fúngica.

En conclusión se debe tener presente que *T. asahii* es un patógeno emergente en pacientes inmunodeficientes y su presencia en estos huéspedes no debe ser considerada una colonización, pues existe un riesgo importante de infección invasora. De esta forma, en aquellos pacientes susceptibles a padecer una trichosporonosis se debe mantener alto grado de sospecha y vigilancia clínica para el diagnóstico de esta infección.

Agradecemos al Dr. Sören Franz Marian Chicata Sutmöller, por la lectura crítica de este trabajo.

Bibliografía

1. Alexander BD. Diagnosis of fungal infection: new technologies for the mycology laboratory. Transpl Infect Dis 2004; 4: 32-37.
2. Anaissie EJ, Hachem R, Karyotakis NC, Gokaslan A, Dignani MC, Stephens LC, Tin-U CK. Comparative efficacies of amphotericin B, triazoles, and combination of both as experimental therapy for murine trichosporonosis. Antimicrob Agents Chemother 1994; 38: 2541-2544.
3. Antachopoulos C, Papakonstantinou E, Dotis J, Bibashi E, Tamiolaki M, Koliouskas D,Roilides E. Fungemia due to *Trichosporon asahii* in a neutropenic child refractory to amphotericin B clearance with voriconazole. J Pediatr Hematol Oncol 2005; 27: 283-285.
4. Bassetti M, Bisio F, Di Biagio A, Pierri I, Balocco M, Soro O, Cruciani M, Bassetti D. *Trichosporon asahii* infection treated with caspofungin combined with liposomal amphotericin B. J Antimicrob Chemother 2004; 54: 575-577.
5. Chowdhary A, Ahmad S, Khan Z, Doval DC, Randhawa HS. *Trichosporon asahii* as an emerging etiologic agent of disseminated trichosporonosis: a case report and an update. Indian J Med Microbiol 2004; 22: 16-22.
6. Falk R, Wolf DG, Shapiro M, Polacheck I. Multidrug-resistant *Trichosporon asahii* isolates are susceptible to voriconazole. J Clin Microbiol 2003; 41: 911.
7. Girmenia C, Pagano L, Martino B, D'Antonio D, Fanci R, Specchia G, Melillo L, Buelli M, Pizzarelli G, Venditti M, Martino P, GIMEMA Infection program. Invasive infections caused by *Trichosporon* species and *Geotrichum capitatum* in patients with hematological malignancies: a retrospective multicenter study from Italy and review of the literature. J Clin Microbiol 2005; 43: 1818-1828.
8. Guého E, Improvisi L, de Hoog GS, Dupont B. *Trichosporon* on humans: a practical account. Mycoses 1994; 37: 3-10.
9. Guého E, Smith M, de Hoog GS, Billon-Grand G, Christen R, Vegte WHB. Contributions to a revision of the genus *Trichosphoron*. Antonie van Leeuwenhoek 1992; 61: 289-316.
10. Herbrecht R, Koenig H, Waller J, Liu KL, Guého E. *Trichosporon* infections: Clinical manifestatios and treatment. J Mycol Med 1993; 3: 129-136.
11. Ichikawa T, Nishikawa A, Ikeda R, Shinoda T. Structural studies of a cell wall polysaccharide of *Trichosporon asahii* containing antigen II. Eur J Biochem 2001; 268: 5098-5106.
12. Ichikawa T, Sugita T, Wang L, Yokoyama K, Nishimura K, Nishikawa A. Phenotypic switching and activity of the pathogenic yeast *Trichosporon asahii*. Microbiol Immunol 2004; 48: 237-242.
13. Kontoyiannis DP, Torres HA, Chagua M, Hachem R, Tarrand JJ, Bodey GP, Raad II. trichosporonosis in a tertiary care cancer center: risk factors, changing spectrum and determinants of outcome. Scand J Infect Dis 2004; 36: 564-569.
14. Lopes JO, Silva CB, Kmohan C, Salla A, Righi R. Peritonite por *Trichospboron beigelli* em uma criança durante tratamento por diálise peritoneal ambulatorial continuada. J Pediatr 1995; 71: 341-343.
15. Moylett EH, Chinen J, Shearer WT. *Trichosporon pullulans* infection in 2 patients with chronic granulomatous disease: an emerging pathogen and review of the literature. J Allergy Clin Immunol 2003; 6: 1370-1374.
16. Muranaka H, Suga M, Nakagawa K, Sato K, Gushima Y, Ando M. Effects of granulocyte and granulocyte-macrophage colony-stimulating factors in a neutropenic murine model of trichosporonosis. Infect Immun 1997; 65: 3422-3429.
17. Paphitou NI, Ostrosky-Zeichner L, Paetznick VL, Rodriguez JR, Chen E, Rex JH. *In vitro* antifungal susceptibilities of *Trichosporon* species. Antimicrob Agents Chemother 2002; 46: 1144-1146.
18. Salazar GE, Campbell JR. Trichosporonosis, an unusual fungal infection in neonates. Pediatr Infect Dis J 2002; 21: 161-52.
19. Serena C, Pastor FJ, Gilgado F, Mayayo E, Guarro J. Efficacy of micafungin in combination with other drugs in a murine model of disseminated trichosporonosis. Antimicrob Agents Chemother 2005; 49: 497-502.
20. Silva V, Zepeda G, Alvarado D. Infección urinaria nosocomial por *Trichosporon asahii*. Primeros dos casos en Chile. Rev Iberoam Micol 2003; 20: 21-23.
21. Toriumi T, Sugita T, Nakajima M, Matsushima T, Shinoda T. Antifungal pharmacodynamic characteristics of amphotericin B against *Trichosporon asahii*, using time-kill methodology. Microbiol Immunol 2002; 46: 89-93.
22. Walsh TJ, Groll A, Hiemenz J, Fleming R, Roilides E, Anaissie E. Infections due to emerging and uncommom medically important fungal pathogens. Clin Microbiol Infect 2004; 10: 48-66.
23. Warnock D. Fungal infections in neutropenia: current problems and chemotherapeutic control. J Antimicrob Chemother 1998; 41: 95-105.
24. Wolf DG, Falk R, Hacham M, Theelen B, Boekhout T, Scorzetti G, Shapiro M, Block C, Salkin IF, Polacheck I. Multidrug-resistant *Trichosporon asahii* infection of nongranulocytopenic patients in three intensive care units. J Clin Microbiol 2001; 39: 4420-4425.
25. Yang R, Ao J, Wang W, Song K, Li R, Wang D. Disseminated trichosporonosis in China. Mycoses 2003; 46: 519-523.

5.2. *Histoplasma capsulatum* fungemia in patients with acquired immunodeficiency syndrome: detection by lysis-centrifugation blood-culturing technique

Rev. Inst. Med. trop. S. Paulo
49(3):135-138, May-June, 2007

Histoplasma capsulatum FUNGEMIA IN PATIENTS WITH ACQUIRED IMMUNODEFICIENCY SYNDROME: DETECTION BY LYSIS-CENTRIFUGATION BLOOD-CULTURING TECHNIQUE

Flávio de Mattos OLIVEIRA(1), Sérgio Sônego FERNANDES(2), Cecília Bittencourt SEVERO, Luciana Silva GUAZZELLI(1) & Luiz Carlos SEVERO(3)

SUMMARY

Progressive disseminated histoplasmosis (PDH) is an increasingly common cause of infection in patients with acquired immune deficiency syndrome (AIDS). We report 21 cases of PDH associated with AIDS diagnosed by lysis-centrifugation blood culture method. The most prevalent clinical findings were fever, weight loss, respiratory symptoms, and mucocutaneous lesions. Chest roentgenogram showed diffuse pulmonary infiltrates in 13 of 21 patients (62%). Brochoalveolar fluid has yelded positive culture in four patients only in medium with cycloheximide.

KEYWORDS: *Histoplasma capsulatum*; Histoplasmosis; Lysis-centrifugation; Fungemia.

INTRODUCTION

Recent advances in the formulation of blood culture media have significantly improved the recovery of fungus from blood culture bottles[4]. Lysis-centrifugation has become the "gold standard" for recovering thermally dimorphic fungi, especially *Histoplasma capsulatum*[1].

In Brazil, specimens of blood have been reported for diagnosis of progressive disseminated histoplasmosis (PDH) in patient with acquired immunodeficiency syndrome (AIDS)[2,5,10], but rarely with lysis-centrifugation blood-culturing technique[14,16]. The limited data in our country justify this report.

MATERIALS AND METHODS

Our laboratory (Laboratório de Micologia, Santa Casa Complexo Hospitalar, Porto Alegre, RS, Brasil) adopted lysis-centrifugation system (Isolator, Wampole Laboratories, Granbury, New Jersey, USA) for performance of all routine fungal blood cultures in January 1994. Isolator tubes contain EDTA as an anticoagulant, saponin as a lysing agent, and a fluorocarbon compound that acts as a cushion during centrifugation. The Isolator was processed according to the manufacturer's directions in a biological safety cabinet and using Isostat device to reduce contamination. The sediment of lysed cells was inoculated onto solid media: brain-heart infusion and Löwenstein-Jensen at 35 ºC; Sabouraud dextrose agar at 25 ºC. All media were incubated for four weeks and examined twice weekly. Identification of *H. capsulatum* was confirmed by microscopy, demonstrating the presence of tuberculate macroconidia and the yeast phase of the fungus.

This study was approved by the ethic committee of Santa Casa Complexo Hospitalar.

RESULTS

Between January 1994 and March 2006, 21 patients (17 men and four women; age range, 24-44 years; mean, 33 years) with positive *H. capsulatum* fungemia and AIDS were identified in the files of the laboratory. All patients had at least one positive blood culture for *H. capsulatum*. The time between the arrival of blood specimens in the Isolator tubes at our laboratory and identification of *H. capsulatum* ranged from five to 11 days (median of seven days). In 12 of 21 patients (57%) histoplasmosis was diagnosed by the first time after blood culture. We retrospectively reviewed the patients' clinical findings. Fever greater than 38 °C occurred in 18 patients (time range, 2-76 days; mean, 20 days), 14 had weight loss, 14 had mucocutaneous lesions and 10 had respiratory complaints. The patients presented with multiple papules, maculopapules, folliculitis and plaques with ulcerations on the extremities, trunk, and face. Biopsy examination of skin lesions showed sparce perivascular infiltrate with polymorphonuclear leukocytes, and occasional histiocytes. Many small spherical to oval, budding yeasts were visible with Gomori stain and *H. capsulatum* was recovered in culture. Chest roentgenograms were abnormal (diffuse bilateral reticulonodular or interstitial infiltrates) in 62% (13 of 21). *Histoplasma* M precipitin band was detected by immunodiffusion in

(1) PPG - Ciências Pneumológicas – Mestrado e Doutorado, Universidade Federal do Rio Grande do Sul (UFRGS). Laboratório de Micologia/Hospital Santa Rita, Santa Casa-Complexo Hospitalar, Porto Alegre, RS, Brazil.
(2) Faculdade de Medicina, UFRGS.
(3) Departamento de Medicina Interna, UFRGS. Pesquisador 1B do CNPq.
Correspondence to: Dr. Luiz Carlos Severo, Laboratório de Micologia/Hospital Santa Rita, Santa Casa-Complexo Hospitalar, Annes Dias 285, 90020-090 Porto Alegre, RS, Brazil. Phone: +55 51 32148409; Fax:+55 51 32148435. E-mail: severo@santacasa.tche.br, severo@pesquisador.cnpq.br

five of 14 cases (36%). Table 1 summarizes the sites were *H. capsulatum* were isolated.

Amphotericin B desoxycholate (induction) and itraconazole (maintenance) were the most frequent treatment 44% (eight of 18). Two patients (10 and 11) died before treatment could be administered.

During the hospitalization 10 patients experienced other opportunistic infections: cryptococcal meningitis (5), *Pneumocystis jirovecii* pneumonia (1). Table 2 summarizes neurologic findings and results of mycology. In one patient *Candida krusei* was also isolated from esophagus and urine. In three patients supervened bacterial septicemia: *Staphylococcus*, *Salmonella*, and *Corynebacterium*.

Table 1
Sites where *H. capsulatum* were isolated

Case	Sex, age	Specimen				
		Blood	Skin	Bone marrow	Lymph node	Other
01	M, 40	+*	+	ND	ND	
02	F, 44	+	+*	+	ND	
03	F, 32	+*	ND	ND	+	
04	M, 31	+*	ND	ND	ND	
05	M, 37	+	+	ND	ND	Lungs, alveolar lavage*#
06	M, 29	+*	ND	ND	ND	
07	M, 35	+*	+	ND	+	
08	M, 37	+	ND	+*	ND	
09	F, 31	+	ND	ND	+*	Nasal mucosa
10	M, 42	+*	ND	ND	ND	CNS, biopsy from chiasma opticum
11	M, 38	+	ND	ND	ND	Lungs, alveolar lavage fluid*#
12	F, 25	+	ND	+*	ND	CNS, cerebrospinal fluid
13	M, 29	+*	+	ND	ND	
14	M, 30	+*	+	ND	ND	
15	M, 30	+*	+	ND	ND	Lungs, alveolar lavage*#
16	M, 34	+*	ND	ND	ND	
17	M, 24	+*	+	ND	+	
18	M, 29	+	+*	+	ND	Lungs, alveolar lavage*#
19	M, 32	+	+*	ND	ND	
20	M, 36	+*	ND	ND	ND	
21	M, 40	+	+	+*	ND	

* Histoplasmosis was identified for the first time; # Inoculated in Mycosel; CNS, Central nervous system; ND, Not done.

Table 2
Sites where *Cryptococcus neoformans* were isolated

Case	Sex, age	Specimen	Mycology			Neurologic findings
			Microscopic	Culture	Latex	
10	M, 42	Cerebrospinal fluid Serum	+	+	1:128 1:32	Headache, convulsion, visual abnormality, dizziness
11	M, 38	Cerebrospinal fluid Urine	+	+	ND	Headache, convulsion, dizziness
12	F, 25	Serum	ND	ND	1:32	None
19	M, 32	Serum	ND	ND	1:16	None
21	M, 40	Blood Cerebrospinal fluid Serum	ND ND ND	+ ND ND	ND 1:128 1:512	Headache, convulsion, dizziness

Latex, cryptococcal antigen titers; ND, Not done.

Total mortality was 52% (11 of 21). In the group of dead patients, nine (82%) experienced other opportunistic infections (five cryptococcosis, three bacterial sepsis, one pneumocystosis).

DISCUSSION

Histoplasmosis is a serious opportunistic infection in patients with AIDS, often representing the first manifestation of the syndrome[19]. The diagnosis of PDH complicating AIDS is easy to establish, because yeast cells are numerous. In our series, the delay in diagnosis (mean, 20 days of fever) due to not considering histoplasmosis in the differential diagnosis of tuberculosis.

In Brazil, PDH in AIDS patients frequently was diagnosed by isolation of *H. capsulatum* from blood, bone marrow, alveolar lavage fluid, cerebrospinal fluid, and histopathologic examination of mucocutaneos lesions[2,5,13-14,16]. In our country *H. capsulatum* was isolated from blood in brain heart infusion (BHI) agar[10] and BHI biphasic medium of agar and broth[2] and rarely by lysis-centrifugation system[14]. Although, the yeast occasionally may be seen within the macrophages in the peripheral-blood smear[7] Isolator should be used in cases of suspected disseminated disease[18] due to sensitivity and reduced mean time for detection of positive culture[8]. If lysis-centrifugation is made, the bone marrow biopsy is not necessary[17].

In patients with pulmonary infiltrates alveolar lavage should be performed. In respiratory specimens selective medium with cycloheximide (Mycosel or Micobiotic) proved useful in the isolation of *H. capsulatum*[16].

Inasmuch lysis-centrifugation blood culture system detect *H. capsulatum* fungemia earlier than other systems[12] and positive blood culture indicate a poor prognosis all routine blood cultures at the laboratory were performed by Isolator since January 1994. It was important because the diagnosis of PDH had not been made until the recovery of *H. capsulatum* from the blood in 57% of our cases. For this reason the implementation of this methodology is highly recommended[15].

Our series of 21 patients over 12 years old show that fungemia due to *H. capsulatum*, although much less common than candidemia, is not rare.

The diagnosis of PDH should be considered in AIDS patients with persistent fever, pulmonary complain, and skin lesions[3,6,9]. Bone marrow biopsy is an important diagnostic approach although invasive. The positive results with blood lysis-centrifugation cultures showed improvement in the success rate with the definitive diagnosis of histoplasmosis when compared to conventional techniques[4,15] including detecting transient fungemia in self-limited acute pulmonary histoplasmosis[11].

In conclusion, Isolator is extremely helpful in patients with AIDS who have PDH to detect *H. capsulatum* fungemia in a reduced time, ensuring that when antifungal therapy starts early, this is essential for recovery. It is necessary for the Infectious diseases specialist and the clinician to familiarize themselves with this technique in order to avoid a more invasive diagnostic approach.

RESUMO

Fungemia por *Histoplasma capsulatum* em pacientes com a síndrome da imunodeficiência adquirida: detecção através da técnica de hemocultivo por lise-centrifugação

Histoplasmose progressiva disseminada (HPD) tem aumentado e é causa comum de infecção em pacientes com síndrome da imunodeficiência adquirida (Aids). Relatamos 21 casos de HPD associado com Aids diagnosticada pela técnica de hemocultivo por lise-centrifugação. Os achados clínicos mais prevalentes foram febre, perda de peso, sintomas respiratórios e lesões mucocutâneas. Raios X de tórax mostrou infiltrados pulmonares difusos em 13 dos 21 pacientes (62%). Amostras de lavado broncoalveolar foram positivos em apenas 4 pacientes através de meio com cicloheximinda.

REFERENCES

1. ALEXANDER, B.D. - Diagnosis of fungal infection: new technologies for the mycology laboratory. **Transpl. infect. Dis., 4**: 32-37, 2002.

2. ALVES, K.S. - **Histoplamose disseminada e síndrome de imunodeficiência adquirida. Estudo clínico-laboratorial de 28 casos.** São Paulo, 1996. (Dissertação de mestrado - Faculdade de Medicina da Universidade de São Paulo).

3. ANTINORI, S.; MAGNI, C.; NEBULONI, M. *et al.* - Histoplasmosis among human immunodeficiency virus-infected people in Europe: report of 4 cases and review of the literature. **Medicine (Baltimore), 85**: 22-36, 2006.

4. BIANCHI, M.; ROBLES, A.M.; VITALE, R. *et al.* - The usefulness of blood culture in diagnosing HIV-related systemic mycoses: evaluation of a manual lysis centrifugation method. **Med. Mycol., 38**: 77-80, 2000.

5. BORGES, A.S.; FERREIRA, M.S.; SILVESTRE, M.T.A.; NISHIOKA, S.A. & ROCHA, A. - Histoplasmose em pacientes imunodeprimidos: estudo de 18 casos observados em Uberlândia, MG. **Rev. Soc. bras. Med. trop., 30**: 119-124, 1997.

6. CORTI, M.E.; CENDOYA, C.A.; SOTO, I. *et al.* - Disseminated histoplasmosis and AIDS: clinical aspects and diagnostic methods for early detection. **AIDS Patient Care STDS, 14**: 149-154, 2000.

7. EDELMAN, M. & McKITRICK, J. - Images in clinical medicine. *Histoplasma capsulatum* in a peripheral - blood smear. **New Engl. J. Med., 342**: 28, 2000.

8. GUERRA-ROMERO, L.; EDSON; R.S.; COCKERILL III, F.R.; HORSTMEIER, C.D. & ROBERTS, G.D. - Comparison of Du Pont Isolator and Roche Septi-Chek for detection of fungemia. **J. clin. Microbiol., 25**: 1623-1625, 1987.

9. KARIMI. K.; WHEAT, L.J.; CONNOLLY, P. *et al.* - Differences in histoplasmosis in patients with acquired immunodeficiency syndrome in the United States and Brazil. **J. infect. Dis., 186**: 1655-1660, 2002.

10. LEIMANN, B.C.Q.; PIZZINI, C.V.; MUNIZ, M.M. *et al.* - Histoplasmosis in a Brazilian center: clinical forms and laboratory tests. **Rev. iberoamer. Micol., 22**: 141-146, 2005.

11. PAYA, C.V.; ROBERTS, G.D. & COCKERILL III, F.R. - Transient fungemia in acute pulmonary histoplasmosis: detection by new blood-culturing techniques. **J. infect. Dis., 156**: 313-315, 1987.

12. REIMER, L.G.; WILSON, M.L. & WEINSTEIN, M.P. - Update on detection of bacteremia and fungemia. **Clin. Microbiol. Rev., 10**: 444-465, 1997.

13. ROCHA, M.M. & SEVERO, L.C. - Histoplasmose disseminada em pacientes com síndrome de imunodeficiência adquirida (SIDA). Estudo de 25 casos. **Rev. Inst. Med. trop. S. Paulo, 36**: 167-170, 1994.

14. ROSAS, R.C.; SALOMÃO, R.; da MATTA, D.A. *et al*. - Bloodstream infections in late-stage acquired immunodeficiency syndrome patients evaluated by a lysis centrifugation system. **Mem. Inst. Oswaldo Cruz, 98**: 529-532, 2003.

15. SANTIAGO, A.R.; HERNANDEZ, B.; RODRIGUEZ, M. & ROMERO, H. - A comparación del método convencional con el de lisis/centrifugación modificado para el diagnóstico de fungemias. **Rev. iberoamer. Micol., 21**: 198-201, 2004.

16. UNIS, G.; SILVA, V.B. & SEVERO L.C. - Histoplasmose disseminada e SIDA. Importância do meio de cultivo para o espécime clínico-broncoscópico. **Rev. Soc. bras. Med. trop., 37**: 234-237, 2004.

17. WHEAT, L.J. - Histoplasmosis in AIDS. **AIDS clin. Care, 4**: 1-8, 1992.

18. WHEAT, L.J. - Laboratory diagnosis of histoplasmosis: update 2000. **Semin. resp. Infect., 16**: 131-140, 2001.

19. WHEAT, L.J.; CONNOLLY-STRINGFIELD, P.A.; BAKER, R.L. *et al.* - Disseminated histoplasmosis in the acquired immune deficiency syndrome: clinical findings, diagnosis and treatment, and review of the literature. **Medicine (Baltimore), 69**: 361-374, 1990.

Received: 5 June 2006
Accepted: 1 November 2006

5.3. *Cryptococcus gattii* fungemia: report of a case with lung and brain lesions mimicking radiological features of malignancy

Rev. Inst. Med. trop. S. Paulo
49(4):263-265, July-August, 2007

Cryptococcus gattii FUNGEMIA: REPORT OF A CASE WITH LUNG AND BRAIN LESIONS MIMICKING RADIOLOGICAL FEATURES OF MALIGNANCY

Flávio de Mattos OLIVEIRA(1,2), Cecília Bittencourt SEVERO(1,2), Luciana Silva GUAZZELLI(1,2) & Luiz Carlos SEVERO(3,4)

SUMMARY

A 64-year-old apparently immunocompetent white man developed lung and brain lesions of disseminated cryptococcosis. The radiologic features mimicked those of lung cancer metastatic to the central nervous system. *C. gattii* was recovered from cultures of bronchoalveolar lavage fluid, brain biopsy, and blood. The same fungus was recovered from pulmonary and brain specimens at autopsy. Serum and cerebrospinal fluid cryptococcal antigen tests were diagnostic in our case and should be included in the diagnostic evaluation of unexplained pulmonary and cerebral lesions. A literature search showed few reports of fungemia by this species of *Cryptococcus*, contrasting to *C. neoformans*.

KEYWORDS: Fungemia; Cryptococcosis; *Cryptococcus gattii*.

INTRODUCTION

Cryptococcus gattii differs from the closely related yeast *C. neoformans* in phenotypic characters, natural habitat, epidemiology, clinical manifestation of disease and response to antifungal therapy. *C. gattii* unlike *C. neoformans*, is considered to be a primary fungal pathogen because virtually always affects apparently immunocompetent hosts, human and animal[8,9].

We describe a case of *Cryptococcus gattii* infection in a patient without evidence of immunosuppression (including HIV infection) with fungemia, an unusual manifestation of this species of *Cryptococcus*, in whom lung and brain lesions of disseminated cryptococcosis mimicked bronchogenic carcinoma with brain metastases.

CASE REPORT

A 64-year-old apparently immunocompentent white man was admitted to the hospital complaining of fever, weakness, anorexia, headache, dyspnea, cough, purulent sputum production, and disorientation (one week duration). It was noted that he had lost 20 kg in weigh during the previous three months. He had smoked one pack of cigarettes daily for the past 50 years. One year prior to admission arterial hypertension was found. On physical examination he was a thin man who was confused and mumbling. The temperature was 39 °C, the pulse was 90, and the respirations were 27. The blood pressure was 140/90 mmHg. The patient had a stiff neck, positive Lasegue's, and Kerning's signs. Bilateral Brudzinski signs were present. Ophthalmologic examination revealed pupils non reactive and bilateral papilledema. Chest roentgenogram revealed overinflation of both lungs and a spherical mass lesion, 5 cm in diameter, in the superior segment of the right lower lobe (Fig. 1). Contrast-enhanced axial cranial computed tomographic (CT) scan showed nonenhancing cystic large mass within the right temporal lobe, hydrocephalus (Fig. 2) and multiple nodules through the brain parenchyma. Dexametazone, 4 mg IV 6/6 hr, was begun, and the patient was transferred to an intensive care unit. He underwent fiberoptic bronchoscopy with bronchoalveolar lavage. The bronchial specimens obtained were centrifuged at 700 rpm for 15 minutes. The sediment was smeared onto glass slides. The preparations were allowed to air dry and them stained with May-Grunwald Giemsa (MGG) solution. Procedure: The air-dried slides were fixed in absolute methanol for five minutes and incubated in 2% MGG solution in distilled water for 15 minutes at room temperature. After rinsing in tap water the slides were air dried in a vertical position. Microscopic examination of bronchial washings and brushings revealed numerous narrow-based budding, encapsulated yeasts (Fig. 3). Sabouraud's dextrose agar (SDA) plus chloramphenicol showed cream-colored mucoid colonies. The culture hydrolysed urea and produced melaninlike pigments in the presence of *Guizotia abyssinica* agar (Staib agar). The canavanine-glycine-bromothymol agar coloured by blue indicated *C. gattii*. The brain temporal mass was aspirated under stereotactic CT guidance. The mucopurulent liquid obtained was microscopically evaluated. Acid-fast organisms, bacterial, and malignant cells were not seen in the smears with special stains, but abundant encapsulated cells morphologically consistent with *Cryptococcus* were identified, and grew *C. gattii*. Bacterial cultures were negative. Lumbar puncture revealed clear cerebrospinal fluid (CSF) with a protein concentration of 105 mg/dL and glucose of 51 mg/dL, while in blood glucose was 143 mg/dL. There were 16 erythrocytes and two white cells

(1) Programa de Pós-Graduação em Pneumologia - Mestrado e Doutorado, Universidade Federal do Rio Grande do Sul.
(2) Laboratório de Micologia, Hospital Santa Rita, Santa Casa-Complexo Hospitalar, Porto Alegre, RS, Brasil.
(3) Departamento de Medicina Interna, Universidade Federal do Rio Grande do Sul, Porto Alegre, RS, Brasil.
(4) Pesquisador 1C do CNPq.
Correspondence to: L.C. Severo, Laboratório de Micologia/Hospital Santa Rita, Santa Casa-Complexo Hospitalar, Annes Dias 285, 90020-090 Porto Alegre, RS, Brazil. Tel.: +55.51.32148409; Fax:+55.51.32148435. E-mail: severo@santacasa.tche.br, severo@pesquisador.cnpq.br

per cubic millimeter. The CSF cryptococcal antigen titer was 1:4096 with a serum titer of 1:2048. An anti-HIV test (ELISA) was negative. Specimen of blood was obtained for culture with lysis-centrifugation technique (Isolator, Wampole Laboratories, Cranbury, NJ) and plated on SDA and brain-heart infusion agar (BHI) grew *C. gattii*.

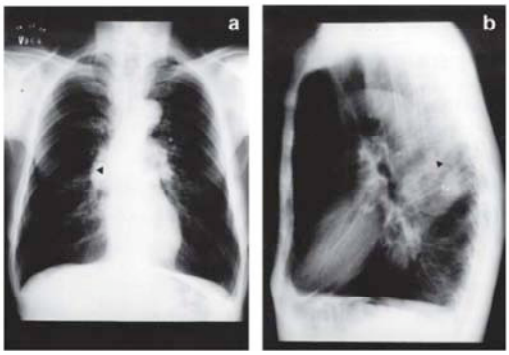

Fig. 1 - Frontal (a) and lateral (b) chest x-rays showing a spherical mass lesion (arrows), 5 cm in diameter.

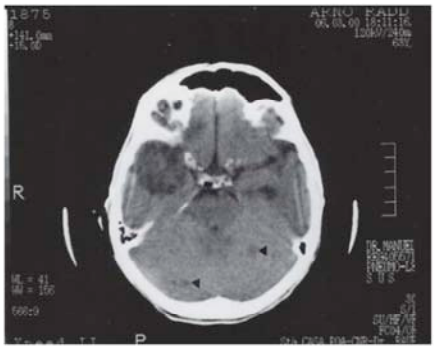

Fig. 2 - Contrast-enhanced axial cranial computed tomographic scan reveals cryptococcoma within the right temporal lobe and multiple nodules (arrows) through the brain parenchyma.

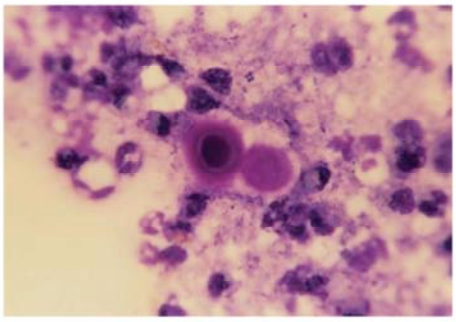

Fig. 3 - Routine MGG stain of bronchoalveolar lavage fluid showing a characteristic budding encapsulated yeast cell of *Cryptococcus gattii* (x400).

Follow-up cranial CT scan carried out one day later revealed the persistence of the mass lesions and the progression of hydrocephalus. Another chest roentgenogram showed diffuse opacity throughout both lungs with a diffuse brochopneumonic appearance.

Despite the institution of intravenous amphotericin B, the patient continued to deteriorate neurologically and died two days after beginning therapy. The autopsy showed diffuse *Cryptococcus* pneumonia and multiple intracerebral lesions with numerous fungal cells. Cultures revealed *C. gattii*.

DISCUSSION

Cryptococcus gattii is emerging as a primary human and animal pathogen. The principal source of the organism is wood debris in hollows, particularly that of eucalyptus[8] and is prevalent in the tropical and subtropical areas and rare in cold climates[5]. In contrast, *C. neoformans* is widespread in the environment, especially in areas burdened with bird excreta, and has a worldwide distribution. After gaining entry through the respiratory tract, both have trophism for the central nervous system (CNS); patients infected by *C. gattii* are more likely to evidence focal pulmonary and CNS mass[2,7,9]. Both inhibition of polymorphonuclear leukocyte migration to the site of infection[3] and inhibition of neutrophil function[11] by products of *C. gattii* may promote survival of extracellular organisms, and local multiplication to form cryptococcomas.

Infection due to *C. gattii* can pose a diagnostic challenge to clinicians. This case vividly illustrates the fact that, pulmonary cryptococcosis with mass-like lesion with associated cerebral infection, exhibit radiologic features that mimic those of lung cancer metastatic to the CNS. Isolated pulmonary cryptococcosis simulate pulmonary cancer particularly when it appears as an apical mass, including with a typical Pancoast's syndrome[6]. In these cases, cryptococcal antigen testing by latex agglutination, a rapid test with high specificity, would be useful in the differential diagnosis.

Fungemia[10] and funguria[4] by *C. gattii* is highly unusual. On the other hand, infections due to *C. neoformans* can be isolated from blood up to 63% of patients[9]. Positive blood culture is a sign of very poor prognosis and most patients had a high tissue burden of organisms in the lung and CNS[1], like our patient.

In summary, *C. gattii* must be included in the differential diagnosis of pulmonary and brain masses. Furthermore, with fungal cultures, smears, and serologic test systemic cryptococcosis will be diagnosed sooner, leading to earlier treatment which may be life-saving.

RESUMO

Fungemia por *Cryptococcus gattii*: relato de um caso com lesões cerebrais e pulmonares nos achados radiológicos mimetizando câncer

Homem branco de 64 anos, aparentemente imunocompetente, desenvolveu lesões pulmonares e cerebrais por criptococose dissemina-

da. Os achados radiológicos foram similares àqueles encontrados em pacientes com câncer de pulmão e metástase no sistema nervoso central. *C. gattii* foi isolado de cultivos de lavado broncoalveolar, biópsia cerebral e sangue. O mesmo fungo foi encontrado em fragmentos pulmonares e cerebrais obtidos da autópsia. Testes de antígeno no soro e no líquido cefalorraquidiano foram diagnóstico no nosso caso e devem ser incluídos na avaliação diagnóstica de lesões pulmonares e cerebrais indefinidas. Pesquisa na literatura mostrou poucos relatos de fungemia por esta espécie de *Cryptococcus*, contrastando com *C. neoformans*.

REFERENCES

1. CASADEVALL, A. & PERFECT, J.R. - Human cryptococcosis. In: CASADEVALL, A. & PERFECT, J.R. ***Cryptococcus neoformans***. Washington, American Society for Microbiology, 1998. p. 407-456.

2. CHEN, S.; SORRELL, T.; NIMMO, G. *et al*. - Epidemiology and host-and variety-dependent characteristics of infection due to *Cryptococcus neoformans* in Australia and New Zealand. Australasian Cryptococcal Study Group. **Clin. infect. Dis., 31**: 499-508, 2000.

3. DONG, Z.M. & MURPHY, J.W. - Effects of the two varieties of *Cryptococcus neoformans* cells and culture filtrate antigens on neutrophil locomotion. **Infect. Immun., 63**: 2632-2644, 1995.

04. IGREJA, R.P.; LAZÉRA, M.S.; WANKE, B. *et al*. - Molecular epidemiology of *Cryptococcus neoformans* isolates from AIDS patients of the Brazilian city, Rio de Janeiro. **Med. Mycol., 42**: 229-238, 2004.

5. KIDD, S.E.; HAGEN, F.; TSCHARKE, R.L. *et al*. - A rare genotype of *Cryptococcus gattii* caused the cryptococcosis outbreak on Vancouver Island (British Columbia, Canada). **Proc. nat. Acad. Sci. (Wash.), 101**: 17258-17263, 2004.

6. MITCHELL, D.H. & SORRELL, T.C. - Pancoast's syndrome due to pulmonary infection with *Cryptococcus neoformans* variety *gattii*. **Clin. infect. Dis., 14**: 1142-1144, 1992.

7. MITCHELL, D.H.; SORRELL, T.C.; ALLWORTH, A.M. *et al*. - Cryptococcal disease of the CNS in immunocompetent hosts: influence of cryptococcal variety on clinical manisfestations and outcome. **Clin. infect. Dis., 20**: 611-616, 1995.

8. SORRELL, T.C. - *Cryptococcus neoformans* variety *gattii*. **Med. Mycol., 39**: 155-168, 2001.

9. SPEED, B. & DUNT, D. - Clinical and host differences between infections with the two varieties of *Cryptococcus neoformans*. **Clin. infect. Dis., 21**: 28-34, 1995.

10. ST-GERMAIN, G.; NOEL, G. & KWON-CHUNG, K.J. - Disseminated cryptococcosis due to *Cryptococcus neoformans* variety *gattii* in a Canadian patient with AIDS. **Europ. J. clin. Microbiol. infect. Dis., 7**: 587-588, 1988.

11. WRIGHT, L.; BUBB, W.; DAVIDSON, J. *et al*. - Metabolites released by *Cryptococcus neoformans* var. *neoformans* and var. *gattii* differentially affect human neutrophil function. **Microbes Infect., 4**: 1427-1438, 2002.

Received: 31 August 2006
Accepted: 9 January 2007

6 CONSIDERAÇÕES FINAIS

- Os pacientes com diagnóstico de fungemia na Santa Casa-Complexo Hospitalar entre janeiro de 1994 e janeiro de 2007 foram em sua maioria do sexo masculino, porém sem significância estatística (55%), a idade variou de 12 dias à 97 anos e a idade mediana foi de 39,64 anos.

- As doenças de base mais frequentes foram câncer e Aids. Febre foi o sinal mais frequente.

- Na fungemia causada por leveduras do gênero *Candida*, as *Candida* não *albicans* foram isoladas com maior frequência 63,5%. Sendo que a *C. tropicalis* e *C. parapsilosis* foram as mais frequentes, 34,73% e 24,8% respectivamente.

- Nos casos de fungemias o mesmo microrganismo foi isolado também de outros sítios: criptococococemia (líquor, urina, fragmento hepático, pele, linfonodo, tumor cerebral, líquido de ascite, lavado brônquico, próstata, punção pulmonar, pulmão e biópsia nasal); candidemia (urina, liquido de diálise, pulmão, cateter e esôfago); fungemia por *Trichosporon* spp (urina e liquido articular); fungemia por *H. capsulatum* (pele, medula óssea e linfonodo).

- O mesmo microrganismo não foi isolado de outro sítio nas fungemias por *Rhodotorula* spp e *S. cerevisiae* .

- Embora as fungemias causadas por leveduras do gênero *Rhodotorula, Trichosporon* e *Saccharomyces* representaram 2,6%, deve-se levar em consideração que são patógenos emergentes e sua presença não pode ser considerada somente como colonização e/ou contaminação.

- Em alguns casos de fungemia, o isolamento do agente etiológico foi através do sistema Bact/Alert® SA (Biomérieux, Inc.) realizado no Laboratório Central da Santa Casa-Complexo Hospitalar: criptocococemia, 40%; candidemia, 75%; fungemia por *Trichosporon* spp, 50%; fungemia por *Rhodotorula* spp, 60%. E as fungemias causadas por *H. capsulatum* e *S. cerevisiae* somente detectadas pela técnica do Isolator®.

- O caso de *Pseudozyma aphidis* foi considerado contaminante, pois o microrganismo não é patógeno primário, o isolamento foi único, não houve correlação clínica e nem fator predisponente.

- A fungemia que apresentou mortalidade mais alta (52%) foi a causada por *H. capsulatum* . Provavelmente por todos pacientes apresentarem Aids como doença de base.

- A taxa de mortalidade global na fungemia variou entre 22% e 52%.

7 ANEXOS

7.1 Anexo I - Identificação etiológica

Micromorfologia

O exame micromorfológico tem a finalidade de confirmar se a colônia isolada é um fungo filamentoso, dimórfico ou uma levedura. Para tanto, observa-se na microscopia a presença de hifas septadas e ramificadas com presença ou não de microconídios; estruturas ovaladas com ou sem brotamento e eventual formação de pseudo-hifas e hifas; e leveduras com ou sem cápsula.

Identificação de leveduras

Tugo germinativo

É um teste que pode rapidamente distinguir *Candida albicans* de outras leveduras do gênero. Consiste na semeadura da levedura em um tubo de ensaio com 0,5 ml de soro humano. Incuba-se a 37°C por 2-3h. Terminado este período, faz-se uma lâmina e observa-se em microscópico se há formação de tubo germinativo. O exame será positivo quando houver crescimento de um filamento originado a partir da levedura sem zona de constrição, caso contrário o exame será considerado negativo.

Método automatizado

O método automatizado para identificação de leveduras é baseado em reações de turbinefrelometria e colorimetria. A técnica é composta por testes de assimilação padronizados e miniaturizados com uma base de dados especialmente adaptados. Estes testes de assimilação são feitos em uma galeria (ID 32 C), onde a mesma compõem-se de 32 cúpulas que contêm cada uma um substrato carbonado desidratado

Preparo da amostra

1º Providenciar colônia com 24-48h de crescimento;

2º Padronizar a colônia no densitômetro através da diluição de pequeno inóculo em água desmineralizada (suspension medium) a concentração deve ser de 2 McFarland (McF) ± 1 McF;

3º Depois de padronizada a amostra, transpor 250 μl para o meio sintético semisólido (c medium), onde irá ocorrer a homogeneização através de uma pipeta automática;

4º Inocular 135 μl de amostra em cada uma das cúpulas da galeria, e incuba-lá por 24-48-72h a 29°C ±2°C;

5º O crescimento é lido no ATB Express e a identificação é confirmada quando a hipótese diagnóstica for ≥ 90% e o índice de tipicidade > 0.

Provas bioquímicas

Utilizadas para confirmar características bioquímicas de algumas leveduras.

ágar Uréia

Meio utilizado para determinar a produção de urease pelo *Cryptococcus* . Onde ocorre a hidrólise da uréia com produção de amônia que alcaliniza o meio, mudando o pH e a cor do meio para tonalidade rósea. Esta mudança ocorre entre 24-48h.

ágar Niger

Meio utilizado para isolamento de *Cryptococcus* que produz fenol-oxidase na presença de sementes do Niger (*Guizotia abyssinica*) resultando na produção de melanina e desenvolvimento de cor marrom nas colônias. Esta mudança ocorre entre 24-48h.

CGB

Meio utilizado para identificar a espécie do *Cryptococcus*. O meio possui cor esverdeada e quando o fungo utiliza a canavanina (ácido fumárico, málico e succínico) como fonte de carbono, ocorre alteração do pH e mudança de cor do meio para azul cobalto. Esta mudança ocorre entre 24-72h.

7.2 Anexo II - Instrumento para colheita de dados

Dados de identificação

Nome:……. Registro……
Data internação:……Idade:……..Sexo: ( ) M ( ) F
Hospital……Nº caso:……

Condições predisponentes

Diabete melito	( ) Sim( ) Não	( ) Não informado
Insuficiência renal	( ) Sim( ) Não	( ) Não informado
HIV	( ) Sim( ) Não	( ) Não informado
Drogas injetáveis	( ) Sim( ) Não	( ) Não informado
Neutropênico	( ) Sim( ) Não	( ) Não informado
Sepse bacteriana	( ) Sim( ) Não	( ) Não informado

Neoplasia Qual:……
Transplante Qual:……. Tempo:……
Outros:……Qual:…..……

Dados clínicos

Motivo internação:…….

Unidade internação	( ) Clínica ( ) Cirúrgica	
Cateter	( ) venoso central	( ) arterial
NPT	( ) Sim( ) Não	( ) Não informado Nºde dias:…..
Terapia intensiva	( ) Sim( ) Não	( ) Não informado
Ventilação mecânica	( ) Sim( ) Não	( ) Não informado

Avaliação clínica de cada episódio de fungemia

Nº hemocultivo positivos:……..
Isolamento do mesmo microrganismo de outros sítios
( ) Sim( ) Não Qual (is):…….
Febre ( ) Sim( ) Não( ) Não informado Máx……..ºC Nº dias……..
Hipotermia ( ) Sim( ) Não( ) Não informado Mín…….ºCNº dias……... ...
Lesões disseminadas (cutâneas ou retina):……..……..
Deterioração clínica sem outra explicação: :……

Terapia antimicrobiana

Fluconazol	( ) Sim( ) Não( ) Não informado	Há quanto tempo:…….
Anfotericina B	( ) Sim( ) Não( ) Não informado	Há quanto tempo:…….
Itraconazol	( ) Sim( ) Não( ) Não informado	Há quanto tempo:…….
Voriconazol	( ) Sim( ) Não( ) Não informado	Há quanto tempo:…….

Outros……..

Evolução

( ) Alta hospitalar Data:…….Duração internação:…….
( ) Óbito Data:…….
( ) Complicações Qual(is):……..……

7.3 Anexo III - Declaração referente a aspectos de Ética Médica

O presente estudo é exclusivamente epidemiológico, não envolvendo a realização de qualquer intervenção terapêutica. Todas as informações clínico-epidemiológicas necessárias para o estudo serão obtidas através de revisão de prontuários, não havendo qualquer contato direto entre investigadores com os pacientes. A pesquisa tem interesse puramente científico.

As informações referentes aos pacientes serão mantidas em completo sigilo; os autores firmam compromisso com a confidencialidade garantido o sigilo quanto à identificação dos pacientes incluídos no estudo.

O projeto será enviado ao Comitê de Ética em Pesquisa Santa Casa de Complexo Hospitalar Porto Alegre. Certificamos que o estudo observará todos os padrões éticos estabelecidos pela Instituição.

Sem mais, colocamo-nos à disposição para qualquer informação adicional.

Flávio de Mattos Oliveira
Laboratório de Micologia
Curso de Pós-Graduação em Ciências Pneumológicas
Universidade Federal do Rio Grande do Sul

Profº Dr. Luiz Carlos Severo
Micologista e Pneumologista, Doutor em Medicina
Professor Associado, Nível I, Faculade de Medicina , Universidade Federal do Rio Grande do Sul
Pesquisador 1B do Conselho Nacional de Desenvolvimneto Científico e Tecnológico

7.4 Anexo IV - *Histoplasma capsulatum* recovery from the urine and a short review of genitourinary histoplasmosis

Histoplasma capsulatum **recovery from the urine and a short review of genitourinary histoplasmosis**

Alessandro Comarú Pasqualotto[1*], Flavio de Mattos Oliveira[2,3], & Luiz Carlos Severo[2,4]

[1] School of Medicine, The University of Manchester, United Kingdom.

[2] Mycology Laboratory, Santa Casa Complexo Hospitalar, Porto Alegre, Brazil.

[3] Post-graduation Program in Pulmonary Sciences, Universidade Federal do Rio Grande do Sul (UFRGS), Porto Alegre, Brazil.

[4] Associate Professor at the Department of Internal Medicine, UFRGS, Brazil.

Researcher at the CNPq (1B).

* *Address for correspondence*: Alessandro C Pasqualotto, MD, PhD. Educational and Research Centre, 2nd Floor, Wythenshawe Hospital, M23 9LT, United Kingdom.

Phone: +44 161 291 5811; Fax: +44 161 291 5806. E-mail: alessandro.pasqualotto@manchester.ac.uk

Abstract

Although virtually any organ can be involved in disseminated histoplasmosis, the recovery of *Histoplasma capsulatum* from the urine is a rare finding. Here we describe that a renal transplant recipient had *Histoplasma capsulatum* recovered from urinary sediment. The organism was also recovered from urine cultures. The potential implications of this finding are discussed, and the literature on genitourinary histoplasmosis is reviewed.

Key words: Histoplasma capsulatum, histoplasmosis, invasive fungal infection, urinary tract infection, urine.

Introduction

Disseminated histoplasmosis usually affects patients with AIDS, transplant recipients, patients with haematological malignancies, and those on corticosteroids or suffering from other conditions affecting cell-mediated immunity [1]. The infection is usually acquired by inhalation. Although virtually any organ can be involved when *Histoplasma capsulatum* disseminates from the lungs, positive urine cultures are rare findings in this context. As part of an audit of cases of disseminated histoplasmosis occurred in our institution, we noticed that *H. capsulatum* was repeatedly recovered from urinary culture in one patient. The rarity of this finding justified this case to be reported. Insights obtained from this case are discussed.

Case report

A 23 year-old man diagnosed with renal tubular acidosis received a living-related donor renal transplant in April 1983. His immunosuppressive regimen consisted of azathioprine (125 mg) and prednisone (10-20 mg). Two years after transplantation he was admitted to the hospital for fever and worsening renal function. Chest radiographs were normal and urinary cultures were negative. Subcutaneous nodules were observed on the right forearm and leg, and biopsy revealed a large number of small round budding yeast-like organisms. *H. capsulatum* was identified on microscopy, and the fungus was recovered at 25ºC in both Sabouraud dextrose agar and Sabouraud dextrose cycloheximide-chloramphenicol agar (Mycosel, BBL), and at 35ºC in brain-heart infusion. The diagnosis of histoplasmosis was also confirmed by the immunodiffusion and complement-fixation serologic tests performed at the Centers for Diseases Control and Prevention, Atlanta, USA. Amphotericin B deoxycholate was initiated and haemodialysis was required. Azathioprine was stopped and high dose of methylprednisolone was given in due to organ rejection. The patient gradually improved with antifungal therapy, with cessation of fever and reduction of subcutaneous nodules. Renal function also recovered with time, and azathioprine was restarted. The patient discharged on ketoconazole after a total of 2 g of amphotericin B.

Six years after transplantation he was readmitted to the hospital due to chronic organ rejection and relapsed histoplasmosis. Haemodialysis was again required. Analysis of urinary sediment showed budding yeast-like organisms (Figures 1 and 2). After 8 days of incubation at 25ºC on Mycosel, *H. capsulatum* grew in a urine sample. The patient completed 1.7 g of amphotericin B deoxycholate and was discharged from the hospital in good clinical conditions, even though urine cultures remained positive for *H. capsulatum*. The transplanted kidney was removed a month later due to organ rejection. Gross pathology revealed a cystic area 2 cm in diameter in the removed organ (Figure 3). Histopathological studies showed chronic rejection, with high number of yeast-like organisms suggesting *H. capsulatum* at Gomori methenamine silver (GMS) stain.

Discussion

Although autopsy series have revealed evidence of urogenital involvement in 17-40% of patients with disseminated histoplasmosis [2-4], genitourinary symptoms are rather uncommon in patients with histoplasmosis. The literature regarding this subject is summarised in Table 1. Similarly to the findings in our patient, most of the reports show kidney involvement. Next in frequency are the prostate gland and seminal vesicles, the penis, the testes and epididymis, and the urinary bladder. The vulva, the ovaries, and the ureters are very rarely affected. Nevertheless, it seems reasonable to assume that the incidence of *Histoplasma* genitourinary infection may be underestimated, since many patients are asymptomatic. Moreover, the genitourinary system is frequently either not examined or the results are not recorded in clinical or autopsy records of patients with histoplasmosis [5]. Many of these patients are non-immunocompromised individuals living or returning (sometimes after many years) from areas where histoplasmosis is endemic.

Most (if not all) cases of genitourinary histoplasmosis occur in the context of disseminated *Histoplasma* infection, and in rare cases the disease is initially manifested with complaints related to the genitourinary tract. Penile histoplasmosis often presents with ulcers reminding syphilitic lesions (i.e., indurated, non-tender, shallow ulcers). Since

genitourinary histoplasmosis can mimics other malignant or inflammatory conditions, a high index of suspicion is therefore required for a proper diagnosis. In the absence of overt disseminated disease, the diagnosis is frequently unsuspected and made only after biopsy and culture of the involved sites are performed. Serology (e.g., immunodiffusion or the complement-fixation serologic test) may be a valuable non-invasive tool to diagnose disseminated histoplasmosis in patients with genitourinary infection. However, as shown in Table 1, serology against *Histoplasma* species was performed in only one third of cases, though it was positive for more than 80% of patients tested.

Whereas genitourinary histoplasmosis seems to follow direct haematogenous seeding of *H. capsulatum*, it is difficult to conclusively demonstrate the origin of these infections. For instance, many cases of testicular or prostate involvement apparently occur after dissemination of the infection from contiguously infected organs (e.g., after infection of the epididymis or seminal vesicles). Actually, *H. capsulatum* has occasionally been recovered from the semen in cases of orchitis or prostatitis. As occurs for cryptococcosis, an infected prostate might also be a *nidus* leading to further haematogenous infection, particularly in the immunocompromised host, and a reservoir for relapsed infections. Interestingly, Sills *et al.* [50] reported the case of a patient who developed disseminated histoplasmosis with penile lesions after treatment with steroids. That was followed by the occurrence of vulvar lesions in his wife, suggesting the possibility of transmission of genitourinary histoplasmosis between humans as a venereal disease.

The precise mechanism of transmission of *H. capsulatum* in our patient is however not likely to be determined. Although there was no unequivocal evidence for lung involvement, kidney involvement could have occurred during disseminated disease from the lungs, at the time subcutaneous nodules were detected. A quiescent focus of kidney infection might then have been reactivated in the context of immunosuppression. Unfortunately, documentation regarding prior *Histoplasma* infection was not obtained, since serology for *H. capsulatum* was not performed before transplantation. It should be

noticed that southern Brazil is an endemic area for histoplasmosis [13], so previous6exposure to the fungus is also not unlikely. An alternative explanation would be the transmission of a contaminated kidney from the donor, as has been previously described [6, 9, 11, 12, 57]. However, there is no evidence for such an assumption. Due to the possibility of transmission of organs contaminated with *H. capsulatum*, serological screening of both donors and receptors in endemic histoplasmosis areas before transplantation seems warranted.

Previous studies have revealed that more than 90% of patients with AIDS and disseminated histoplasmosis eliminate *Histoplasma* antigens in the urine, which can be detected by sandwich enzyme immunoassay. In these patients, urine testing has revealed to be more sensitive than serum testing [1, 58]. Contrastingly with the high frequency *Histoplasma* antigens recovered from the urine of patients with disseminated disease, urine cytological diagnosis of fungi other than the *Candida* species is rather uncommon. A distinctive aspect in our report is the growth of *H. capsulatum* from a urine sample, a rare finding. It might be that the rare detection of *Histoplasma* in urine specimens is due to a low index of suspicion, since urine specimens are not generally submitted to fungal stains [55]. In addition, it is also likely that the current inability to grow the organism from the urine is related to the short duration used for routine culture of urine specimens [54]. As shown in Table 1, urine is not usually submitted to culture in patients with genitourinary histoplasmosis. It has been suggested that reactive urothelial changes as detected by urine cytology could be used as a diagnostic pitfall in patients with disseminated histoplasmosis involving the genitourinary tract [55].

Similar to other studies, we found that urine can remain positive for *Histoplasma*, regardless of effective antifungal therapy. The formation of a cystic lesion as described for our patient might have led to persistent and intermittent release of viable *Histoplasma* cells in the urine. In the study by Mukunyadzi *et al.* [55] despite the cessation of hematuria repeat urine cytology done after 2 weeks of treatment was still positive for a few *Histoplasma* organisms. Interestingly, the same also occurred in studies evaluating the performance of the urinary *Histoplasma* antigen in patients treated with antifungals.

Even though the amount of antigen detected in urine can be used to monitor a patient's response to therapy, persistence of positive results up to 112 weeks has been reported [59].

Renal failure has been suggested as a marker for renal histoplasmosis. In the study by Reddy *et al*. [23], 24% of patients with disseminated histoplasmosis (n=6) had positive urine cultures for *H. capsulatum*, and 67% of these patients had azotemia prior to institution of therapy. Smith *et al*. [18] also reported that 10 out of 26 patients with disseminated histoplasmosis had a urine culture which was positive for *Histoplasma*. In an analogous way, blood urea nitrogen or creatinine was high in 60% of these patients. Abnormal renal function correlated well with culture of *H. capsulatum* from urine – which also occurred for our patient. Nevertheless, some patients show impaired renal function after antifungal drugs are initiated (particularly amphotericin B), while others develop renal failure due to obstruction due to histoplasmosis involving the prostate, kidneys or ureters. In this Therefore, although an unspecific finding, the occurrence of renal failure in patients with disseminated histoplasmosis should alert to the possibility of genitourinary involvement by *H. capsulatum*.

In conclusion genitourinary histoplasmosis usually occurs in the context of disseminated *H. capsulatum* infection. In contrast to the elevated prevalence of genitourinary involvement in patients with disseminated histoplasmosis as demonstrated in autopsy studies, clinically manifested disease is rare. Most of these patients are asymptomatic, although in rare cases this may be the presentation symptom. A high index of suspicion is therefore required to diagnose *Histoplasma* involvement of genitourinary tract in the absence of systemic manifestations of the disease, particularly in non-endemic settings. Urine culture should be seen as an alternative source to recover *H. capsulatum* in patients with disseminated histoplasmosis, mainly in those with renal involvement. Serology is probably also useful in this context, although the diagnosis cannot be excluded in the presence of a negative serological result. The importance of genitourinary histoplasmosis as a *nidus* for disease relapse deserves further study.

Acknowledgments

Dr Pasqualotto receives a grant from CAPES (Brazilian government).

References

1. Kauffman CA. Histoplasmosis: a clinical and laboratory update. Clin Microbiol Rev 2007; 20: 115-132.
2. Goodwin RAJ, Shapiro JL, Thurman GH, Thurman SS, Des Prez RM. Disseminated histoplasmosis: clinical and pathologic correlations. Medicine 1980; 59: 1-33.
3. Parsons RJ, Zarafonetis CJD. Histoplasmosis in man: reports of seven cases and a review of 71 cases. Arch Intern Med 1945; 75: 1-23.
4. Salfelder K, Brass K, Doehnert G, Doehnert R, Sauerteig E. Fatal disseminated histoplasmosis: anatomic study of autopsy cases. Virchows Arch A Pathol Anat 1970; 350: 303-335.
5. Schwarz J. Mycotic prostatitis. Urology 1982; 19: 1-5.
6. Watanabe M, Hotchi M, Nagasaki M. An autopsy case of disseminated histoplasmosis probably due to infection from a renal allograft. Acta Pathol Jpn 1988; 38: 769-780.
7. Sridhar NR, Tchervenkov JI, Weiss MA, Hijazi YM, First MR. Disseminated histoplasmosis in a renal transplant patient: a cause of renal failure several years following transplantation. Am J Kidney Dis 1991; 17: 719-721.
8. Delfino VD, Guembarovski AL, Soares AE, Gordan PA, Matni AM, Mocelin AJ. Loss of renal allograft function caused by *Histoplasma capsulatum*. Transplant Proc 1995; 27: 1817-1818.
9. Davies SF, Sarosi GA, Peterson PK, Khan M, Howard RJ, Simmons RL, Najarian JS. Disseminated histoplasmosis in renal transplant recipients. Am J Surg 1979; 137: 686-691.
10. Superdock KR, Dummer JS, Koch MO, Gilliam DM, Van Buren DH, Nylander WA, Richie RE, MacDonell RCJ, Johnson HK, Helderman JH. Disseminated histoplasmosis presenting as urinary tract obstruction in a renal transplant recipient. Am J Kidney Dis 1994; 23: 600-604.
11. Wong SY, Allen DM. Transmission of disseminated histoplasmosis via cadaveric renal transplantation: case report. Clin Infect Dis 1992; 14: 232-234.
12. Hood AB, Inglis FG, Lowenstein L, Dossetor JB, MacLean LD. Histoplasmosis and thrombocytopenic purpura: transmission by renal homotransplantation. Can Med Assoc J 1965; 93: 587-592.
13. Unis G, Oliveira F de M, Severo LC. Disseminated histoplasmosis in Rio Grande do Sul. Rev Soc Bras Med Trop 2004; 37: 463-468.
14. Unis G, da Silva VB, Severo LC. Disseminated histoplasmosis and AIDS. The role of culture medium for the bronchoscopic clinical specimens. Rev Soc Bras Med Trop 2004; 37: 234-237.

15. Ahuja TS, Remmers A, Rajaraman S, Funtanilla M. Acute renal failure in a patient with AIDS: histoplasmosis-induced granulomatous interstitial nephritis. Am J Kidney Dis 1998; 32: E3.
16. Ludmerer KM, Kissane JM. Fever and renal failure in a 31-year-old male with AIDS. Am J Med 1997; 102: 310-315.
17. Burke DG, Emancipator SN, Smith MC, Salata RA. Histoplasmosis and kidney disease in patients with AIDS. Clin Infect Dis 1997; 25: 281-284.
18. Smith JW, Utz JP. Progressive disseminated histoplasmosis. A prospective study of 26 patients. Ann Intern Med 1972; 76: 557-565.
19. Kauffman CA, Israel KS, Smith JW, White AC, Schwarz J, Brooks GF. Histoplasmosis in immunosuppressed patients. Am J Med 1978; 64: 923-932.
20. Vanke J, Schwartz J. The gamut of histoplasmosis. Am J Med 1971; 50: 89-104.
21. Walker JV, Baran D, Yakub N, Freeman RB. Histoplasmosis with hypercalcemia, renal failure, and papillary necrosis: confusion with sarcoidosis. JAMA 1977; 237: 1350-1352.
22. Wheat LJ, Slama TG, Eitzen HE, Kohler RB, French ML, Biesecker JL. A large urban outbreak of histoplasmosis: clinical features. Ann Intern Med 1981; 94: 331-337.
23. Reddy P, Gorelick DF, Brasher CA, Larsh H. Progressive disseminated histoplasmosis as seen in adults. Am J Med 1970; 48: 629-636.
24. Kedar SS, Eldar S, Abrahamson J, Boss J. Histoplasmosis of kidneys presenting as chronic recurrent renal disease. Urology 1988; 31: 490-494.
25. Bullock WE, Artz RP, Bhathena D, Tung KS. Histoplasmosis. Association with circulating immune complexes, eosinophilia, and mesangiopathic glomerulonephritis. Arch Intern Med 1979; 139: 700-702.
26. Papo T, Boisnic S, Piette JC, Frances C, Beaufils H, Le TH, Godeau P. Disseminated histoplasmosis with glomerulonephritis mimicking Wegener's granulomatosis. Am J Kidney Dis 1993; 21: 542-544.
27. Binford CH. Histoplasmosis: tissue reactions and morphologic variations of the fungus. Am J Clin Pathol 1955; 25: 25-36.
28. Bersack SR, Howe JS, Rabson AS. Inflammatory pseudopolyposis of the small and large intestines with the Peutz-Jeghers syndrome in a case of diffuse histoplasmosis. Urology 1958; 80: 73-78.
29. Shah RD, Nardi PM, Han CC. Histoplasma prostatic abscess: rare cause in an immunocompromised patient. AJR Am J Roentgenol 1996; 166: 471.
30. Zighelboim J, Goldfarb RA, Mody D, Williams TW, Bradshaw MW, Harris RL. Prostatic abscess due to *Histoplasma capsulatum* in a patient with the acquired immunodeficiency syndrome. J Urol 1992; 147: 166-168.

31. Marans HY, Mandell W, Kislak JW, Starrett B, Moussouris HF. Prostatic abscess due to *Histoplasma capsulatum* in the acquired immunodeficiency syndrome. J Urol 1991; 145: 1275-1276.
32. Orr WA, Mulholland SG, Walzak MP. Genitourinary tract involvement with systemic mycosis. J Urol 1972; 107: 1047-1050.
33. Miller AA, Ramsden F, Geake MR. Acute disseminated histoplasmosis of pulmonary origin probably contracted in Britain. Thorax 1961; 16: 388-394.
34. Mawhorter SD, Curley GV, Kursh ED, Farver CE. Prostatic and central nervous system histoplasmosis in an immunocompetent host: case report and review of the prostatic histoplasmosis literature. Clin Infect Dis 2000; 30: 595-598.
35. Reddy PA, Sutaria M, Brasher CA, Christianson CS. Disseminated histoplasmosis: cutaneous (subcutaneous abscess), vesical and prostatic histoplasmosis. South Med J 1970; 63: 819-821.
36. Rubin H, Furcolow ML, Yates JL. The course and prognosis of histoplasmosis. Am J Med 1959; 27: 278-288.
37. Aach R, Kissane J. Clinicopathologic Conference. Chronic lymphocytic leukemia complicated by disseminated histoplasmosis. Am J Med 1967; 43: 593-603.
38. Schuster TG, Hollenbeck BK, Kauffman CA, Chensue SW, Wei JT. Testicular histoplasmosis. J Urol 2000; 164: 1652.
39. Boone WT, Allison F Jr. Histoplasmosis. Am J Med 1969; 46: 818-826.
40. Kauffman CA, Slama TG, Wheat LJ. *Histoplasma capsulatum* epididymitis. J Urol 1981; 125: 434-435.
41. Monroe M. Granulomatous orchitis due to *Histoplasma capsulatum* masquerading as sperm granuloma. J Clin Pathol 1974; 27: 929-930.
42. Randhawa HS, Chaturvedi S, Khan ZU, Chaturvedi VP, Jain SK, Jain RC, Bazaz-Malik G. Epididymal histoplasmosis diagnosed by isolation of Histoplasma capsulatum from semen. Mycopathologia 1995; 131: 173-177.
43. Preminger B, Gerard PS, Lutwick L, Frank R, Minkowitz S, Plotkin N. Histoplasmosis of the penis. J Urol 1993; 149: 848-850.
44. Jayalakshmi P, Goh KL, Soo-Hoo TS, Daud A. Disseminated histoplasmosis presenting as penile ulcer. Aust N Z J Med 1990; 20: 175-176.
45. Curtis AC, Cawley EP. Genital histoplasmosis. J Urol 1947: 57: 781-787.
46. Palmer AE, Amolsch AL, Shaffer LW. Histoplasmosis with mucocutaneous manifestations. Arch Derm Syph 1942; 45: 912-916.
47. Nayak RG, Ramnaryayan K, Rao RV, Shenoy MG. A case of histoplasma posthitis. Trop Geogr Med 1984; 36: 309-311.
48. Mankodi RC, Kanvinde MS, Mohapatra LN. Penile histoplasmosis: a case report. Indian J Med Sci 1970; 24: 354-356.

49. Talvalkar GV. Histoplasmosis simulating carcinoma. A report of three cases. Indian J Cancer 1972; 9: 149-153.
50. Sills M, Schwartz A, Weg JG. Conjugal histoplasmosis: a consequence of progressive dissemination in the index case after steroid therapy. Ann Intern Med 1973; 79: 221-224.
51. Gass M, Kobayashi GS. Histoplasmosis. An illustrative case with unusual vaginal and joint involvement. Arch Dermatol 1969; 100: 724-727.
52. Smith MB, Schnadig VJ, Zaharopoulos P, Van Hook C. Disseminated *Histoplasma capsulatum* infection presenting as genital ulcerations. Obstet Gynecol 1997; 89: 842-824.
53. Conrad FG, Saslaw S, Atwell RJ. The protean manifestations of histoplasmosis as illustrated in twenty-three cases. Arch Intern Med 1959; 104: 692-709.
54. Friskel E, Klotz SA, Bartholomew W, Dixon A. Two unusual presentations of urogenital histoplasmosis and a review of the literature. Clin Infect Dis 2000; 31: 189-191.
55. Mukunyadzi P, Johnson M, Wyble JG, Scott M. Diagnosis of histoplasmosis in urine cytology: reactive urothelial changes, a diagnostic pitfall. Case report and literature review of urinary tract infections. Diagn Cytopathol 2002; 26: 243-246.
56. Isotalo PA, McCarthy AE, Eidus L. Ovarian histoplasmosis in systemic lupus erythematosus. Pathology 2000; 32: 139-141.
57. Limaye AP, Connolly PA, Sagar M, Fritsche TR, Cookson BT, Wheat LJ, Stamm WE. Transmission of *Histoplasma capsulatum* by organ transplantation. N Engl J Med 2000; 343: 1163-1166.
58. Wheat LJ. Laboratory diagnosis of histoplasmosis: update 2000. Semin Respir Infect 2001; 16: 131-140.
59. Wheat LJ, Connolly-Stringfield P, Blair R, Connolly K, Garringer T, Katz BP, Gupta M. Effect of successful treatment with amphotericin B on *Histoplasma capsulatum* variety *capsulatum* polysaccharide antigen levels in patients with AIDS and histoplasmosis. Am J Med 1992; 92: 153-160.

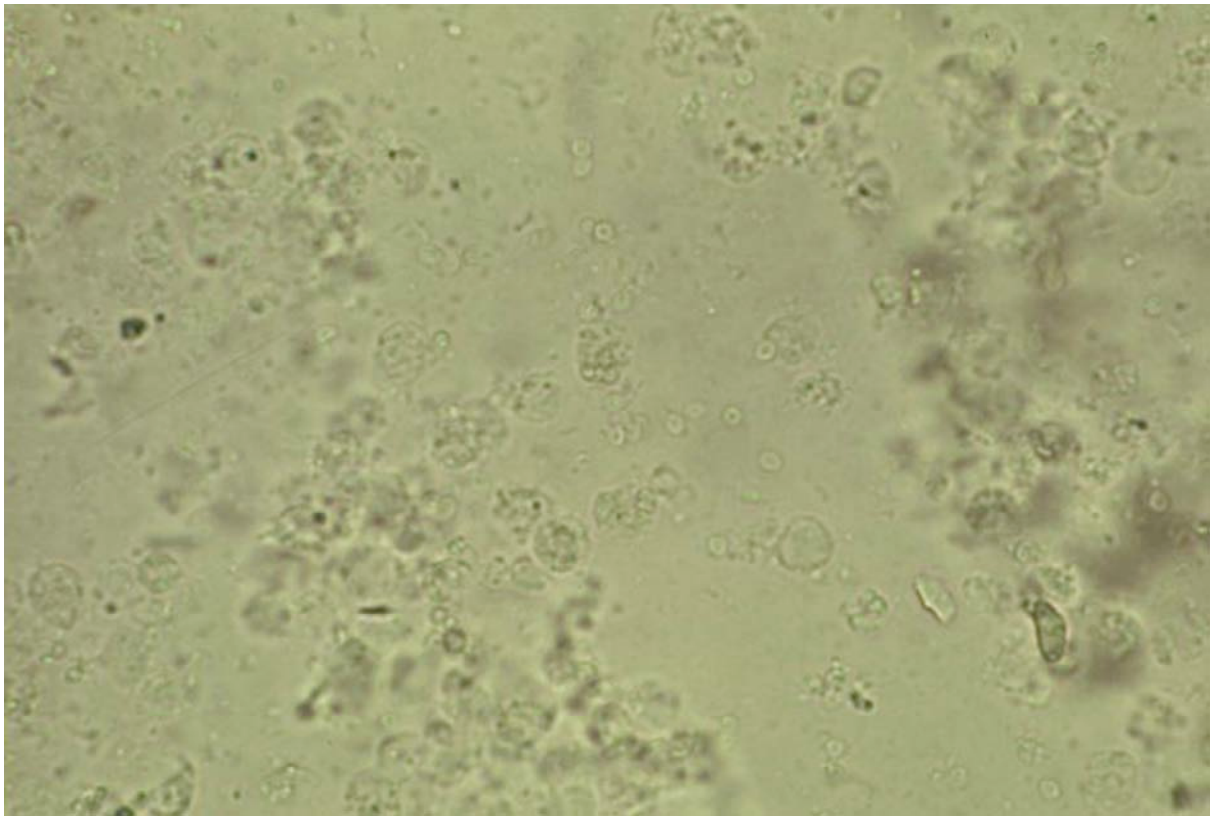

Figure 1. Direct microscopy of the urinary sediment showing yeast cells (400x).

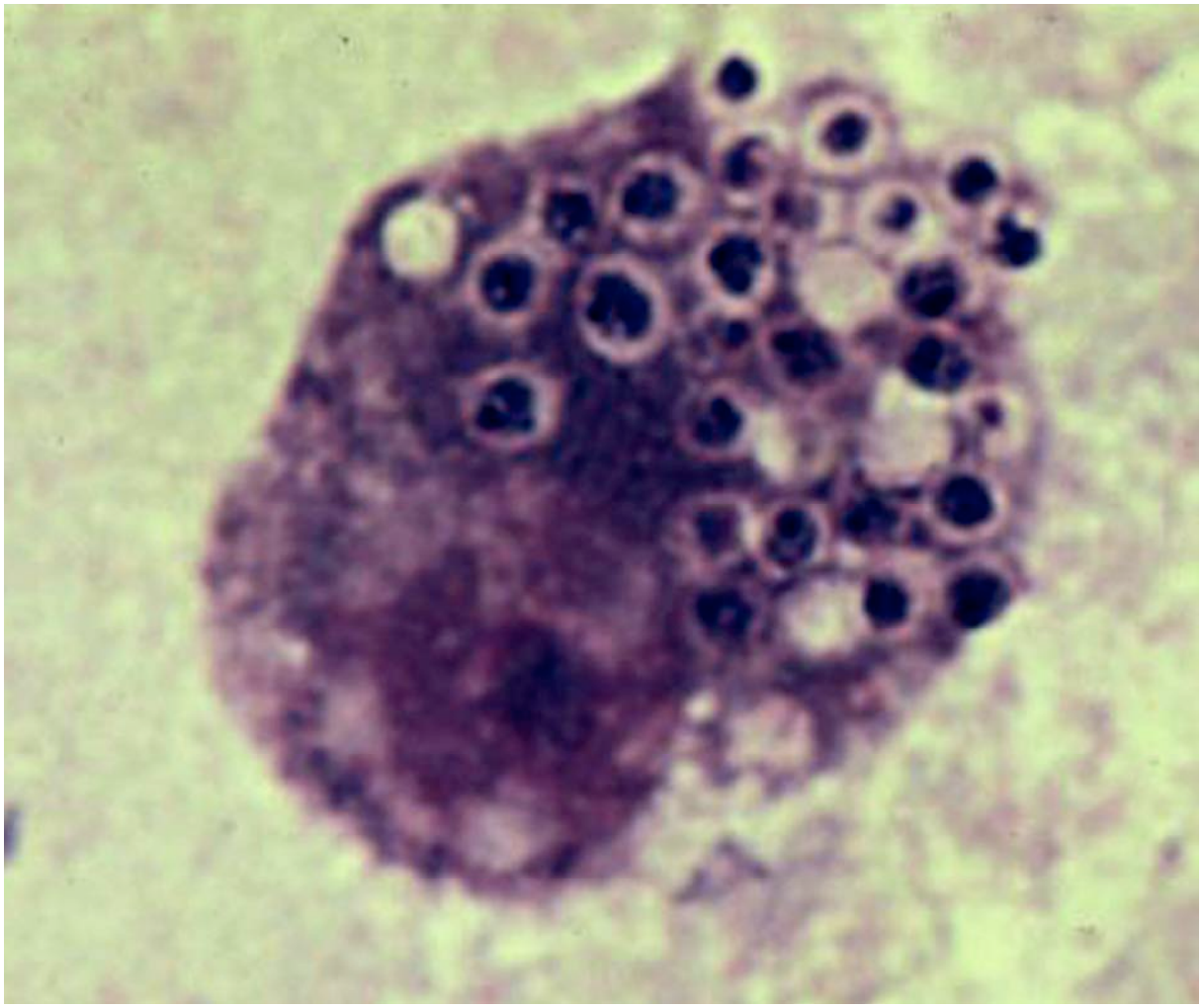

Figure 2. *Histoplasma capsulatum* in urine smear (modified Giemsa stain) (400x).

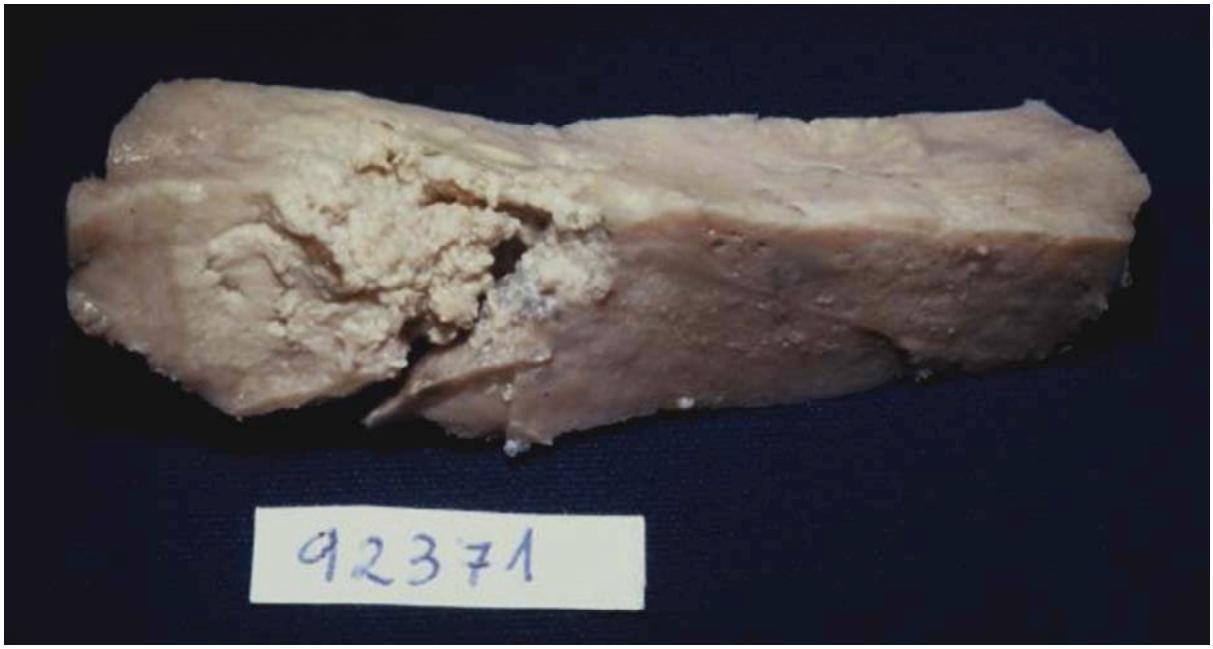

Figure 3. Gross aspect of the removed transplanted kidney revealing an abscess containing *Histoplasma capsulatum*.

Table 1. Summary of previous published cases of genitourinary histoplasmosis.

Author and reference	No. of cases	Underlying diseases	Urinary culture	Clinicopathological findings (related to genitourinary system)	Serology
This report	1	Renal Tx	(+)	Renal failure (single kidney cystic lesion)	(+)
Watanabe [6]	1	Renal Tx	NA	Disseminated infection involving the transplanted kidney	NA
Sridhar [7]	1	Renal Tx	(+)	Renal failure (renal biopsy: poorly developed granulomas with extensive central caseous necrosis)	NA
Delfino [8]	2	Renal Tx	(-) (n=1); NA (n=1)	Loss of renal cadaveric allograft function (removed kidneys in both patients showing various granulomatous lesions)	(-) (n=1); NA (n=1)
Davies [9]	1	Renal Tx	NA	Organ rejection (? contaminated graft)	NA
Superdock [10]	1	Renal Tx	NA	Urinary tract obstruction secondary to sloughed renal papilla infested with *H. capsulatum*	NA
Wong [11]	1	Renal Tx	(-)	Funguria (culture negative), acute rejection (?contaminated graft)	NA
Hood [12]	1	Renal Tx	NA	Renal failure, graft loss (massive necrosis, haemorrhage) (?contaminated graft)	NA
Unis [13]	4	2 AIDS patients	NA	NA	NA
Unis [14]	1	AIDS	(+)	NA	(+)
Ahuja [15]	1	AIDS	NA	Acute renal failure (granulomatous interstitial nephritis)	NA
Ludmerer [16]	1	AIDS	(-)	Glomerulonephritis	(-)
Burke [17]	1	AIDS	(-)	Glomerulonephritis	(-)
Smith [18]	10	AML (n=1), Hodgkin's disease (n=1), CML (n=1)	(+)	Azotemia in 6 (60%) patients	(+) 60% of cases
Kauffman [19]	12	ALL, CLL, and Hodgkin's disease	(+) (n=1)	NA	NA
Vanke [20]	3	(a) Chronic glomerulonephritis, (b) osteogenic sarcoma; and (c) immunocompentent patient	NA	(a): renal failure (several round foci of infection in both kidneys); (b): autopsy showing a solitary lesion in the cortex of the right kidney; (c) autopsy showing multiple renal foci of histiocytes containing *H. capsulatum*	(+) (a); NA (b, c)
Walker [21]	1	Previous splenectomy	NA	Hypercalcemia and azotemia (interstitial nephritis and papillary necrosis)	(+)
Wheat [22]	1	Urban outbreak involving non-transplant patients	NA	Interstitial nephritis with *H. capsulatum* identified in a renal hilar lymph node (no organisms were seen within the kidney)	NA
Reddy [23]	7	Mostly therapy with steroids	(+) (n=6)	Bilateral renal involvement in 1 patient submitted to necropsy (small cortical lesions). One patient had vesical and prostatic involvement	(+) (n=4)
Kedar [24]	1	Immunocompetent patient	NA	Intermittent purulent discharge from the right flank (pyelocutaneous fistula with extensive kidney damage; recurrent stones formation)	NA
Bullock [25]	1	Immunocompetent patient	NA	Mild renal dysfunction (transient glomerulonephritis associated with circulating immune complexes)	(+)
Papo [26]	1	Immunocompetent patient	NA	Focal glomerulonephritis mimicking Wagener's granulomatosis	NA
Binford [27]	3	Autopsy series	NA	Necrotizing lesions of renal medulla which extended to papillae in 13.6% of patients	NA
Salfelder [4]	7	Autopsy series	NA	Kidney lesions in 7 out of 15 patients examined (47%); involvement of testis (n=1)	NA
Goodwin [2]	20	Autopsy series	NA	Renal function not compromised Minor pathological abnormalities (larger focal lesions in _); kidney=15, ovary=1, testis=1, bladder=3	(+) (in ~2/3)
Parsons [3]	12	Autopsy series	(-)	Kidney lesions (n=11), prostate (n=1)	NA
Bersack [28]	1	Inflammatory pseudopolyposis	NA	Rectal urgency and dysuria (autopsy revealed widespread histoplasmosis involving kidneys, ureters, prostate, and seminal vesicles)	(+)
Shah [29]	1	AIDS	NA	Pelvic pain (prostatic abscess)	NA
Zighelboim [30]	1	AIDS	(-)	Urinary urgency, hematuria, decreased flow rate, retrograde ejaculation (prostatic abscess)	NA
Marans [31]	1	AIDS	(-)	Urinary frequency, urgency, dysuria; perineal ache (prostatic abscess)	NA
Orr [32]	2	Immunocompetent patient (n=1); NA (n=1)	NA	Dysuria, lower urinary obstruction (prostate involvement); kidney affected in one patient (no details)	NA
Miller [33]	1	Immunocompetent patient	NA	No symptoms (autopsy: prostatic involvement by *Histoplasma duboisii*)	NA
Mawhorter [34]	1	Immunocompetent patient	(+)	Microscopic haematuria and post-renal azotemia (prostatitis)	(+)
Reddy [35]	1	Immunocompetent patient	NA	Lower abdominal pain, dysuria, hematuria (autopsy revealed bladder and prostate involvement)	NA
Rubin [36]	2	Autopsy series	NA	Prostatic involvement (n=1), testis (n=1)	NA
Aach [37]	1	CLL	(-)	Tender and swollen testis (epididymo-orchitis)	NA
Schuster [38]	1	Immunocompetent patient	NA	Solid testicular mass	(+)
Boone [39]	1	Immunocompetent patient	(+)	Pain in the right lower abdomen and testes (epididymitis)	(-)
Kauffman [40]	2	Immunocompetent patients	(-)	Epididymal mass (epididymal abscess, epididymitis)	(+)
Monroe [41]	1	Immunocompetent patient	NA	Tender and swollen testis	NA
Randhawa [42]	1	Immunocompetent patient	(-)	Lump in the left scrotum (epididymitis)	(-)
Preminger [43]	1	Type II diabetes mellitus	NA	Penile ulcer	NA
Jayalakshmi [44]	1	Cachexia	NA	Two circular non-tender penile ulcers with indurated margins (1 on the glans penis and other on the prepuce, measuring 3 and 2 cm, respectively).	NA

Curtis[45]	2	Immunocompetent patients	NA	Penile ulcers (2 slightly indurated round shallow ulcers over	NA
Palmer [46]	1	Immunocompetent patient	NA	Extensive ulcerations on the prepuce and glans penis (bilateral pyelonephritis at autopsy)	NA
Nayak [47]	1	Ill-nourished, anaemic patient	NA	Phimosis resulting from *Histoplasma* posthitis	NA
Mankodi [48]	1	Immunocompetent patient	NA	2 cm non-painful warty nodule on the glans penis	NA
Talvalkar [49]	1	Immunocompetent patient	NA	Single ulcerative lesion on the under surface of the penis (epididymis was also palpable and tender)	NA
Sills [50]	2	Immunocompetent patient (1 patient on steroids)	(-)	Penile lesion after taking steroids. Wife acquired vulvar lesion (?venereal transmission)	NA (n=1); (-) (n=1)
Gass [51]	1	Immunocompetent patient (positive latex agglutination for rheumatoid arthritis)	NA	Vaginal ulcerations (painless, non-purulent, bloody vaginal discharge)	(-)
Smith [52]	1	Type II diabetes mellitus	NA	Vaginal ulcerations (dysuria, vaginal pain and bleeding)	NA
Conrad [53]	1	Immunocompetent patient	NA	Autopsy revealed ulcerations on the labia majora in a patient who died due to disseminated histoplasmosis	(+)
Friskel [54]	2	Immunocompetent patient (n=1), rheumatoid arthritis on steroids (n=1)	(-) (n=1); NA (n=1)	Gross hematuria (chronic cystitis); necrotic penile lesion	NA
Mukunyadzi [55]	1	Immunocompetent patient	NA	Gross hematuria (cystitis with atypical reactive urothelial changes)	NA
Isotalo [56]	1	Systemic lupus erythematosus	NA	Pelvic abscess, anovulatory cycles, irregular menses (multiple necrotizing granulomas of the ovary)	NA

Legend. (+), positive; (-), negative; NA, not available; Tx, transplantation; SC, subcutaneous; AIDS, acquired immunodeficiency syndrome; AML, acute myeloid leukaemia; CML, chronic myeloid leukaemia; ALL, acute lymphocytic leukaemia; CLL, chronic lymphocytic leukaemia.

8 REFERÊNCIAS BIBLIOGRÁFICAS

Alexander BD. Diagnosis of fungal infection: new technologies for the mycology laboratory. **Transpl Infect Dis, 4**: 32-7, 2002.

Bille J, Edson RS, Roberts GD. Clinical evaluation of the lysis-centrifugation blood culture system for the detection of fungemia and comparison with a conventional biphasic broth blood culture system. **J Clin Microbiol, 19**:126-8, 1984.

Corti ME, Cendoya CA, Soto I, Esquivel P, Trione N, Villafane MF, Corbera KM, Helou S, Negroni R. Disseminated histoplasmosis and Aids: clinical aspects and diagnostic methods for early detection. **AIDS patient Care STDS, 14**: 149-54, 2000.

Creger RJ, Weeman KE, Jacobs MR, Morrissey A, Parker P, Fox RM, Lazarus HM. Lack of utility of the lysis-centrifugation blood culture method for detection of fungemia in immunocompromised cancer patients. **J Clin Microbiol, 36**:290-3, 1998.

Kellogg JA, Manzella JP, McConville JH. Clinical laboratory comparison of the 10-ml isolator blood culture system with BACTEC radiometric blood culture media. **J Clin Microbiol, 20**:618-23, 1984.

Kiehn TE. Bacteremia and fungemia in the immunocompromised patient. **Eur J Clin Microbiol Infect Dis, 8**:832-7, 1989.

Kiehn TE, Wong B, Edwards FF, Armstrong D. Comparative recovery of bacteria and yeasts from lysis-centrifugation and a conventional blood culture system. **J Clin Microbiol, 18**:300-4, 1983.

Kwon-Chung KJ, Polacheck I & Bennett JE. Improved diagnostic medium for separation of *Cryptococcus neoformasn* var. *neoformans* (serotype A and B) and *Cryptococcus neoformans* var. *gattii* (serotypes B and C). **J Clin Microbiol, 15**: 1982.

Lyon R, Woods G. Comparison of the BacT/Alert and Isolator blood culture systems for recovery of fungi. **Am J Clin Pathol, 103**:660-2, 1995.

Morrell RM Jr, Wasilauskas BL, Steffee CH. Performance of fungal blood cultures by using the Isolator collection system: is it cost-effective? **J Clin Microbiol, 34**:3040-3, 1996.

Murray PR. Comparison of the lysis-centrifugation and agitated biphasic blood culture systems for detection of fungemia. **J Clin Microbiol, 29**:96-8, 1991.

Rosas RC, Salomão R, da Matta DA, Lopes HV, Pignatari AC, Colombo AL. Bloodstream infections in late-stage acquired immunodeficiency syndrome patients evaluated by a lysis centrifugation system. **Mem Inst Oswaldo Cruz, 98**:529-32, 2003.

Tarrand JJ, Guillot C, Wenglar M, Jackson J, Lajeunesse JD, Rolston KV. Clinical comparison of the resin-containing BACTEC 26 Plus and the Isolator 10 blood culturing systems. **J Clin Microbiol, 29**:2245-9, 1991.

Thomson RB Jr, Vanzo SJ, Henry NK, Guenther KL, Washington JA II. Contamination of cultures processed with the isolator lysis-centrifugation blood culture tube. **J Clin Microbiol, 19**:97-9, 1984.

Wheat LJ, Bartlett M. Histoplasma capsulatum fungemia documented using the DuPont Isolator System. **Diagn Microbiol Infect Dis, 2**:51-3, 1984.