

# Histological Features of Initial Secondary Caries Adjacent to Composite Resin Restorations

Características Histológicas da Lesão Inicial da Cárie Secundária Adjacente a Restaurações de Resina Composta

Berenice Barbachan e Silva<sup>1</sup>, Débora Heller<sup>2</sup>, Marisa Maltz<sup>1</sup>

## Abstract

The aim was to analyze morphologically the initiation of secondary caries lesion. 33 proximal surfaces adjacent to Class II resin restorations were examined by stereomicroscope (x40) for the presence of caries and gap. 60 sites (39 sound, 7 with lesions, 14 adjacent to lesions) were prepared for examination using polarized light microscopy. Lesions were observed in 52.7% of the wet sections and 85.0% of the dried sections. Dried ground sections displayed larger lesions. Further analyses were performed on dried sections. 100% of ground sections from the stereomicroscope carious sites, 87.2% from sound sites, and 71.4% from sites adjacent to lesions displayed demineralized areas. Morphological analysis indicated that caries lesion initiates at the external enamel surface in the interface between tooth and restoration. Two distinct patterns of caries development were observed, related to the direction of enamel rods: (1) the direction of the rods in the adjacent enamel was parallel to the cavity wall (the deepest part of caries penetration was located at the cavity wall), and (2) the direction of the rods ran in the apical direction (the deepest part of caries penetration was oblique to the cavity wall). The pattern 1 could be mistaken for a wall lesion. The prevalence of lesions adjacent to restorations was similar in the sites with (85.7%) and without (84.0%) gaps. The findings support the assumption that secondary caries initiation *in vivo* is not related to the presence of a gap and follows the direction of the enamel rods.

**Key-words:** dental caries, secondary caries, diagnosis, histopathology

## Resumo

O objetivo deste estudo foi analisar morfologicamente o início da lesão de cárie secundária. Trinta e três superfícies proximais adjacentes a restaurações de resina classe II foram examinadas ao estereomicroscópio (40x) para a presença de carie e gap. Sessenta sítios (39 sadios, 7 com lesões, 14 adjacentes a lesões) foram preparados para exame utilizando microscopia de luz polarizada. As lesões foram observadas em 52,7% dos corte úmidos e 85,0% dos cortes secos. Os cortes secos demonstraram lesões maiores. Análises posteriores foram realizadas nos cortes secos. Cem por cento das secções observadas no estereomicroscópio, 87,2% das lesões hígidas, e 71,4% dos sítios adjacentes a lesões demonstraram áreas desmineralizadas. A análise morfológica indicou que a lesão cariiosa inicia na superfície de esmalte externa na interface entre dente e restauração. Dois padrões distintos de desenvolvimento de carie foram observados, relacionados à direção dos prismas de esmalte: (1) a direção dos prismas no esmalte adjacente foi paralela à parede da cavidade (a parte mais profunda da penetração da cárie foi localizada na parede da cavidade), e (2) a direção dos prismas corria na direção apical (a parte mais profunda da penetração da cárie foi oblíqua à parede da cavidade). O padrão 1 pode ser confundido por uma parede da lesão. A prevalência de lesões adjacentes às restaurações foi similar em sítios com (85,7%) e sem (84,0%) gaps. Os achados suportam o pressuposto de que o início da lesão de cárie secundária *in vivo* não está relacionado à presença de um gap e segue a direção dos prismas de esmalte.

**Palavras-chave:** cárie dentária, cárie secundária, diagnóstico, histopatologia

<sup>1</sup> Professor of Department of Social and Preventive Dentistry, Faculty of Dentistry, Federal University of Rio Grande do Sul, Porto Alegre, Brazil

<sup>2</sup> Graduate student of Faculty of Dentistry, Federal University of Rio Grande do Sul, Porto Alegre, Brazil

**Correspondência:** Berenice Barbachan e Silva

**Endereço:** Faculty of Dentistry – UFRGS – Department of Social and Preventive Dentistry – Rua Ramiro Barcelos, 2492 – CEP 90035-003, Porto Alegre – RS, Brazil

**Fone:** (51) 3316-5189

**E-mail:** tchus@portoweb.com.br

Data de Submissão: 11/07/2011

Data de Aceite: 06/03/2012

## Introduction

A dental surgeon spends most of his daily practice replacing restorations (FORSS; WIDSTROM, 2004; THOMAS et al., 2007, MO et al., 2010). Usually this is an effort to prevent or treat secondary caries. The place where the demineralization process starts is critical. *In vitro* studies suggest that internal lesions may occur at the tooth-restoration junction, beneath sound enamel (HALS; NERNAES, 1971; DERAND et al., 1991). Yet *in vivo* study does not confirm this finding (ÖZER, 1997). The fact that an internal lesion may occur without an external lesion reduces confidence in this diagnosis, which is based on external evidence that the lesion is present rather than on actual fact itself. Indicators of disease may be degradation, ditching, and staining along the margins of the restoration. Special attention is paid to looking for such spaces, where microleakage of bacterial biofilm may occur, leading to a lesion at the tooth-restoration interface. Studies have shown the absence of any relation between this external evidence and the presence of secondary caries (KIDD et al., 1995; KIDD; BEIGHTON, 1996; FONTANA; GONZÁLEZ-CABEZAS, 2000; HANNIG et al., 2009; KIDD, 2001; MAGALHÃES et al., 2009). For these reasons, a number of authors have suggested that the criteria underpinning replacement of restorations owing to the presence of secondary caries are quite subjective and inefficient (OLEINSKY, 1996; HAMILTON, 1983).

The most common location of secondary caries is the cervical margin of any kind of restoration, since this is where microbial accumulation usually occurs (MJÖR, 1998; DEMARCO et al., 2001). In the case of composite resin restoration, the cervical region of class II preparations presents a special problem when it comes to sealing, since this may prompt even greater microbial accumulation. The margin of this cavity can consist of very thin enamel leading to variations in the quality of adherence. When the composite resin contracts during polymerization, this defective adherence may break, prompting marginal defects and subsequent microleakage; this may account for the greater prevalence of secondary caries in this region (DEMARCO et al., 2001; KID et al., 1992; MANHART et al., 2001; BEZNOS, 2001).

The replacements of restorations based on the possible existence of an internal lesion at the tooth-restoration interface have

been used to justify by only few studies on morphological features of secondary caries (HALS; NERNAES, 1971; DERAND et al., 1991). Investigation of this issue is essential to guiding the replacement of restorations. The present study undertook a histological analysis of initial *in vivo* secondary caries adjacent to the cervical region of class II composite resin restorations.

## Materials and Methods

This study was approved by the Odontology Faculty (UFRGS) Ethics and Research Committee (56/02).

The sample comprised 33 proximal surfaces of class II composite resin restorations of extracted human permanent teeth (11 with adjacent secondary caries and 22 with adjacent sound surface). The sound areas were chosen in order to detect any microscopic demineralization in enamel not clinically detectable.

The teeth were selected from places where Oral Health Services are provided in the city of Porto Alegre, from Human Teeth Banks at the University of São Paulo (São Paulo state), and from the Federal University of Pelotas (Rio Grande do Sul state). No teeth displaying a fracture or cavitation adjacent to the restoration were included. Likewise excluded were proximal boxes that extended into buccal or lingual surfaces.

All organic surface material was removed from the tooth surface. For the cleaning procedure, teeth were cleaned with a toothbrush with a 5% sodium hypochlorite (NaOCl) solution for 5 min and rinsed in distilled water for 1 minute. In order to sterilize the teeth, they were stored in a 2% formol solution at pH 7 for thirty days (WHITE, 1987).

After the cleaning procedure the tooth was dried to followed exams with air compression for about 5 seconds. The caries diagnoses were performed using a stereomicroscope at a magnification of 40X (Zeiss, SV 8, Germany). The proximal surfaces were photographed using a digital camera (Nikon D100, Nikon, Japan). The presence of a tooth-restoration gap was then ascertained. The gaps were measured with the help of Adobe Photoshop 6.0. The location was confirmed with the help of a stereomicroscope and the measurement was performed using software tools. Measurements were taken three times with a one-hour interval over three days. Differences greater than 25  $\mu\text{m}$  were not allowed between measurements. The largest measurement was used in the analyses.

To obtain sections for analysis, the teeth were first sectioned, separating the crowns from the roots, using diamond disks with the motor on low speed. The teeth were attached to an acrylic plate using utility wax (Kerr® - Brazil). In order to separate the mesial and distal portions of the crown, a cut was then made in the bucco-lingual direction. Sections were next taken in a mesio-distal direction, matching the area of the proximal box. Sections were made using a diamond disc (Buehler®, number 11-4243, Lake Bluff, IL, USA), coupled to a 150 rpm low-speed saw (ISOMET TM Low Speed Saw, Buehler®, Lake Bluff, IL, USA), while irrigating constantly with distilled water. The sections were hand-ground (600, 1000, and 1200 grade, alumina-water slurry) to a thickness of about 80 to 100  $\mu\text{m}$ . Section thickness was measured with the aid of a digital pachimeter (Digimess® - China). Sections were cool-stored at 100% relative humidity. The number of the slices obtained from each tooth was variable according to the width of the restoration. Only slices that displayed the enamel surfaces were further analyzed using the Differential Interference Contrast (DIC) method. Sixty sites of the cervical region of the proximal surface at the interface tooth/restoration were analyzed: 39 sound sites, 14 sites tangential to caries lesions that clinically presented aspects of shiny and health enamel (BJORNDALE; THYLSTRUP, 1995), and 7 sites inside the caries lesion (Fig 1) represented by whitish spots or opaque enamel.

The DIC method is a microscope polarization of light method modified with addition of two prisms, one in the focal plan of the condenser and another at the focal plan of the objective. The combination of these two prisms is the key of interferential contrast to form clear images in great numerical openings. The images produced for the microscopy of interferential contrast present an appearance of distinct standards of shade, what frequently it confers to the specimen a three-dimensional appearance (DANZ; GRETSCHER, 2004). Sections were photographed using a Nikon CoolPix 990 (Nikon, Japan) coupled to the microscope. Observations were made on humid and dry specimens.

It was used the Mann-Whitney Test to analyze the difference about the lesion presence in the sites with and without gaps.

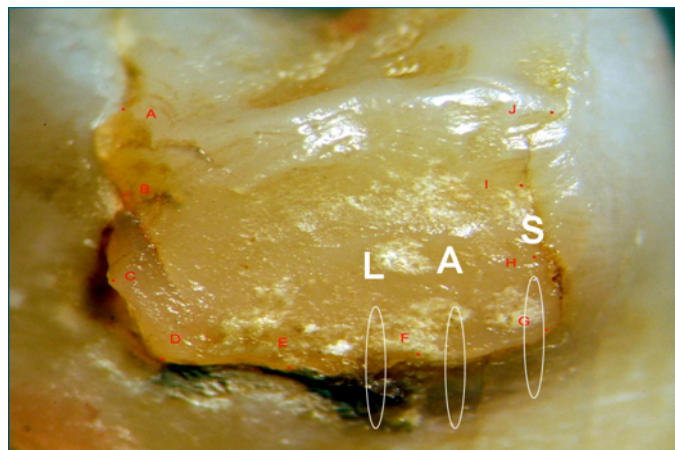


Figure 1. Example of analyzed sites of the cervical area of one proximal surface (L: site in the middle of the lesion, A: site adjacent to lesions and S: site outside the lesion - sound surface).

## Results

Dried sections presented more and larger lesions than humid sections (Fig 2). Of the 60 sites under study, 31 (52.67%) displayed positive birefringence (demineralized enamel) when the sections were humid and 51 (85%) when the sections had been dried. Further analyses were performed in the dried sections.

The Table 1 shows the distribution of gap sizes in the observed site locations in relation to the positive (caries lesions) and negative birefringence. At 41.67% of the observed sites, there was no gap. The percentage of zones displaying positive birefringence was similar whether in the presence (85.7%) or absence (84%) of a gap ( $p=0.192$ ). Histopathological analysis showed higher prevalence of lesions than stereomicroscope analyses. Of the 39 sites judged as sound during macroscopic analysis, 34 (87.18%) displayed positive birefringence (demineralized area). Of the 14 sites tangential to secondary caries, 10 (71.43%) displayed positive birefringence. Of the 7 sites obtained from caries lesions, all displayed positive birefringence. Histopathological analysis of the sections displaying positive birefringence showed that 50 slices out of 51 showed lesions adjacent to restorations beginning on outer surface of the enamel. The deepest part of the lesions were always related to the external part of the tooth/restoration interface and related with the enamel rods direction (Figs. 3a, 3b e 3c). The slice that showed a wall lesion independent of the external lesion (Fig. 3d) was in a site with a gap of 1361.08  $\mu\text{m}$  (Table 1).




Figure 2. Sections imbibed in water (a,c) and after air drying (b,d) examined using DIC: (a, b) - positive birefringence area was observed only after air drying; (c, d) - the lesion area gets larger after air drying. Arrows indicate the tooth/restoration interface.

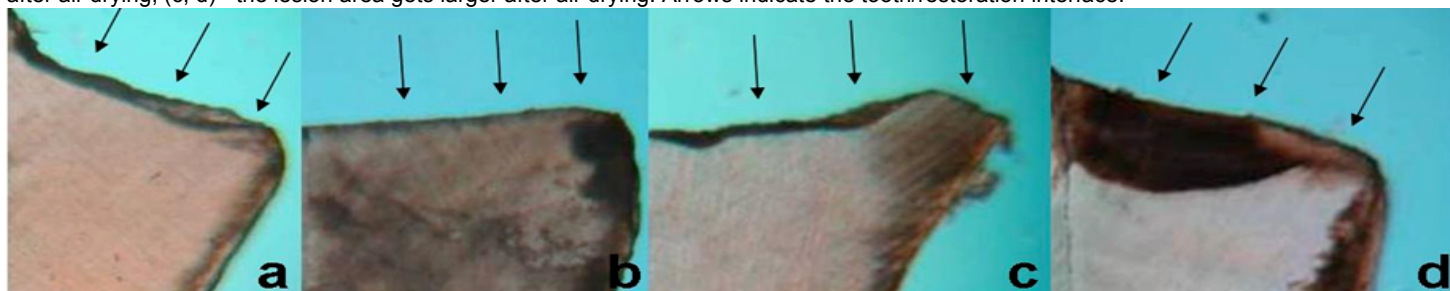


Figure 3. Slices a, b, c and d showed lesions related only to the external part of the tooth (white arrows). The slice d showed an external lesion and an independent wall lesion. Black arrows indicate the tooth/restoration interface.

Table 1. Distribution of observed sites according to gap size in relation to positive\*\* (PB) or negative birefringence (NB).

Gap ( $\mu\text{m}$ )	PB	NB	Total
0	21	4	25
>0<100	9	5	14
$\geq 100 < 200$	11	0	11
$\geq 200 < 1000$	9	0	9
$\geq 1000$	1	0	1
Total	51	9	60

\*\* demineralized tissue

## Discussion

Unlike laboratory studies that provide a limited simulation of the oral environment, analysis of the occurrence of secondary caries in extracted teeth allows us to observe the real process that takes place in an individual. Examination of extracted teeth can be compared to the examination of biopsies (ÖZER, 1997).

In this study, sites were selected with the goal of gathering information on the development of secondary caries. With the help of analyses performed using a stereomicroscope (40X), we therefore chose sound sites, tangential sites, and sites on caries lesions. Sections of these sites were analyzed using polarized light microscopy with the DIC method to detect lesions at the structural level. The sound sites were chosen with the goal of analyzing the possibility of finding incipient lesions and thus ascertaining the initial features of secondary caries. The tangential sites were chosen

because peripheral portions of the lesion displayed areas of surface demineralization, while sites from lesions were selected because they would provide information on caries development (BJORNDAL; THYLSTRUP, 1995).

Even an examination with the aid of a stereomicroscope, which refines a clinical diagnosis, was not able to diagnose the existing lesions at an ultra structural level. Roughly 87% of the 39 sites selected as sound, based on stereoscopic examination, displayed initial caries lesion when examined under greater magnification. The polarized light microscopy with the DIC method performed with the aid of water or air showed that initial lesions were only evident following drying (Fig. 2a, Fig. 2b). Furthermore, drying the specimens increased the visibility of the lesion area (Fig. 2c, Fig. 2d). This shows that drying dental surfaces is indispensable to an accurate clinical diagnosis of the presence and severity of enamel caries (SILVERSTONE, 1973).

This study showed that the caries lesions adjacent to the restorations begin on the outer surface of the enamel. Lesions were found around restorations at the same rate whether or not there was a gap. An image consonant with a wall lesion appearing to develop independent of an external lesion was found in only one section with gap size of >1 mm. This might indicate that larger gaps or isolated marginal failure in conjunction with heavy accumulation of biofilm are responsible for the lesion and hence not a micro leakage (ÖZER, 1997).

Enamel demineralization runs in the direction of the enamel prisms and its deepest part is related to the thicker part of the biofilm (BJORNDAL; THYLSTRUP, 1995). As the thicker part of the biofilm is usually located at the interface between the tooth and restoration the deepest part of the lesion is generally located at this interface. Therefore, caries lesions located around restorations with enamel prisms parallel to the cervical wall of the cavity can be misinterpreted as wall lesions.

## Conclusões

The results of this study allow us to conclude that the lesions at the interface tooth restoration formed *in vivo* begins at the external portion and follows the direction of the enamel prisms. These lesions are, therefore, new lesions located around restorations and have no correlation with the presence or absence of gaps between tooth and restoration.

## References

BEZDOS, C. Microleakage at the cervical margin of composite class II cavities with different restorative techniques. **Oper. Dent.**, Seattle, v. 26, no.1, p. 60-69, Jan./Feb. 2001.

BJORNDAAL, L.; THYLSTRUP, A. A structural analysis of approximal enamel caries lesions and subjacent dentin reactions. **Eur. J. Oral Sci.**, Copenhagen, v. 103, no. 1, p. 25-31, 1995.

DANZ, R.; GRETSCHER, P. C-DIC: a new microscopy method for rational study of phase structures in incident light arrangement. **Thin Solid Films**, Amsterdam, v. 462-463, p. 257- 262, Sept. 2004.

DEMARCO, F.F. et al. Influence of different restorative techniques on micro leakage in Class II cavities with gingival wall in cement. **Oper. Dent.**, Seattle, v. 26, no. 3, p. 253-259, May/June 2001.

DERAND, T.; BIRKHED, D.; EDWARDSSON, S. Secondary caries related to various marginal gaps around amalgam restorations *in vitro*. **Swed. Dent. J.**, Jönköping, Sweden, v.15, no. 3, p. 133-138, 1991.

FONTANA, M.; GONZÁLEZ-CABEZAS, C. Secondary caries and restoration replacement: an unresolved problem. **Compend. Contin. Educ. Dent.**, Jamesburg, N.J., v. 21, no.1, p. 15-18, 21-24,26, Jan. 2000.

FORSS, H.; WIDSTROM, E. Reasons for restorative therapy and the longevity of restoration in adults. **Acta Odontol. Scand.**, London, v. 62, no. 2, p. 82-86, Apr. 2001.

HALS, E.; NERNAES, A. Histopathology of *in vitro* caries developing around silver amalgam fillings. **Caries Res.**, New York, v. 5, no. 1, p. 58-77, 1971.

HAMILTON, J.C. et al. Marginal fracture not a predictor of longevity for two dental amalgam alloys: a ten-year study. **J. Prosthet. Dent.**, St. Louis, v. 50, no. 2, p. 200-202, Aug. 1983.

HANNIG, C. Validity of decision criteria for replacement of fillings. **Schweiz. Monatsschr. Zahnmed.**, Bern, v. 119, no. 4, p.328-338, 2009.

KIDD E. A.M.; TOFFENETTI, F.; MJÖR I. A. Secondary caries. **Int. Dent. J.**, London, v. 42, no. 3, p. 127-138, June 1992.

KIDD, E.A.M.; JOYSTON-BECHAL, S.; BEIGHTON, D. Marginal ditching and staining as a predictor of secondary caries around amalgam restorations: a clinical and microbiological study. **J. Dent. Res.**, Chicago, v. 74, no. 5, p. 1206-1211, Mar. 1995.

KIDD, E.A.M.; BEIGHTON, D. Prediction of secondary caries around tooth-colored restorations: a clinical and microbiological study. **J. Dent. Res.**, Chicago, v. 75, no. 12, p.1942-1946, 1996.

KIDD, E.A.M. Diagnosis of secondary caries. **J. Dent. Educ.**, Washington, v. 65, no. 10, p. 997-1000, Oct. 2001.

MAGALHÃES C. S. et al. Validity of staining and marginal ditching as criteria for diagnosis of secondary caries around occlusal amalgam restorations: an *in vitro* study. **Braz. Dent. J.**, Ribeirão Preto, v. 20, no. 4, p. 307-313, 2009.

MANHART, J. Marginal quality of tooth-colored restorations in class II cavities after artificial aging. **Oper. Dent.**, Seattle, v. 26, no. 4, p. 357-366, July/Aug. 2001.

MJÖR, I.A. The location of clinically diagnosed secondary caries. **Quintessence Int.**, Berlin, v. 29, no. 5, p. 313-317, May 1998.

MO, S.S. et al. The microfloral analysis of secondary caries biofilm around class I and class II composite and amalgam fillings. **BMC Infect. Dis.**, London, v. 10, p. 241, Aug. 2010.

OLEINSKY, J.C. et al. Influence of finishing and polishing procedures on the decision to replace old amalgam restorations: an *in vitro* study. **Quintessence Int**, Berlin, v. 27, no.12, p. 833-840, Dec.1996.

ÖZER, L. **The relation between gap size, microbial accumulation and the structural features of natural caries in extracted teeth with class II amalgam restorations. A stereo - and polarized light microscopic study.** 1997. 98p. PhD Thesis. School of Dentistry - Faculty of Health Sciences- University of Copenhagen Denmark, Copenhagen.

SILVERSTONE, L. M. Structure of carious enamel, including the early lesion. **Oral Sci. Rev.**, Copenhagen, v. 3, no. 2, p. 100-160, 1973.

THOMAS, R. Z. et al. Approximal secondary caries lesion progression, a 20-week *in situ* study. **Caries Res.**, Basel, v. 41, no. 5, p. 399-405, 2007.

WHITE, D.J. Reactivity of fluoride dentifrices with artificial caries I. Effect on early lesions, fluoride uptake, surface hardening and remineralization. **Caries Res.**, Basel, v. 21, no. 2, p. 126-140, 1987.

## Acknowledgements

To CNPq from whom the second author received a scholarship during her undergraduate course in Dentistry at FO-UFRGS. To the Porto Alegre Oral Health Services and to the Human Teeth Banks at the University of São Paulo (São Paulo state), and from the Federal University of Pelotas (Rio Grande do Sul state) for the contribution to this study.