

## Bone tissue microscopic findings related to the use of diode laser (830<sub>nm</sub>) in ovine mandible submitted to distraction osteogenesis<sup>1</sup>

Achados microscópicos no tecido ósseo relacionados à utilização do laser diodo (830<sub>nm</sub>) em mandíbulas de ovelhas submetidas à distração osteogênica

Arlei Cerqueira<sup>2</sup>, Roger Lanes Silveira<sup>3</sup>, Marília Gerhardt de Oliveira<sup>4</sup>, Manoel Sant'ana Filho<sup>5</sup>, Cláiton Heitz<sup>5</sup>

1. Research performed at Oral and Maxillofacial Surgery and Traumatology (OMFST). Pontific Catholic University of Rio Grande do Sul (PUCRS), Brazil.
2. Surgeon-in-Chief, Department of Oral and Maxillofacial Surgery and Traumatology (OMFST), Roberto Santos Hospital. Salvador, Bahia, Brazil
3. Fellow PhD degree, Department of OMFST, Faculty of Dentistry of Porto Alegre, PUCRS, Porto Alegre, Brazil;
4. Assistant Professor, Department of OMFST, Faculty of Dentistry of Porto Alegre, PUCRS. Porto Alegre, Brazil
5. PhD, Associate Professor, Department of OMFST, Faculty of Dentistry of Porto Alegre, PUCRS. Porto Alegre, Brazil

---

### ABSTRACT

**Purpose:** To analyze the microscopic characteristics of the effect of Gallium-Aluminum Arsenid diode laser (GaAlAs - 830nm) applied during the activation and consolidation period to ovine mandibles submitted to distraction osteogenesis.

**Methods:** Eighteen sheep underwent surgery in order to have bone distractors implanted in the left side of the jaw area. They were divided into three groups: 1 – Control; 2 – Laser irradiation during the activation period; 3 – Laser irradiation during the fixation period. The irradiation was carried out in five sessions, on every other day, with 4,0J/cm<sup>2</sup> doses applied to four pre-established areas, totaling 16J per session. After four days of latency under post-operative care, ten days of distractor activation (at 1mm/day) and twenty-one days of fixation the animals were sacrificed and the devices removed for microscopic analysis. **Results:** The groups that received laser irradiation (GaAlAs) presented a greater amount of mineralized bone trabeculae when compared to the Control Group. Despite that, cartilaginous tissues were also found in Group 2.

**Conclusion:** The laser has been more favorable when used in the consolidation period, after bone elongation.

**Key words:** Lasers. Bone lengthening. Wound healing. Sheep.

---

### RESUMO

**Objetivo:** Avaliar as características microscópicas do efeito do laser diodo de Arsenieto de Gálio-Alumínio (AsGaAl - 830nm), aplicado no período de ativação e consolidação de mandíbulas de ovelhas submetidas a distração osteogênica.

**Métodos:** Dezoito ovinos foram submetidos a procedimento cirúrgico para colocação de distrator ósseo em região de mandíbula do lado esquerdo, sendo divididos em três grupos: 1 – Controle; 2 – Irradiação de laser no período de ativação; 3 – Irradiação de laser no período de contenção. As irradiações foram feitas em cinco seções em dias alternados, com doses de 4,0J/cm<sup>2</sup> em quatro pontos pré-determinados, somando 16J por seção. Após quatro dias de latência no pós-operatório, 10 dias de ativação do distrator (1 mm/dia) e 21 dias de contenção os animais foram mortos e as peças removidas para análise microscópica. **Resultados:** Os resultados foram que os grupos irradiados com laser (AsGaAl) apresentaram maior disposição de trabéculas ósseas mineralizadas em relação ao grupo controle, contudo, no Grupo 2 foi observada a presença de tecido cartilaginoso. **Conclusão:** O laser atuou de forma mais favorável quando utilizado no período de consolidação, após o alongamento ósseo.

**Descritores:** Lasers. Alongamento ósseo. Cicatrização de feridas. Ovinos.

---

## Introduction

The first references to distraction osteogenesis date from 1905, by Codvilla, in which he carried out the elongation technique in a patient whose legs were discrepant. However, the results were not satisfactory due to the high incidence of complications. From 1973 on, Snyder et al.<sup>13</sup> applied the bone elongation technique to the craniofacial bones, granting class I occlusion to dogs which had been previously affected by class II occlusion (retrognathism), proving thus the effectiveness of such procedure by means of clinical and radiographic evaluations after the consolidation. In 1989, Ilizarov<sup>6</sup> starts a series of studies of major importance within the scope of distraction osteogenesis, demonstrating that among the success factors that influence the final results are both the firm fixation of the bone after elongation and the greater osteogenic potential when blood and cellular aids are preserved. Whether the treatment could take shorter time, or the possible rate of daily elongation the tissues can bear have been some of the topics approached by recent studies, all aiming at the final results. Microscopic evaluation studies of distractor elongated rabbit mandibles have demonstrated a daily growth of 3mm, with activation twice a day, allowing thus the formation of a greater fiber union when compared to the daily growth of 1mm, with activation twice a day as well<sup>15</sup>. The increase in the elongation rate in ovine mandibles, considering daily activations of 1mm, 2mm, 3mm and 4mm, has shown, microscopically, the absence of cartilaginous tissue in the bone. Despite that, the histological, mechanical results were the best in the 1mm group<sup>1</sup>.

In addition to the distractor activation rate, other resources such as laser have been used as supporting elements in order to make the treatment less time-consuming. Laser (Light Amplification by Stimulated Emission of Radiation) is a source of electromagnetic radiation whose wave length may be visible to the human eye (between 400 and 700 nm). Below 400nm the light is called ultraviolet, and above 700nm, infrared. Furthermore, laser can be classified as surgical, ablative, therapeutic or non-ablative, and the interaction of light with the body may be able to produce effects that, when well managed, can bring benefits such as pain and inflammation reduction, as well as tissue repair stimulus<sup>8</sup>. The use of small doses (around 1 to 4 J/cm<sup>2</sup>) and multiple sessions has produced better effects, as well as greater biomodulation<sup>14</sup>. The use of Gallium-Aluminum Arsenid laser (GaAlAs) has been positive when it is irradiated in the following cases: rats' bone cell cultures (*in vitro*)<sup>4</sup>; in hydroxyapatite grafts in rabbits' femurs, increasing osseointegration<sup>3</sup>; in the first stages of bone repair, speeding up the process, which has been indicated in many experimental papers<sup>7, 11, 12</sup>.

In the present research, the purpose is to evaluate the microscopic characteristics of the GaAlAs laser (830nm) applied to ovine mandibles submitted to distraction osteogenesis, in different treatment stages.

## Methods

The project was first submitted to the assessment of the Ethics and Science Committee of the Dentistry Faculty of Pontificia Universidade Católica do Rio Grande do Sul (PUCRS), who approved its execution. Eighteen two year-old female sheep (young adults) - properly submitted to conventional vaccination practices, derived from the mating of *Corridale* female sheep and *Border Leicester* male sheep - were provided by the Faculty of Veterinary Medicine, Federal University of Rio Grande do Sul for the experiment. The animals were prophylactically treated through anti-helminthic drugs and both parasitological and hematological exams to evaluate the plasmatic amount of electrolytes, which are related to bone metabolism (calcium, phosphorus and alkaline phosphatase). Such measures were taken in order to avoid possible alterations that may interfere in the final results. The animals were randomly divided into three groups, each of which containing six animals and receiving one of the three suggested treatments, as follows: Group 1 (control) - submitted to the osteogenic distractor implant; Group 2 - submitted to the osteogenic distractor implant with laser irradiation during the activation period of the device (bone elongation); Group 3 - submitted to the osteogenic distractor implant with laser irradiation during the bone fixation period (after bone elongation).

### *Surgical procedure*

The animals were admitted to the Veterinary Hospital of Universidade Federal do Rio Grande do Sul (VH-UFRGS), where they stayed in appropriate places until the end of the experiment, divided into groups. Each animal was weighed, as shown in Table 1. Veterinarians administered the anesthetic intramuscularly by using a mixture of 2% Xylazine Chloride (0,3 mg/kg) and 125mg of Zolazepan Chloride with 125mg of Tiletamine Chloride (4,0 mg/Kg - Zoletil). We have established intravenous access in the lateral saphenous vein in order to administer 20 drops per minute of Ringer Sodium Lactate solution, as well as complementary anesthetic doses. The prophylactic administration of 1.200.000 UI of Benzatin Benzilpenicillin was performed intramuscularly. The left cervical area of each animal was submitted to trichotomy and degermination through 0.5% alcoholic iodoform. Then, we established the sterile areas and carried out the subcutaneous infiltration of 4 ml of 1% lidocaine with epinephrine in the proportion of 1:100.000. A linear 4 cm submandibular incision was done, and the parts were dissected up to the bone area, where the extra-oral distractor was parallelly placed by means of four transcutaneous, bicortical pins, each measuring 3 mm of diameter (PROMM). This distractor was specifically designed for this experiment. After that, we performed the mandibular corticotomy in the angle area, allowing the separation of a proximal segment and a distal segment, each containing the pins.

The tissual plans were repositioned by means of internal stitching, and the other components of the extra-oral distractor were arranged, fixed to the transcuteaneous pins, enabling the proximal segment to move in the antero-posterior sense. Finally, the skin was sutured through intradermal stitches.

**TABLE 1** - Animals' initial and final weight and division per group according to the different treatments

	Animal	Inicial Weight (kg)	Final Weight (kg)
<b>Group 1 (Control)</b>	1	34,0	33,6
	2	27,0	27,6
	3	37,0	38,8
	4	38,0	40,6
	5	36,0	40,4
	6*	29,0	-
<b>Group 2</b>	7	35,0	36,0
	8*	33,0	-
	9	38,0	33,5
	10	39,0	29,0
	11	39,0	32,5
<b>Group 3</b>	12	34,0	23,0
	13*	34,0	-
	14	30,0	29,0
	15	37,0	32,0
	16	30,0	27,0
	17	36,5	38,0
	18	31,0	32,0

\*Animals excluded from the experiment

*Post-operative care*

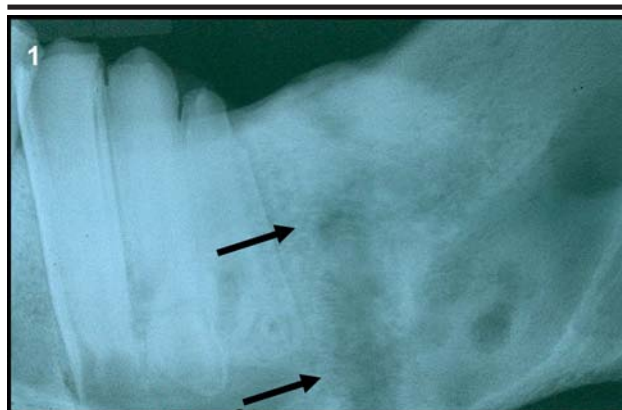
The animals received anti-inflammatory and their surgical wounds were cleansed with 1% alcoholic iodoform for three days and, on the third day, and extra Benzilpenicillin dose was injected. From the fourth day on, we started activating the distractor every twelve hours, at 0.5mm each activation (1mm of elongation per day), during 10 days, totaling 10mm of elongation. After this activation period, the distractor remained in static position for 21 days, during the fixation period. By the end of this 21-day period, the animals were weighed once again (Table 1), submitted to general anesthetic, and sacrificed through a 20 ml intracardiac injection of 10% potassium chloret. The mandibles were dissected, separated in the synphysis area, allowing us to reach the hemimandible submitted to the distraction process. Finally, they were radiographed and catalogued according to the group to each they belonged.

*Laser irradiation*

The experimental groups (i.e. 2 and 3) received irradiation of the Gallium-Aluminum Arsenite laser ( $\lambda=830\eta\text{m}$  and 40nW) on every other day, directly on the bone elongation area, through the skin which underwent trichotomy and degreasing through a gauze soaked with alcoholic solution, not requiring animal sedation or anesthetization. A 4J/cm<sup>2</sup> laser dose was administered per session directly on four areas along the corticotomy, all equidistant from the transcuteaneous pins, totaling 16J/cm<sup>2</sup>. Five sessions were carried out, resulting in a total dose of 80 joules for each sheep of groups 2 and 3. The group 2 animals were submitted to irradiation during the bone elongation period from the first day on, even without the distractor activation having started. The group 3 animals, on the other hand, received irradiation during the fixation period over the elongated bone area.

**Results**

Three animals had to be excluded from the experiment for the following reasons, respectively: breathing disorders due to the anesthetics, loss of part of the bone distractor (it might have gotten stuck on the fence), and myiasis in the distractor area. Since each animal belonged to a different group, we actually had five animals in each group rather than six. The mandibles of the animals belonging to different groups were radiographed and analyzed. The results showed that regardless of the kind of treatment used, the animals presented areas that were less radiodense when compared to the intact, neighboring ones, related to the bone elongation areas. Such finding points towards an immaturity in the process of new bone formation (Figure 1). In order to make the analysis by optical microscopy viable, the mandible area containing new bone formation as well as a margin of pre-existing adjacent bone was separated so as to reduce the dimensions. The obtained parts were placed on 10% formalin for 48 hours, decalcified in 5% nitric acid, embedded in paraffin blocks, and cut up longitudinally in 6 $\mu\text{m}$  thick sections (from vestibular to lingual).

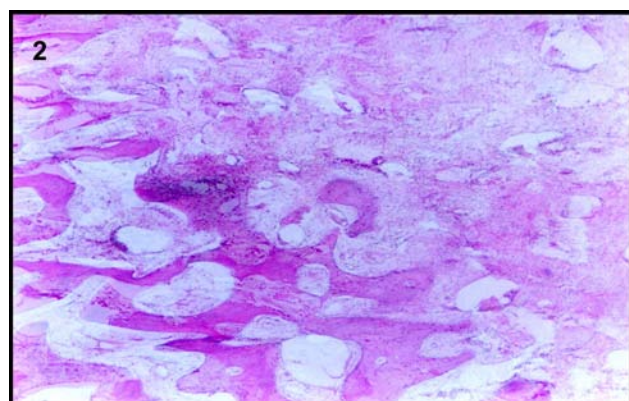


**FIGURE 1** - Region less radiodense correspondent to the bone elongation area (Group 3)

For the microscopic descriptive analysis of each group to take place, slides were prepared by using Hematoxylin and Eosin (HE) dyes.

#### *Group 1 (Control)*

It was possible to observe a margin of pre-existing mature lamellar bone containing calcified matrix, Haversian canals and a few osteocytes. By moving away from the mature bone, less voluminous, elongated trabeculae were found lying longitudinally, in the sense of the distraction. Such trabeculae are characterized by young bones. In the area correspondent to the central elongation zone, we found the presence of fibrous connective tissue containing a variable amount of blood vessels and calcification areas in synthetization (Figure 2).



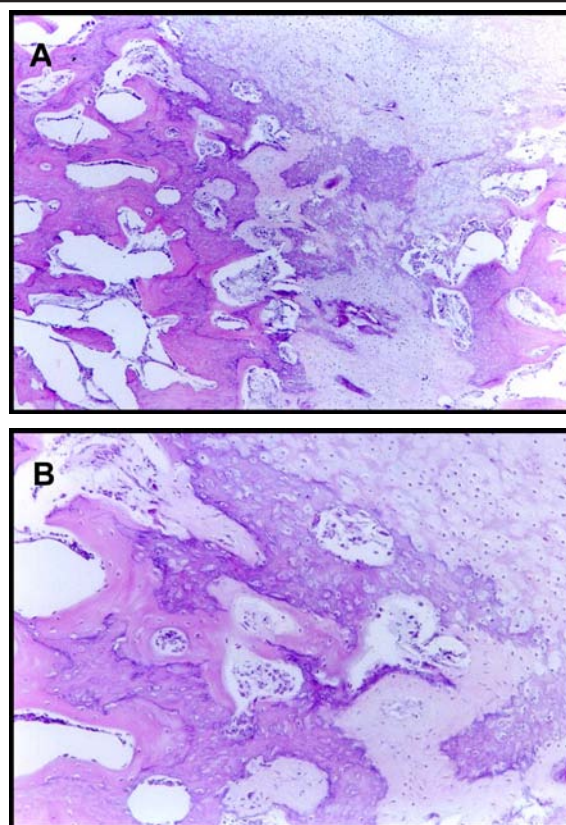
**FIGURE 2** - Optical microscopy of Group 1 – control (increase of 40X)

#### *Group 2 (laser irradiation during the activation period)*

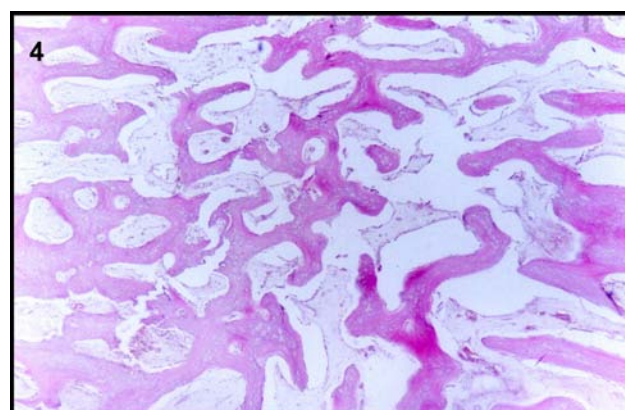
In the areas correspondent to bone elongation we found a great amount of bone trabeculae of immature but voluminous bone, involved in loose connective tissue, highly vascularized and poorly-cellulated, stretching up to the (pre-existing) mature lamellar bone margin. Although we did not find a dense connective tissue stripe in the central area (correspondent to the central elongation zone), large areas of cartilaginous tissue were observed (Figure 3).

#### *Group 3 (laser irradiation during the fixation period)*

We found a great amount of young, stretched bone trabeculae along the distraction area, lying longitudinally in the elongation sense. The fibrous connective tissue stroma, which fills the medullary spaces, was poorly-cellulated and poorly-vascularized, since there was not an intermediary, isolated stripe of fibrous tissue (Figure 4).



**FIGURE 3** - A. Optical microscopy of Group 2 – laser irradiation during the activation period (increase of 40X); B. (increase of 100X)



**FIGURE 4** - Optical microscopy of Group 3 - laser irradiation during the fixation period (increase of 40X)

### **Discussion**

The use of sheep in this experiment was adopted due to their physical structure and resistance, which were key factors for the project to be accomplished. In addition, we know that these animals are successfully used in experiments involving osteogenic distractors<sup>1,16</sup>. Also, the study of the bone metabolism of female animals is mentioned in several different papers<sup>5, 8, 9</sup>, and in order to eliminate any systemic alterations that may interfere in the bone metabolism, we decided to carry out the count

of serum minerals, which was within the standards of normality. The relative weight maintenance of the animals reflects their tolerance to the occlusion derived from the elongation of the left-side jaw angle, a tolerance which had already been pointed out in other studies<sup>1, 8</sup>. The use of elongation activations at 1mm divided into two sessions a day was carried out in a pace considered viable for the tissues, since such step in bone elongation is the object of studies which aim at making the treatment less time-consuming. Furthermore, certain authors consider rates above 1 mm a day inadequate<sup>5, 15</sup>. In Ilizarov's original studies, the more fractioned the daily elongation, the greater the osteogenic potential, although studies in rabbits' jaws have not shown any activation difference in one or more sessions<sup>9</sup>. In the present experiment, we decided to use two daily activations because it was a cautious process, already accomplished in other experimental projects. Therefore, both the elongation rates and the fixation period adopted are considered viable for the biologic model employed<sup>16</sup>. The therapeutic laser irradiation, whose wave length is 830nm, and whose aim is to speed up bone repair in rats is perceived as effective when applied after palatal expansion<sup>11</sup>, in orthodontic molar movement<sup>7</sup>, and in defects in the diaphysis of long bones<sup>12</sup>, resulting in the production of thicker trabeculae and a quicker regeneration. The GaAlAs laser was adopted in this experiment because its wave length goes through the buccal tissues due to its low absorption in water and cutaneous chromophores, acting as a biostimulator in the subjacent bone tissue, where the affinity with such wave length is greater<sup>2</sup>. The main benefits of therapeutic laser seem to derive from the administering of doses, since there have been unfavorable results when the laser is used at higher levels or for extended periods of time<sup>2</sup>. Satisfactory results are obtained when the number of applications ranges from two to twelve low-energy sessions<sup>3, 4, 14, 17</sup>. Many studies have not identified the presence of cartilagenous tissue associated to the use of therapeutic laser<sup>7, 11, 12, 17</sup>, as has been the case of the group in which the laser was used in the activation period. The presence of such tissue is either the cause of an accelerated pace in bone elongation, or a sign of bone distractor instability<sup>10, 15</sup>. However, it is important to bear in mind that in the present experiment the distractor was anchored bicortically by means of four pins, not to mention that the surgical technique was exactly the same in all three groups. Komuro et al.<sup>8</sup>, when working on elongation in rabbit mandibles, mention the existence of cartilagenous tissue after two weeks of fixation. Despite that, this tissue is no longer observed after four weeks. The time span of the experiment, as well as in Meyer's studies<sup>9, 10</sup>, does not contemplate more advanced stages of bone repair, i.e. after six to eight weeks, which would allow the assessment of the evolution of the cartilagenous tissue into bone tissue. The studies in which the fixation period

is longer have demonstrated that by the end of the consolidation period, because of the insignificant bone production, no mechanism is capable of improving the physical properties of a stimulated bone in relation to a natural bone<sup>5, 12</sup>. However, the acceleration in the fibrous callus mineralization through the calcification of bone matrix, by means of biostimulating resources such as laser, has proven to be extremely significant, especially because it has reduced the time span of the treatment. New studies are required in order to assess the behavior of the cartilagenous tissue after a longer consolidation period.

### Conclusions

- The groups that received laser irradiation presented a greater production of mineralized bone trabeculae when compared to the control group;
- The GaAlAs laser (830nm) has been more effective when used in the consolidation period of the distraction osteogenesis process due to the absence of alterations in the ossification pattern;

### References

1. Farhadieh RD, Gianoutsos MP, Dickinson R, Walsh WR. Effect of distraction rate on biomechanical, mineralization, and histological properties of an ovine mandible model. *Plast Reconstr Surg.* 2000; 105(3):889-95.
2. Gordjestani M, Dermaut L, Thierens H. Infrared laser and bone metabolism: a pilot study. *Int J Oral Maxillofac Surg.* 1994; 23:54-6.
3. Guzzardella GA, Torricelli P, Nicoli Aldini N, Giardino R. Laser technology in orthopedics: preliminary study low power laser therapy to improve the bone-biomaterial interface. *Int J Artif Organs.* 2001; 24(12):898-902.
4. Guzzardella GA, Fini M, Torricelli P, Giavaresi G, Giardino R. Laser stimulation on bone defect healing: an in vitro study. *Laser Med Sci.* 2002; 17(3):216-20.
5. Hagiwara T, Bell WH. Effect of electrical stimulation on mandibular distraction osteogenesis. *J Craniomaxillofac Surg.* 2000; 28(1):12-9.
6. Ilizarov GA. The tension-stress effect on the genesis and growth of tissues: Part 1. The influence of stability of fixation and soft tissues preservation. *Clinic Orthop Relat Res.* 1989; 238:249-81.
7. Kawasaki K, Shimizu N. Effects of low-energy laser irradiation on bone remodeling during experimental tooth movement in rats. *Laser Surg Med.* 2000; 26:282-291.
8. Komuro Y, Takato T, Harii K, Yonemara Y. The histological analysis of distraction osteogeneses of the mandible in rabbits. *Plast Reconstr Surg.* 1994; 94:152-9.
9. Meyer U, Wiesmann HP, Kruse-Lösler B, Handschel J, Stratmann U, Joos U. Strain-related bone remodeling in distraction osteogenesis of the mandible. *Plast Reconstr Surg.* 1999; 103(3):800-7.

10. Meyer U, Meyer T, Wiesmann HP, Kruse-Lösler B, Vollmer D, Stratmann U, Joos U. Mechanical tension in distraction osteogenesis regulates chondrocytic differentiation. *Int J Oral Maxillofac Surg.* 2001; 30:522-30.
11. Saito S, Shimizu N. Stimulatory effects of low-power laser irradiation on bone regeneration in midpalatal suture during expansion in the rat. *Am J Orthod Dentofac Orthop.* 1997; 111:525-32.
12. Silva Júnior AN, Pinheiro AL, Oliveira MG, Wiesmann R, Ramalho LM, Nicolau RA. Computerized morphometric assessment of the effect of low-level laser therapy on bone repair: an experimental animal study. *J Clinic Laser Med Surg.* 2002; 20(2):83-7.
13. Snyder CC, Levine GA, Swanson HM, Browne EZ Jr. Mandibular lengthening by gradual distraction: preliminary report. *Plast Reconstr Surg.* 1973; 51:506-8.
14. Sommer AP, Pinheiro AL, Mester AR, Franke RP, Whelan HT. Biostimulatory windows in low-intensity laser activation: lasers, scanners, and NASA's light-emitting diode array system. *J Clinic Laser Med Surg.* 2001; 19(1): 29-33.
15. Stewart KJ, Lvaff GO, White SA, Bonar SF, Walsh WR, Smart RC, Poole MD. Mandibular distraction osteogenesis a comparison of distraction rates in the rabbit model. *J Craniomaxillofac Surg.* 1998; 26:43-9.
16. Tavakoli K, Walsh WR, Bonar F, Smart R, Wulf S, Poole MD. The role of latency in mandibular osteodistraction. *J Craniomaxillofac Surg.* 1998; 26: 209-19.
17. Trelles MA, Mayayo E. Bone fracture consolidates faster with low-power laser. *Laser Med Sci.* 1987; 7(1):36-45.

---

**Correspondence:**

Profa. Dra. Marília Gerhardt  
Av. Ipiranga 6681, prédio 06/209  
90610-001 Porto Alegre - RS Brasil  
Phone/Fax: (55 51)3320-3538

Conflict of interest: none  
Financial source: none

Received: November 23, 2006  
Review: December 18, 2006  
Accepted: January 15, 2007

---

**How to cite this article:**

Cerqueira A, Silveira RL, Oliveira MG, Sant'ana Filho M, Heitz C. Bone tissue microscopic findings related to the use of diode laser (830<sub>nm</sub>) in ovine mandible submitted to distraction osteogenesis. *Acta Cir Bras.* [serial on the Internet] 2007 Mar-Apr;22(2). Available from URL: <http://www.scielo.br/acb>

---

\* Color figures available from [www.scielo.br/acb](http://www.scielo.br/acb)