

Imipenem-associated encephalopathy

Alert to physicians

Alessandro Finkelsztein¹, Lucas Cabral², José Augusto Bragatti¹,
Aline Vitali da Silva³, Arthur Francisco Schumacher Schuh²,

Imipenem, one of the first antibiotics of the carbapenem class, was developed more than 2 decades ago and has been utilized for multi-resistant bacterial infections in more than 26 million patients¹. It also has been a life-saving drug, as some bacteria are frequently resistant to other broad-spectrum antibiotics. Imipenem-related encephalopathy was not formally reported, and can be overlooked by practitioners.

The aim of this report is to alert physicians to this condition.

CASE

A 69-year-old, diabetic and hypertense, Caucasian male who presented to our hospital with behavioral disturbances, forget-

fulness and a constant new-onset headache for the previous 10 days. His physical examination disclosed a right supranuclear facial palsy. A head MRI (Fig 1) was ordered and showed a right frontal mass lesion surrounded by marked edema and signs of subfalcial herniation. A routine screening for systemic cancer was normal. He was taken to neurosurgical treatment and a subtotal resection was achieved; the final pathological diagnosis was glioblastoma. In the post-operative period the patient developed multiple respiratory infections; his general medical condition worsened, and critical care was necessary for about 2 months. After partial recovery, he started on fractionated radiotherapy.

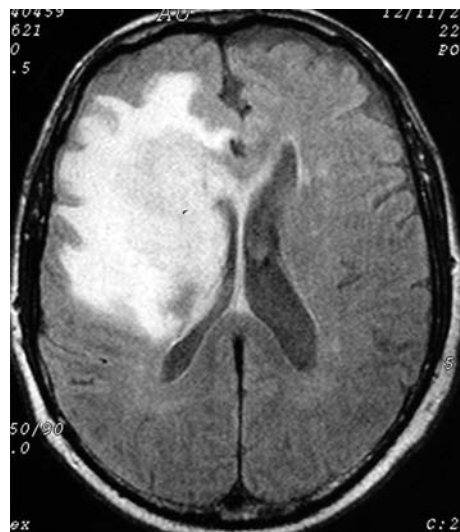

Fig 1. First head MRI disclosed a gadolinium-enhancing right frontal mass lesion adjacent to the frontal horn of right lateral ventricle. Coronal T1 sequence showed a ring lesion involving right caudate nucleus head. This FLAIR sequence shows marked vasogenic edema. Anatomicopathological studies confirmed glioblastoma.

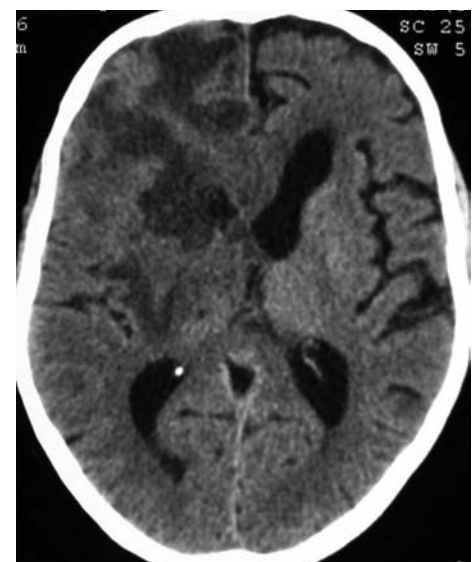

Fig 2. This head CT shows post-operative changes in deep white matter, extensive vasogenic edema, diffuse right sulci effacement, moderate right ventricular lateral compression and mild subfalcial herniation. No obvious new changes were observed.

Correspondence

Alessandro Finkelsztein
Rua Mostardeiro 5 / 1002
90430-001 Porto Alegre RS - Brasil
E-mail: afinkels@portoweb.com.br

Received 13 April 2009
Received in final form 18 April 2009
Accepted 17 September 2009

ENCEFALOPATIA ASSOCIADA A IMPENEM: ALERTA AOS MÉDICOS

Hospital de Clínicas de Porto Alegre, Porto Alegre RS, Brazil: ¹Neurologist, Neurology Unit; ²Physician, Neurology Resident; ³Medical student, Federal University of Rio Grande do Sul.

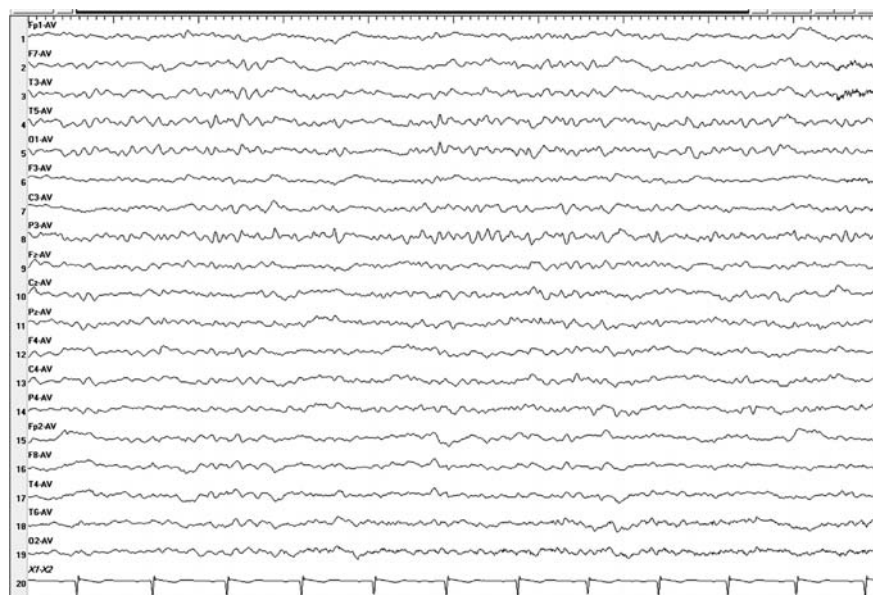


Fig 3. EEG recorded on 4th day on imipenem. Diffuse continuous irregular slow waves with left hemisphere accentuation. Scarce non-periodic left parieto-temporal sharp waves are observed.

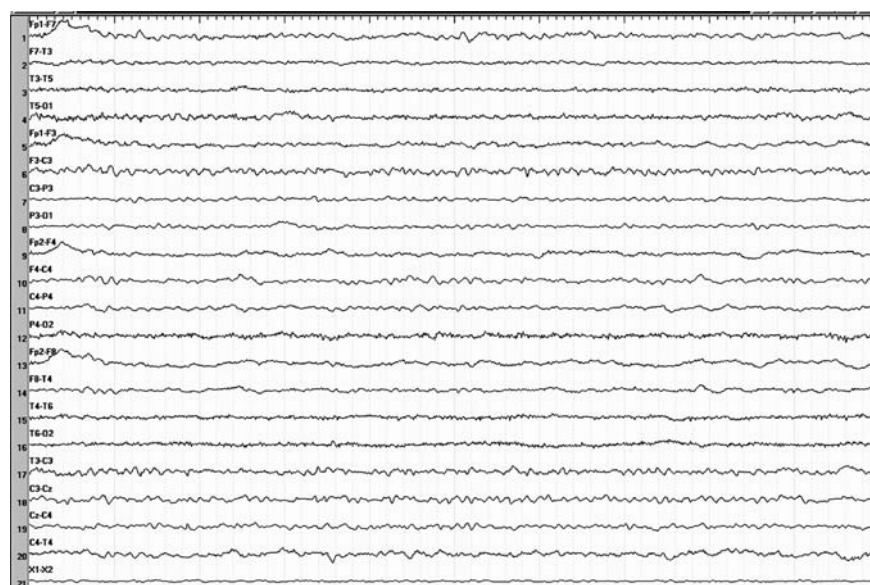


Fig 4. EEG recorded 72h after imipenem withdrawal. Improved background rhythms are seen. Some degree of somnolence is noted by the frontal theta activity recorded.

At that moment, he showed paroxysmal clonic jerks on his right hemiface, and phenytoin was successful in suppressing them. Electroencephalogram (EEG) and cranial CT were performed, and revealed no new significant abnormalities. His general medical condition substantially improved. About a month later, he developed a mixed skin / respiratory severe sepsis. ESBL-producing *Klebsiella pneumoniae* was isolated from skin specimens, and imipenem was started at an adjusted dose. In the next two days, an impaired level of consciousness was established, and fluctuations between sleepiness and obtundation went on. Four days later, his relatives reported new-onset generalized movements; on clinical examination sudden, brief, shock-like, involuntary, symmetrical, synchro-

nous and repetitive muscle contractions were observed on proximal limb muscles (positive myoclonus). Common causes of metabolic encephalopathy were excluded by means of laboratory exams (complete blood count, glucose levels, renal / hepatic function, electrolytes and phenytoin level). A new head CT (Fig 2) showed stable edema and post-operative alterations but was not particularly helpful. A wake-up EEG (Fig 3) was performed concomitantly to the hyperkinesias and disclosed irregular slow waves and non-periodic left parieto-temporal sharp waves. In light of these findings, imipenem therapy was withdrawn, and 3 days later his consciousness level was fully recovered and myoclonus had disappeared. In order to confirm the improvement and to document

the electrophysiological changes, a control EEG (Fig 4) was performed and was consistent with improved background rhythms; no sharp waves were detected anymore.

DISCUSSION

This report aims to show a probable adverse drug reaction related to imipenem use. The chronological relationship between the introduction of the drug and the onset of encephalopathy, and its withdrawn and patient recovery reveal a close association with imipenem. Additionally, the combined EEG findings give support to this association.

The most recommended method for estimating the probability of an adverse drug reaction is the Naranjo Scale². Analyzed by this method, our case scored a total of 6, which represents a “probable” adverse drug reaction.

Medical literature demonstrates some articles on imipenem neurotoxicity, most of them reporting seizures. A paper from Rivera et al.³ reports a case of a 80-year-old male who developed reversible myoclonus after the beginning of Imipenem. This patient had the most common risk factor for neurotoxicity, chronic renal insufficiency.

The article from Norrby⁴ discusses the prevalence of seizures caused by imipenem to be 0.2%, while Rodloff et al.¹ refers to the prevalence of seizures to be 1.4%. All these articles present seizures as the most common neurologic adverse event caused by imipenem. Similarly as

reported by Norrby⁴, our patient also had previous CNS disease as a risk factor for neurotoxicity from imipenem. The case presented here, however, is an example of encephalopathy, not of an isolated seizure.

Betalactamic-related encephalopathy is not a new clinical entity. Broadly used antibiotics such cefepime are soundly related to various abnormal mental status disorders⁵. The clinical picture and EEG findings from cefepime encephalopathy can perfectly be superimposed to our case. To our knowledge, no previous imipenem-related encephalopathy was formally reported.

Considering this patient evolution, imipenem-related encephalopathy appears to be a reversible and relevant clinical entity. We conclude that physicians should be alert about symptoms of encephalopathy. We suggest that more studies on this subject should be done.

REFERENCES

1. Rodloff AC, Goldstein EJC, Torres A. Two decades of imipenem therapy. *J Antimicrob Chemotherapy* 2006;58:916-929.
2. Naranjo CA, Busto U, Sellers EM, et al. A method for estimating the probability of adverse drug reaction. *Clin Pharmacol Ther* 1981;30:239-245.
3. Rivera M, Crespo M, Teruel JL, Marcén R, Ortuño J. Neurotoxicity due to imipenem-cilastatin in patients on continuous ambulatory peritoneal dialysis. *Nephrol Dial Transplant* 1999;14:258-259.
4. Norrby RS. Neurotoxicity of carbapenem antibacterials. *Drug Safety* 1996; 15:87-90.
5. Bragatti JA, Rossato R, Ziolkowski S, Kliemann FAD. Encefalopatia induzida por cefepime: achados clínicos e eletroencefalográficos em sete pacientes. *Arq Neuropsiquiatr* 2005;63:87-92.