

Pathology in Practice

In collaboration with the American College of Veterinary Pathologists

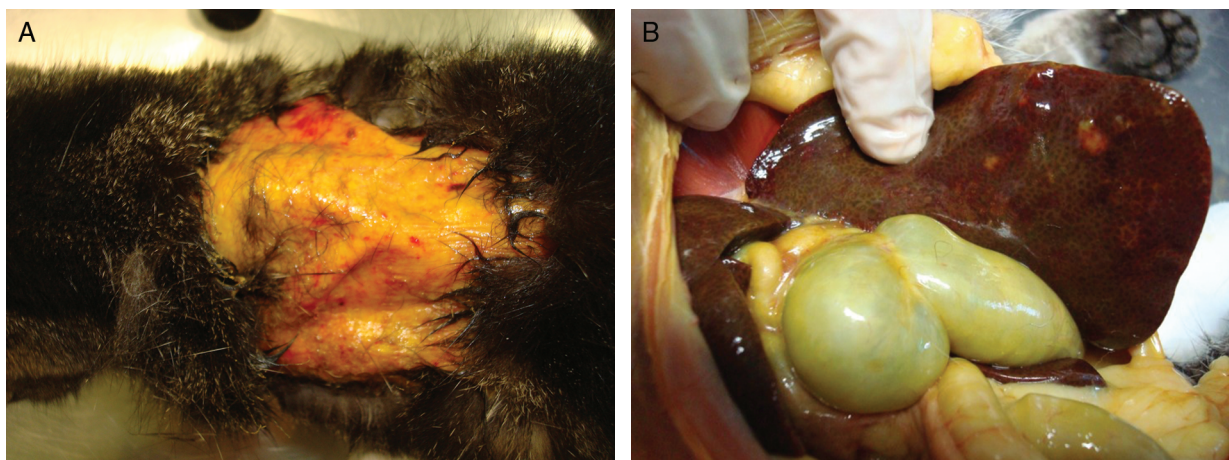


Figure 1—Postmortem images of an adult 2.5-kg spayed female domestic shorthair stray cat that was euthanized after evaluation for a 2-week history of weight loss, lethargy, and hyporexia. **A**—Skin fragility and a severe interscapular skin tear occurred during routine restraint and revealed intense icterus of underlying tissue. **B**—The gallbladder is severely distended, and the liver has an irregular surface, diffusely yellowish-brown color, multifocal variably sized tan nodules, and diffusely enhanced zonal pattern.

History

An adult 2.5-kg spayed female domestic shorthair stray cat that lived in a public park in Rio de Janeiro, Brazil was referred to the Federal Fluminense University Veterinary Hospital for an evaluation. The person responsible for feeding the stray cat in the park had noticed weight loss, lethargy, and hyporexia during the last 2 weeks. The cat was first taken to a private veterinary clinic, and during physical examination, minimal restraint caused a substantial tear in the skin of the interscapular region; however, the

tear did not bleed. The cat received buprenorphine (0.02 mg/kg, buccal transmucosal) and was referred for further evaluation and treatment.

Clinical and Gross Findings

On physical examination at the Federal Fluminense University Veterinary Hospital, a cervicodorsal skin tear of approximately 10 X 7 cm with muscle exposure was evident. The lesion revealed severe jaundice in the underlying tissues (**Figure 1**). The cat was lethargic, thin (body condition score of 2/5), anorectic, moderately dehydrated (7%), and hypothermic. Mucous membranes were icteric, and the liver was enlarged on palpation. Because of the cat's deteriorating condition and poor prognosis, euthanasia was elected.

On a postmortem examination, which was performed immediately after euthanasia, fragility of the cat's skin was generalized; the skin was thin, tore easily, and could be easily detached from the subcutaneous tissue. The liver was enlarged and had rounded edges, an irregular surface, and a yellowish-brown color. On cut surface, biliary ducts were distended and thickened. The gallbladder was severely distended, had a thickened wall, and contained a viscous greenish fluid with numerous brown spots (**Figure 1**).

Aline Bomfim Vieira, DVM, PhD^{1*}; Juliana Werner, DVM, MSc²; Fernanda Vieira Amorim da Costa, DVM, PhD³; Sara Maria de Carvalho e Suzano, DVM, PhD⁴; Maria Cristina Nobre e Castro, DVM, PhD⁴; Nayro Xavier de Alencar, DVM, PhD⁴

¹Biomedical Department, Ross University School of Veterinary Medicine, West Farm, Basseterre, St. Kitts

²Werner and Werner Veterinary Pathology Laboratory, Ahú, Curitiba, PR, Brazil

³College of Veterinary Medicine, Rio Grande do Sul Federal University, Agronomia, Porto Alegre, RS, Brazil

⁴College of Veterinary Medicine, Fluminense Federal University, Niterói, Rio de Janeiro, Brazil

*Corresponding author: Dr. Vieira (avieira@rossvet.edu.kn)

<https://doi.org/10.2460/javma.20.03.0111>

Bile flow was obstructed. Regional lymph nodes were enlarged, but no other clinically important macroscopic lesions were found in the remaining organs. Samples were collected for histopathologic analyses of all organs, and a sample of bile fluid was collected for cytologic evaluation.

Formulate differential diagnoses, then continue reading.

Cytologic and Histopathologic Findings

Cytologic examination of the bile fluid revealed 4- to 8-mm-long trematode parasites (flukes) consistent with *Platynosomum fastosum* (Figure 2). They had a smooth external cuticle, no coelomic cavity, a subterminal oral sucker, and both male and female reproductive organs. Numerous eggs ranging from 30 to 50 μ m were also identified. Eggs had an operculum at one of the ends. They were golden brown, oval, thick shelled, and embryonated, containing a ciliated miracidium.

Histological evaluation of liver tissue revealed diffuse hepatocellular atrophy, moderate multifocal portal fibrosis with lymphoplasmacytic and neutrophilic inflammatory infiltrate, and mildly distended portal veins. There was severe, multifocal dilation of bile ducts with marked epithelial hyperplasia and moderate periductal fibrosis. The hyperplastic dilated bile ducts frequently contained neutrophils, macrophages, and organisms morphologically consistent with *Platynosomum fastosum* (Figure 3).

Histological sections of haired skin showed epidermal atrophy and basketweave orthokeratosis (Figure 3). The dermis was also atrophic with very

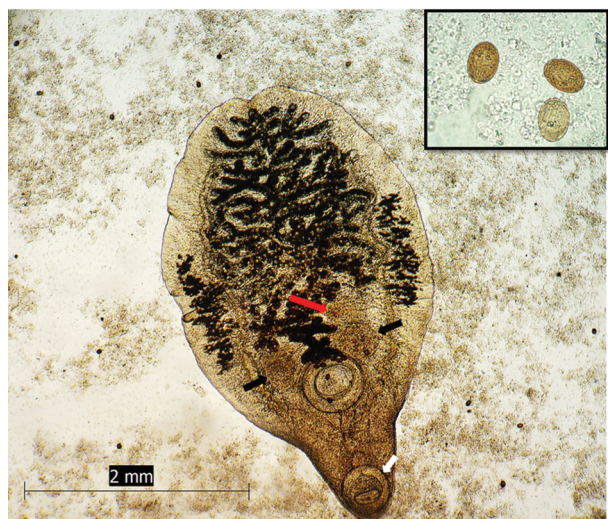


Figure 2—Photomicrograph of a trematode consistent with an adult *Platynosomum fastosum* surrounded by numerous eggs in the bile fluid from the cat described in Figure 1. Note the thin tegument, no coelomic cavity, subterminal oral sucker (white arrow), testes (black arrow), and ovary (red arrow). No stain; bar = 2 mm. Inset—Golden brown, oval, thick-shelled eggs ranging in size from 30 to 50 μ m, each with a miracidium inside. Unstained.

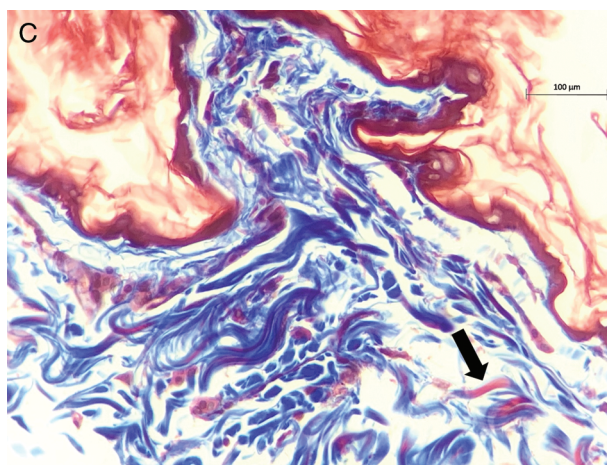
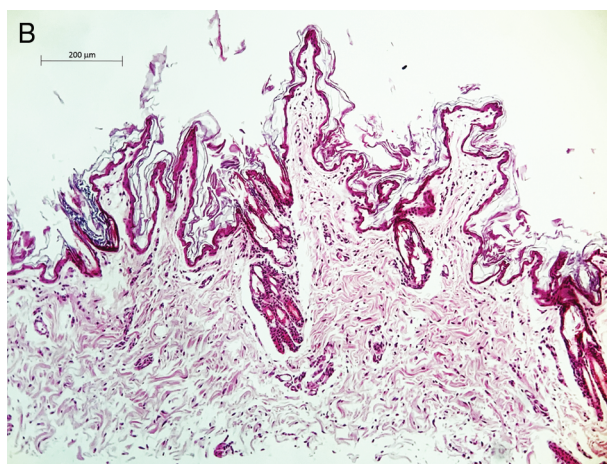
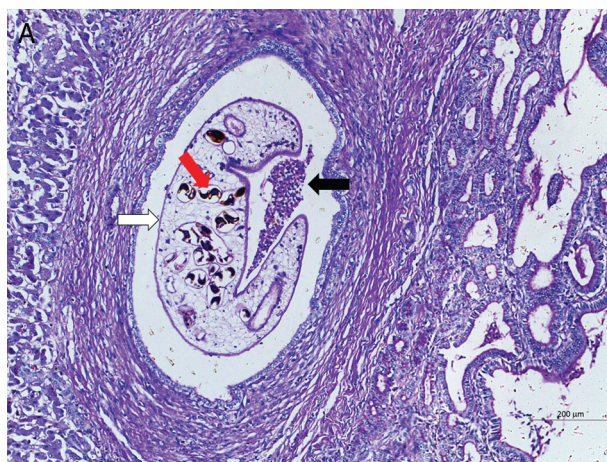


Figure 3—Photomicrographs of section of the cat's liver (A) and haired skin (B and C). A—Chronic cholangitis due to liver fluke infestation. Note the severe, intrahepatic biliary hyperplasia with periductular fibrosis (rightward). One duct is markedly dilated and contains neutrophils (black arrow) and a C-shaped organism compatible with *P fastosum* (white arrow). Dark brown eggs can be visualized within the parasite (red arrow). H&E stain; bar = 200 μ m. B—The epidermis and dermis are atrophic, and dermal collagen fibers are thin, irregular, and loose. H&E stain; bar = 200 μ m. C—Abnormal collagen fibers have red cores (arrow), in contrast to the diffuse blue staining of normal collagen fibers. Masson trichrome stain; bar = 100 μ m.

attenuated collagen fibers. Hair follicles were in telogen phase, atrophic, and contained hair shafts (Figure 3). The residual arrector pili muscles were prominent. The sebaceous glands were atrophic, and the apocrine glands were histologically normal. There were moderate numbers of putatively abnormal collagen fibers with red cores demonstrated by Masson's trichrome stain, in contrast to the diffuse blue staining of normal collagen fibers. Findings were consistent with acquired feline skin fragility syndrome (FSFS).

Morphologic Diagnosis and Case Summary

Morphologic diagnosis and case summary: FSFS in a cat with chronic cholangiohepatitis secondary to *P. fastosum* infection.

Comments

Differential diagnoses for posthepatic jaundice in a cat include transient or persistent mechanical bile duct obstruction (pancreatitis, neoplasia of bile ducts, pancreas, or duodenum), intraluminal duct occlusion (cholelithiasis, sludged bile, liver flukes, or immune-mediated duct destruction), and ruptured biliary tree causing bile peritonitis.¹

Platynosomum fastosum is a liver fluke that has been reported in wild and domestic cats from many countries, including Brazil. It is the most common liver parasite detected in domestic cats and is usually localized in the biliary ducts and gallbladder causing inflammation and obstruction.²⁻⁴ Cats become infected with *P. fastosum* after ingestion of lizards, geckos, salamanders, or toads containing metacercariae, which is common for stray cats. In cats, cercariae are released in the upper digestive tract and enter the biliary tree.^{5,6} After 8 to 12 weeks, fluke eggs start to be shed in the feces and can be identified by a centrifugal fecal flotation procedure in Sheather sugar solution.⁷ Finding parasite eggs in fecal samples is not always possible because egg production is limited and complete biliary obstruction is possible,⁸ as was seen in this case.

Although *P. fastosum* usually causes subclinical or mild disease, clinical findings may vary with the severity of infestation, the number of adult parasites, and individual reactions to parasite invasion. Lesions of the liver and biliary tract include hepatic and biliary duct fibrosis^{9,10} and cholangiohepatitis.^{9,11} The severity of the cholangiohepatitis in the cat of the present report was likely due to the poor living conditions, the cat's immunity status, and severity of infestation.

Available treatment protocols for *P. fastosum* involve praziquantel (20 mg/kg, PO, q 24 h for 3 to 5 days), surgical removal of the flukes, or both. When severe infestation exists, the prognosis is poor.¹²

Feline skin fragility syndrome is an uncommon, acquired condition characterized by markedly fragile, thin skin that could be damaged readily by minor trauma and without bleeding.¹³⁻¹⁵ Middle-aged to

older cats with no previous history of dermatologic signs before onset are affected.¹⁵ Differential diagnosis for skin fragility in cats includes FSFS, hereditary collagen dysplasia, and feline paraneoplastic syndrome.¹⁶

Feline skin fragility syndrome is most commonly associated with spontaneous and iatrogenic hypercortisolism or excessive use of progestational drugs, which can inhibit collagen synthesis.^{17,18} Additionally, FSFS has rarely been described concomitantly with severe inflammatory or neoplastic diseases including cholangiohepatitis, hepatic lipidosis, and cholangiocarcinoma.^{13,14} The pathogenesis of cutaneous changes associated with hepatic disease remains unknown, but a severe catabolic state and starvation have been suggested as possible causes.¹⁹

Infectious agents have also been reported in association with FSFS. Feline infectious peritonitis (FIP)¹⁴ and, more recently, disseminated histoplasmosis and FIV were reported in association with FSFS.^{19,20} However, to the authors' knowledge, this is the first report of FSFS associated with *P. fastosum* infection in a cat.

Based on the history and results of clinicopathologic examinations performed, hyperadrenocorticism and steroidal drug administration were ruled out as possible causes for the skin fragility in the cat of the present report. Furthermore, no signs of tumor, viral, or fungal infection were found during necropsy and histological examination. Nevertheless, we cannot completely rule out that a concomitant infectious agent may have played a role in the evolution of the presented case because the cat was never tested for FIV, FeLV, or FIP.

Hereditary collagen dysplasia (Ehlers-Danlos syndrome or cutaneous asthenia) is a congenital form of skin fragility, in which animals from a very early age show a connective tissue disorder caused by defective collagen synthesis or assembly.²¹ These animals have a chronic history of concurrent skin hyper extensibility and lacerations.^{21,22} Although the acquired and congenital conditions are difficult to differentiate histologically,²³ it was unlikely that the cat reported here could have lived for several years with the congenital form of skin fragility.²² Additionally, the skin tear of this cat occurred because of normal handling, without bleeding or hyperextensibility, which is classical of FSFS, as are the histopathologic abnormalities observed.^{13,14}

There is no current treatment for FSFS other than supportive care (eg, clothing and avoiding skin trauma) and treatment of a possible associated metabolic, infectious, or neoplastic disease. Patients are often quite debilitated, and most have poor prognoses.^{13,14} However, a recent report described successful recovery of 3 cats with FSFS.¹⁹

Although a cause and effect relationship cannot be stated with certainty in this case, it is important to note that liver flukes should be taken into consideration as a possible underlying cause in cats with skin fragility and jaundice.

Acknowledgments

The authors are grateful to Dr. Aline Mattos and Dr. Beatriz Donda for providing help during necropsy.

References

1. Sherding RG. Feline jaundice. *J Feline Med Surg.* 2000;2:165-169.
2. Braga RR, Teixeira AC, Oliveira JA, Cavalcanti LP. Prevalence of *Platynosomum fastosum* infection in free roaming cats in northeastern Brazil: fluke burden and grading of lesions. *Vet Parasitol.* 2016;227:20-25.
3. Salomão M, Souza-Dantas LM, Mendes-de-Almeida F, Branco AS, Bastos OP, Sterman F, et al. Ultrasonography in hepatobiliary evaluation of domestic cats (*Felis catus*, L., 1758) infected by *Platynosomum* Looss, 1907. *Int J Appl Res Vet Med.* 2005;3:271-279.
4. Ferreira A, Paes de Almeida E, Labarthe N. Liver fluke infection (*Platynosomum concinnum*) in Brazilian cats: prevalence and pathology. *Feline Pract.* 1999;27:19-22.
5. Basu AK, Charles RA. A review of the cat liver fluke *Platynosomum fastosum* Kossack, 1910 (Trematoda: Dicrocoeliidae). *Vet Parasitol.* 2014;200:1-7.
6. Maldonado JF. The life-history and biology of *Platynosomum fastosum* Kossack, 1910 (Trematoda: Dicrocoeliidae). *PR J Public Health Trop Med.* 1945;21:17-39.
7. Rocha NO, Portela RW, Camargo SS, Souza WR, Carvalho GC, Bahiense TC. Comparison of two coproparasitological techniques for the detection of *Platynosomum* sp. infection in cats. *Vet Parasitol.* 2014;204:392-395.
8. Fossum T, Willard MD. Diseases of the gallbladder and extrahepatic biliary system. In: Ettinger SJ, Feldman FC, eds. *Textbook of Veterinary Internal Medicine: Diseases of the Dog and Cat.* W. B. Saunders. 1995:1393-1398.
9. Andrade RL, Dantas AF, Pimentel LA, Galiza GJ, Carvalho FK, Costa VM, et al. *Platynosomum fastosum*-induced cholangiocarcinomas in cats. *Vet Parasitol.* 2012;190:277-280.
10. Headley SA, Gillen MA, Sanches AW, Zatti MC. *Platynosomum fastosum*-induced chronic intrahepatic cholangitis and *Spirometra* spp. infections in feral cats from Grand Cayman. *J Helminthol.* 2012;86:209-214.
11. Carreira VS, Vieira RF, Machado GF, Luvizotto MC. Feline cholangitis/ cholangiohepatitis complex secondary to *Platynosomum fastosum* infection in a cat. *Rev Bras Parasitol Vet.* 2008;17(Suppl 1):184-187.
12. Little S. *The Cat-E-Book: Clinical Medicine and Management.* Elsevier Health Sciences; 2011.
13. Daniel AG, Lucas SR, Junior AR, Monteiro PR, Ramos D, Pires CG, et al. Skin fragility syndrome in a cat with cholangiohepatitis and hepatic lipidosis. *J Feline Med Surg.* 2010;12:151-155.
14. Trotman TK, Mauldin E, Hoffmann V, Del Piero F, Hess RS. Skin fragility syndrome in a cat with feline infectious peritonitis and hepatic lipidosis. *Vet Dermatol.* 2007;18:365-369.
15. Miller WH Jr, Griffin CE, Campbell KL. *Muller and Kirk's Small Animal Dermatology.* Elsevier Health Sciences; 2012.
16. Tilley LP, Smith FW Jr. *Blackwell's Five-Minute Veterinary Consult: Canine and Feline.* John Wiley & Sons; 2015.
17. Spada E, Proverbio D, Giudice C, DiGiancamillo M, Lodi M, Perego R. Pituitary-dependent hyperadrenocorticism and generalised toxoplasmosis in a cat with neurological signs. *J Feline Med Surg.* 2010;12:654-658.
18. Cross E, Moreland R, Wallack S. Feline pituitary-dependent hyperadrenocorticism and insulin resistance due to a plurihormonal adenoma. *Top Companion Anim Med.* 2012;27:8-20.
19. Furiani N, Porcellato I, Brachelente C. Reversible and cachexia-associated feline skin fragility syndrome in three cats. *Vet Dermatol.* 2017;28:508-e121.
20. Tamulevicius AM, Harkin K, Janardhan K, Debey BM. Disseminated histoplasmosis accompanied by cutaneous fragility in a cat. *J Am Anim Hosp Assoc.* 2011;47:e36-e41.
21. Freeman LJ, Hegreberg GA, Robinette JD. Ehlers-Danlos syndrome in dogs and cats. *Semin Vet Med Surg (Small Anim).* 1987;2:221-227.
22. Hansen N, Foster SF, Burrows AK, Mackie J, Malik R. Cutaneous asthenia (Ehlers-Danlos-like syndrome) of Burmese cats. *J Feline Med Surg.* 2015;17:954-963.
23. Scott DV. Cutaneous asthenia in a cat, resembling Ehlers-Danlos syndrome in man. *Vet Med Small Anim Clin.* 1974;69:1256-1258.