

## PERITONITIS BY *Scedosporium apiospermum* IN A PATIENT UNDERGOING CONTINUOUS AMBULATORY PERITONEAL DIALYSIS

Luiz Carlos SEVERO(1), Flávio de Mattos OLIVEIRA(1), Clotilde Druck GARCIA(2), Anelise UHLMANN(2) & Alberto Thomaz LONDERO(3)

### SUMMARY

A case of peritonitis due to *Scedosporium apiospermum* in a boy undergoing continuous ambulatory peritoneal dialysis is reported. The finding of suggestive tissual form of the fungus in the effluent hastened the diagnosis of the infection.

**KEYWORDS:** Scedosporiosis; *Scedosporium apiospermum*; Dialysis; Peritonitis.

### INTRODUCTION

Fungal peritonitis is an uncommon complication of continuous ambulatory peritoneal dialysis (CAPD). This condition is predominantly caused by fungi inhabiting patient's skin, more rarely by environmental fungi and, exceptionally, by dimorphic pathogenic fungi<sup>9,15</sup>.

In spite of being an environmental cosmopolitan soil and water living fungus<sup>4</sup>, *Scedosporium apiospermum* has not yet been quoted as an agent of CAPD associated peritonitis. This is the reason for the presentation of this report. In addition some commentaries on the suggestive forms of *S. apiospermum* in clinical specimens were also made.

### CASE REPORT

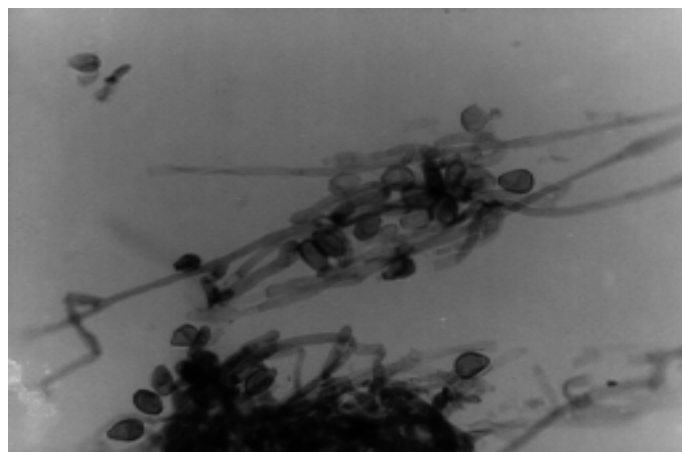
This patient, a 12 year - old boy, was a carrier of hepatitis B surface antigen. He has been undergoing CAPD since Jun/92 because of end-stage renal disease, secondary to cystinosis. Baxter (Deerfield, IL) conventional spike system was used. Four exchange of dialysate fluid (4.25 g/l in 1.5% dextrose solution) per day was performed.

On Dec/92 and, again, on May/93 the patient suffered from *Staphylococcus aureus* peritonitis. In both episodes he was successfully treated with intraperitoneal vancomycin. On Aug/93, the patient complained of abdominal pain. Soon the dialysate effluent became cloudy. The effluent was then collected for microbiological examination.

**Laboratory findings.** The dialysate effluent concentration of leukocytes was 1,600/mm<sup>3</sup> (90% polymorphs, 10% monocytes/macrophage). Microscopic examination of the sediment of the centrifugated dialysate revealed hyaline, septate hyphae and many one-celled, smooth, ovoid, pale brown conidia with truncate base. These structures, consistent with *Scedosporium* sp., were also observed in smear

of the specimen stained by Gomori methenamine silver stain (Fig. 1). No bacteria were disclosed in Gram stain. Floccose white colonies, that soon turned to dark grey, were obtained on Sabouraud dextrose agar medium, incubated at room temperature. These colonies were composed of hyaline, ramified, septate hyphae and light brown ovoid annelloconidia (6-10x3.5-5µm) with a truncate base. These characteristics identify *S. apiospermum*.

The Tenckhoff catheter was removed and the patient was put back in hemodialysis. No antifungal therapy was used. On Dec/93 the boy was submitted to a living related donor transplantation. In Jun/96 creatinine value was 1.7 mg% . On Dec/98 the patient was clinically very well.



**Fig.1** - Microscopic examination of peritoneal effusion, showing branching septate hyphae and annelloconidia suggestive of *S. apiospermum* (GMS, x 100)

(1) Laboratório de Microbiologia Clínica, Instituto Especializado em Pesquisa e Diagnóstico, Santa Casa, Porto Alegre, RS, Brasil.

(2) Serviço de Nefrologia, Santa Casa, Porto Alegre, RS, Brasil.

(3) Universidade Federal de Santa Maria, Santa Maria, RS, Brasil.

**Correspondence to:** Dr. Luiz Carlos Severo, Laboratório de Microbiologia Clínica, IPD-Santa Casa, Annes Dias 285, 90020-090 Porto Alegre, RS, Brazil.

Fax: (5551) 214 8435, E-mail:severo@santacasa.tche.br

## COMMENTS

To our knowledge our case is the first one of CAPD associated peritonitis caused by *S. apiospermum*.

It was interesting to note that the agent of our patient's infection was suspected since the direct microscopic examination of the clinical specimen. A great number of characteristic conidia of *Scedosporium* type at the side of hyaline, septate hyphae were seen in direct mount of the sediment of the dialysate. This finding hastened the removal of the catheter and also facilitates the selection of the culture medium for the identification of the species.

*Scedosporium* conidia has been an important finding in the clinical specimen for the diagnosis of scedosporiosis<sup>2,7</sup>. However, the isolation in culture is necessary to identify the species of *Scedosporium*. This characteristic forms of the potentially pathogenic species of *Scedosporium* has been detected in exsudates<sup>13</sup>, pus from abscess<sup>6</sup>, organic fluids<sup>8</sup>, infections or colonization of cavities<sup>1,3</sup>, endocarditis thrombus<sup>5</sup>, as well as in histological sections of tissues obtained from many organic active<sup>2,9,14,16</sup> or residual<sup>17</sup> lesions caused by the two species of pathogenic *Scedosporium*.

## RESUMO

### Peritonite por *Scedosporium apiospermum* em paciente sob diálise peritoneal ambulatorial continuada

É relatado caso de peritonite por *Scedosporium apiospermum* em menino sob diálise peritoneal ambulatorial continuada. O achado de formas teciduais sugestivas do fungo acelerou o diagnóstico da infecção.

## REFERENCES

1. BAKERSPIGEL, A.; WOOD, T. & BURKE, S. - Pulmonary alloscheriasis. Report of a case from Ontario, Canada. **Amer. J. clin. Path.**, 62: 299-303, 1977.
2. BERENQUER, J.; RODRÍGUES-TUDELA, J.L.; RICHARD, C. *et al.* - Deep infections caused by *Scedosporium prolificans*. A report of 16 cases in Spain and a review of the literature. **Medicine (Baltimore)**, 76: 256-265, 1997.
3. BRYAN, C.S.; DiSALVO, A.F.; KAUFMAN, L. *et al.* - *Petriellidium boydii* infection of the sphenoid sinus. **Amer. J. clin. Path.**, 74: 846-851, 1980.
4. CREMER, G. & BOIRON, P. - Epidemiology and biology of *Scedosporium* species. **J. Mycol. méd.**, 6: 165-171, 1996.
5. ENGGANO, I.L.; HUGHES, W.T.; KALWINSKY, D.K. *et al.* - *Pseudallescheria boydii* in a patient with acute lymphoblastic leukemia. **Arch. Path. Lab. Med.**, 108: 619-622, 1984.
6. GUYOTAT, D.; PIENS, M.A.; BOUVIER, R. & FIERE, D. - A case of disseminated *Scedosporium apiospermum* infection after bone marrow transplantation. **Mykosen**, 30: 151-154, 1987.
7. HOOG, G.S.; MARVIN-SIKKEMA, F.D.; LAHPOOR, G.A. *et al.* - Ecology and physiology of the emerging opportunistic fungi *Pseudallescheria boydii* and *Scedosporium prolificans*. **Mycoses**, 37: 71-78, 1994.
8. LUTWICK, L.I.; GALGIANI, J.N.; JOHNSON, R.H. & STEVENS, D.A. - Visceral fungal infections due to *Petriellidium boydii* (*Allescheria boydii*). In vitro drug sensitivity studies. **Amer. J. Med.**, 61: 632-640, 1976.
9. MENT, S.H.; SMITH, R.R.; KARP, J.E. & MERZ, W.G. - Pulmonary, cardiac and thyroid involvement in disseminated *Pseudallescheria boydii*. **Arch. Path. Lab. Med.**, 108: 859-861, 1984.
10. NAGAPPAN, R.; COLLINS, J.F. & LEE, W.T.L. - Fungal peritonitis in continuous peritoneal dialysis. The Auckland experience. **Amer. J. Kidney Dis.**, 20: 492-496, 1992.
11. PIENS, M.A.; JIMENEZ, J.L.; GUYOTAT, D. *et al.* - A propos de trois observations d'infection humaine a *Scedosporium apiospermum*. Intérêt du traitement par itraconazole. **J. Mycol. méd.**, 1: 156-159, 1991.
12. RABDONIRINA, M.; PAULUS, S.; THEVENET, F. *et al.* - Disseminated *Scedosporium prolificans* (*S. inflatum*) infection after a single-lung transplantation. **Clin. infect. Dis.**, 19: 138-142, 1994.
13. SEVERO, L.C.; OLIVEIRA, F.M. & LONDERO, A.T. - Subcutaneous scedosporiosis. Report of two cases and review of the literature. **Rev. Inst. Med. trop. S. Paulo**, 39: 227-230, 1997.
14. SMITH, A.G.; CRAIN, S.M.; DEJONGH, C. *et al.* - Systemic pseudallescheriasis in a patient with acute myelocytic leukemia. **Mycopathologia (Den Haag)**, 90: 85-89, 1985.
15. von GRAEVENITZ, A. & AMSTERDAM, M. - Microbiological aspects of peritonitis associated with continuous ambulatory peritoneal dialysis. **Clin. Microbiol. Rev.**, 5: 36-48, 1992.
16. WILSON, C.M.; O'ROURKE, E.J.; MCGINNIS, M.R. & SALKIN, I.F. - *Scedosporium inflatum*: clinical spectrum of a newly recognized pathogen. **J. infect. Dis.**, 161: 102-107, 1990.
17. WOODARD, B.H. - Asymptomatic pulmonary coin lesion with *Petriellidium boydii*. **Sth. med. J. (Bgham, Ala.)**, 75: 229-230, 1982.

Received: 09 March 1999

Accepted: 05 April 1999