

An *in vitro* assessment of type, position and incidence of isthmus in human permanent molars

Fernando José Camello de LIMA¹, Francisco MONTAGNER², Rogério Castilho JACINTO³, Glaucia Maria Bovi AMBROSANO⁴, Brenda Paula Figueiredo de Almeida GOMES⁵

1- Department of Restorative Dentistry, Endodontics Division, Piracicaba Dental School, State University of Campinas - UNICAMP, Piracicaba, SP, Brazil; Department of Morphology at the Biological Sciences Center, Federal University of Alagoas, Maceió, AL, Brazil.

2- Department of Restorative Dentistry, Endodontics Division, Piracicaba Dental School, State University of Campinas - UNICAMP, Piracicaba, SP, Brazil; Department of Restorative Dentistry, Endodontics Division, Federal University of Rio Grande do Sul, Porto Alegre, RS, Brazil.

3- Department of Restorative Dentistry, Endodontics Division, Piracicaba Dental School, State University of Campinas - UNICAMP, Piracicaba, SP, Brazil; Department of Semiology and Clinics, Endodontics Division, Federal University of Pelotas, Pelotas, RS, Brazil.

4- Department of Social Dentistry, Biostatistics Division, Piracicaba Dental School, State University of Campinas - UNICAMP, Piracicaba, SP, Brazil.

5- Department of Restorative Dentistry, Endodontics Division, Piracicaba Dental School, State University of Campinas - UNICAMP, Piracicaba, SP, Brazil.

Corresponding address: Brenda P. F. A. Gomes - Faculdade de Odontologia de Piracicaba - Universidade Estadual de Campinas - UNICAMP - Área de Endodontia - Av. Limeira 901 - Areião - Piracicaba - SP - Brazil - 13414-903 - Phone: (55) 19 2106 5343 - Fax: (55) 19 2106 5218 - e-mail: bpgomes@fop.unicamp.br

Submitted: November 06, 2013 - Modification: April 5, 2014 - Accepted: April 22, 2014

ABSTRACT

Root canal anatomical complexities, such as isthmus, may limit the action of the Endodontic instruments, irrigant solutions and intracanal medications, leading to endodontic treatment failure. Objectives: This *in vitro* study assessed the type, position and incidence of isthmus in human permanent molars. Material and Methods: One hundred and twenty eight upper and lower first and second permanent molars were analyzed. The roots were embedded in transparent resin, and then split at different distances from the apex (1.0–2.5–4.0–5.5–7.0 mm). Following the sample examination in stereomicroscope, the data were submitted to chi-square statistical test at a 5% significance level. Results: The highest isthmus incidence was at 7.0 mm from the root apex in all samples, except the distal root of lower molars (at 5.5 mm). In upper and lower molars, type V (complete isthmus with a continuous opening between the two main root canals) was the most common classification of isthmus (28.8%). In the mesial root of first and second mandibular molars, type IV had the highest incidence (36% and 23.9%, respectively). Conclusion: It was concluded that isthmus was widely found in flat roots, with a low percentage in areas close to the apex. In upper and lower molars, these structures were most frequently found at 7 mm from the apex.

Keywords: Anatomy. Molar. Endodontics.

INTRODUCTION

Conventional root canal therapy addresses the entire root canal system with predictable successful clinical results. However, anatomical complexities limit the action of the instruments, irrigant substances and intracanal medications. Not properly cleaned canals are associated with periapical inflammatory responses and bone destruction, indicating in some cases, a need for periapical surgery to remove the lesion and the contaminated area of the apex⁴. One of the main anatomical complexities in molars is the area of

isthmus, which can act as a reservoir for organic matter and microorganisms⁶. Frequently they are not filled, emphasizing the difficulty of orthograde instrumentation and root filling of canal isthmuses²⁴.

An isthmus is defined as a narrow anatomical part or passage connecting two larger structures or cavities, which can be considered it as a lateral connection between canals of the same root¹⁵, or classified as an anastomosis²². Isthmus can also be classified as complete or partial; i.e., a continuous connection between two main root canals is considered a complete isthmus, while an incomplete communication with one or more patent openings

through the section between the two main canals is classified as partial isthmus²⁵.

Isthmus has been classified into five categories according to particular features¹¹ as follows: type I comprised roots with either two or three canals without visible communication; type II comprised roots with two canals with a visible connection between the two main canals; type III differs from type II due to the presence of a canal between the two main canals – incomplete C-shaped canals with three canals were also included in this classification; type IV was defined as an extension from the canals to the isthmus area; and type V was recognized as a real connection or corridor throughout the section. Types I and III were the most frequently found isthmuses in mesial-buccal roots of first upper molars (37.5 and 31.2%, respectively) in a previous report²⁶.

Any root possessing a compressed form or presenting more than one canal has the potential to contain an isthmus. It has been reported that there is a high incidence of isthmus in the mesial-buccal root of the upper first molars and in the mesial root of lower first molars, particularly at 3-5 mm from the apex²¹. Isthmus has been found in 30.1% of the mesial-buccal roots of first and second upper molars and in 60.2% and 14.8% of the mesial and distal roots, respectively, of first and second lower molars². It has also been detected in 76% of the maxillary first molars resected from mesial-buccal roots and in 83% of the mesial roots of mandibular first molars²⁴.

The incidence of different types of isthmus might vary in different populations, and studies around the world are necessary. Therefore, the aim of this study was to determine the type, position and incidence of isthmus in upper and lower human molars.

MATERIAL AND METHODS

This research was approved by the local research ethics committee of the Piracicaba Dental School, State University of Campinas (UNICAMP), Piracicaba, SP, Brazil.

The methods used in the present report have previously been described by Teixeira, et al.²¹ (2003). Seventy-two upper molars presenting separated roots and 56 lower molars were selected and stored in 10% formalin. To assess the presence of compression form and isthmus, 38 first and 34 second upper molars and 30 first and 26 second lower molars, recently extracted due to reasons unrelated to the present research, were randomly selected from unknown patients. The identification of these teeth as upper or lower molars was confirmed by accepted criteria¹⁸.

Every tooth was radiographed with the beam

directed first buccolingually and then in a mesiodistal direction. The following exposure parameters were standardized: 66 kVp and 6.5 mA, intraoral dental radiographic films (Kodak Dental E-speed, Eastman Kodak Co., Rochester, NY, EUA), 20 cm distance of focus to film, exposure time of 0.5 s and a constant incidence of the central ray perpendicular to the film. All specimens were radiographed by the same apparatus (Gnatus, Time model X66, Ribeirão Preto, SP, Brazil) and the same operator. All exposed films were processed automatically (Gendex GXP Dental X-ray Processor, KaVo Dental GmbH, Biberach, Germany). The radiographs were examined on a conventional illuminated X-ray viewer with the aid of a magnifying glass in order to record information related to the number and morphology of the root canals.

Furthermore, macroscopic data of the tooth, such as length, root length, crown length, presence or absence of root fusion, root shape (conical, flattened), root direction, position of the apical foramen, among other findings were also recorded.

After that, the teeth were sectioned at the enamel-cementum junction by using an ultra-thin separating disk. Only the segments containing the whole roots were used in this study.

Each sectioned root was embedded in clear resin (Crystal, São Paulo, SP, Brazil). Using the root apex as a reference, five serial horizontal sections were made perpendicular to the root long axis. These sections were 1.0 mm thick and performed with a low-speed diamond saw (South Bay Technology Inc., DW 114122, 323190117, San Clement, CA, USA). The sectioning started at 1 mm from the apex with intervals of 1.5 mm between them. Considering that the disc was 1 mm thick, the cuts were made 1.0–2.5–4.0–5.5–7.0 mm distant from the apex.

Each section was stored in 2.5% sodium hypochlorite for 24 hours in order to remove any organic material remaining inside the root canals. All specimens were examined under a stereomicroscope (Lambda Let 2, ATTO Instruments Co., Hong Kong, China) at 30x magnification to ensure that all organic materials were removed. Each slice was rinsed in water during 24 h and then air-dried. Only the apical side of each slice was evaluated. When the five levels of the sections were considered, a total of 190 samples were obtained from each mesial-buccal, distal-buccal and palatine root of upper first molars. The total number of slices for each root of upper second molars was 170. With regard to the lower molars, 150 slices were analyzed in each root of first molars, whereas 130 slices were obtained from each root of second molars.

The resected surface was stained with 2% methylene blue dye (The Coleman & Bell Co., Norwood, OH, USA) during 60 seconds and

examined under a stereomicroscope at 30x magnification. The images were obtained with a video camera (LG colour camera, CCD digital, Seoul, Korea) were stored by using the VidCap3 software (Informer Technologies, Inc, Commonwealth of Dominica) and then observed with a projector (Pro Screen/Philips 4600, Syncrotape, São Paulo, SP, Brazil) on a white screen. Two trained operators analyzed and classified the images in a double-blind manner in order to determine the presence or absence of an isthmus as well as its morphologic classification.

All slices were evaluated and the type of isthmus configuration present in each root was classified according to Hsu and Kim¹¹ (1997). Data were statistically analyzed by using SPSS 10.0 for Windows before being submitted to chi-square statistical test or Fisher's exact test, both at 5% significance level. Linear regression analysis was performed in order to predict a relationship between location and isthmus incidence.

RESULTS

Table 1 presents the percentage of occurrence and configuration of canals in each root of first and second upper and lower molars. It can be noted that the percentage of two canals is higher in mesial-buccal roots of either first or second upper molars. The mesial-palatal (MP) canal was found in 78.9% and 52.9% of the first and second upper molars, respectively. All mesial roots of the first lower molars and 65.4% of the lower second molars presented two canals.

Table 2 presents the frequency and percentage of isthmus and compression form in upper and lower

molars. All mesial-buccal roots of upper molars and mesial and distal roots of lower molars presented flattening (100%). However, the percentage of isthmus was different in such roots, varying in 98.5%, 91.1% and 46.4%, respectively. Palatine roots were not included because they presented oval or circular shape, without the presence of isthmus.

Tables 3 and 4 present the isthmus distributions according to the split levels in upper and lower first and second molars. The highest isthmus incidence occurred at 7.0 mm from the root apex, except for the distal roots of lower first molars (at 5.5 mm). The smallest incidence of isthmus occurred at 1.0 mm from the apex. Nevertheless, it is important to consider the high frequency of isthmus in lower molars involving segments of 2.5 to 5.5 mm from the apex.

Regression analysis suggests that regions more distant from the apex showed higher incidence of isthmus, in the upper and lower molar roots.

Table 5 presents the isthmuses distribution according to their types. The highest incidence of type V can be observed in all molars, except in the mesial roots of the lower molars, where type IV predominated. Fisher's exact test demonstrated statistical difference in the incidence of all isthmus types only between mesial-buccal roots of first and second upper molars ($p < 0.05$). However, no statistical difference was observed between mesial ($p = 0.182$) and distal ($p = 0.423$) roots in lower molars. The reference values for the calculations were the amounts of slices studied in each tooth, comprehending 190 in the upper first molars, 170 in the upper second molars, 150 in the lower first molars and 130 in the lower second molars.

Table 1- Percentage and configuration of canals in upper and lower molars

Configuration	Upper First Molar (n=38)		Upper Second Molar (n=34)		Configuration	Lower First Molar (n=30)		Lower Second Molar (n=26)	
	One Canal	Two Canals	One Canal	Two Canals		One Canal	Two Canals	One Canal	Two Canals
Mesiobuccal	21.1% (08)	78.9% (30)	47.1% (16)	52.9% (18)	Mesial	0%	100% (30)	34.6% (09)	65.4% (17)
Distobuccal	92.1% (35)	7.9% (03)	91.2% (31)	8.8% (03)	Distal	70% (21)	30% (09)	100% (26)	0%

Table 2- Frequency of flattened roots and isthmuses

Molar Tooth/Root	N of slices	Flatten	Isthmus
Upper/Mesiobuccal	360	100% (360)	98.5% (355)
Upper/Distobuccal	360	93.1% (335)	10.4% (35)
Lower/Mesial	280	100% (280)	91.1% (255)
Lower/Distal	280	100% (280)	46.4% (130)

Table 3- Isthmus position along the root segments in upper molars

	Upper First Molar (n=38)				Upper Second Molar (n=34)			
	Mesiobuccal Root		Distobuccal Root		Mesiobuccal Root		Distobuccal Root	
	Number	%	Number	%	Number	%	Number	%
1.0 mm	8	21.1%	0	0%	9	26.5%	0	0%
2.5 mm	21	55.3%	0	0%	9	26.5%	0	0%
4.0 mm	23	60.5%	4	10.5%	17	50%	0	0%
5.5 mm	29	7.3%	4	10.5%	20	59%	0	0%
7.0 mm	32	84.2%	5	13.2%	24	70.6%	0	0%
R2	0.99		0.99		0.99		-	
Int (sdtr)*	0.07 (0.03)		-0.005 (0.02)		-0.003 (0.02)		-	
CR (stdr)**	2.63 (0.001)		2.63 (0.007)		2.94 (0.001)			

*Intercept (Standard error), **Coefficient of regression (Standard error)

Table 4- Isthmus position along the root segments in lower molars

	First Molar (n=30)				Second Molar (n=26)			
	Mesial Root		Distal Root		Mesial Root		Distal Root	
	N of roots	% of isthmus	N of roots	% of isthmus	N of roots	% of isthmus	N of roots	% of isthmus
1.0 mm	13	43.3%	5	16.7%	7	26.9%	1	3.8%
2.5 mm	25	83.3%	11	36.7%	15	57.7%	1	3.8%
4.0 mm	28	93.3%	10	33.3%	19	73.1%	3	11.5%
5.5 mm	28	93.3%	17	56.7%	20	76.9%	4	15.4%
7.0 mm	29	96.7%	16	53.3%	22	84.6%	6	23.1%
R2	0.99		0.99		0.99		0.99	
Int (sdtr)*	-0.06 (0.06)		0.03 (0.05)		-0.02 (0.03)		-0.02(0.02)	
CR (stdr)**	3.33 (0.002)		3.33 (0.004)		3.85 (0.002)		3.86 (0.004)	

*Intercept (Standard error), **Coefficient of regression (Standard error)

Table 5- Isthmus distribution according to their morphologic classification

	Upper Teeth				Lower Teeth			
	First Molar (n=190)		Second Molar (n=170)		First Molar (n=150)		Second Molar (n=130)	
	Mesiobuccal (n=113)	Distobuccal (n=13)	Mesiobuccal (n=79)	Distobuccal (n=0)	Mesial (n=123)	Distal (n=59)	Mesial (n=83)	Distal (n=15)
	%	%	%	%	%	%	%	%
	(Number)	(Number)	(Number)	(Number)	(Number)	(Number)	(Number)	(Number)
Type I	24% (27)	15.4% (02)	19% (15)	0	12.2% (15)	10.2% (06)	12%(10)	26.7% (04)
Type II	8% (09)	0	0	0	8.9%(11)	5.1% (03)	7.2% (06)	0
Type III	15% (17)	0	2.5% (02)	0	13.8% (17)	10.2% (06)	7.2% (06)	0
Type IV	23% (26)	15.4% (02)	16.4% (13)	0	43.1% (53)*	16.9% (10)	37.3% (31)*	13.3% (02)
Type V	30% (34)*	69.3% (09)*	62% (49)*	0	21.9% (27)	57.6% (34)*	36.1% (30)	60% (09)*

* p<0.05

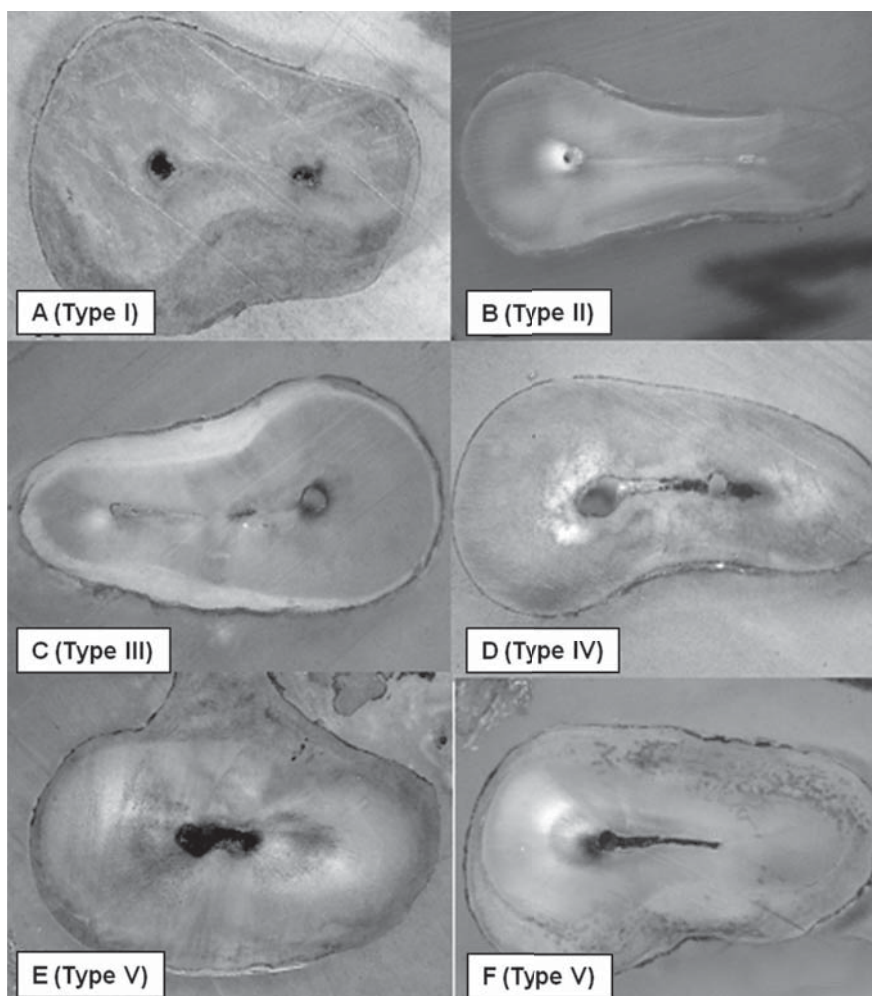


Figure 1- Isthmus: morphologic types in mesial-buccal roots of upper first molar. From A to D, types I to IV; E and F are type V

Figures 1 and 2 show the morphologic types of isthmus found in mesial-buccal roots of upper first molars and in mesial roots of lower first molars, respectively.

DISCUSSION

The presence of isthmus in roots of human molars has been investigated by both sectioning methods^{1,5,6,8,11,12,17,18,21,25,26} micro-computed tomography^{7,8,10,13,19,20,23,24} and cone beam computed tomography¹⁴.

The methodology used in the present study was based on Teixeira, et al.²¹ (2003). By using the same methods, an agreement was observed between the results of both investigations, i.e., mesial-distal flattened roots presented high incidence of two canals and high frequency of isthmus. However, the present work involves a deeper analysis of the incidence, position and type of isthmus in both first and second upper and lower molars, whereas previous studies neither analyzed second molars nor compared upper and lower molars, or used smaller number of specimens, or did not classify

the type of isthmus^{9,13,20,22,24,26}.

Studies showing the incidence of the anatomical variations and classifying these complexities are a didactic way of educating dental professionals to perform a better clinical practice based on sound principles. The analysis performed here provides a better understanding of the predicted location of isthmus and improves the classification of the different forms that can be observed in routine clinic procedures. All clinicians must be aware of the complexity of the spaces they are expected to access, shape, clean and fill during the endodontic treatment, including the isthmus, in order to perform the adequate treatment and consequently to get a higher level of success. Moreover, the presence of isthmus should also be investigated during periradicular surgery as a high frequency of canal isthmuses at the resection level can be found. When detected, the main canals should be joined to include the isthmus, cleaned and filled to ensure predictable periapical healing²⁴.

In the present work, a high amount of isthmus was found in mesial-buccal roots of upper molars at 2.5 to 7.0 mm from the apex, which is in accordance

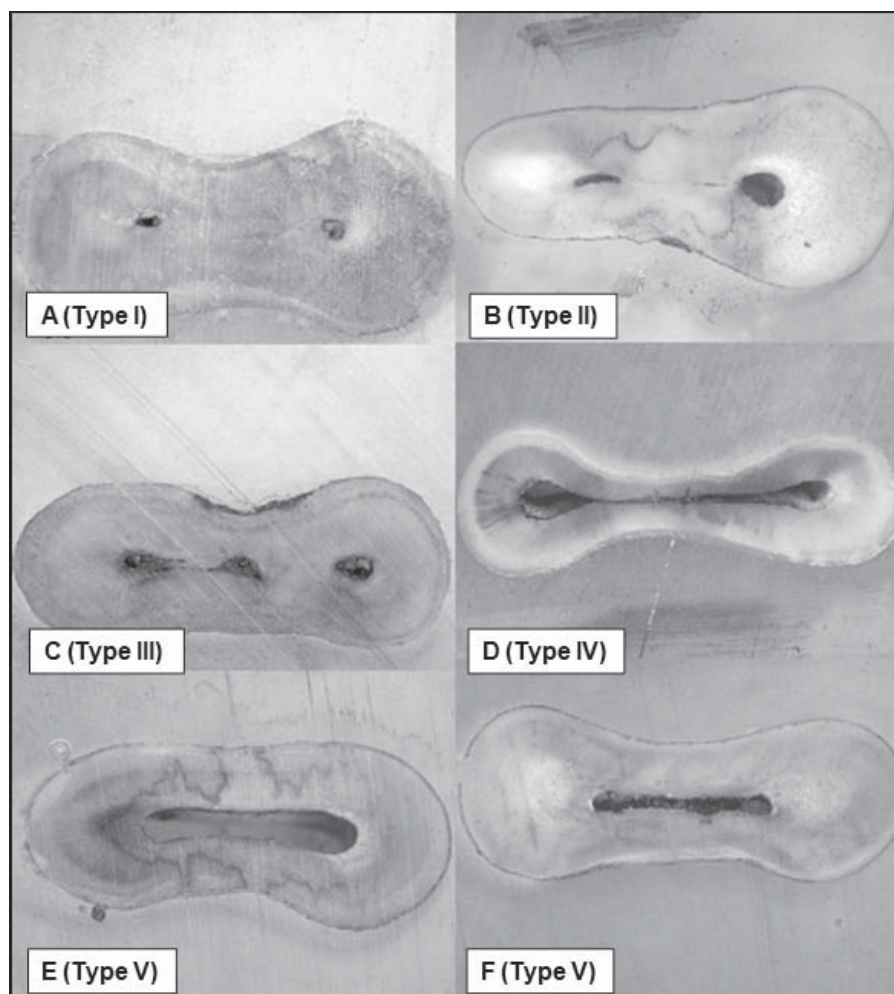


Figure 2- Isthmus: morphologic types in mesial roots of lower first molar. From A to D, types I to IV; E and F are type V

with previous reports^{6,20,26}. Lower molars showed a high incidence of isthmus, especially at 7 mm from the apex, while the highest prevalence of isthmus has been reported at 3 mm from the apex in the mesial root of lower first molars^{13,24}. However, a micro-computed tomographic analysis has revealed a high prevalence of isthmus (up to 81%) in the apical 6 mm of the mesial root of lower molars⁹. It is important to highlight that these above mentioned studies analyzed samples collected from different geographical locations, which might explain the variation in the results. In the present study, the analyzed extracted teeth were from a teeth bank in Brazil.

The closer to the apex, the lower was the incidence of isthmus observed in the upper and lower roots. Even though there was such a decrease, the percentage of isthmus found, particularly in the lower first molars, was still high, and must be clinically regarded as a complexity that might affect the outcome of the endodontic treatment.

An isthmus is formed when an individual root projection is unable to close itself off, forming a constriction. The approximation of the root projections can fuse completely and form one root

with one root canal system, as in the distobuccal root of maxillary molars. Alternately, partial fusion results in the formation of two root canals with an isthmus formed in between, such as the mesial root of the mandibular first molar. No fusion leads to a large ribbon shaped canal that contains an isthmus throughout the entire root, which is a common finding in the distal root of the mandibular first molars and maxillary second premolars¹¹.

The continuous deposition of dentine by odontoblasts throughout life accounts for the smaller areas of pulp found in older individuals. It might also be responsible for the different type of isthmus, which may explain the different results reported in the current literature. Types I and III have been reported to be the most frequently found isthmuses in mesial-buccal roots of first upper molars (37.5 and 31.2% respectively)¹⁶, whereas in the present study type V was found in higher incidence in the mesial-buccal roots of both first and second molars.

The existence of a type I isthmus is controversial because roots with two or three canals with no communication should not be considered as having isthmus. Type II isthmus shows no proper

communication between the canals, suggesting that dentin deposition sealed this pathway¹¹. However, if a type II had previously been a type V, it could display organic tissues, which might be hard to be eliminated by chemo-mechanical procedures. Also, when type III of isthmus is detected clinically, it can be often negotiated as an extra canal. In the present study its incidence comprised 7.2% to 13.8% in lower molars and 2.5% to 15% in upper molars.

Type IV suggests a partial isthmus with incomplete communication between the two main canals¹¹. This is of clinical relevance because special efforts are required in order to clean and seal this area. Type V is a complete isthmus with continuous opening between the two main root canals⁹. In fact, this type is the "real isthmus", presenting pulp tissues and demanding meticulously debridement and sealing. The continuous deposition of dentin even after tooth formation might keep organic tissues inside unfilled areas. These tissues are substrate for microorganisms that colonize areas usually difficult to be reached by endodontic instruments and antimicrobial substances, leading to failure of the root canal treatment/retreatment or even of the periapical surgery if the clinicians fail to remove them.

As the highest incidence of isthmus was found 2.5 to 7.0 mm from the apex, cautious preparation of the cervical and middle third of canals must be performed not only to remove infected tissues, but also to reduce interferences and provide better access to the apical third.

Canal isthmuses are often unnoticed and, when located, are difficult to be prepared. *Pendulum movements* of the instruments combined with antimicrobial substances and a copious irrigation optimized with ultrasound are procedures employed in the endodontic treatment of roots with isthmus to improve the disinfection of the area¹¹. Nowadays, the use of clinical microscopy for root canal treatment allows a higher detection of extra root canals⁵ and also enables proper visualization and cleaning of the isthmus, increasing the quality and success rates of the endodontic treatment³. Moreover, digital radiography, including advanced imaging techniques such as computed tomography (CT), micro-CT and cone beam volumetric imaging, provides three-dimensional information for either research or routine endodontic and surgical treatment planning without damaging the sample. Bringing it all together, a successful treatment is more expected when the experienced clinician has not only adequate armamentarium and technology but also a comprehensive knowledge of the root canal anatomy to guide both nonsurgical and surgical endodontic therapy²⁰.

CONCLUSIONS

It was concluded that isthmus was widely found in flat roots, with a low percentage in areas close to the apex. In upper and lower molars, these structures were most frequently found at 7 mm from the apex.

ACKNOWLEDGEMENTS

This study was supported by the Brazilian funding agencies Alagoas Research Foundation (FAPEAL), National Council for Scientific and Technological Development (CNPq) (302575/2009-0) & Coordination for the Improvement of Higher Education and Graduate Training Personnel (CAPES).

REFERENCES

- 1- Bolger W, Schindler WG. A mandibular first molar with a C-shaped root configuration. *J Am Dent Assoc.* 1998;14:515-9.
- 2- Cambuzzi JV, Marshall FJ. Molar endodontic surgery. *J Can Dent Assoc.* 1983;1:61-5.
- 3- Carr GB. Microscopes in endodontics. *J Calif Dent Assoc.* 1992;20:55-61.
- 4- Carrotte P. Endodontics: Part 1. The modern concept of root canal treatment. *Br Dent J.* 2004;197:181-3.
- 5- Coutinho Filho T, La Cerda RS, Gurgel Filho ED, De Deus GA, Magalhães KM. The influence of surgical operating microscope in locating the mesiolingual canal orifice: a laboratory analysis. *Braz Oral Res.* 2006;20:59-63.
- 6- Degerness RA, Bowles WR. Dimension, anatomy and morphology of the mesiobuccal root canal system in maxillary molars. *J Endod.* 2010;36:985-9.
- 7- Fan B, Pan Y, Gao Y, Fang F, Wu Q, Gutmann JL. Three-dimensional morphologic analysis of isthmuses in the mesial roots of mandibular molars. *J Endod.* 2010;36:1866-9.
- 8- Green D. Double canals in single roots. *Oral Surg.* 1973;35:689-96.
- 9- Gu L, Wei X, Ling J, Huang X. A microcomputed tomographic study of canal isthmuses in the mesial root of mandibular first molars in a Chinese population. *J Endod.* 2009;35:353-6.
- 10- Harris SP, Bowles WR, Fok A, McClanahan SB. An atomic investigation of the mandibular first molar using micro-computed tomography. *J Endod.* 2013;39:1374-8.
- 11- Hsu YY, Kim S. The resected root surface. The issue of canal isthmus. *Dent Clin North Am.* 1997;41:529-40.
- 12- Kontakiotis EG, Palamidakis FD, Farmakis ET, Tzanetakos GN. Comparison of isthmus detection methods in the apical third of mesial roots of maxillary and mandibular first molars: macroscopic observation versus operating microscope. *Braz Dent J.* 2010;21:428-31.
- 13- Mannocci F, Peru M, Sherriff M, Cook R, Pitt Ford TR. The isthmuses of the mesial root of mandibular molars: a micro-computed tomographic study. *Int Endod J.* 2005;38:558-63.
- 14- Pécora JD, Estrela C, Bueno MR, Porto OC, Alencar AH, Sousa-Neto MD, et al. Detection of root canal isthmuses in molars by map-reading dynamic using CBCT images. *Braz Dent J.* 2013;24:569-74.
- 15- Pineda F, Kuttler Y. Mesiobuccal and buccolingual roentgenographic investigation of 7275 root canals. *Oral Surg.* 1972;33:101-10.
- 16- Sauáia TS, Gomes BP, Pinheiro ET, Zaia AA, Ferraz CC, Souza-Filho FJ, et al. Thickness of dentine in mesial roots of mandibular molars with different lengths. *Int Endod J.* 2010;43:555-9.

- 17- Seo M S, Park D S. C-shaped root canals of mandibular second molars in a Korean population: clinical observation and *in vitro* analysis. *Int Endod J*. 2004;37:139-44.
- 18- Sicher H, Dubrul EL. *Oral anatomy*. St Louis: VC Mosby; 1975. p. 236-9.
- 19- Somma F, Leoni D, Plotino G, Grande NM, Plasschaert A. Root canal morphology of the mesiobuccal root of maxillary first molars: a micro-computed tomographic analysis. *Int Endod J*. 2009;42:165-74.
- 20- Tam A, Yu DC. Location of canal isthmus and accessory canals in the mesiobuccal root of maxillary first permanent molars. *J Can Dent Assoc*. 2002;68:28-33.
- 21- Teixeira FB, Sano CL, Gomes BP, Zaia AA, Ferraz CC, Souza-Filho FJ. A preliminary *in vitro* study of the incidence and position of the root canal isthmus in maxillary and mandibular first molars. *Int Endod J*. 2003;36:276-80.
- 22- Vertucci FJ. Root canal anatomy of the human permanent teeth. *Oral Surg*. 1984;58:589-99.
- 23- Villas-Bôas MH, Bernardineli N, Cavenago BC, Marciano M, Del Carpio-Perochena A, Moraes IG, et al. Micro-computed tomography study of the internal anatomy of mesial root canals of mandibular molars. *J Endod*. 2011;37:1682-6.
- 24- Von Arx T. Frequency and type of canal isthmuses in first molars detected by endoscopic inspection during periradicular surgery. *Int Endod J*. 2005;38:160-8.
- 25- Weller RN, Niemczyk SP, Kim S. Incidence and position of the canal isthmus. Part 1. Mesiobuccal root of the maxillary first molar. *J Endod*. 1995;21:380-3.
- 26- Yu DC, Tam A, Chen MH. The significance of locating and filling the canal isthmus in multiple root canal systems. A scanning electron microscopy study of the mesiobuccal root of maxillary first permanent molars. *J Can Dent Assoc*. 1998;29:261-5.