

Effect of Three Different Protocols of Low-Level Laser Therapy on Thyroid Hormone Production After Dental Implant Placement in an Experimental Rabbit Model

João Batista Blessmann Weber, PhD,¹ Luciano Mayer, PhD,¹ Rodrigo Alberto Cenci, MSc,¹ Carlos Eduardo Baraldi, PhD,² Deise Ponzoni, PhD,² and Marília Gerhardt de Oliveira, PhD³

Abstract

Objective: The purpose of this study was to assess the systemic effects of low-level laser therapy (LLLT) on thyroid gland function and, consequently, calcium regulation – as measured by serum triiodothyronine (T3), thyroxine (T4), and free calcium levels – when administered after dental implant placement in a rabbit model. **Background data:** Protocols for the use of laser therapy in several clinical procedures are currently under investigation, as not all of the actions and systemic effects of laser irradiation have been clearly established. **Materials and methods:** Forty male adult New Zealand rabbits were distributed across five groups of eight animals each: two control groups (C-I and C-II) of unirradiated animals, and three experimental groups (E-5, E-10, and E-20), each exposed to a distinct dose of gallium-aluminum-arsenide (GaAlAs) laser [$\lambda = 830$ nm, 50 mW, continuous wave (CW)] every 48 h for a total of seven sessions. The total dose per session was 5 J/cm² in E-5, 10 J/cm² in E-10, and 20 J/cm² in E-20. Animals in C-II and all experimental groups underwent surgical extraction of the mandibular left incisor followed by immediate placement of an osseointegrated implant (Nanotite[®], Biomet 3iTM) into the socket. Animals in group C-I served as an absolute control for T3, T4, and calcium measurements. The level of significance was set at 5% ($p \leq 0.05$). **Results:** ANOVA with Tukey's post-hoc test revealed significant differences in T3 and calcium levels among experimental groups, as well as significant within-group differences in T3, T4, and calcium levels over time. **Conclusions:** Although not reaching abnormal values, LLLT applied to the mandible influenced thyroid function in this model.

Introduction

LASER-EMITTING DEVICES ARE MORE COMMONLY USED by health professionals, mostly for therapeutic and diagnostic purposes. In dentistry, the use of lasers of different wavelengths for distinct indications in the field of oral health has enabled incorporation of laser technology into a wide range of clinical and surgical procedures,^{1,2} even though the levels of evidence to support their clinical application are low.

Indication for low-level laser therapy (LLLT) is based on the stimulating effects on the molecular and biochemical processes during tissue repair at the cellular level. Previous studies have evaluated the irradiation of extraction sockets,³ modulation of skin wound healing,⁴⁻⁶ regeneration of ner-

vous tissue,⁵ enhancement of peri-implant tissue repair after implant placement,^{2,7-16} and modulation of postoperative pain.^{2,7,17-24} Other *in vivo* and *in vitro* studies have reported the positive effects of LLLT on the repair process in animal models and tissue cultures.^{4,22,25} However, there are large variations in laser doses,^{7-15,26} even though dose is considered an important parameter in laser therapy,²⁷ especially when some specific biomodulatory effects are expected.

These biomodulatory effects of laser may also occur remotely from the site of irradiation.^{5,28-30} Therefore, LLLT may lead to effects on organs and tissues far from the actual site of application (systemic effects). The literature suggests that LLLT may have repercussions on endocrine function because of potential effects on the secretory glands,³¹ including the thyroid gland. Studies on the effect of infrared

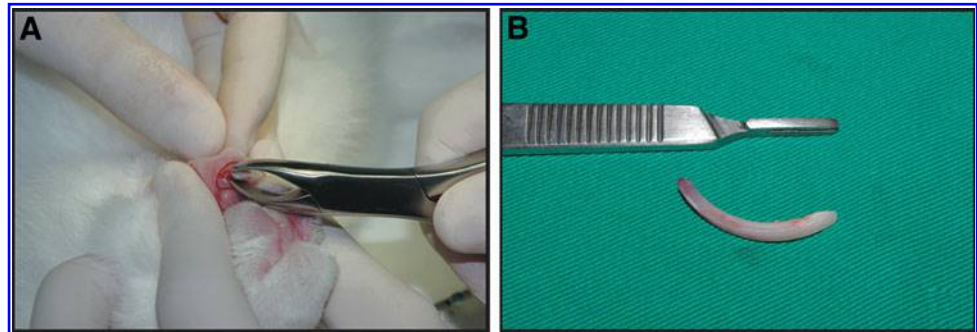
¹School of Dentistry, Pontifícia Universidade Católica do Rio Grande do Sul (PUCRS), Porto Alegre, RS, Brazil.

²School of Dentistry, Universidade Federal do Rio Grande do Sul, Porto Alegre, RS, Brazil.

³Maxillofacial Surgery Service, Hospital Cristo Redentor – Grupo Hospitalar Conceição (GHC), Porto Alegre, RS, Brazil.

The study was conducted at Pontifícia Universidade Católica do Rio Grande do Sul (PUCRS) and Universidade Federal do Rio Grande do Sul (UFRGS), Porto Alegre, RS, Brazil.

FIG. 1. Surgical procedure: (A) Extraction with #5 pediatric extraction forceps. (B) Freshly extracted mandibular left incisor.



laser irradiation directly on the thyroid gland have shown increased mitotic activity in follicular cells, transient hyperactivity of some thyroid follicles,^{32,33} and changes in circulating serum levels of the hormones secreted by the thyroid gland, triiodothyronine (T3) and thyroxine (T4).³⁴⁻³⁶

These findings prompted the present study, as the thyroid gland is located near the mandibular region, a frequent site of irradiation after dental procedures. The objective of this study was to assess the side effects or systemic effects of LLLT used after mandibular dental implant insertion to improve osseointegration through a systematic assessment of circulating serum levels of T3, T4, and calcium in a rabbit model after three different protocols of low-level laser irradiation of the area of implantation of the osseointegrated implant placed immediately into the fresh extraction socket of the mandibular left incisor.

Materials and Methods

This study was approved by the Pontifícia Universidade Católica do Rio Grande do Sul (PUCRS), Animal Experimentation Ethics Committee with protocol no. 11/00235. All study procedures were conducted so as to minimize pain or discomfort, and all were in compliance with the Brazilian Ethical Principles for Animal Experimentation, as set forth in Law 11.794 (October 8, 2008) and the Ethical Principles of Experimental Research set forth by the Brazilian Society for Laboratory Animal Science (formerly the Brazilian College of Animal Testing).

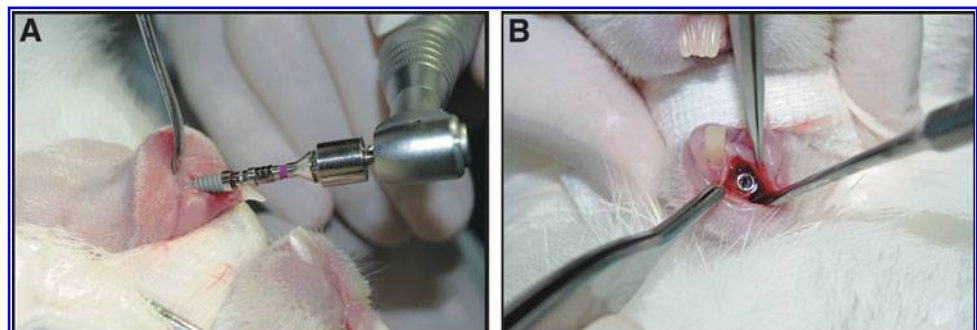
The study sample comprised 40 male adult New Zealand rabbits (*Oryctolagus cuniculus*), 3 months of age, weighing 3–4 kg. Animals were allocated randomly into five distinct groups of eight rabbits each: three experiment groups, E-5, E-10, and E-20, and two control groups, C-I and C-II. Animals were fed solid chow (Purina[®]) and water *ad libitum*,

and were kept in a climate-controlled environment, under normal lighting, humidity, and temperature conditions. All animals (except those in group C-I) underwent surgical extraction of the mandibular left incisor and immediate placement of an osseointegrated implant, creating a condition of equality between groups at baseline.

General anesthesia was induced, the mandibular left incisor region was disinfected and anesthetized by local infiltration, and the tooth was extracted (Fig. 1). After gradual, intermittent, and precise preparation of the implant socket with sequentially sized drills, according to manufacturer instructions, a 3.25 \times 11.5 mm NanoTite[®] osseointegrated implant (Biomet3i, Palm Beach Gardens, FL) was placed into the socket (Fig. 2). The surgical wound was closed with 4-0 monofilament (Ethicon[®], Johnson & Johnson). While animals were still under general anesthesia, those in the experimental groups were shaved and tattooed with a surgical marker (Codman[®]) over the region corresponding to the long axis of the dental implant, creating a target for gallium-aluminum-arsenide (GaAlAs) laser irradiation (Fig. 3). At the end of the procedure, all animals were placed on a 3 day course (once a day) of analgesia (tramadol, 5 mg/kg IM) and antimicrobial prophylaxis (enrofloxacin, 5 mg/kg IM).

Laser therapy was performed with a GaAlAs infrared diode laser, wavelength 830 nm, power 50 mW, in continuous emission mode (Thera Lase[®], DMC Equipamentos, São Carlos, SP, Brazil). In the experimental groups, the irradiation protocol was started immediately after extraction of the mandibular left incisor and placement of the osseointegrated implant. Unirradiated animals (control groups) underwent sham irradiation with the laser device unpowered; all other procedures were performed as in the other groups. During laser and sham treatments, the animals were restrained in a box (suitable to their sizes), and a gauze pad was placed over their eyes for protection and to ensure that the animals would

FIG. 2. Surgical procedure: (A) Placement of a 3.25 \times 11.5 mm osseointegrated implant (NanoTite[®]). (B) Occlusal view after implant placement.



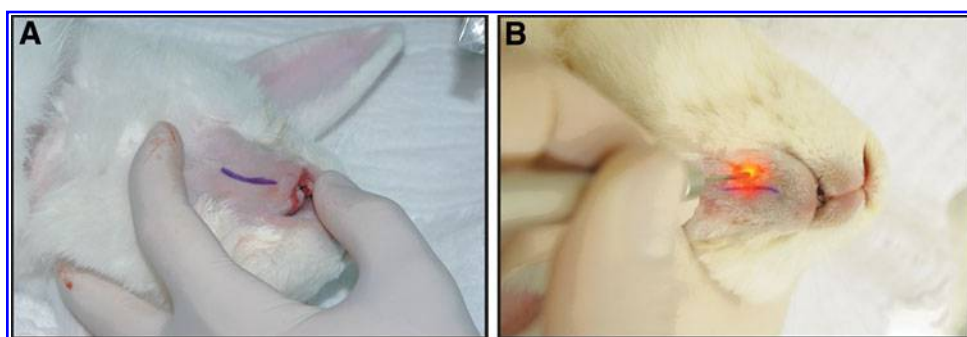


FIG. 3. Low-level laser therapy (LLLT): (A) Long axis of the implant (Nano-Tite[®]) tattooed onto the skin. (B) Application of low-level laser with the handpiece perpendicular to, but not directly over, the long axis of the implant.

remain calm (Supplementary Fig. S1; Supplementary data are available online at www.liebertonline.com/pho).

Animals in group E-5 received two spot doses of 2.5 J/cm^2 , applied over two points: one medial and one lateral to the long axis of the implant as previously marked on the skin (Fig. 3). Application was performed with the laser handpiece held perpendicular to the basal bone of the mandible, for a total dose of 5 J/cm^2 per session, over an irradiation time of 51 sec (irradiation time was adjusted automatically by the laser unit after the other parameters were set). Animals in group E-10 received double the dose administered to group E-5 (5 J/cm^2 per spot), over an irradiation time of 1 min 41 sec, for a total dose of 10 J/cm^2 per session. Group E-20 received quadruple the initial dose: 10 J/cm^2 for a total of 20 J/cm^2 per session, over an irradiation time of 3 min 21 sec.

In all experimental groups, irradiation was performed every 48 h, for a total of seven sessions over 13 days, with total cumulative doses of 35 J/cm^2 for group E-5, 70 J/cm^2 for group E-10, and 140 J/cm^2 for group E-20 (Table 1).

Using methods similar to those of Mebis et al.³⁷ and Fronza et al.,³⁸ levels of T3, T4, and calcium were measured in all animals at four points in time: before dental extraction/implant placement; immediately after surgery; after the first LLLT session; and after the last LLLT session. Blood samples (3 mL per collection) were obtained by venipuncture of the jugular vein. Blood was collected into anticoagulant-free Vacutainer[®] tubes (BD-Vacutainer[®], Pediatric Systems, Becton & Dickinson Co), which were centrifuged in an appropriate apparatus (Excelsa[®] 3 Model 280 benchtop centrifuge; FANEM Ltda., São Paulo, SP, Brazil) for 15 min at 3000 rpm, at constant temperature and pressure. Serum was then separated and pipetted into Eppendorf[®] (Eppendorf[®]

3810X standard; Eppendorf do Brasil Ltda., São Paulo, SP, Brazil) tubes, which were sent under refrigeration to the Veterinary Clinical Chemistry Laboratory, Universidade Federal do Rio Grande do Sul (LacVet – UFRGS, Porto Alegre, Brazil), for measurement of T3, T4, and calcium levels.

Statistical analyses were performed in SPSS[®] 17.0 (Statistical Package for the Social Sciences, SPSS Inc., Chicago, IL) and SAS[®] 8.0 (Statistical Analysis System, SAS Institute Inc., Cary, NC). The level of significance was set at 5% ($p \leq 0.05$). Repeated measures analysis of variance (ANOVA) with Tukey's post-hoc multiple comparisons test was used for between-subject and between-group comparisons of laboratory values.

Results

The baseline levels for all animals (time point 1) and the results of serum T3, T4, and calcium measurements during LLLT (time points 2 and 3) and after LLLT (time point 4) are described in Table 2.

Separate assessment of each of the laboratory parameters of interest showed that T3, T4, and calcium levels were significantly altered between study groups in relation to LLLT therapy.

Analysis of the behavior of calcium levels showed that, in addition to within-group differences over time for experimental groups (E-5, E-10, and E-20), significant differences also occurred between the control and experimental (LLLT) groups at the first and last time points of collection. Between-group comparisons showed a significant difference in calcium levels at time points 1 and 4 between LLLT groups and control groups (C-I and C-II) (Table 2).

TABLE 1. STUDY PARAMETERS

	CI and CII control groups (n = 16)	E-5 group (n = 8)	E-10 group (n = 8)	E-20 group (n = 8)
Light source type	—	Laser (AlGaAs)	Laser (AlGaAs)	Laser (AlGaAs)
Average power (mW)	—	50	50	50
Wavelength (nm)	—	830	830	830
Pulse parameters	—	CW	CW	CW
Irradiation points	0	2	2	2
No. applications per point	0	1	1	1
Energy per point (J/cm^2)	0	2.5	5	10
Total energy density per session (J/cm^2)	0	5	10	20
Irradiation time per point (sec)	0	51	101	201
Total dose (J/cm^2)	0	35	70	140

TABLE 2. STATISTICAL ANALYSIS: RESULTS OF SERUM T3, T4, AND CALCIUM MEASUREMENT

	Group	Energy	Time 1	Time 2	Time 3	Time 4
Calcium	C-I	0 J/cm ²	14.01 ± 1.02 ^{A-a}	13.82 ± 0.62 ^{A-a}	13.67 ± 0.72 ^{A-a}	13.72 ± 0.70 ^{A-ab}
	C-II	0 J/cm ²	12.82 ± 0.27 ^{A-b}	13.63 ± 0.75 ^{A-a}	13.53 ± 0.19 ^{A-a}	13.65 ± 0.62 ^{A-ab}
	E-5	5 J/cm ²	13.47 ± 0.34 ^{B-ab}	14.41 ± 0.55 ^{A-a}	13.91 ± 0.31 ^{AB-a}	13.59 ± 0.70 ^{AB-ab}
	E-10	10 J/cm ²	13.05 ± 0.32 ^{C-ab}	13.95 ± 0.55 ^{AB-a}	13.79 ± 0.27 ^{BC-a}	14.46 ± 0.47 ^{A-a}
	E-20	20 J/cm ²	13.81 ± 0.26 ^{AB-ab}	14.39 ± 0.28 ^{A-a}	13.43 ± 0.30 ^{B-a}	13.41 ± 0.73 ^{B-b}
Triiodothyronine T3	C-I	0 J/cm ²	162.07 ± 30.04 ^{A-a}	151.97 ± 15.30 ^{A-a}	151.89 ± 22.41 ^{A-a}	165.04 ± 20.43 ^{A-b}
	C-II	0 J/cm ²	143.07 ± 17.42 ^{B-a}	168.98 ± 23.19 ^{AB-a}	181.57 ± 23.63 ^{AB-a}	198.64 ± 52.62 ^{A-ab}
	E-5	5 J/cm ²	144.32 ± 13.34 ^{A-a}	175.64 ± 25.15 ^{A-a}	179.23 ± 40.07 ^{A-a}	163.02 ± 22.85 ^{A-b}
	E-10	10 J/cm ²	163.42 ± 26.86 ^{B-a}	193.90 ± 28.62 ^{AB-a}	165.68 ± 43.81 ^{B-a}	223.86 ± 40.26 ^{A-a}
	E-20	20 J/cm ²	166.72 ± 39.68 ^{A-a}	182.80 ± 19.05 ^{A-a}	185.94 ± 38.77 ^{A-a}	196.96 ± 52.35 ^{A-ab}
Thyroxine T4	C-I	0 J/cm ²	2.56 ± 0.71 ^{AB-a}	2.29 ± 0.35 ^{B-a}	2.98 ± 0.67 ^{AB-a}	3.29 ± 0.19 ^{A-a}
	C-II	0 J/cm ²	2.30 ± 0.56 ^{B-a}	3.03 ± 0.56 ^{AB-a}	2.69 ± 0.66 ^{AB-a}	3.18 ± 0.65 ^{A-a}
	E-5	5 J/cm ²	2.19 ± 0.73 ^{B-a}	3.05 ± 0.79 ^{A-a}	3.29 ± 0.92 ^{A-a}	3.07 ± 0.47 ^{A-a}
	E-10	10 J/cm ²	2.40 ± 0.83 ^{A-a}	2.73 ± 0.85 ^{A-a}	2.75 ± 0.79 ^{A-a}	3.12 ± 0.84 ^{A-a}
	E-20	20 J/cm ²	2.75 ± 0.82 ^{A-a}	3.29 ± 0.93 ^{A-a}	3.39 ± 1.20 ^{A-a}	3.37 ± 0.71 ^{A-a}

Baseline levels expressed as mean ± standard deviations. Means followed by different uppercase superscript letters across the same row denote significant differences. Means followed by different lowercase superscript letters across the same column denote significant differences on repeated measures. Analysis of variance (ANOVA) with Tukey's multiple comparisons test, for a significance level of 5% ($p \leq 0.05$).

Significant differences in the behavior of T3 levels were detected over time in groups C-II and E-10 and between groups at time point 4, that is, at the end of the experiment (72 h after the last LLLT session) (Table 2).

Assessment of the five study groups over time revealed significant differences in T4 levels in groups C-I, C-II, and E-5. Within-group comparisons showed no statistically significant or clinically relevant changes that could be attributed to laser therapy or surgical intervention.

Discussion

Indications for use of LLLT are increasing in dental procedures, despite the low evidence levels supporting its application. It has been proven a safe therapy, from a local point of view, and most studies report no harmful effects for the target tissues, as well as positive effects on healing. Unfortunately, this given safety invites the overindication of LLLT, as well as the lack of evidence-based support for indications and delivering protocols. Researchers should be aware of the possible systemic and cumulative effects of LLLT on health, as well as of systemically affected patients.

The present investigation is part of a more comprehensive project evaluating the effects of LLLT on osseointegration. Any other surgical or nonsurgical model applying LLLT could be used to investigate systemic effects, as LLLT is increasingly used in clinical settings. The main issue discussed here is the anatomical proximity between the irradiated structures of the lower face and the thyroid gland, which is the nearest hormonal secretory gland to the oral tissues. Fronza et al.³⁸ have recently described a similar experiment after mandibular incisive extraction, using 6 J/cm² per session applied to the socket.

The best laser aimed at improving bone healing seems to be the GaAlAs diode laser ($\lambda = 830$ nm), because of its greater tissue penetration and cell influence. Other wavelengths without this property have shown no effects on bone healing.¹² We assumed that LLLT applied to the lower face could lead to indirect exposure of the thyroid gland, as

830 nm wavelength lasers can reach deeper planes and exert both local and systemic effects.^{5,6,28-30,36,38}

The rabbit model was chosen because of the previously reported ease of handling, surgical preparation, and post-operative follow-up.^{8,28,34,38} Moreover, the size of these animals enabled the use of conventional implants available for clinical use in humans. As for implant placement in fresh tooth extraction sockets, we chose this method of implant placement, rather than the tibia (which is the most common site reported in the literature), in order to provide the closest possible simulation of a clinical situation. This method is also more reliable, as the mandibular alveolar bone is subjected to different forces than the rabbit tibia³⁹. The size of animals also enabled the collection of blood samples in volumes required for laboratory analysis. These procedures would not be possible in rats or mice.^{9,10,13,40} In accordance with the most recent literature, LLLT was delivered by an infrared laser^{7-15,26-28,35,38} of 830 nm wavelength^{7,10,12-15} and 50 mW output power in two sites near the mandibular implant, in seven sessions^{7,11,12,15} every 48 h, using three different doses. The use of a sham surgery and sham LLLT control group (C-I), as well as a baseline surgery but sham LLLT group (C-II), enabled us to isolate both the influence of baseline surgery and the systemic effects of LLLT. This design eliminated potential bias in laboratory values that could be attributed to surgical intervention. Although these animals did not receive any treatment, they provided a reference standard against which laboratory values from experimental animals (operated, irradiated, and unirradiated) could be compared.

The type of comparison that we presented here would not have been possible with a split-mouth design² or a subject-as-own-control design.¹⁴ Moreover, the C-I group was as an absolute control for T3, T4, and calcium levels, as these animals were not subjected to surgical intervention or laser therapy, only to blood collection.

Thyroid function is usually assessed by measurement of baseline serum levels of thyroid hormones. Radioimmunoassay (RIA) is one of several methods available for

hormone measurement, and has been used by some investigators for determination of circulating T3 and T4 concentrations.⁴⁰ Its advantages include high sensitivity and greater ease of batch testing, as the tubes provided in most RIA kits are coated with the specific antibody required for the assay, thus cutting down on manual operations, facilitating the separation process and reducing the odds of error.⁴¹ Variations in T3 and T4 levels would trigger a cascade of events that would, in turn, lead to changes in circulating calcium levels, which justifies their measurement. In the present experimental model, LLLT did lead to changes in T3, T4, and calcium levels. There were significant between-group differences in T3 and calcium levels, whereas the other parameters remained essentially similar between groups. Therefore, LLLT had an influence on thyroid hormone levels, in addition to variations occurring over time during the experimental period.

We found significant differences in thyroid hormone levels after LLLT, from time points 1–4. These findings differed from those reported by Lerma et al.⁴⁰ after helium-neon (HeNe) LLLT in the thyroid gland of Wistar rats, who found no difference in serum levels of thyroid hormones. Likewise, Fronza et al.³⁸ found no significant differences in serum T3 and T4 levels after 6 J/cm² GaAlAs LLLT applied to a rabbit fresh incisor socket experimental model. However, our findings do corroborate those of Azevedo et al.,²⁵ who administered three doses of 4 J/cm² GaAlAs 780 nm LLLT directly over the thyroid gland in mice. Those authors found significant differences in T3 and T4 levels between the baseline and after the last session of LLLT.

Notably, the use of different LLLT protocols hinders interpretation of the effects of laser on thyroid gland function, as well as comparison of the values of other variables among studies. It is known that better-defined protocols are needed to improve the reliability of comparisons, thus enabling proper conduction of studies that can ascertain the true effects of laser radiation on living tissues, organs, and systems.¹

Although the results of this study are encouraging and indicative of the feasibility of safe nonablative laser irradiation of regions near the thyroid gland, further studies using different laser dosages, power settings, and periods of irradiation are warranted to provide a better understanding of the effects of LLLT on thyroid function. It is also important to consider samples composed of subjects with thyroid comorbidities, such as hyperthyroidism or hypothyroidism.³⁵

Conclusions

The objective of this study was to assess the side effects or systemic effects of LLLT used to improve osseointegration after mandibular dental implant insertion, through a systematic assessment of circulating serum levels of T3, T4, and calcium in a rabbit model after three different protocols of low-level laser irradiation of the area of implantation of the osseointegrated implant placed immediately into the fresh extraction socket of the mandibular left incisor. Despite a significant impact on serum T3, T4, and calcium levels, the LLLT protocols tested herein did not lead to permanent impairment of thyroid function.

In conclusion, the results presented herein show that the different laser irradiation protocols used to speed the osseointegration process of titanium dental implants in an

experimental rabbit model were associated with changes in systemic levels of thyroid hormones. However, although not reaching abnormal values, LLLT applied to the mandible (near a secretory gland) influenced thyroid function in this model.

Author Disclosure Statement

No competing financial interests exist.

References

- Basford, J.R. (1986). Low-energy laser treatment of pain and wounds: hype, hope, or hokum? *Mayo Clin. Proc.* 61, 671–675.
- García-Morales, J.M., Tortamano-Neto, P., Todescan, F.F., de Andrade, J.C., Jr., Marotti, J., and Zezell, D.M. (2012). Stability of dental implants after irradiation with an 830-nm low-level laser: a double-blind randomized clinical study. *Lasers Med. Sci.* 27, 703–711.
- Takeda, Y. (1988). Irradiation effect of low-energy laser on alveolar bone after tooth extraction. *Experimental study in rats.* *Int. J. Oral Maxillofac. Surg.* 17, 388–391.
- Corazza, A.V., Jorge, J., Kurachi, C., Bagnato, V.S. (2007). Photobiomodulation on the angiogenesis of skin wounds in rats using different light sources. *Photomed. Laser Surg.* 25, 102–106.
- Rochkind, S., Rousso, M., Nissan, M., Villarreal, M., Barr-Nea, L., and Rees, D.G. (1989). Systemic effects of low-power laser irradiation on the peripheral and central nervous system, cutaneous wounds, and burns. *Lasers Surg. Med.* 9, 174–182.
- Rodrigo, S.M., Cunha, A., Pozza, D.H., et al. (2009). Analysis of the systemic effect of red and infrared laser therapy on wound repair. *Photomed. Laser Surg.* 27, 929–935.
- Campanha, B.P., Gallina, C., Geremia, T., et al. (2010). Low-level laser therapy for implants without initial stability. *Photomed. Laser Surg.* 28, 365–369.
- Khadra, M., Ronold, H.J., Lyngstadaas, S.P., Ellingsen, J.E., and Haanaes, H.R. (2004). Low-level laser therapy stimulates bone-implant interaction: an experimental study in rabbits. *Clin. Oral Implants Res.* 15, 325–332.
- Kim, Y.D., Kim, S.S., Hwang, D.S., et al. (2007). Effect of low level laser treatment after installation of dental titanium implant-immunohistochemical study of vascular endothelial growth factor: an experimental study in rats. *Laser Phys. Lett.* 4, 681–685.
- Kim, Y.D., Kim, S.S., Hwang, D.S., et al. (2007). Effect of low-level laser treatment after installation of dental titanium implant-immunohistochemical study of RANKL, RANK, OPG: an experimental study in rats. *Lasers Surg. Med.* 39, 441–450.
- Lopes, C.B., Pinheiro, A.L., Sathaiyah, S., Duarte, J., and Cristinamartins, M. (2005). Infrared laser light reduces loading time of dental implants: a Raman spectroscopic study. *Photomed. Laser Surg.* 23, 27–31.
- Lopes, C.B., Pinheiro, A.L., Sathaiyah, S., Da Silva, N.S., and Salgado, M.A. (2007). Infrared laser photobiomodulation (lambda 830 nm) on bone tissue around dental implants: a Raman spectroscopy and scanning electronic microscopy study in rabbits. *Photomed. Laser Surg.* 25, 96–101.
- Maluf, A.P., Maluf, R.P., Brito Cda, R., Franca, F.M., and de Brito, R.B., Jr. (2010). Mechanical evaluation of the

- influence of low-level laser therapy in secondary stability of implants in mice shinbones. *Lasers Med. Sci.* 25, 693–698.
14. Pereira, C.L., Sallum, E.A., Nociti, F.H., Jr., and Moreira, R.W. (2009). The effect of low-intensity laser therapy on bone healing around titanium implants: a histometric study in rabbits. *Int. J. Oral Maxillofac. Implants* 24, 47–51.
 15. Lopes, C.B., Sathaiyah, S., Pinheiro, A.L.B., Duarte, J., and Martins, M.C. (2003). Laser biomodulation in bone implants: a Raman spectral study. *Int. Congr. Ser.* 1248, 449–451.
 16. Dörtbudak, O., Haas, R., and Mailath-Pokorny, G. (2002). Effect of low-power laser irradiation on bony implant sites. *Clin. Oral Implants Res.* 13, 288–292.
 17. Rigau, J., Trelles, M.A., Calderhead, R.G., and Mayayo, E. (1991). Changes in fibroblast proliferation and metabolism following in vitro helium-neon laser irradiation. *Laser Ther.* 3, 25–33.
 18. Silva Junior, A.N., Pinheiro, A.L., Oliveira, M.G., Weismann, R., Ramalho, L.M., and Nicolau, R.A. (2002). Computerized morphometric assessment of the effect of low-level laser therapy on bone repair: an experimental animal study. *J. Clin. Laser Med. Surg.* 20, 83–87.
 19. do Nascimento, P.M., Pinheiro, A.L., Salgado, M.A., and Ramalho, L.M. (2004). A preliminary report on the effect of laser therapy on the healing of cutaneous surgical wounds as a consequence of an inversely proportional relationship between wavelength and intensity: histological study in rats. *Photomed. Laser Surg.* 22, 513–518.
 20. Weber, J.B., Pinheiro, A.L., de Oliveira, M.G., Oliveira, F.A., and Ramalho, L.M. (2006). Laser therapy improves healing of bone defects submitted to autologous bone graft. *Photomed. Laser Surg.* 24, 38–44.
 21. Mohammed, I.F., Al-Mustawfi, N., and Kaka, L.N. (2007). Promotion of regenerative processes in injured peripheral nerve induced by low-level laser therapy. *Photomed. Laser Surg.* 25, 107–111.
 22. Soares, L.P., Oliveira, M.G., Pinheiro, A.L., Fronza, B.R., and Maciel, M.E. (2008). Effects of laser therapy on experimental wound healing using oxidized regenerated cellulose hemostat. *Photomed. Laser Surg.* 26, 10–13.
 23. Freddo, A.L., Rodrigo, S.M., Massotti, F.P., Etges, A., and de Oliveira, M.G. (2009). Effect of low-level laser therapy after implantation of poly-L-lactic/polyglycolic acid in the femurs of rats. *Lasers Med. Sci.* 24, 721–728.
 24. Bensadoun, R.J., and Nair, R.G. (2012). Efficacy of low-level laser therapy (LLLT) in oral mucositis: what have we learned from randomized studies and meta-analyses? *Photomed. Laser Surg.* 30, 191–192.
 25. Azevedo, L.H., de Paula Eduardo, F., Moreira, M.S., de Paula Eduardo, C., and Marques, M.M. (2006). Influence of different power densities of LILT on cultured human fibroblast growth: a pilot study. *Lasers Med. Sci.* 21, 86–89.
 26. Jakse, N., Payer, M., Tangl, S., Berghold, A., Kirmeier, R., and Lorenzoni, M. (2007). Influence of low-level laser treatment on bone regeneration and osseointegration of dental implants following sinus augmentation. An experimental study on sheep. *Clin. Oral Implants Res.* 18, 517–524.
 27. Pinheiro, A.L. (2009). Advances and perspectives on tissue repair and healing. *Photomed. Laser Surg.* 27, 833–836.
 28. Coelho, R.C., Zerbinati, L.P., Oliveira, M.G., and Weber, J.B. (2014). Systemic effects of LLLT on bone repair around PLLA-PGA screws in the rabbit tibia. *Lasers Med. Sci.* 29, 703–708.
 29. Karu, T. (1989). Photobiology of low-power laser effects. *Health Phys.* 56, 691–704.
 30. Schindl, A., Heinze, G., Schindl, M., Pernerstorfer-Schon, H., and Schindl, L. (2002). Systemic effects of low-intensity laser irradiation on skin microcirculation in patients with diabetic microangiopathy. *Microvasc. Res.* 64, 240–246.
 31. Smith-Agreda, V., Ferres, E., Renovell, A., et al. (1985). [Contributions to the study of morphological and chemical interactions of anterior pituitary cells after stimulation with low-power He/Ne laser (632.8 nm)]. [Article in Spanish]. *Invest. Clín. Laser.* 2, 51–62.
 32. Parrado, C., Peláez, A., Vidal, L., and Pérez de Vargas, I. (1990). Quantitative study of the morphological changes in the thyroid gland following IR laser radiation. *Lasers Med. Sci.* 5, 77–80.
 33. Parrado, C., Carrillo de Albornoz, F., Vidal, L., and Perez de Vargas, I. (1999). A quantitative investigation of microvascular changes in the thyroid gland after infrared (IR) laser radiation. *Histol. Histopathol.* 14, 1067–1071.
 34. Azevedo, L.H., Aranha, A.C., Stolf, S.F., Eduardo Cde, P., and Vieira, M.M. (2005). Evaluation of low intensity laser effects on the thyroid gland of male mice. *Photomed. Laser Surg.* 23, 567–570.
 35. Höfling, D.B., Chavantes, M.C., Juliano, A.G., et al. (2013). Low-level laser in the treatment of patients with hypothyroidism induced by chronic autoimmune thyroiditis: a randomized, placebo-controlled clinical trial. *Lasers Med. Sci.* 28, 743–753.
 36. Höfling, D.B., Chavantes, M.C., Juliano, A.G., et al. (2010). Low-level laser therapy in chronic autoimmune thyroiditis: a pilot study. *Lasers Surg. Med.* 42, 589–596.
 37. Mebis, L., Eerdeken, A., Güiza, F., et al. (2012). Contribution of nutritional deficit to the pathogenesis of the nonthyroidal illness syndrome in critical illness: a rabbit model study. *Endocrinology* 153, 973–984.
 38. Fronza, B., Somacal, T., Mayer, L., de Moraes, J.F., de Oliveira, M.G., and Weber, J.B. (2013). Assessment of the systemic effects of low-level laser therapy (LLLT) on thyroid hormone function in a rabbit model. *Int. J. Oral Maxillofac. Surg.* 42, 26–30.
 39. de Jong, W.C., Korfage, J.A., and Langenbach, G.E. (2010). Variations in habitual bone strains in vivo: long bone versus mandible. *J. Struct. Biol.* 172, 311–318.
 40. Lerma, E., Hevia, A., Rodrigo, P., Gonzalez-Campora, R., Armas, J.R., and Galera, H. (1991). The effect of HeNe laser radiation on the thyroid gland of the rat. *Int. J. Exp. Pathol.* 72, 379–385.
 41. Steinbeck, M.J., and Wyner, L.R. (1993). Immunoassay and related principles, in: *Clinical chemistry: concepts and applications*. S.C. Anderson, and S. Cockayne (eds.). Philadelphia: HBJ International Edition, W. B. Saunders, pp. 96–99.

Address correspondence to:
 Marília Gerhardt de Oliveira
 Rua Visconde do Herval
 725/404B, Menino Deus
 90130-151 – Porto Alegre, RS
 Brazil

E-mail: gerhardtoliveira@gmail.com