

Comparison of lyophilization, and freezing in honey as techniques to preserve cortical bone allografts used to repair experimental femoral defects in domestic adult cats

[*Comparação de enxerto ósseo cortical autógeno e implante ósseo cortical alógeno conservados no mel, congelados ou liofilizados na substituição de segmento diafisário do fêmur de gatos domésticos*]

M.P. Ferreira, M.M. Alievi, C.A.C. Beck, I.S. Dal-Bó, P.C. Gonzalez, F.S. Nóbrega, L.M. Silva, R. Stédile, S. Scherer, J.P.V. Rocha, A.P.F. Silva Filho, B. Svierk, G. Costa

Faculdade de Veterinária - Universidade Federal do Rio Grande do Sul - Porto Alegre, RS

ABSTRACT

Cats with orthopedic conditions are a prominent part of the clinical work of veterinary. Conditions such as comminuted fractures, bone tumors and non-unions are often difficult to repair and may require the use of bone grafts for treatment. This study evaluated cortical bone allografts preserved in honey, frozen or lyophilized for correcting long bone defects created in the diaphysis of the right femur of domestic cats (n=24). In the control group (n=6), the defect was repaired using autogenous cortical bone graft. In the remaining animals (n=6/group), the defect was repaired with cortical bone allografts preserved in honey, frozen or lyophilized. Success of graft incorporation and length of time for consolidation were assessed through clinical, radiographic and histological evaluations performed up to 180 days. In the control, frozen, honey and lyophilized groups, respectively, success of graft incorporation was 91.6%, 83.3%, 75%, and 25%, with corresponding mean length of time for consolidation of 83.1, 78, 105 and 120 days. Incorporation percentage in the lyophilized group was significantly lower than in the frozen and control groups. In conclusion, bone grafts preserved in honey or frozen were effective for repairing cortical defects in the femurs of cats as compared to autogenous cortical bone grafts.

Keywords: preservation, bone, animal, orthopedic, traumatology

RESUMO

Afeções ortopédicas em gatos são frequentes, podendo-se encontrar fraturas cominutivas, neoplasias ósseas ou não-uniões de fraturas. Uma opção para o tratamento dessas afecções é a utilização de enxerto ou implante ósseo. O objetivo deste trabalho foi avaliar implantes ósseos corticais alógenos conservados em mel, congelados ou liofilizados na substituição de segmento diafisário do fêmur de felinos. Foi confeccionada uma falha óssea na diáfise do fêmur de 24 felinos. Em seis felinos a falha foi preenchida com o próprio osso removido e nos outros 18 animais, com implantes ósseos corticais alógenos conservados em mel, congelados ou liofilizados. Os animais foram avaliados clínica, radiográfica e histologicamente durante 180 dias. A incorporação foi de 91,6% no grupo controle, com tempo médio para consolidação de 83,1 dias; no mel foi de 75%, com tempo médio de 105 dias; no congelado foi de 83,3% com tempo médio de 78 dias e no liofilizado foi de 25%, com tempo médio de 120 dias. A porcentagem de consolidação foi significativamente menor no grupo liofilizado em relação aos grupos congelado e controle. É possível concluir que os implantes ósseos autógenos e os conservados no mel e congelados são eficazes no preenchimento de defeito cortical em fêmur de felinos.

Palavras-chave: conservação, osso, animal, ortopedia, traumatologia

INTRODUCTION

Veterinary traumatologists frequently admit animals with comminuted fractures of long bones, apart from bone tumors, non-unions and

malunions. One of the main ways of treating these conditions consists in replacing a segment or filling a bone defect using bone grafts (Bloomberg *et al.*, 1984; Morello *et al.*, 2001). The best source to obtain this material would be

the animal itself, in what is called autograft, since the approach is biologically compatible (Goldberg and Stevenson, 1987). However, in small animals such as cats, the collection of autologous graft may be problematic, because the technique does not afford to collect a suitable amount of bone (Dorea et al., 2005).

A major source of bone material is the bones from animals of the same species, in a technique called allogeneic grafts (Kerwin et al., 1991). Although allogeneic grafts have greater immune response when compared to autografts (Goldberg and Stevenson, 1987), the approach has produced satisfactory results (Alievi et al., 2007). These grafts can be osteoconductive, osteoinductive and provide mechanical support (Fitch et al., 1997).

Treatment of comminuted fractures is the main indication for the use of cortical allograft bone in veterinary medicine (Kerwin et al., 1991). It may also be used in bone lengthening, treatment of malunion and nonunion of fractures and in limb sparing (Sinibaldi, 1989). Allogeneic bone grafts are an alternative to fill gaps in bones of domestic cats (Dorea et al., 2005); however, the effectiveness of this type of bone graft has not been adequately assessed in this species.

Several methods and means for maintaining these grafts can be used, among which is preservation by freezing (Nather, 2001), lyophilization (Galia et al., 2009), glycerin (Del Carlo et al., 1999) and honey (Alievi et al., 2007). Freezing and lyophilization are successful in the preservation and incorporation of allografts, but require costly, sophisticated equipment (Del Carlo et al., 1999), which are obstacles as regards to the use of these methods in many hospitals and clinics. Another option would be to conserve bone in honey, as this material is readily available, inexpensive, it does not require specialized equipment to be obtained (Amendola et al., 2003), apart from the fact that it exhibits antimicrobial properties both *in vitro* and *in vivo* (Cooper et al., 1999; Alievi et al., 2007). Among these properties are osmolarity (Cooper et al., 1999), production of hydrogen peroxide (Mendes e Coelho, 1983), low pH (Bergman et al., 1983), besides the presence of enzymes (Molan, 1992) and flavonoids (Sabatier et al., 1992) with antibacterial action. Honey has been used in the preservation of tissues such as

skin (Subrahmanyam, 1993) and cornea (Abramov and Markicheva, 1983). Bone segments preserved in honey have been implanted with satisfactory results in dogs (Amendola et al., 2003; Alievi et al., 2007) and humans (Mschvidobadse, 1978), though the use of cortical bone grafts preserved in honey has not been evaluated in cats. Moreover, it is necessary to compare this way of conservation with established methods, such as freezing and lyophilization.

This work compares the clinical, radiographic and histological examination of autogenous cortical bone grafts and allograft cortical bone preserved in honey, frozen at -70 °C or lyophilized in the replacement of the femoral diaphysis of domestic cats.

MATERIALS AND METHODS

This study was approved by the Ethics Committee of the Brazilian College of Veterinary Surgery and Anesthesiology for presentation in the eighth Brazilian Congress of Veterinary Surgery and Anesthesiology under number 90-1. The sample was composed of 26 spayed mixed-breed female adult domestic cats weighing between 3 and 4 kg from the Center for Zoonosis Control in Porto Alegre, RS. The animals were free of musculoskeletal alterations or other diseases that could affect the physicochemical properties of bones. The first two cats were used as donors (four implants collected from femurs), starting from there, the bone segments removed for the making of the cortical bone flaw in the femur of the experimental animals was prepared and used in other animals in the experiment. The other 24 cats were housed in individual cages with a habituation period of at least 14 days before the surgery, treated for parasites and immunized. The animals were divided into four groups of six subjects each: control group, honey-preserved, frozen and lyophilized grafts. The animals underwent osteotomy surgical procedure of a 3cm segment from the right femoral diaphysis and replaced by cortical allografts preserved in honey, frozen at -70°C or lyophilized. In the control group, the graft removed was reimplanted.

For preservation in honey, the bone segments were collected aseptically and placed

Comparison of lyophilization...

individually in sterile, opaque plastic bottles and kept fully submerged in sterile honey for a period of between 30 and 35 days, in the dark, at room temperature. Honey was chosen from blooming flowers, predominantly Yopo (*Anadenanthera* sp.). The grafts were kept under refrigeration, packed the same way and kept in a freezer at -70°C for 30 to 35 days. Freeze-dried implants, after around 45 days to remove the fat and lyophilization, were sterilized in an autoclave at 132°C for 4min.

For the surgical procedure, animals were kept with no water intake for 4h and no food for 12h. As premedication (PM), 0.1mg/kg acepromazine maleate was administered at a dose of 3mg/kg meperidine. After 15min of PM, the induction of anesthesia was performed using 5mg/kg propofol. The anesthesia was maintained with isoflurane in 100% oxygen. In association to inhalation anesthesia, epidural block was performed with lidocaine hydrochloride and morphine. All animals received 22mg/kg of sodium ampicillin (IV) 30min before surgical procedure.

After antisepsis, access to the diaphysis of the femur was performed. Proximal and distal osteotomies were performed with an oscillating saw to remove a 3-cm-long bone fragment, which represented approximately 30% of the total femoral length. During the bone sectioning, the area was constantly irrigated with sterile saline solution. Next, the bone fragment was either reinserted in the defect created (control group) or kept sterile to serve as an implant in another animal after preservation in honey, frozen at -70°C, or lyophilized.

The grafts were rehydrated in a sodium chloride 0.9% solution for at least 45min prior to insertion in the receptor using a dynamic compression plate (DCP), 2.7mm with 10 holes and eight 2.7mm cortical screws. The grafts were initially stabilized at the plate with two screws. Six screws were used to fix the bone graft and plate into receptor bone, three proximal and three distal to the implant, with two screws (one distal and one proximal) being formerly inserted immediately adjacent to the graft, with a compression effect. All bone grafts of the honey-

preserved, frozen and lyophilized bone groups were submitted to microbiological control in collection and deployment. The fascia lata was approached using synthetic absorbable 3-0 polyglactin 910 and Sultan suture, the subcutaneous tissue was closed using the same suture sewn as a simple continuous pattern, and the skin was sutured with 3-0 monofilament nylon as a simple isolated pattern.

As anti-inflammatory and analgesic therapy after surgery, the animals received ketoprofen (2mg/kg SC) in the immediate postoperative period and every 24h over 3 days, and tramadol (2mg/kg IM) every 6h, 24h after epidural anesthesia, for 48h. As antimicrobial prophylaxis, 2.5mg/kg IM enrofloxacin was used immediately after surgery and every 24h for 10 days.

Radiographic evaluations were carried out after the surgical procedure and every 15 days until the end of the assessment period of 180 days. All radiographs were performed in the mediolateral and craniocaudal projections under tranquilization with a combination of tiletamine hydrochloride and zolazepam hydrochloride as a 0.5mg/kg dose (IM). The radiographs were examined for the alignment of the bone graft in the proximal and distal femoral segments, the stability of the graft and the bone plate, the migration of screws, signs of consolidation of the host-bone interface, the bone callus and the appearance of the graft.

The radiographic union was considered present when there was a complete continuity in the cortical bone-implant interface and the periosteal and endosteal callus were shown in active remodeling. All radiographic examinations after surgery were assessed using Table 1, developed to evaluate the large allogenic grafting (Ehrhart *et al.*, 2005) and adapted for this work. Radiographies taken at each point in time were evaluated by a single experienced orthopedist who was screened from the group to which each animal belonged. The scores of the six cats in each group were summed and compared, being sorted in terms of the item evaluated, to a maximum score of 12.

Table 1. Graphical score of radiographic evaluation¹ and adapted for autograft or allograft cortical bone evaluation in repair of experimental femoral bone defects in domestic cats

Score criteria	Points
Autograft/allograft incorporation/union	
Proximal Interface	
Loss of osteotomy line detail	2
Osteotomy line still visible	1
Widening of osteotomy line	0
Distal Interface	
Loss of osteotomy line detail	2
Osteotomy line still visible	1
Widening of osteotomy line	0
Autograft/allograft bone quality	
Autograft/allograft contour unchanged	2
Cortical resorption present but not marked, no deformation or fracture present	1
Marked resorption of cortical, deformation or fracture	0
Receptor bone quality	
Marked new host bone formation and bridging callous	2
New host bone formation visible but poor bridging	1
No new bone production present	0
Aspect and fixation of the plate and screws	
Metallic implants appear normal	2
Lysis around screws	1
Loosening, migration or break of the plate and/or screws	0
Overall impression of healing	
Radiographic union	2
Radiographic evidence of callous but delayed union	1
Minimal or no radiographic evidence of healing	0

¹created by Ehrhart et al. (2005).

At the end of the evaluation period, two randomly chosen animals from each group were euthanized using potassium chloride IV after general anesthesia with thiopental IV. After the removal of the femur, the existence of soft tissue reaction, the formation of callus, the presence of infection, appearance and stability of the plate, screws and bone graft were recorded. The femur was sent for histological evaluation. The histological sections had a thickness of 5µm and were stained with hematoxylin-eosin and Masson's Trichrome.

Statistical analysis was performed with the Statistical Package for Social Sciences version 14.0, and the association between the variable consolidation (yes/no) and the groups was performed by the Chi-square test. A significance level of 5% (P<0.05) was considered.

RESULTS

Bone grafts frozen at -70°C maintained the same aspect in collection and implantation. Bones preserved in honey were yellow, with small amounts of the preservative impregnated to the bone. No discernible difference in the resistance of the receptor bone in relation to the graft was observed as of making the holes neither in the frozen bone nor in bones preserved in honey. In the freeze-dried bone it was possible to detect subjectively an increase in porosity by manipulation, which disappeared after rehydration. However, when making the holes for the screws, lyophilized grafts had lower resistance when compared with the recipient bone. Bacterial evaluations revealed that one sample in the honey-preserved grafts, collected at deployment, was contaminated with the gram-positive bacterium *Brevibacterium sp.*

Comparison of lyophilization...

A domestic cat from the lyophilized group presented fistulous tract on the operated limb, showing purulent drainage at the beginning and later serosanguineous. All animals showed adequate ambulation soon after surgery and maintained or improved ambulation along evaluation.

The graft incorporation in the control group was 91.6% (11/12), with an average time for incorporation of 83.1 days (Figure 1 a-f). In the honey-preserved bone group, the incorporation was 75% (9/12) with an average time for incorporation of 105 days (Figure 2a-f). Regarding the frozen group, the incorporation was 83.3% (10/12), with an average time for

incorporation of 78 days. In one of the animals which received a frozen graft, there was displacement of the distal receptor bone in relation to the plate, with three loose screws and no limb alignment and, in another case, there was intense resorption in both receptor and the implanted bone (Figure 3a-f) in the distal interface. In the lyophilized group, incorporation was 25% (3/12) with an average time for incorporation of 120 days. There was longitudinal fissure of the implant in three cats, identified within 30 days after surgery, which compromised the alignment of the graft with the receptor bone. In five animals from this group there was absorption of the graft (Figure 4a-f).

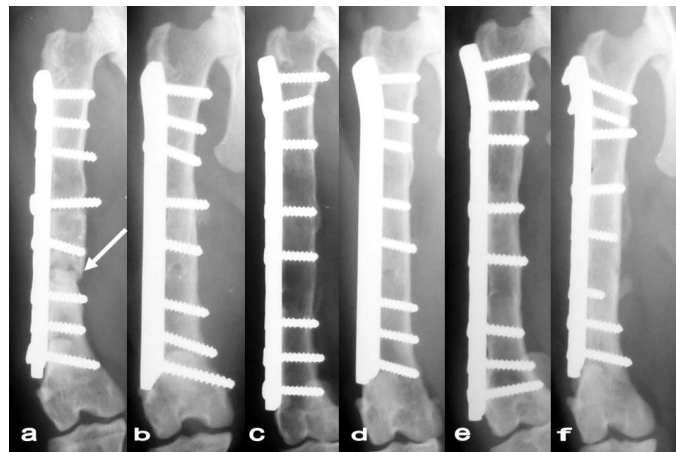


Figure 1(a-f). Craniocaudal radiograph of cortical bone autografts in the six domestic cats of control group 180 days post-operatively, showing the host-graft interfaces with nonunion (white arrow).

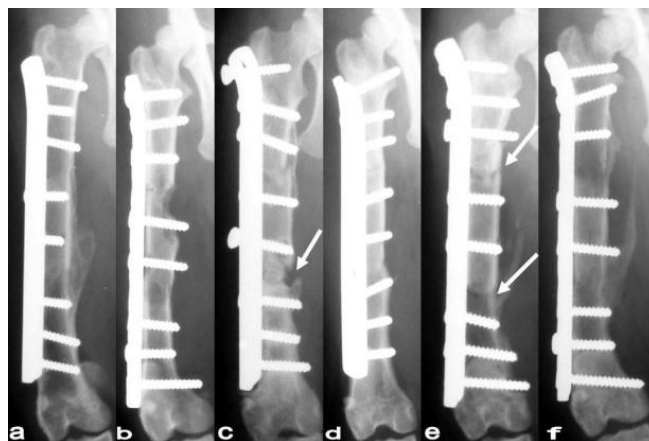


Figure 2(a-f). Craniocaudal radiograph of cortical bone allografts preserved in honey in the six domestic cats of honey group 180 days post-operatively, showing the host-graft interfaces with nonunion (white arrows).

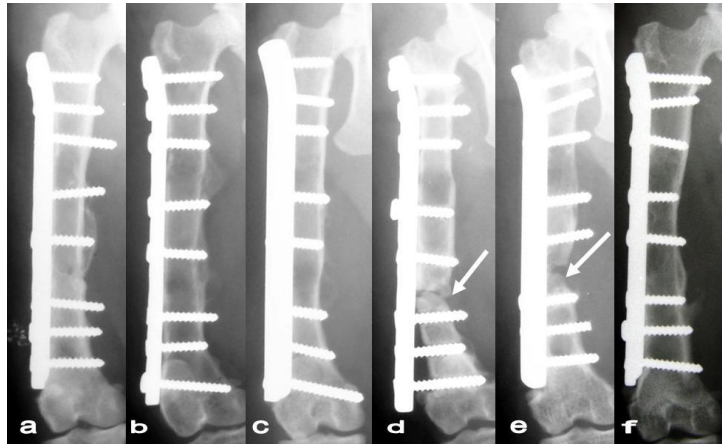


Figure 3 (a-f). Craniocaudal radiograph of cortical bone allografts preserved frozen at -70°C in the six domestic cats of frozen group 180 days post-operatively, showing the host-graft interfaces with nonunion (white arrows).

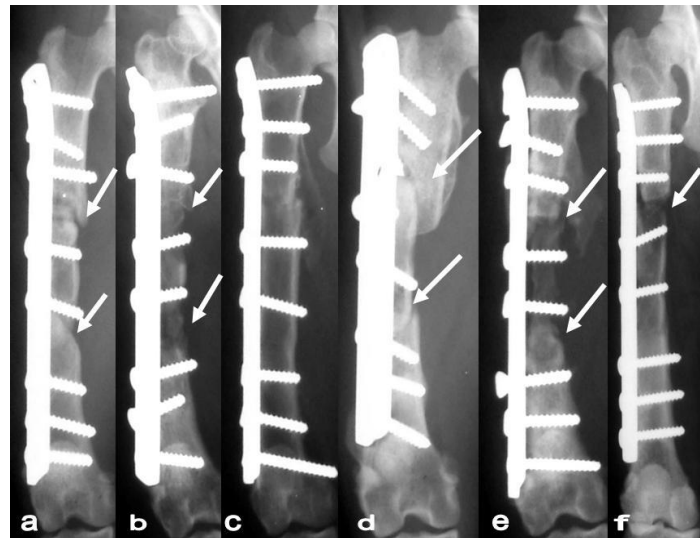


Figure 4 (a-f). Craniocaudal radiograph of cortical bone allografts lyophilized in the six domestic cats of lyophilized group 180 days post-operatively, showing the host-graft interfaces with nonunion (white arrows).

During the macroscopic evaluation it was possible to differentiate the graft bone from the receptor by the difference in color, in the honey-preserved as much as in the frozen bone groups, which interfered in mobility. In one of animals from the lyophilized group, the graft presented a dark color and both interfaces were mobile.

Tissue remodeling and periosteal reaction could be observed in the histological evaluation of the control group, though histological differentiation between the graft and receptor bone was not visible in three of the four interfaces evaluated.

In the distal interface of one animal, no incorporation of the graft was identified, but areas of necrosis, fibrosis and cartilaginous tissue were visualized. In the honey-preserved bone group, two animals showed good incorporation of the graft in a remodeling stage, thus it was not possible to observe the transition between the normal and the implanted bone.

In the frozen bone group, areas of cartilaginous tissue and periosteal reaction were observed, showing complete incorporation with remodeling of the graft in two proximal and one distal interface. In the distal interface of one animal, a

Comparison of lyophilization...

large area of reabsorption of bone graft and recipient bone could be seen with replacement by fibrous tissue and cartilage. In one animal of the lyophilized bone group, an extensive area of fibrous tissue surrounding the graft was observed associated with the presence of a purulent inflammation process. It was found that the bone graft was in a necrotic reaction characterizing a reaction to foreign body. Regarding the other animal, it was observed that the graft bone was necrotic and was associated with the presence of fibrous tissue and cartilage.

The evaluations carried out using the table of radiographic scores, the incorporation of the graft in the proximal (Figure 5) and distal (Figure 6) interfaces, graft bone quality (Figure 7), aspect and fixation of the plate and screws (Figure 8), there was little variation among the control, honey-preserved and frozen bone

groups, though the lyophilized bone group had the lowest score. As for the quality of the receptor bone (Figure 9), the results were similar in honey-preserved and frozen bone groups, with a high score and between the control and lyophilized groups with low scores. Considering the overall impression of consolidation (Figure 10) the scores of the four groups were similar.

There was no statistical difference among the groups when they were compared for incorporation time and animal weight. Statistical difference was found in the percentage of interfaces with incorporation, and the lyophilized bone group (25%) was statistically lower than the control (91.7%) and frozen (83.3%) bone groups. The honey-preserved bone group (75%) was statistically similar to other groups.

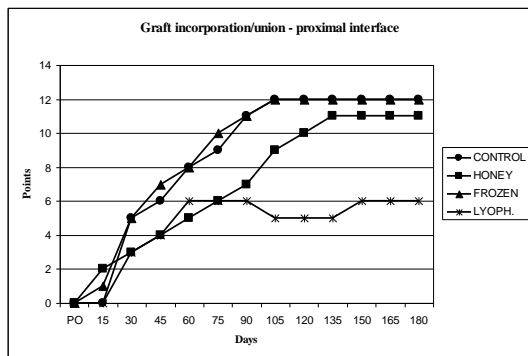


Figure 5. Graphical score of radiographic evaluation of control, honey, frozen and lyophilized groups in the item autograft/allograft incorporation/union on proximal interface.

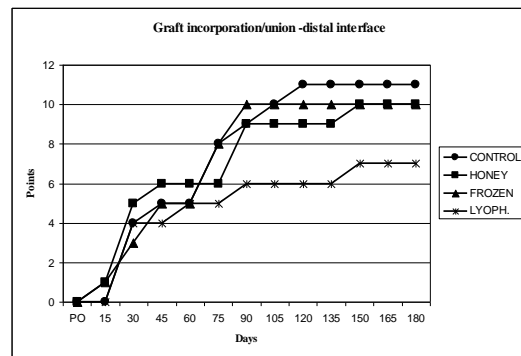


Figure 6. Graphical score of radiographic evaluation of control, honey, frozen and lyophilized groups in the item autograft/allograft incorporation/union on distal interface.

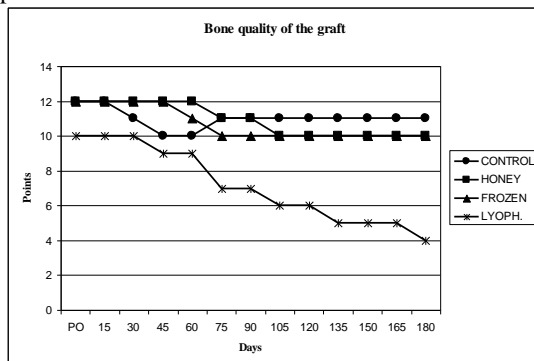


Figure 7. Graphical score of radiographic evaluation of control, honey, frozen and lyophilized groups in the item autograft/allograft bone quality.

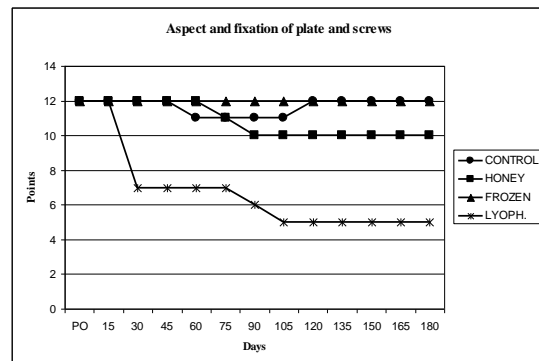


Figure 8. Graphical score of radiographic evaluation of control, honey, frozen and lyophilized groups in the item aspect and fixation of the plate and screws.

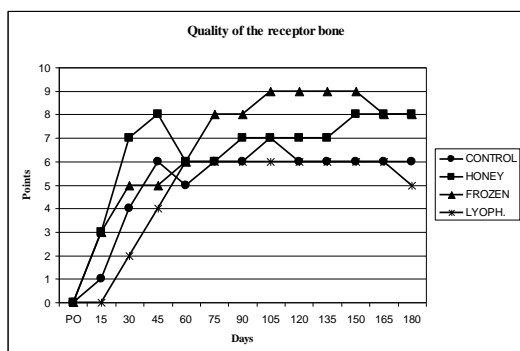


Figure 9. Graphical score of radiographic evaluation of control, honey, frozen and lyophilized groups in the item receptor bone quality.

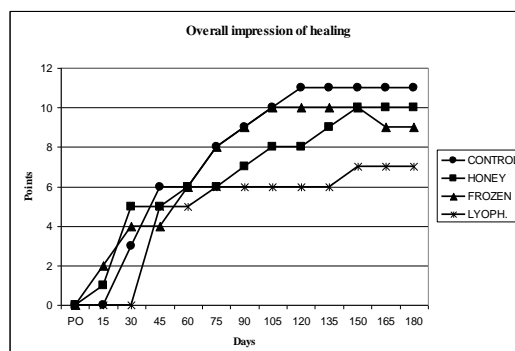


Figure 10. Graphical score of radiographic evaluation of control, honey, frozen and lyophilized groups in the item overall impression of healing.

DISCUSSION

The use of the bone segment removed from an animal subjected to allogeneic cortical bone implantation in another animal in the experiment allowed to decrease the number of animals euthanized to form the bone bank, as has been adopted in cats (Toombs and Wallace 1985; Nather, 2001; Nather *et al.*, 2004) and dogs (Alievi *et al.*, 2007).

The bone regeneration ability was studied in several species such as dogs (Harris *et al.*, 1977) and rabbits (Criguel and Balligand, 2002). It is known that a segmental cortical defect with 1.5 times the diaphyseal diameter exceeds the regenerative capacity of bone in dogs (Key, 1934). In domestic cats, segmental bone defects with 1.25 to 1.52 times the diameter of the tibia diaphysis produced four non-unions and a delayed union in five animals (Toombs *et al.*, 1985). This supported the validity of this experimental model, because the minor bone defect produced in the present animals was almost three times the diameter of the femoral diaphysis. Honey has been tested as a preservative in this study due to favorable results in studies where it was used for preservation of bone grafts in dogs (Amendola *et al.*, 2003; Alievi *et al.*, 2007), birds (Gaiga and Schossler, 2003) and humans (Mschvidobdase, 1978). The allograft preserved in honey still needs further studies to identify the minimum and maximum storage time (Alievi *et al.*, 2007). In this study, in order to avoid any influence of preservation time in honey, it was decided to keep the grafts for a period of 30-35 days, even though the successful use of honey for between one and eight months

has been cited in the literature (Amendola *et al.*, 2003; Gaiga and Schossler, 2003).

For the sake of standardization, a rehydration period of at least 45min was observed for all bone grafts. Other studies utilized freeze-dried bone that had been rehydrated for 1h (Fujiki *et al.*, 2005) or 2h (Burchardt *et al.*, 1978). Although the rehydration time of bone graft observed in the present study was shorter than these intervals, this is unlikely to have influenced the complications observed in this experiment, because even if the time was insufficient to complete the rehydration of the graft, the rehydration process is completed with body fluids after implantation (Conrad *et al.*, 1993).

Whilst there are other methods for stabilizing bone grafts such as intramedullary pin associated to type I Kirschner (Bloomberg *et al.*, 1984), intramedullary pin (Nather, 2001) and locked intramedullary nail (Julian and Valentí, 2006), in this study, dynamic compressive plates and screws were used as a form of rigid stabilization, enabling the animals' early return to ambulation as observed in dogs (Alievi *et al.*, 2007).

Although it is easier to get 360° of contact between the graft and receptor bone interfaces in domestic cats than in dogs (Henry Jr. and Wadsworth, 1981), in this work, this was not obtained in all cases, as small angles during osteotomy prevented the perfect positioning of the interfaces, keeping, however, the compression and contact between the ends.

The table recommended by Ehrhart *et al.* (2005) to evaluate the influence of radiation therapy on

Comparison of lyophilization...

the incorporation of cortical allograft on the radius of 24 dogs was adapted for this work, but instead of adding the scores of the items evaluated in each animal, this experiment summed the scores of all domestic cats in each group for each of the six items assessed, thus quantifying and standardizing the variables assessed in the different groups and assessment periods, thereby facilitating the comparison. It was observed that in the evaluation of the graft incorporation in the proximal and distal interfaces, quality and appearance of the graft and fixation of plates and screws, there was little variation among the control, honey-preserved and frozen groups, since these groups showed similar results. However, in the lyophilized group, scoring was much lower because there were only three interfaces with consolidation. As for the quality of the recipient bone, results were similar in the honey-preserved and frozen bone groups with high scores, and between control and freeze-dried with low scores. The low scores in the control group were caused by the rapid consolidation and minimal callus formation which occurs when using autogenous bone grafts (Denny and Butterworth, 2006).

Neither radiographic nor histological assessment evidenced the rejection of the graft conserved in honey in any of the animals in this experiment, resulting in incorporation in nine of 12 interfaces (75%), a result similar to that found in a study with dogs, which showed 79.17% of consolidation (Alievi *et al.*, 2007). Therefore, it is possible to infer that honey can reduce the antigenicity of bone grafts. The results of this experiment allow the recommendation of honey as a preservative in allogeneic bone grafts used in domestic cats as recommended for bone grafts in pigeons (Gaiga and Schossler, 2003) and dogs (Amendola *et al.*, 2003; Alievi *et al.*, 2007).

Despite showing results statistically identical to the results of the honey-preserved bone group, the grafts kept frozen at -70°C require specific and expensive equipment concerning maintenance (Alievi *et al.*, 2007). Maintenance costs involved in the preservation of bone grafts in honey are almost negligible. The only precaution consists in avoiding exposure to light and high temperatures, conditions that could compromise its antimicrobial properties (Mathews and Binnington, 2002), like high osmolarity (Cooper *et al.*, 1999), production of

hydrogen peroxide (Mendes and Coelho, 1983), low pH (3,6) (Bergman *et al.*, 1983), enzymes (Molan, 1992) and flavonoids (Sabatier *et al.*, 1992) with antibacterial action.

As a preservation method, lyophilization affords inferior results when compared to freezing at -80°C because, although presenting incorporation, the lyophilized implants took longer to consolidate into the tibia of cats (Nather *et al.*, 2004). In this study, lyophilization proved to be the least effective method of preservation regarding the handling and the frequency of consolidation when compared with the bone frozen at -70°C , preserved in honey or autogenous.

The lyophilized grafts used in this procedure were sterilized in an autoclave at a temperature of 132°C as the lyophilization process is not aseptic and does not completely eliminate viral strains (Uhlenhaut *et al.*, 2005). Autoclaving at 132°C for 1 h can reduce the resistance to compression of lyophilized bone grafts in as much as 70% (Viceconti *et al.*, 1996). Fractures in bone grafts occur due to defects created at deployment time (Thompson Jr. *et al.*, 1993) or by rapid revascularization in the bone with subsequent resorption and weakening of the bone graft (Gebhardt *et al.*, 1990). As both fractures in animals of the lyophilized group occurred shortly after surgery, with no time for revascularization and resorption of bone graft, it is likely that they occurred as a consequence of bone weakness caused by lyophilization and autoclaving.

The main complications associated with the use of cortical bone grafts are: infection, pseudoarthrosis (non-union) and fracture (Julian and Valentí, 2006). All these complications were observed in this work, especially in the lyophilized group, with two fractures, one infection and two non-unions, and the other groups presented only non-unions. The overall rate of non-unions in this study was 31.25%, which is close to 30% — a percentage expected in this type of surgery (Ortiz-Cruz *et al.*, 1997).

The infection observed in one animal of the lyophilized group was likely due to failure of asepsis during the surgical procedure. In addition, the bone implant was weakened by autoclaving (Viceconti *et al.*, 1996), which allowed early abnormal mobility at the interface

implant/bone receptor in the follow up. Probably a form of sterilization that does not weaken the bone implant, such as ethylene oxide, would have permitted the post-operative antimicrobial therapy to control the infection in an environment without instability.

In all groups, there were animals that showed some degree of resorption of the graft, an event more frequent and intense in the lyophilized bone group. This can be explained by the fact that in the process of incorporation of the graft, osteoclastic activity and resorption initially occur, followed by osteoblastic activity and the beginning of new bone formation, and resorption may last for up to one year after surgery (Newman - Gage, 2000).

CONCLUSIONS

The results of the present study show that cortical allograft preserved for 30-35 days in honey or in a freezer at -70°C are effective for filling bone defects with approximately 30% of the femoral diaphysis of domestic cats. Although these grafts may have complications such as nonunions and resorption, lyophilized cortical allografts are not efficient for filling segmental bone defects, since they presented more complications such as nonunion, resorption, fracture and infection.

ACKNOWLEDGMENTS

This study was funded by the National Council for Scientific and Technological Development (CNPq) through the Edital Universal 2007, recorded in number 484767/2007-0. The authors thank DM, PhD Carlos Roberto Galia for providing the lyophilized bone grafts.

REFERENCES

ABRAMOV, V.G.; MARKICHEVA, N.A. Therapeutic lamellar keratoplasty with honey preserved material. *Oftalmol. Zh.*, v.38, p.81-83, 1983

ALIEVI, M.M.; SCHOSSLER, J.E.W.; GUIMARÃES, L.D. *et al.* Implante ósseo cortical alógeno conservado em mel na reconstrução de falha óssea diafisária em fêmur de cães: avaliação clínica e radiográfica. *Cienc. Rural*, v.37, p.450-457, 2007.

AMENDOLA, G.F.; ILHA, M.; BERGER, R. *et al.* Correção de defeito ósseo femoral em cães utilizando implante cortical homólogo conservado em mel. *Acta Cir. Bras.*, v.18, p.302-307, 2003.

BERGMAN, A.; YANAI, J.; WEISS, J. *et al.* Acceleration of wound healing by topical application of honey. An animal model. *Am. J. Surg.*, v.145, p.374-376, 1983.

BLOOMBERG, M.S.; GORING, R.L.; BORN, F. Frozen diaphyseal bone allografts combined with external and internal pin splintage in small animal orthopedic surgery. *J. Am. Anim. Hosp. Assoc.*, v.20, p.393-402, 1984.

BURCHARDT, H.; JONES, H.; GLOWCZEWSKIE, F. *et al.* Freeze-dried allogeneic segmental cortical-bone graft in dogs. *J. Bone Jt. Surg. Am.*, v.60A, p.1082-1090, 1978.

CONRAD, E.U.; ERICKSEN, D.P.; TNCER, A.F. *et al.* The effects of freeze-drying and rehydration on cancellous bone. *Clin. Orthop. Relat. Res.*, v.290, p.279-284, 1993.

COOPER, R.A.; MOLAN, P.C.; HARDING, K.G. Antibacterial activity of honey against strains of *Staphylococcus aureus* from infected wounds. *J. Rev. Soc. Med.*, v.92, p.283-285, 1999.

CRIGUEL, M.H.; BALLIGAND, M. Critical size defect model on the femur in rabbits. *Vet. Comp. Orthop. Traumatol.*, v.15, p.158-163, 2002.

DEL CARLO, R.J.; GALVÃO, S.R.; VILORIA, M.I.V. *et al.* Aloenxertos ósseos caninos diferentemente preservados. *Rev. Bras. Cien. Vet.*, v.6, p.121-125, 1999.

DENNY, H.R.; BUTTERWORTH, S.J. Enxertos ósseos. In: DENNY, H.R.; BUTTERWORTH, S.J. (Eds.) *Cirurgia Ortopédica em Cães e Gatos*. 4.ed. São Paulo:Roca, 2006, p.14-18.

DOREA, H.C.; McLAUGHLIN, R.M.; CANTWELL, H.D. *et al.* Evaluation of healing in feline femoral defects filled with cancellous autograft, cancellous allograft or bioglass. *Vet. Comp. Orthop. Traumatol.*, v.18, p.157-168, 2005.

EHRHART, N.P.; EURELL, J.A.; CONSTABLE, P.D. *et al.* The effect of host tissue irradiation on large-segment allograft incorporation. *Clin. Orthop. Relat. Res.*, n.435, p.43-51, 2005.

FITCH, R.; KERWIN, S.; NEWMAN-GAGE, H.; SININBALDI, K.R. Bone autografts and allografts in dogs. *Comp. Vet. Cont. Educ.*, v.19, p.558-575, 1997.

FUJIKI, E.N.; HONDA, E.K.; FUKUSHIMA, W.Y. *et al.* Enxerto liofilizado homólogo em artroplastias de revisão em quadril. *Rev. Bras. Ortop.*, v.40, p.280-287, 2005.

Comparison of lyophilization...

- GAIGA, L.H.; SCHOSSLER, J.E.W. Osteossíntese de úmero por xenoinxerto ósseo preservado em mel em pombos domésticos (*Columba livia*). *Cienc. Rural*, v.33, p.709-715, 2003.
- GALIA, C.R.; MACEDO, C.A.; ROSITO, R. *et al.* Femoral and acetabular revision using impacted non demineralized freeze-dried bone allografts. *J. Orthop. Sci.*, v.14, p.259-265, 2009.
- GEBHARDT, M.C.; ROTH, Y.F.; MANKIN, H.J. Osteoarticular allografts for reconstruction in the proximal part of the humerus after excision of a musculoskeletal tumor. *J. Bone Jt. Surg. Am.*, v.72A, p.334-345, 1990.
- GOLDBERG, V.; STEVENSON, S. Natural history of autografts and allografts. *Clin. Orthop. Relat. Res.*, v.225, p.7-16, 1987.
- HARRIS, W.H.; MOYEN, B.J.; THRASHER, E.L. *et al.* Differential response to electrical stimulation: a distinction between induced osteogenesis in intact tibiae and the effect on fresh fracture defects in radii. *Clin. Orthop. Relat. Res.*, n.124, p.31-40, 1977.
- HENRY, J.R.; WADSWORTH, P.L. Diaphyseal allografts in the repair of long bones fractures. *J. Am. Anim. Hosp. Assoc.*, v.17, p.525-534, 1981.
- JULIÁN, M.S.; VALENTÍ, A. Trasplante óseo. *An. Sist. Sanit. Navar.*, v.29, p.125-136, 2006.
- KERWIN, S.C.; LEWIS, D.D.; ELKINS, A.D. Bone grafting and banking. *Compend. Contin. Educ. Pract., Vet.*, v.13, p.1558-1566, 1991.
- KEY, J.A. The effects of a local calcium depot on osteogenesis and healing of fractures. *J. Bone Jt. Surg. Am.*, v.16A, p.176-184, 1934.
- MATHEWS, K.A.; BINNINGTON, A.G. Wound management using honey. *Compend. Contin. Educ. Pract. Vet.*, v.24, p.53-60, 2002.
- MENDES, B.A.; COELHO, E.M. Considerações sobre características do mel de abelhas – análises e critérios de inspeção. *Inf. Agropec.*, v.9, p.56-57, 1983.
- MOLAN, P.C. The antibacterial activity of honey. 1. The nature of the antibacterial activity. *Bee World*, v.73, p.5-28, 1992.
- MORELLO, E.; BURACCO, P.; MARTANO, M. *et al.* Bone allografts and adjuvant cisplatin for the treatment of canine appendicular osteosarcoma in 18 dogs. *J. Small Anim. Pract.*, v.42, p.61-66, 2001.
- MSCHVIDOBADSE, V.M. Allotransplantation sterilisierter Knochen und Halbgelenke bei Knochendefekten. *Zentralbl. Chir.*, v.103, p.1138-1148, 1978.
- NATHER, A. Biological healing of large diaphyseal deep-frozen allograft transplants. *Cell Tissue Bank*, v.2, p.3-7, 2001.
- NATHER, A.; THAMBYAH, A.; GOH, J.C.H. Biomechanical strength of deep-frozen versus lyophilized large cortical allografts. *Clin. Biomech.*, v.19, p.526-533, 2004.
- NEWMAN-GAGE, H. Banco de injertos óseos alogeneicos: panorama sobre teoría y usos vigentes. In: BOJRAB, M.J.; ELLISON, G.W.; SLOCUM, B. (eds.) *Técnicas actuales en cirugía de pequeños animales*. 4.ed. Buenos Aires: Intermédica, 2000. p.846-850.
- ORTIZ-CRUZ, E.; GEBHARDT, M.C.; JENNINGS, L.C. *et al.* The results of transplantation of intercalary allografts after resection of tumors. *J. Bone Jt. Surg. Am.*, v.79A, p.97-106, 1997.
- SABATIER, S.; AMIOT, M.J.; TACCHINI, M.; AUBERT, S. Identification of flavonoids in sunflower honey. *J. Food Sci.*, v.57, p.773-774, 1992.
- SINIBALDI, K.R. Evaluation of full cortical allografts in 25 dogs. *J. Am. Vet. Med. Assoc.*, v.194, p.1570-1577, 1989.
- SUBRAHMANYAM, M. Storage of skin grafts in honey. *Lancet*, v.341, p.63-64, 1993.
- THOMPSON Jr., R.C.; PICKVANCE, E.A.; GARRY, D. Fractures in large-segment allografts. *J. Bone Jt. Surg. Am.*, v.75, p.1663-1673, 1993.
- TOOMBS, J.P.; WALLACE, L.J.; BJORLING, D.E.; ROWLAND, G.N. Evaluation of Key's hypothesis in the feline tibia: an experimental model for augmented bone healing studies. *Am. J. Vet. Res.*, v.46, p.513-518, 1985.
- TOOMBS, J.P.; WALLACE, L.J. Evaluation of autogenic and allogenic cortical chip grafting in a feline tibial nonunion model. *Am. J. Vet. Res.*, v.46, p.519-528, 1985.
- UHLENHAUT, C.; DÖRNER, T.; PAULI, G.; PRUSS, A. Effects of lyophilization on the infectivity of enveloped and non-enveloped viruses in bone tissue. *Biomaterials*, v.26, p.6558-6564, 2005.
- VICECONTI, M.; TONI, A.; BRIZIO, L. *et al.* The effect of autoclaving on the mechanical properties of bank bovine bone. *Chir. Organi. Mov.*, v.81, p.63-68, 1996.