

The use of hydroxyapatite for arthrodesis in dogs and cats: a clinical study

[Utilização de hidroxiapatita para artrodeses em cães e gatos: ensaio clínico]

F.A. Dórea Neto^{1,2}, J.G. Padilha Filho², L.A. Santos⁴, A.P. Oriá^{1,2}, J.C. Canola³
S.A. Stefanos², E. Regonato²

¹União Metropolitana de Educação e Cultura
Av. Luiz Tarquínio Pontes, 600
42700-000 - Lauro de Freitas, BA

²Aluno de pós-graduação - FCAV-UNESP – Jaboticabal, SP

³Faculdade de Ciências Agrárias e Veterinária - UNESP – Jaboticabal, SP

⁴Universidade Federal do Rio Grande do Sul – Porto Alegre, RS

ABSTRACT

Twenty-five arthrodeses were performed in four cats and 17 dogs using synthetic hydroxyapatite as fresh autogenous graft cancellous bone substitute. Arthrodesis was performed in the carpal joint in eight cases, in the tarsal joint in 10, in the elbow joint in six, and in the knee joint in one case. The mean radiographic follow-up time was 30 days in one animal, 45 days in another animal and 60 days in the 19 remaining cases. Bone union was observed in 24 arthrodeses. Non-union of one elbow arthrodesis was due to failure of stabilization. Restoration of limb functionality was classified as good to excellent in 22 cases. Hydroxyapatite was able to promote bone growth and is suitable for using in routine surgical procedures for small animals.

Keywords: dog, cat, bone fusion, carpal, tarsal, stifle, elbow

RESUMO

Realizaram-se 25 artrodeses em 21 casos, quatro em gatos e 17 em cães, utilizando hidroxiapatita sintética como substituto ao enxerto ósseo autógeno esponjoso fresco, sendo oito na articulação do carpo, 10 na articulação do tarso, seis na do cotovelo e uma na do joelho. As avaliações radiográficas foram realizadas aos 30 dias em um animal, aos 45 dias em outro e aos 60 dias nos 19 casos restantes. Visibilizou-se união óssea em 24 artrodeses e a não-união em um cotovelo foi atribuída a falha na estabilização. O retorno à função do membro foi classificado de bom a excelente em 22 casos. A hidroxiapatita foi capaz de viabilizar o crescimento ósseo e mostrou-se factível para utilização na prática cirúrgica rotineira em pequenos animais.

Palavras-chave: cão, gato, fusão óssea, carpo, tarso, joelho, cotovelo

INTRODUCTION

Arthrodesis is defined as the surgical fixation of a joint in order to permit fusion of the articular surfaces through the proliferation of bone cells (Penwick, 1987; Lesser, 1993; Turner and Lipowitz, 1996). Arthrodesis has been well documented as a treatment option for comminuted joint fractures, irreparable injuries

to the articular ligaments, as a limb saving procedure in the case of sciatic nerve injuries, and for severe degenerative joint diseases (Johnson, 1995; Turner and Lipowitz, 1996; Trostel and Radasch, 1998). Instability induces pain due to abnormal movement and the tension placed on the soft tissues and nerves of the joint. Thus, arthrodesis relieves pain by providing a rigid support (Lesser, 1993).

Recebido em 19 de julho de 2006

Aceito em 2 de abril de 2007

E-mail: d.oria@terra.com.br

Since their introduction in the beginning of the 1980s, calcium phosphate ceramics, especially hydroxyapatite, have been used for the remodeling and reconstruction of bone defects. The properties of biocompatibility, bioactivity and osteoconduction of bioceramics permit their implantation into the bone site without inducing an immune response. These materials are able to bind directly to bone tissue, promoting bone growth along its surface (Legeros, 1991). However, these synthetic bone substitutes are not commonly employed in veterinary surgery (Fitch et al., 1997).

The objective of the present study was to clinically and radiographically evaluate the use of hydroxyapatite as a graft in joints submitted to arthrodesis.

MATERIAL AND METHODS

Twenty-five arthrodeses were performed in 21 animals, four cats and 17 dogs, for the treatment of severe joint disorders using synthetic hydroxyapatite as a fresh autogenous graft cancellous for defect filling between opposite articular sides.

Medical records as well as data regarding surgical treatment (arthrodesis) in cats and dogs with severe joint injuries, pain and instability, were obtained from January 2001 to December 2002. The data included clinical signs, etiology of the injury, concurrent problems, extent and site of the injuries, time elapsed until surgical stabilization of the joint, stabilization methods and postoperative management, duration of hospitalization, cultures and antibiotic therapy, healing period and complications. The interval between the occurrence of the injury and surgery ranged from 24h in some cases of shearing injury to 3 months in cases of osteoarthritis.

Clinical reassessment comprised complete clinical and orthopedic examination and was performed whenever possible. The presence of any gait abnormality and the presence or absence of pain, crepitation and articular edema were evaluated.

The age of the animals, including 12 (57.1%) males and nine (42.9%) females, ranged from 4 months to 10 years. Six (28.6%) of the 21

animals were younger than one year, 14 (66.7%) were from 1 to 6 years and one animal (4.7%) was over 10 years old. The weight of the animals ranged from 2 to 35kg, with 12 (57.1%) animals weighing less than 10kg, seven (33.4%) between 10 and 20kg and two (9.5%) more than 20kg.

Arthrodesis was performed in the carpal joint in eight (32%) cases, in the tarsal joint in 10 (40%), in the elbow in six (24%), and in the knee joint in one (4%).

The injuries presented by the animals included radial agenesis in two (9.5%); fracture of the calcaneus in three (14.3%); luxation due to shearing injury in seven (33.3%); fracture caused by a firearm projectile in one (4.5%); closed luxation, open luxation and osteoarthritis in two animals each (9.5% each); contracture of the carpal flexor tendons caused by fracture of the radius in one (4.5%); and fracture of the olecranon in one (4.5%).

Bilateral carpal arthrodesis was performed in one animal (Table 1, case 2). Two animals presented radial agenesis and were submitted to carpal and elbow arthrodesis (Table 1, cases 4 and 5). Three animals underwent pantarsal arthrodesis due to the extent of the injuries (Table 1, cases 12, 15 and 17).

The joints were prepared by debridement of articular cartilage using curettes and an electrical milling machine coupled to a high-rotation micro-rectifier, hand-held saws and bone files. The contour of the joint was preserved in all cases, except for the knee joint in which the femoral condyles and proximal portion of the tibia were sawed off, forming a platform to provide better coaptation of the two bones. After joint preparation, the defect produced by curettage was completely filled with granule hydroxyapatite (<177 μ m)¹ (Fig. 1).

The joints were positioned at angles predetermined with a goniometer, ranging from 175 to 180° for carpal joints, from 125 to 145° for tarsal joints, from 130 to 150° for elbow joints and an angle of 140° for knee joint.

¹ Biosynth Ltda, Campinas, São Paulo, Brazil

Table 1. Summary data: arthrodesis with treat by hydroxyapatite as graft bone in dogs and cats

Case No.	Species	Sex	Breed	Age	Weight (kg)	Type of injury	Treatment	TA	RF	Complications
1	Cat	M	Siamese	10 y	5	Luxation/osteoarthritis	Type IIb SF	60	E	Loosening of the proximal radial pin
2	Dog	F	Mongrel	6 m	8	Abrasion of the styloid process, central carpus, 2nd, 3rd and 4th distal carpals, and 3rd, 4th and 5th metacarpals. Abrasion of the styloid process, central carpus, and 3rd and 4th metacarpals	Transarticular pin Type II SF + cross-pins	60	E	
3	Dog	M	Mongrel	4 m	5	Abrasion of the styloid process, central carpus, 2nd, 3rd and 4th distal carpals, and 3rd, 4th and 5th metacarpals	Transarticular pin	60	E	
4	Dog	M	Dachshund	3 y	10	Elbow/radial agenesis, and of the arthrodesis	Elbow/non-union Type I SF + Transarticular pin in elbow Type I SF + screw for non-union.	60	G	Loosening of the proximal radial pin Non-union of the articular sides
5	Dog	M	Fox Paul.	3 m	4	Elbow/radial agenesis	Type I SF + Transarticular screw	60	P	Closure of the growth plate
6	Cat	M	Mongrel	5 m	2	Contracture of flexor tendons	Type IIb SF	30	G	Loosening of the fixation pins
7	Dog	F	Mongrel	3 y	4	Abrasion of the styloid process, central carpus, 2nd, 3rd and 4th distal carpals, and 3rd, 4th and 5th metacarpals	Cross-pins	60	E	
8	Dog	F	Pit Bull	1y	35	Distal fracture of the tibia and fibula due to a gunshot wound	Type II SF	60	E	
9	Cat	M	Siamese	1 y	5	Distal fracture of fibula/luxation	Type IIb SF	45	E	
10	Cat	F	Mongrel	2 y	5	Fracture of calcaneus/luxation	Type IIb SF + transarticular pin	60	E	
11	Dog	F	Pinscher	2 y	4	Fracture of calcaneus/luxation	Type I SF + screws and cerclage wire	60	E	
12	Dog	F	Pinscher	5 m	2	Abrasion of the medial malleolus and talus, central tarsus, 2nd and 3rd tarsals, and 2nd, 3rd pin	Type I SF + transarticular pin	60	E	
13	Dog	M	Akita	1 y	35	Abrasion of the medial malleolus and talus	Type IIb SF + transarticular pin	60	G	Loosening of the proximal fixation pin
14	Dog	M	Cocker Spaniel	6 m	15	Fracture of calcaneus/luxation	Type II SF + transarticular pin	60	G	Loosening of the proximal fixation pin
15	Dog	M	Mongrel	4 y	7	Abrasion of the medial malleolus and talus, central tarsus, 2nd and 3rd tarsals, and 2nd, 3rd and 4th metatarsals	Type I SF + transarticular pin	60	G	Surgical wound infection
16	Dog	F	Mongrel	4 y	10	Exposed tarsocrural luxation	Type IIb SF + transarticular pin	60	E	Loosening of the proximal fixation pin
17	Dog	M	Mongrel	1 y	15	Abrasion of the medial malleolus and talus, central tarsus, 2nd and 3rd tarsals, and 2nd, 3rd and 4th metatarsals	Type II SF	60	E	Loosening of the proximal (tibia) and distal (metatarsal) fixation pins
18	Dog	M	Poodle	3 y	12	Elbow/fracture of the olecranon	Type IIb SF + transarticular pin	60	E	
19	Dog	M	Dachshund	3 y	15	Elbow/luxation	Type IIb SF + transarticular pin	60	E	
20	Dog	F	Mongrel	4 y	10	Elbow/osteoarthritis	Type IIb SF + transarticular pin	60	E	
21	Dog	F	Mongrel	4 y	7	Stifle/osteoarthritis	Cross-pins + cerclage wire	60	E	

M: male; F: female; SF: skeletal fixator; TA: time of radiographic assessment (days) after the surgical procedure; RF: restoration of limb functionality (E: excellent; G: good; P: poor).

The joints were stabilized using pins, cerclage wires, screws and types I, II and IIb external fixators combined or not with pins, transarticular screws and cerclage wires as separately listed in Table 1.

The bone fixation pins of the external fixators were connected to polymethylmethacrylate bars. During the postoperative period, padded bandages were used to protect the limb and fixators. Three (14.3%) animals undergoing carpal arthrodesis also received an indirect pedicled skin flap on the lateral chest due to injuries caused by shearing trauma. The owners were advised to keep the animals in confinement until removal of the implants.

Empirical antibiotic therapy was adopted after surgery and consisted of the subcutaneous administration of 2.2mg/kg sodium ceftiofur² every 24h for 6 days. In cases of bone exposure, 25mg/kg metronidazole³ was additionally administered orally every 12h for 5 days. This procedure was also adopted for cases in which signs of infection or osteomyelitis persisted until the results of cultures and sensitivity tests permitted the most appropriate choice of antibiotic in each case. Additionally, 1.0mg/kg ketoprofen⁴ was administered

² Excenel®, Schering Plough Veterinária

³ Flagil®, Searle

⁴ Ketofen®, Meryal

subcutaneously every 24h for 3 days and 0.01mg/kg buprenorphine⁵ was injected intramuscularly every 12h for 3 consecutive days.

The animals were clinically and radiographically assessed immediately after surgery and on the 60th day; however, two animals were evaluated less than 60 days (case 6 on the 30th day and case 9 on the 45th day). The following aspects were analyzed: arthrodesis stability, loosening of the metal implants, presence of infection, exudate or signs of sequestration of the implanted bioceramic and bone union.

RESULTS AND DISCUSSION

The results obtained for each case are individually illustrated in Table 1. No formation of fistulas or a purulent exudate was observed during follow-up of the animals. During the immediate postoperative period, intense edema was noted in the extremity of the limb and around the pins, which persisted on average until day 8. Hot and cold compresses were administered as coadjuvant therapy to the anti-inflammatory drugs.

With respect to the degree of lameness, the animals were non-weightbearing on the operated limb on days 1st to 2nd after surgery, presented intermittent weightbearing lameness between days 4th and 6th, and continuous weightbearing until removal of the implants. Three animals (Table 1, cases 6, 17 and 21) were no longer weightbearing due to loosening of the metal implants during the evaluation period.

The bone fixation methods were well tolerated by the animals, with rapid restoration of limb functionality. Serous secretion was observed in most animals receiving external fixators, especially in the proximal pins, by postoperative on day 30th in case 6, day 45th in case 9 and day 60th in the other cases.

Radiographically, bone union was noted after 30 days in case 6, after 45 days in case 9 (Fig. 2) and after 60 days in the other animals submitted to arthrodesis with hydroxyapatite, except for one animal (Table 1, case 4). In this case, the non-union was due to instability of the bone fixation. A new arthrodesis was performed in this animal using a type I external fixator with hydroxyapatite and bone union was observed upon reassessment after 60 days (Fig. 3). In the two animals evaluated 30 days

after surgery (Table 1, cases 7 and 9), bone union was already present after this period.

No formation of fistulas or a purulent exudate that could be associated with the presence of hydroxyapatite was observed. Radiographic analysis revealed migration or excess of the biomaterial applied during the surgical procedure in soft tissues.

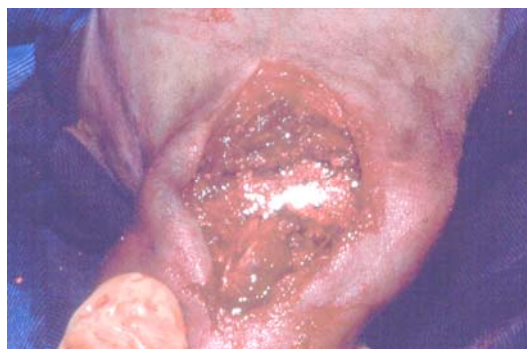

Figure 1. Photographic image of the surgical procedure of elbow arthrodesis. Hydroxyapatite was used to fill the bone defect.

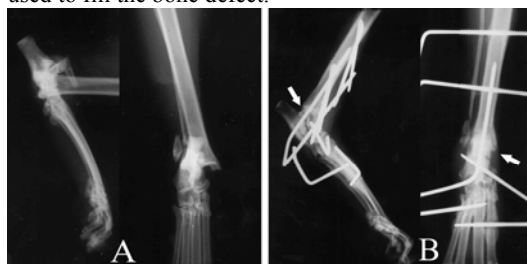

Figure 2. Radiographic images of traumatic luxation of the tarsocrural joint in a cat. (A) Forty-five days after tarsocrural arthrodesis. (B) Stable union of the arthrodesis (arrows).

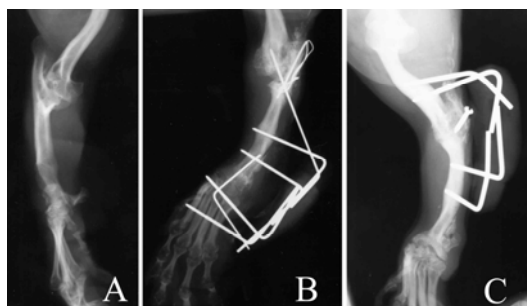


Figure 3. Radiographic images of carpal and elbow arthrodeses with hydroxyapatite in a Dachshund dog. (A) Radial agenesis. (B) Sixty days after the first surgical procedure. Bone union in the carpal joint and non-union in the elbow. (C) Sixty days after the second surgical procedure. Bone union in the elbow.

⁵ Tengesic®, Schering Plough

Evaluation of the bone fixation methods showed loosening of the pins of some external fixators and transarticular pins. However, there was no need to replace any fixation pin. Premature closure of the growth plates was observed in growing animals. In animal 5, which presented radial agenesis and functional impotence of the affected limb, the procedure only permitted the use of the limb as support due to limb shortening as a result of premature closure of the growth plate.

In this study, the relative outcomes of the 25 arthrodeses, in terms of limb functionality after removal of the fixation systems, were excellent in 68% of the cases, good in 20% and poor in 12%.

Arthrodesis is indicated in most cases as a limb saving method due to the impossibility of correction of alterations resulting from degenerative processes, for luxations in which functional reduction was not possible and for traumatic injuries that compromise limb functionality. Arthrodesis is also recommended for processes that involve chronic pain, instability and functional loss, restoring limb functionality (Penwick, 1987; Lesser, 1993; Johnson, 1995; Moak et al., 2000). Shanil et al. (2006) reported the successful use of type II external fixator that spans the tarsometatarsal joint in four dogs. This technique enables the patient to bear weight on the limb immediately after surgery until bony fusion is achieved. These authors reported the successful use of type II external fixator that spans the tarsometatarsal joint in four dogs.

According to Toombs (1992), the frequent use of ESFs in small animal orthopedics can be attributed to the improvement of fixator pin mechanics, insertion techniques of the implants and biomechanical characteristics of the different configurations. When ESFs are used as the exclusive method for stabilization in arthrodesis, these fixators should be strong enough to withstand folding, torsion, sliding and axial forces (Nieves, 2002). This author also emphasized that ESF devices should be used during the process of arthrodesis to evaluate the joint and to promote alignment and juxtaposition of the articular surfaces. According to Decamp et al. (2002), type I or type II ESFs can be used for the stabilization of tarsal shearing injuries for 4-6

weeks as an adjuvant or as the primary fixation, reducing or eliminating the orthopedic implant at the site of open luxation.

The lack of bone union in case 4 was due to instability of the bone fixation. Possible causes of arthrodesis failure, associated with other complications, include inadequate reduction, persistence of articular cartilage, failure in the application of the bone graft, infection, failure of fixation, diaphyseal fractures and early migration of the implants (Lesser, 1993; Johnson, 1995; Piermattei and Flo, 1997).

In the present study, the arthrodeses was evaluated immediately after surgery and on the 60th day. Bone fusion was observed on the 60th day in all but one case. The time to bone fusion in arthrodeses is variable, ranging from 4 to 8 weeks (Johnson, 1995). The times to bone fusion obtained in the present study were similar to those reported in the literature for experimental carpal arthrodesis in dogs using a fresh autogenous graft cancellous (Johnson and Belenger, 1980; Grumadas, 1987). This finding might be attributed to the osteoconductive capacity of hydroxyapatite which implies the simultaneous biodegradation and replacement of this material with new bone (Carrodeguas et al., 1999).

In the seven cases with shearing injuries and in the two cases with open luxations, no bone abnormalities that could be associated with infection were observed and the process of bone union occurred normally within a period similar to that observed for arthrodeses performed in the other animals described in this study.

Autogenous bone grafts are the gold standard, but host tissue is often scarce and can hardly be modeled to the shape required for successful reconstruction (Charrière et al., 2002). In addition, two surgical procedures are necessary for the collection of autogenous bone graft, with a consequent longer duration of surgery, increased postoperative pain, blood loss and possible contamination of the collection site (Stevenson, 1993; Paker, 1995; Fitch et al., 1997). Bioceramics are advantageous since they are available in large amounts and possess a chemical composition similar to that of vertebrate mineral phases, in addition to their properties of biocompatibility, bioactivity and

osteoconductivity. These materials have been proven to be efficient as bone substitutes (Carrodeguas et al., 1999; Nicolazo et al., 2003).

Calcium phosphate is prepared in powder, granule or block form. The hydroxyapatite used in the present cases in the form of granules migrated outside the joint at the time of implantation, absorbing humidity and modifying its physical conformation to a more pasty consistency. The adjacent soft tissues were affected as can be seen on the radiographs. In animals in which the arthrodeses were redone, hydroxyapatite was present in the soft tissues scattered around the joints. Driessens et al. (1998) also reported that hydroxyapatite granules may migrate outside the implantation site reaching the soft tissues leading to adverse reactions and even expulsion of the material.

Hydroxyapatite was chosen for filling of the articular space created by curettage based on its frequent application in medicine and dentistry and because it is one of the most biocompatible materials known (Blokhuys et al., 2000). The biocompatibility of hydroxyapatite is attributed to its hexagonal crystal structure and similarity to the mineral phase of bone tissue, in addition to the porosity of the bioceramic that influences its osteoconductivity by serving as a framework for the migration of blood vessels and deposition of new bone (Blokhuys et al., 2000). A similar phenomenon has also been reported by Steveson (1993) and Parker (1995) for bone grafts. In experimental tarsocrural arthrodesis using hydroxyapatite as a bone graft substitute, articular fusion was observed within 30 days, i.e., 15 days more than for the control group without a fresh autogenous graft cancellous (Dórea Neto, 2002).

Despite the extensive and frequent use of hydroxyapatite in medicine and dentistry, in veterinary medicine its application is restricted almost exclusively to experimental procedures in which the material is implanted at various sites but only for assessment of its biocompatibility. These studies have also reported satisfactory results in terms of the incorporation and osteointegration of hydroxyapatite and bone growth between the ceramic and host bone (Daculsi et al., 1989; Fuller et al., 1996; Delécrin et al., 1997; Dórea Neto, 2002). A scanning electron microscopy study of experimental

tarsocrural arthrodesis has demonstrated the presence of bone-bioceramic integration and the absence of gap formation (Dórea Neto, 2002). Histologically, there was active remodeling of host bone accompanied by the presence of giant cells, multinuclear osteoclasts and basophilic osteoblasts. In addition, absorption of hydroxyapatite was observed parallel to the formation of new bone, a finding that, according to this author, encourages the use of hydroxyapatite in arthrodeses.

CONCLUSION

The clinical and radiographic results regarding bone union of the arthrodeses obtained with the use of hydroxyapatite indicate this material to be a promising bone substitute in small animal surgical practice.

ACKNOWLEDGMENTS

The authors thank Fundação de Amparo a Pesquisa do Estado de São Paulo (FAPESP) for financial support (grants 00/007715-5 and 00/12655-1).

REFERENCES

- BLOKHUIS, T.J.; TERMAAT, M.F.; DEN BOER F.C. et al. Properties of calcium phosphate ceramics in relation to their in vivo behavior. *J. Trauma*, v.48, p.179-186, 2000.
- CARRODEGUAS, R.G., SANTOS, L.A., OLIVEIRA, L.C. et al. Cimentos de alfa-fosfato tricálcico de fraguado doble. *Rev. CENIC – Cien. Quim.*, v.30, p.153-158, 1999.
- CHARREIÈRE, E.; LAMAITRE J.; ZYSSET, PH. Hydroxyapatite cement scaffolds with controlled macroporosity: fabrication protocol and mechanical properties. *Biomaterials*, v.24, p.809-817, 2002.
- DACULSI, G.; PASSUTI, N.; MARTIN, S. et al. Comparative study of bioactive calcium phosphate ceramics after implantation in spongy bone in dogs. Histologic, ultrastructural and electron probe microanalysis. *Rev. Chir. Orthop.*, v.75, p.65-71, 1989.
- DECAMP, C. E. External skeletal fixation. *Proceedings... Western Veterinary Conference 2002*. Accessed February 15, 2006. Online. Available at <http://www.vin.com/Members/Proceedings>.

- DELECRIN, J.; AGUADO, E.; NGUYEN, J.N. et al. Influence of local environment on incorporation of ceramic for lumbar fusion. Comparison of laminar and intertransverse sites in a canine model. *Spine*, v.22, p.1683-1689, 1997.
- DÓREA NETO, F.A. *Avaliação da hidroxiapatita em artrodeses experimentais e em ensaio clínico*. 2003. 71f. Dissertação (Mestrado) – Faculdade de Ciências Agrárias e Veterinárias, Universidade Estadual Paulista, Jaboticabal, SP.
- DRIESENS, F.C.M.; BOLTONG, M.G.; DE MAEYER, E.A.P. et al. In: _____ LEGEROS R.Z., LEGEROS J.P. (Eds). *Bioceramics*, New York: World Scientific Publishing, 1998. v.11, p.231-233.
- FITCH, R.; NEWMAN-GAGE, H.; SINIBALDI, K.R. Bone autografts and allografts in dogs. *Comp. Cont. Educ. Pract. Vet.*, v.19, p.558-575, 1997.
- FULLER, D.A.; STEVENSON, S.; EMETY, S.E. The effects of internal fixation on calcium carbonate. Ceramic anterior spinal fusion in dogs. *Spine*, v.21, p.2131-2136, 1996.
- GRUMADAS, C.E.S. *Pan-artrodese do carpo na correção de instabilidade articular provocada experimentalmente por neurectomia do radial em caninos*. 1987. 77f. Dissertação (Mestrado) – Universidade Federal de Santa Maria, Santa Maria, RS.
- JOHNSON, K.A. Arthrodesis. In: _____ OLMSTEAD, M.L. *Small animal orthopedics*. 3.ed, Philadelphia: Mosby, 1995. p.503-529.
- JOHNSON, K.A.; BELENGER, C.R. The effects of autologous bone grafting on bone healing after carpal arthrodesis in the dog. *Vet. Rec.*, v.107, p.126-132, 1980.
- LEGEROS, R.Z. Calcium phosphate in oral biology and medicine. In: _____ MYERS, H.M. *Monographs in oral science*. Basel: Karger, 1991. p.210.
- LESSER, A.S. Arthrodesis. In: _____ SLATTER, D. *Textbook of small animal surgery*. 2.ed., Philadelphia: Saunders, 1993. v.2, p.1888-1900.
- MOAK, P.C.; LEWIS, D.D.; ROE, S.C. et al. Arthrodesis of the elbow in three cats. *Vet. Comp. Orthop. Traumatol.*, v.13, p.149-153, 2000.
- NIEVES, M. A. Tarsal luxation. *Proceedings... Western Veterinary Conference 2002*. Disponível em Feb. 15, 2006. <<http://www.vin.com/Members/Proceedings>>. Acessado em 15 fev.2006.
- NICOLAZO, C.; GAUTIER, H.; BRANDÃO, M.J. et al. Compactibility study of calcium phosphate biomaterials. *Biomaterials*, v.24, p.255-262, 2003.
- PARKER, R.B. Injertos ósseos en cirugía de pequeños animales. *Waltham Focus*, v.5, p.90-99, 1995.
- PENWICK, R.C. Arthrodesis. *Vet. Clin. N. Am.: Small Anim. Pract.*, v.17, p.811-819, 1987.
- PIERMATTEI, D.L. Approach to distal radius and carpus through a dorsal incision. In: _____. *An atlas of surgical approaches to the bones and joints of the dog and cat*. 3.ed. Philadelphia: Saunders, 1993. p.204-205.
- PIERMATEI, D. L., FLO, G. L. Arthrology. In: _____. *Handbook of small animal orthopedics and fracture repair*. 3.ed. Philadelphia: Saunders. 1997. p.170-200.
- SHANIL, J.; WESHURUN, Y.; SHAHAR, R. et al. Arthrodesis of the tarsometatarsal, using type II ESF with acrylic connecting bars in four dogs. *Vet. Comp. Orthop. Traumatol.*, v.19, p.61-63, 2006.
- STEVESON, S. Bone grafting. In: _____ SLATTER, D. *Textbook of small animal surgery*. 2.ed, Philadelphia: Saunders, 1993. v.2, p.1694-1703
- TOOMBS, J.P. Transarticular application of external skeletal fixation. *Vet. Clin. N. Am.: Small Anim. Pract.*, v.22, p.181-194, 1992.
- TROSTEL, C.T.; RADASCH, R.M. Tarsocrural arthrodesis: a clinical report using a circular external fixator. *Vet. Comp. Orthop. Traumatol.*, v.11, p.193-196, 1998.
- TURNER, T.M.; LIPOWITZ, A. J. Artrodese. In: _____ BOJRAB, J. M. *Técnicas atuais em cirurgia de pequenos animais*. 3.ed., São Paulo: Roca, 1996. p.775-93.