

# Reatividade da proteína p53 em lesões odontogênicas: Um estudo imunohistoquímico

## *P53 protein reactivity in odontogenic lesions: An immunohistochemical study*

OLIVEIRA, Márcia Gaiger de\*  
LAUXEN, Isabel da Silva\*\*  
FILHO, Manoel Sant'Ana\*\*\*

### ABSTRACT

The purpose of this study was to investigate p53 immunoeexpression in some odontogenic lesions. Fifty-seven odontogenic lesions were studied: 12 radicular cysts, 17 dentigerous cysts, 16 calcifying odontogenic cysts and 12 parakeratinized odontogenic keratocyst. All samples were stained for p53. The number of positive cells and staining intensity varied for the different types of lesions. Radicular cysts had the greatest number of positive cells, followed by calcifying odontogenic cysts. Most of the positive cells in the parakeratinized odontogenic keratocysts were in the suprabasal layer. Both parakeratinized odontogenic keratocysts and calcifying odontogenic cysts showed more intense and better defined staining than the other types of cysts. Considering the characteristics of odontogenic keratocysts and the fact that their p53 expression is similar to that of calcifying odontogenic cysts, we suggest that odontogenic keratocysts should be classified as tumors.

### KEYWORDS

p53. Odontogenic lesions. Immunohistochemistry.

### INTRODUCTION

The p53 gene, located on chromosome 17p13, encodes a nuclear phosphoprotein that is believed to control cell growth at the G1/S checkpoint. The p53 gene and its protein product have become the focus of intensive study ever since it became clear that slightly more than 50% of all human cancers contain mutations in this gene (LEVINE, 1997; NYLANDER et al., 2000; SOUSSI, 2003).

In a cell, the p53 protein is usually kept at a low concentration by its relatively short half-life (about 20 minutes). In addition to this low protein concentration, the p53 protein is probably also present in some cells in a latent form, inactive for transcription. Under this condition, it must receive a signal or detect an alteration to be activated. The upstream events or signals that flow to p53 are mediated by several stressful situations. The p53 concentration increases when the protein half-life is lengthened, probably because the rate of translational initiation of p53 mRNA in the cells is enhanced (LEVINE, 1997).

Wild-type p53 can suppress or inhibit the transformation of culture cells by viral or cellular oncogenes, reduce or eliminate the tumorigenic potential of a cell line in culture, and arrest the cell cycle of a transformed cell at the G1 phase, whereas the mutant forms show dominant oncogene properties that

promote cell proliferation and malignant transformation (LEVINE, 1997).

Expression of high levels of wild-type (but not mutant) p53 has two outcomes: cell cycle arrest or apoptosis. Although not required for viability, p53 acts as an "emergency brake" in response to genotoxic stress, inducing either arrest or apoptosis, and protecting the genome from accumulating excess mutations (KO; PRIVES, 2003).

According to Soussi (2003) the difficulties in understanding p53 have been exacerbated by the marked diversity of methodological approaches. One of the major misleading approaches is the comparison of immunohistochemical analysis used to evaluate the accumulation of stable p53 mutations in tumor cells with molecular analyses to demonstrate the nature of the mutational events that inactivate the p53 gene.

Immunohistochemical detection of p53 protein is frequently associated with the presence of p53 gene mutation, suggesting that the mutant product may be more stable than the wild-type product, which is not always detected by immunohistochemistry.

It is still unclear whether p53 immunohistochemical expression indicates p53 gene mutation or overexpression of the wild-type product due to stabilization by other gene products (LI et al, 1996).

Some antibodies used for immunohistochemical analysis of paraffin embedded ma-

terial recognize wild-type as well as mutant p53 proteins. The wild-type usually has a very short half-life, and it is difficult to detect it with antibodies. However, under certain conditions, the wild-type protein may be retained in the tissue by some defect in the normal degradation pathway, and may therefore be detected by antibodies. It is very important to keep in mind that the "retained" wild-type protein is inactive, either due to blocking by another protein or to partial degradation (NYLANDER et al., 2000).

A study undertaken by Pillai et al. (2003) investigated the staining properties of two widely used antibodies to p53, DO7 and 1801 (DAKO), in normal tissues. The results showed that both detect wild-type p53, but the DO7 antibody detects it more reliably in normal tissues. Those authors believe that DO7 is a more robust antibody for the detection of wild-type p53.

The epithelial lining of odontogenic cysts and tumors is derived from primitive oral epithelium of the oral mucosa, and contributes to tooth formation. Such epithelial cells are the common origin of odontogenic lesions, but the molecular mechanisms of the development of odontogenic lesions is not completely understood.

Odontogenic keratocysts behave differently from other types of cysts, such as dentigerous or radicular cysts, in that they have a more aggressive biological behavior with a

\*DDS, MsC in Oral Pathology, Federal University of Rio Grande do Sul (UFRGS)

\*\* Biologist, Oral Pathology Laboratory, Federal University of Rio Grande do Sul (UFRGS)

\*\*\* DDS, PhD, Professor of Oral Pathology, Federal University of Rio Grande do Sul (UFRGS)

marked tendency to recurrence. Some authors believe that odontogenic keratocysts should be classified as benign cystic tumors.

This study examines three types of odontogenic cysts - odontogenic keratocysts, dentigerous cysts and radicular cysts - and one type of odontogenic tumor, calcifying odontogenic cysts, and compares their immunohistochemical expression of p53.

#### MATERIALS AND METHODS

A total of 57 specimens were retrieved from the files of the Oral Pathology Laboratory, School of Dentistry, Universidade Federal do Rio Grande do Sul (Porto Alegre, RS, Brazil). The following formalin-fixed, paraffin-embedded tissues were used in this study: 12 radicular cysts (RC), 17 dentigerous cysts (DC), 16 calcifying odontogenic cyst (COC), and 12 parakeratinized odontogenic keratocyst (OKCp). All selected samples had been routinely fixed in 10% neutral buffered formalin, dehydrated in graded alcohols, cleared in xylene, and embedded in paraffin. The slides stained with hematoxylin-eosin were all reviewed and the diagnoses were confirmed on the basis of their clinical, radiological and histopathological features.

Immunohistochemical staining for p53 protein was performed at the Immunohistochemistry Laboratory, Armed Forces Institute of Pathology (Washington DC, USA) using a standardized EnVision™+ (DAKO Corporation, CA, USA) method. Sections (4 µm thick) were deparaffinized in 2 changes of xylene for 10 minutes each, rehydrated through graded alcohols, and immersed in 0.3% hydrogen peroxide in methanol for 5 minutes to block endogenous peroxidase. Sections were then washed in phosphate-buffered saline (PBS). Epitope retrieval was performed by using citrate buffer pH 6.0 (Dako Corporation, Carpinteria, CA, USA) and heated for 20 minutes in a steamer. Following this, the sections were allowed to cool at room temperature in a citrate buffer solution for 45 minutes. The p53 antibody (mouse monoclonal anti-human; DO-7, DAKO Cytomation, Carpinteria, CA; dilution 1:200) reactive to both wild-type and mutant p53 was used in a DAKO Autostainer.

Sections from a breast cancer were used as positive control, and a negative control was obtained by omitting the primary antibody.

The slides were washed in 2 changes of water and counterstained with Mayer's hematoxylin. The sections were then rehydrated, cleared in xylene and mounted in Permount (FisherScientific, Pittsburgh, PA).

For quantitative analysis of p53 positive cells, the slides were examined with a Nikon optical microscope, Eclipse E200 model, at 400x magnification. The full length of the

lining epithelium was observed, and the image, under a fixed focus and with a clear field, was captured by a digital camera (Nikon Coolpix 995) and analyzed by ImageTool for Windows version 3.00 (UTHSCSA-University of Texas Health Science Center in San Antonio). The positivity to p53 protein was evaluated by counting the number of positive cells per 1000 epithelial cells for each case, 500 from the basal layer and 500 from the suprabasal layer. Only nuclear staining of epithelial cells was recorded, and the nuclei with brown color, regardless of staining intensity, were considered p53 positive. This procedure was applied for cells from the basal and suprabasal layers. The superficial cells were not counted.

The criterion used to identify the cells on the suprabasal layer was the nuclear morphology. The cells above the basal layer with a spherical nucleus were classified as suprabasal cells; the cells with a flattened nuclear form were classified as superficial and were not counted.

Friedman, Mann-Whitney U and Kruskal-Wallis tests were used to evaluate statistically significant differences. Statistical significance was established at  $p < 0.05$ .

#### RESULTS

Table 1

The results show that all the lesions studied had p53 immunoreactivity (Table 1). The number of positive cells, the distribution of these cells, and the intensity of staining varied from lesion to lesion.

Graph 1

The radicular cysts had the greatest number of p53 positive cells, followed by the calcifying odontogenic cysts (Graph 1).

When comparing the basal layer with the suprabasal layer in each lesion, a significant difference was found for radicular cysts ( $P = .035$ ), which had a greater number of positive cells in the basal layer, and for odontogenic keratocysts ( $P = .021$ ), in which the greatest number of positive cells was in the suprabasal layer.

Comparing p53 positivity in the basal layer, a significant difference was found between radicular cysts and dentigerous cysts ( $P = .021$ ), and between radicular cysts and odontogenic keratocysts ( $P = 0.05$ ); in both cases radicular cysts showed a greater number of positive cells in the basal layer. The comparison of results for the suprabasal layers did not reveal any significant differences.

Most odontogenic keratocysts and calcifying odontogenic cysts had more intense and better defined staining than radicular and dentigerous cysts.

#### DISCUSSION

The expression of p53 in odontogenic lesions has been investigated in several studies, but the results reported are quite conflicting (ODGEN et al., 1992; LOMBARDI et al., 1995; LI et al., 1996; CARVALHAIS et al., 1999; MUZIO et al., 1999; PIATELLI et al., 2002).

In this study, all lesions had immunoreactivity to p53. This may, to a certain extent, be explained not only by the analysis criteria adopted - all cells with brown nuclear staining, regardless of color intensity, were classified as positive -, but also by the immunohistochemical technique used, which was performed with the EnVision+ system (DAKO Corporation, Carpinteria, CA, USA), a very sensitive detection system.

Studies in the literature report that p53 immunohistochemical detection may be affected by many technical variables, such as the use of different antibody clones, antigen absolute concentration, antibody affinity, antibody dilution, incubation time, detection system sensitivity, fixation, and performance of antigen retrieval (WYNFORD-THOMAS, 1992; LAMBKIN et al., 1994; HALL; LANE, 1994; DOWELL; ODGEN, 1996).

Most of the studies associate protein p53 immunohistochemical expressivity with a variety of malignant tumors that show mutations in the p53 gene (ODGEN et al., 1992a; 1992b; TRIVEDI et al., 1998; COLETTA et al., 2001). It is important to point out that the DO-7 antibody (DAKO), used in this study, detects both the wild-type and mutated p53, and that Pillai et al. (2003), reported that this antibody can detect wild-type p53 more reliably in normal tissues.

Therefore, the concept that p53 immunoreexpression occurs only due to p53 gene mutations should be reviewed. It is known that cell environment can affect the stability of the p53 protein. Hudson et al. (1999) in an in vitro study, suggested that p53 may be inactivated by a pro-inflammatory cytokine released from T cells and macrophages. Interleukin-6, a cytokine that induces cell differentiation, is also a factor that inhibits the p53 apoptotic function (YONISH-ROUACH et al., 1991). Jarnbring et al. (2002) found p53 expression in gingival biopsies of patients with periodontitis and gingivitis, and observed dense inflammatory infiltrate in all sections.

Recent studies have shown that wild-type p53 stabilizes in the absence of mutation. Also, it becomes detectable by immunohistochemistry when forming a complex with the MDM2 gene protein, when degraded by HPV E6 protein, and when certain physiological mechanisms are active, such as DNA damage, hypoxia, or other relevant but not yet clearly defined mechanisms (NYLANDER et al., 2000). For these reasons, the overexpressi-

on of p53 protein detected by immunohistochemistry may or may not be indicative of p53 gene mutation.

Nylander et al. (2000), suggested that p53 expression in epithelial cells may be caused by gene mutation, by accumulation of wild-type protein as a result of a defect in normal degradation pathways, or by binding to other proteins. In our study, due to the antibody used, we were not able to distinguish mutant p53 from wild-type p53 protein. However, the lesions studied and the number of stained cells led us to the conclusion that most of our results correspond to wild-type p53.

The description of differences in staining patterns in the different lesions analyzed, although not the purpose of this study, revealed important features. Calcifying odontogenic cysts and odontogenic keratocysts had more intense and better defined staining than dentigerous and radicular cysts.

According to Nylander et al. (2000) the evaluation of staining intensity is very difficult because intensity depends on several variables, such as pre-treatment, antibody concentration, and room temperature. Those authors point out that intensity can only be evaluated when the technique is carried out under reproducible conditions, such as when a programmable staining machine is used. In our study, all the staining was done following the same protocol and using a programmable machine and controlled room temperature, which allowed us to evaluate the intensity of staining.

The radicular cyst, an inflammatory lesion, has a high number of p53 positive cells, which may be attributed to the inflammatory stimulus. Most of the lesions analyzed had a dense inflammatory infiltrate, and the epithelium showed signs of reaction to this stimulus. Most of the p53 positive cells were located in the basal layer of the epithelium, indicating that the cells were active, probably by induction of the inflammatory stimulus. The distribution of the positive cells suggested that p53 expression in radicular cysts may be associated with cell proliferation. The intensity of staining in this type of lesion was usually weaker than in odontogenic keratocysts or calcifying odontogenic cysts (Figure 1-a,b,c).

According Cruz et al. (1998) the p53 protective role is exerted during cell cycle, as the majority of studies performed so far indicate and that the proliferative compartment of the normal oral epithelium is the basal cell layer, one expects that p53 protein, when detectable in normal epithelium, will be restricted to the basal cell layer.

In dentigerous cysts, staining intensity was weak, and a larger number of positive cells were found in the basal layer (Figure 1-d). The highest numbers of positive cells were

usually found in areas of more intense inflammatory infiltrate.

Our results suggest that the inflammatory stimulus increases the proliferation rate of epithelial cells in dentigerous cysts and, more markedly, in radicular cysts. With proliferation, more cells pass by the check point, and consequently more cells express p53. Furthermore, the inflammatory cytokine may be a stabilization factor of wild-type p53. This would explain the high number of p53 positive cells and the weak intensity of staining found mainly in the basal layer, probably because cells are undergoing proliferation and differentiation.

Recently, Kaplan and Hirshberg (2004) demonstrate a local increase in Ki-67 expression in the metaplastic epithelium of the odontogenic keratocyst in areas with moderate to severe inflammation. However, they consider that inflammation did not affect the overall proliferation activity of the epithelial lining of odontogenic keratocyst cases.

In the odontogenic keratocysts of our study, most of the p53 positive cells were in the suprabasal layer (Figure 1-b), showing that this type of lesion has different characteristics. In this case, the positivity of cells is not associated with an inflammatory stimulus, which was demonstrated by the fact that the lesions analyzed did not have inflammatory infiltrates. Previous studies with AgNOR and PCNA as proliferation markers in odontogenic keratocysts revealed a high proliferation rate of epithelial cells in these cysts, and a distribution of the proliferative cells predominantly in the suprabasal layer (OLIVEIRA et al. 2001). These studies found an association between the cells in proliferation and p53 positive cells, which shows that, in this type of lesion, a number of epithelial cells are proliferating more than usual and that the control of the cell cycle may have been altered.

Piatelli et al. (2002) reported that p53 positivity in the suprabasal layer of epithelium of some oral lesions is usually found when there is some disorder in growth regulation or cell differentiation. Those authors found positivity stainings only in the basal layer in the normal buccal epithelium, whereas p53 expression was found in the suprabasal and basal layers in leukoplakia, dysplasia and carcinoma.

Calcifying odontogenic cysts, which are neoplastic lesions, also had a high number of p53 positive cells both in the basal and suprabasal layers (Figure 1-c). This should be expected in a tumoral lesion in which the cells have a growth regulation and differentiation disorder.

In odontogenic keratocysts and calcifying odontogenic cysts, p53 expression had different characteristics, such as a high number of positive cells in the suprabasal layer

and intense staining. These findings suggested some alteration in cell regulation or differentiation, or even some DNA damage that stabilizes wild-type p53, which has a higher expression in these cells. Mutated cells may also be present and be expressed without function, and thus be unable to correct damage or take the cell to apoptosis. However, as this was an immunohistochemical study, we were not able to define whether p53 positive cells were mutated.

Studies have shown p53 positive staining in the odontogenic keratocyst epithelial lining using polyclonal and/or monoclonal antibodies for mutant and wild-type p53 (LI et al., 1996; ODGEN et al., 1992; LOMBARDI et al., 1995; SLOOTWEG et al., 1995). According to these studies, p53 overexpression in odontogenic keratocysts may indicate the physiological pattern of the wild-type protein instead of the gene mutation, and be associated with cell proliferation. The absence of gene mutation was reported by Li et al. (1996) in their molecular analysis of odontogenic keratocysts samples.

The literature presents abundant evidence to support the suggestion that odontogenic keratocyst is a benign cystic tumor (SHEAR, 2002a; 2002b; 2002c). Agaram et al. (2004), showed that there is a significant loss of heterozygosity of the tumoral suppressor genes, mainly p16, p53, PTCH and MCC in odontogenic keratocysts. According to those authors, the presence of these allelic losses lends substantial support to the hypothesis that odontogenic keratocysts are neoplastic lesions.

We agree with Pillai et al. (2003) that further molecular studies will have to be undertaken to determine the exact mechanisms of p53 accumulation in normal tissues.

Considering the more aggressive clinical behavior of odontogenic keratocysts and their high recurrence rate, comparable to that of tumors, as well as previous cell proliferation studies with AgNOR, PCNA (OLIVEIRA et al., 2001) and p53 expression that showed them to be similar to calcifying odontogenic cysts, which are already classified as tumors, we suggest that odontogenic keratocysts be classified as tumors rather than as odontogenic cysts.

## RESUMO

O objetivo deste estudo foi investigar a expressão da p53 em algumas lesões odontogênicas. Foram selecionadas 57 lesões odontogênicas: 12 cistos radiculares, 17 cistos dentígeros, 16 cistos odontogênicos calcificantes e 12 ceratocistos odontogênicos paraceratinizados. Todos os espécimes foram marcados, pela técnica da imunohistoquímica, para a p53. O número de células positivas e a intensidade de marcação varia-

ram nos diferentes tipos de lesão. Os cistos radiculares apresentaram o maior número de células positivas seguido pelo cisto odontogênico calcificante. A maioria das células positivas nos ceratocistos odontogênicos estavam localizadas na camada suprabasal. Tanto o ceratocisto odontogênico quanto o cisto odontogênico calcificante apresentaram marcação mais intensa e melhor definida que os outros tipos de cistos. Considerando as características do ceratocisto odontogênico e a expressão da p53 semelhante ao cisto odontogênico calcificante, os autores sugerem que o ceratocisto odontogênico seja classificado como uma lesão tumoral.

#### **PALAVRAS-CHAVE**

p53, Lesões odontogênicas, Imunohistoquímica.

#### **ACKNOWLEDGEMENTS**

We are especially grateful to Dr. Lester Thompson for giving us the opportunity to learn from him and to allow our access at AFIP's immunohistochemical lab. We also thank Wanda King and Renne for technical laboratory facilities. We wish to thank BIOGEN Ltda (Dako Cytomation representative office in Brazil) that support part of this research project.

#### **REFERENCES**

- AGARAM, N.P. et al. Molecular Analysis to Demonstrate that Odontogenic Keratocyst are Neoplastic. **Arch. Pathol. Lab. Med.**, Chicago v.128, no.3, p. 313-317, Mar. 2004.
- CARVALHAIS, J.N. et al. p53 and MDM2 Expression in Odontogenic Cysts and Tumors. **Oral Dis.**, Copenhagen, v.5, no. 3, p.218-222, July. 1999.
- COLETTA, R.D. et al. Basaloid Squamous Carcinoma of the Oral Cavity: Report of 2 Cases and Study of AgNOR, PCNA, p53 and MMP Expression. **Oral Surg. Oral Med. Oral Pathol. Oral Radiol. Endod.**, St. Louis, v.91, no.5, p.563-569, May 2001.
- CRUZ, I.B. et al. p53 Expression Above the Basal Cell Layer in Oral Mucosa is an Early Event of Malignant Transformation and has Predictive Value for Developing Oral Squamous Cell Carcinoma. **J. Pathol.**, Copenhagen, v.184, no.4, p.360-368, Apr. 1998.
- DOWELL, S.P.; ODGEN, G.R. The Use of Antigen Retrieval for Immunohistochemical Detection of p53 Over-expression in Malignant and Benign Oral Mucosa: a Cautionary Note. **J. Oral. Pathol. Med.**, Copenhagen, v.25, no.2, p.60-64, Feb. 1996.
- HALL, P.A.; LANE, D.P. Editorial: p53 in Tumor Pathology: Can We Trust Immunohistochemistry? – revisited! **J. Pathol.**, London, v.172, no.1, p.1-4, Jan.1994.
- HUDSON, J.D. et al. A Proinflammatory Cytokine Inhibits p53 Tumor Suppressor Activity. **J. Exp. Med.**, New York, v.190, n.º.10, p.1375-1382, Nov 1999.
- JARNBRING, F. et al. Quantitative Assessment of Apoptotic and Proliferative Gingival Keratinocytes in Oral and Sulcular Epithelium in Patients with Gingivitis and Periodontitis. **J. Clin. Periodontol.**, Copenhagen, v.29, no.12, p.1065-1071, Dec. 2002.
- KAPLAN, I.; HIRSHBERG, A. The Correlation Between Epithelial Cell Proliferation and Inflammation in Odontogenic Keratocyst. **Oral Oncol.**, Oxford, v.40, no.10, p.985-91, Nov. 2004.
- KO, L.; PRIVES, C. p53: Puzzle and Paradime. **Genes Dev.**, New York, v.10, no.9, p.1054-1072, May 1996.
- LAMBKIN, H.A.; MOTHERSILL, C.M.; KELEHAN, P. Variations in Immunohistochemical Detection of p53 Protein Overexpression in Cervical Carcinomas with Different Antibodies and Methods of Detection. **J. Pathol.**, London, v.172, no.1, p.13-18, Jan. 1994.
- LEVINE, A.J. p53, the Cellular Gatekeeper for Growth and Division. **Cell**, Cambridge, v.88, no.7, p.323-331, Feb. 1997.
- LI, T.J. et al. p53 Expression in Odontogenic Keratocyst Epithelium. **J. Oral Pathol. Med.**, Copenhagen, v.25, no.5, p.245-55, May 1996.
- LOMBARDI, T.; ODELL, E.W.; MORGAN, P.R. p53 Immunohistochemistry of Odontogenic Keratocysts in Relation to Recurrence, Basal Cell-budding and Basal-cell Naevus Syndrome. **Arch. Oral Biol.**, Oxford, v.40, no.12, p.1082-1084, Dec. 1995.
- MUZIO, L.; STAIBANO, S.; PANNONE, G. et al. Expression of Cell Cycle and Apoptosis-related Proteins in Sporadic Odontogenic Keratocysts and Odontogenic Keratocysts Associated with the Nevoid Basal Cell Carcinoma Syndrome. **J. Dent. Res.**, Alexandria, v.78, no.7, p.1345-1353, July. 1999.
- NYLANDER, K.; DABELSTEEN, E.; HALL, P.A. The p53 Molecule and its Prognostic Role in Squamous Cell Carcinomas of the Head and Neck. **J. Oral Pathol. Med.**, Copenhagen, v.29, no.9, p.413-25, Oct. 2000.
- OGDEN, G.R. et al. p53 Protein in Odontogenic Cysts: Increased Expression in some Odontogenic Keratocysts. **J. Clin. Pathol.**, London, v.45, no. 11, p.1007-1010, Nov. 1992. (a)
- OGDEN, G.R. et al. Assesment of p53 Protein Expression in Normal, Benign and Malign Oral Mucosa. **J. Pathol.**, London, v.166, no.4, p.389-394, Apr. 1992. (b)
- OLIVEIRA, M.G. et al. Quantificação de AgNORs e Expressão da PCNA em Ceratocisto Odontogênico. **Rev. Fac. Odontol.**, Porto Alegre, v.43, no.2, p.51-56, Dec. 2001.
- PIATELLI, A. ET AL. p53 Protein Expression in Odontogenic Cysts. **J. Endod.**, Baltimore, v.27, no. 7, p.459-61, July 2001.
- PIATELLI, A. et al. Prevalence of p53, bcl-2 and Ki-67 Immunoreactivity and of Apoptosis in Normal Epithelium and in Premalignant and Malignant Lesions of the Oral Cavity. **J. Oral Maxillofac. Surg.**, Philadelphia, v.60, no.5, p.532-540, May 2002.
- PILLAI, G. et al. p53 Expression in Normal Paraffin-embedded Tissue using Different Antibodies and Antigen Retrieval Buffer Systems. **Histopathology**, Oxford, v.42, no.1, p.83-87, Jan. 2003.
- SHEAR, M. The Agressive Nature of the Odontogenic Keratocyst: is it a Benign Cystic Neoplasm? Part I. Clinical and Early Experimental Evidence of Agressive Behavior. **Oral Oncol.**, Oxford, v.38, no.3, p.219-26, Apr. 2002. (a)
- SHEAR, M. The Agressive Nature of the Odontogenic Keratocyst: is it a Benign Cystic Neoplasm? Part II. Proliferation and Genetic Studies. **Oral Oncol.**, Oxford, v.38, no.4, p.323-31, Jun. 2002. (b)
- SHEAR, M. The Agressive Nature of the Odontogenic Keratocyst: is it a Benign Cystic Neoplasm? Part III. Immunocytochemistry of Cytokeratin and other Epithelial Markers. **Oral Oncol.**, Oxford, v.38, no.5, p.407-15, Jul. 2002. (c)

SLOOTWEG, P.J. p53 Protein and Ki-67 Reactivity in Epithelial Odontogenic Lesions. An Immunohistochemical Study. **J. Oral Pathol. Med.**, Copenhagen, v.24, no.9, p.393-7, Oct. 1995.

SOUSSE, T. Focus on the p53 Gene and Cancer: Advances in TP53 Mutation Research. Editorial. **Hum. Mutat.**, New York, v. 21, no.3, p.173-175, Mar.2003.

TRIVEDY, C. et al. p53 Aberrations in Oral Submucous Fibrosis and Oral Squamous Cell Carcinoma Detected by Immunocytochemistry and PCR-SSCP. **J. Oral Pathol. Med.**, Copenhagen, v.27, no.2, p.72-7, Feb.1998.

YONISH-ROUACH, E. et al. Wild-type

p53 Induce Apoptosis of Myeloid Leukaemic Cells that is Inhibited by Interleukin-6. **Nature**, Basingstoke, v.352, no.6333: 345-347, July. 1991.

WYNFORD-THOMAS, D. p53 in Tumor Pathology: Can we Trust in Immunohistochemistry? **J. Pathol.**, London, v.166, no.4, p.329-330, Apr. 1992.

**Endereço para correspondência:**

Universidade Federal do Rio Grande do Sul

Faculdade de Odontologia

Rua Ramiro Barcelos, 2492 sala 503.

Porto Alegre, Rio Grande do Sul, Brazil.

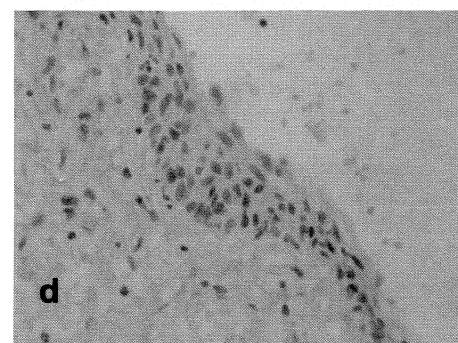
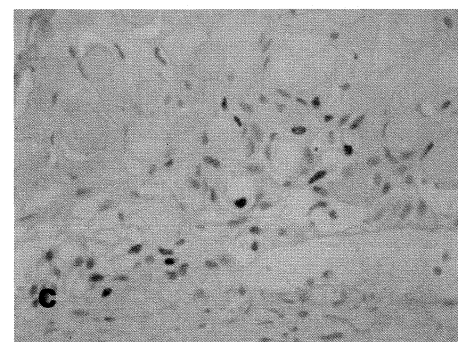
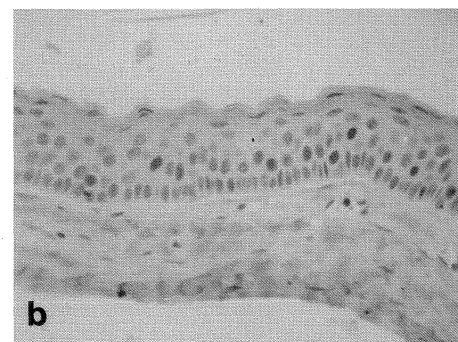
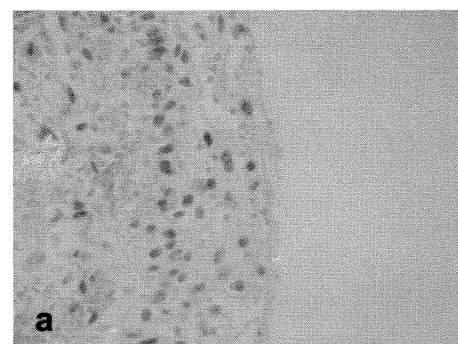
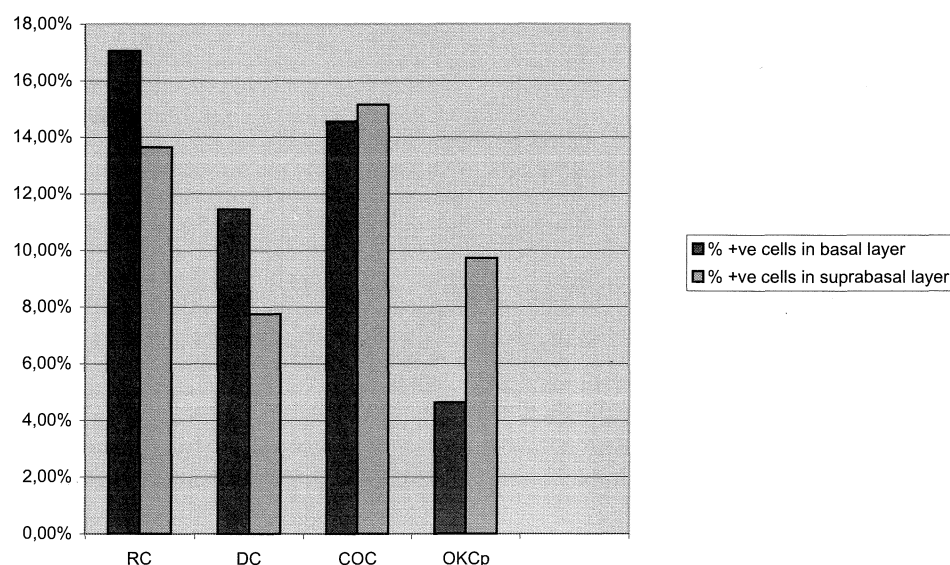
CEP 90035-003. Phone: +55 51 3316-5011. Fax: +55 51 3316-5023.

Email: manoloel@ufrgs.br

**Table 1**- Quantification of p53 immunoreactivity in odontogenic lesions.

Diagnosis	n	+ve cells in basal layer	% +ve cells in basal layer	+ve cells in suprabasal layer	% +ve cells in suprabasal layer
RC12	1023	17.05%	819	13.65%	
DC17	974	11.45%	657	7.73%	
COC	16	1166	14.57%	1213	15.16%
OKCp	12	278	4.63%	584	9.73%

**Graph 1.** Percentage of p53 positive cells in the basal and suprabasal layers of odontogenic lesions.



**FIGURE 1** - Differences in p53 (DO7, DAKO) expression in odontogenic lesions. High number of p53+ cells with weak staining in radicular cyst (a); odontogenic keratocyst showing p53+ cells with intense and defined staining mainly in suprabasal layer (b); Calcifying odontogenic cyst showing basal and suprabasal layer with intense and defined staining of p53+ cells (c) and weak staining of p53+ cells located mainly in the basal layer of dentigerous cyst (d).