

EUMYCETOMA BY *Madurella grisea*. REPORT OF THE FIRST CASE OBSERVED IN THE SOUTHERN BRAZILIAN REGION

Luiz Carlos SEVERO(1), Gerson VETORATTO(2), Flávio de
Mattos OLIVEIRA(3) & Alberto Thomaz LONDERO(4)

SUMMARY

The first case of eumycetoma by *Madurella grisea* occurred in Southern Brazilian Region is herein related. In addition, Brazilian literature on this subject was reviewed and, the geographic distribution of this eumycetoma is presented.

KEYWORDS: Eumycetoma; *Madurella grisea*; Mycetoma; Subcutaneous mycoses.

INTRODUCTION

In Brazil black grain eumycetoma have been caused by three species of fungi. They are: *Madurella grisea*, *Madurella mycetomatis*, and *Exophiala jeanselmei*, in that order of frequency. Cases of eumycetoma due to *M. grisea* have been recorded in the Brazilian States located above the Tropic of Capricorn, the majority of which in states of the Northeastern Brazilian Region^{2,3,11-13,15,24}.

The first case of eumycetoma by *M. grisea* occurred in the Southernmost state of Brazil will be herein reported. In addition comments on the geographic distribution of this type of eumycetoma and on reported Brazilian cases will be presented.

CASE REPORT

On Jan/86, a 33 year-old white man, mechanic, resident in Esteio (RS) sought for medical attention due to a tumefaction of his right foot. The patient was submitted to a biopsy and, with the diagnosis of actinomycetoma, he was treated with clotrimoxazole.

On Mar/94, the patient was admitted to our hospital complaining of the tumefaction on his right foot and pain on walking. Physical examination revealed a tumefaction (3.0 x 3.5 cm) on the plantar arch of his right foot. The skin over the lesion was slightly erythematous, but no crusts were seen neither nodules were palpated ([Fig. 1](#)).

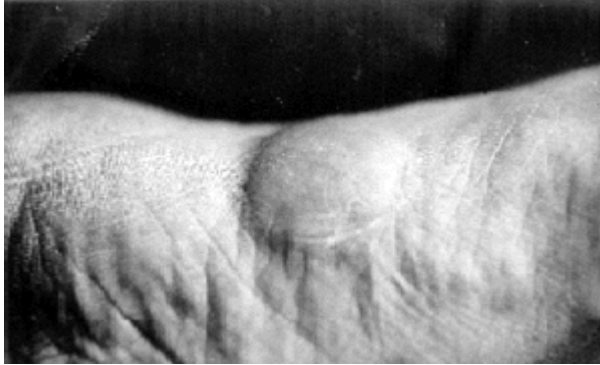

Fig. 1.- Tumefaction in the cavum of the right foot. Note the inexistence of draining sinuses.

A biopsy was then performed, part of which was preserved in formalin for hystological examination, another part was crushed and cultured.

Microbiological findings. Cut sections of biopsied tissue, stained by H&E, revealed a granulomatous lesion, productive fibrosis, and necrotic focus containing small dark brown grains. The grains, varying in size and shape, were composed of an interwoven septate hyphae (3.5 μ m). In the central portion of the grain a loose network of hyaline or slightly brown hyphae were seen. The periphery was composed of a dense network of dark brown hyphae and chlamydoconidia ([Fig. 2](#)).

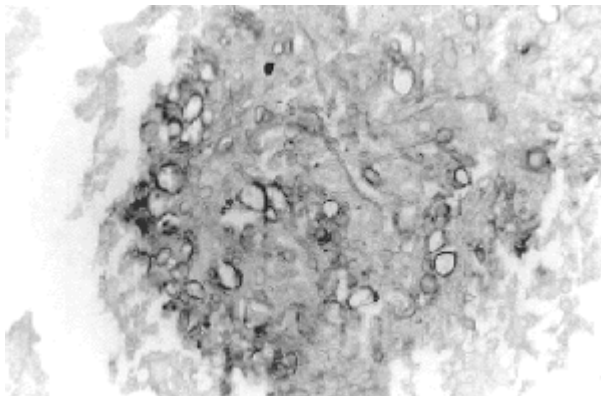


Fig. 2. - Histological section of the grain, (H&E, x 40).

Slow growing colonies were obtained on Sabouraud dextrose agar, incubated at 25°C. The colonies were grayish, leathery folded and, later on, covered by a short gray aerial mycelium. Microscopic examination revealed only dematiaceous septate hyphae. Based on these findings *M. grisea* was identified.

Treatment and evolution. The patient was treated with itraconazole (200 mg twice a day). With the improvement of the lesion the doses was reduced to 200 mg/day.

On Oct/95 the patient returned for consultation. He had discontinued the treatment and his lesions had increased in size. Examination revealed a 3.0 x 4.0 cm tumefaction, draining a whitish secretion from the scar of the biopsy. No grains were obtained. Itraconazole was reintroduced (400 mg/day), and, on Feb/97 reduced to 200 mg/day.

After one year and five months of treatment a superficial tumefaction (3.5 cm in diameter) was still present. The tumefaction was well delimited and covered by a slightly erythematous skin. On account of the poor response to antifungal drug the patient was submitted to surgery (Jun 98).

The excised tumor measured 4.0 x 3.5 x 1.5 cm, and was composed of derma and hypoderma. Four coalescent hypodermal nodules were observed in cut section of the mass. The nodules were dun-colored, had a suppurative or purulent center containing small black grains ([Fig. 3](#)). Histologic sections of the nodules, stained by H&E, revealed that they were surrounded by a thick fibrous capsule. Inside the capsule, a granulomatous tissue, infiltrate by lymphocytes and plasma cell, in the midst of which coalescent cavities were observed. These cavities contained a neutrophilic infiltrate and black grains. Some grains were surrounded by foreign body giant cells.

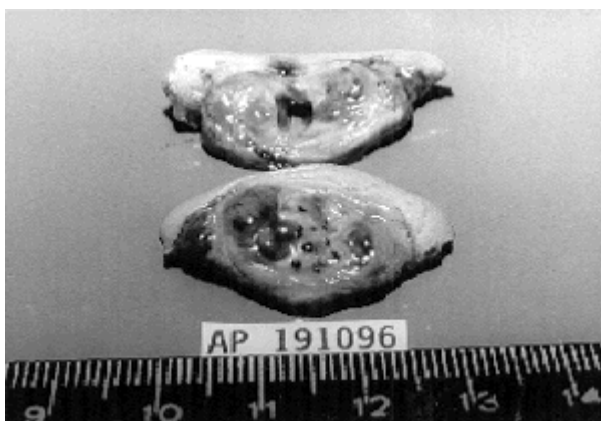

Fig. 3. - Cut sections of the excised tumor: note the small black grains.

About 4 months (Oct 98) after the surgery, the patient was free of pain on walking. Physical examination showed only the surgical scar in his right foot.

COMMENTARIES

Mackinnon et al¹⁶, in 1949, described *M. grisea* as new species based on cultures obtained from black grain eumycetoma occurred in Argentina, Chile, Paraguay, and Venezuela. Since then eumycetoma by *M. grisea* have been reported or recorded in the following countries of the Americas: Argentina²¹, Brazil¹³, Chile¹⁶, El Salvador¹⁴, Guatemala²⁰, Mexico⁶, Paraguay²¹, United States⁶, and Venezuela²². Cases occurred also in Caribbean Islands: Curaçao⁴, Grenade⁸, and St. Christopher¹. In Asia cases seems to be limited to India¹⁰, Malay¹⁹ and Philippines²³. In Africa they occurred sporadically in Chad⁹, Madagascar¹⁸, Sudan¹⁷, and Zaire²⁵.

Nine cases of eumycetoma by *M. grisea* have been related in Brazil. Patient's data, duration and localization of the lesion as well as treatment are shown in [Table 1](#).

TABLE 1
Clinical features of nine Brazilian cases of eumycetoma due to *Madurella grisea*

Case # (Ref.)	Patient's data		Lesion Duration/Localization/X-ray result	Treatment/Outcome
	Age/Sex/Occupation			
1 (12)	66/M/Field laborer		10 years/Left foot and left ankle/ Bone involvement	Amputation
2 (13)	35/M/Field laborer		7 years/Left foot/Bone involvement	Not related
3 (11)	38/M/Barber		22 years/Left foot and left ankle/ Bone involvement	KET 400 mg/day, 2 months/ Not improved. Amputation
4 (3) Relapse.	47/?/Field laborer		11 years/Right foot/Osseous involvement	SMT 1600 mg/day, 1 year/ ITRA 200 mg/day/No follow-up
5 (2) day/	3/M/Field laborer		3 years/Ankle and dorsum of left foot/Bone involvement	AmpB 2 g and DDS 100 mg/ Not improved
6 (24)	9/F/House-keeping		9 years/Left foot/Not done	DDS 100 mg/day 3 months/ Improved. Relapse
7 (15)	30/M/Field laborer		6 years/Left foot/Without bone involvement	ITRA 200 mg/day, 3 months/ Improved. No follow-up
8 (15)	53/M/Field laborer		2 years/Left foot/Bone involvement	ITRA 200 mg/day 4 months/ Improved. No follow-up
9 (Present case)	33/M/Mechanic		8 years/Right foot/Not done	ITRA 200 mg/day, 1 year/ Improved, then surgery

KET: Ketoconazole; SMT: Cotrimoxazole; AmpB: Amphotericin B; DDS: Diaminodiphenylsulfone; ITRA: Itraconazole

Five of the Brazilian cases occurred in individual⁵ coming from the Northeastern Region (cases 1, 2, 5, 7, and 8), a recognized endemic area of eumycetoma⁷. In the Centralwestern, eastern, and southern regions occurred one case each. All patients presented pedal lesions. Osseous involvement were observed in 6 of the 7 patients submitted to x-ray examination. Draining sinuses were not seen in two patients (case 5 and the present one). Both patients

were submitted to two biopsies. The grain was not identified in the first biopsied tissue from patient case 5, and, in our patient it was misdiagnosed as an actinomycotic granule.

It may be presumed that eumycetoma caused by *M. grisea* must be more frequent in Brazil, because, at least, one case was not reported and many black grains eumycetomata have been recognized only histopathologically⁷.

Mycetoma by *M. grisea* seems to be refractory to treatment. However, proper management with antifungal drug, improving and delimiting the size of the lesion, allows to its surgical excision.

Finally, the world distribution of eumycetoma due to *M. grisea* resembles that of *Exophiala jeanselmei*. Both these diseases have been prevalent in countries of the Americas.

RESUMO

Eumicetoma por *Madurella grisea*. Relato do primeiro caso observado na Região Sul do Brasil

É relatado o primeiro caso de eumicetoma por *Madurella grisea* ocorrido na Região Sul (Brasil). Além disso, a literatura brasileira correspondente foi revisada e a distribuição geográfica deste tipo de eumicetoma é apresentada.

REFERENCES

1. ANNING, S.T.; La TOUCHE, C.J. & HUNTER, G. - Madura foot (Mycetoma). **Brit. J. Derm.**, **70**: 301, 1958. [[Links](#)]
2. ARRUDA NETO, E.; PIGNATARI, A.C.C.; CASTELO FILHO, A.; COLOMBO, A.L. & LONGO, J.C. - Micetoma eumicótico. Relato de um caso por *Madurella grisea*. **Rev. Microbiol. (S. Paulo)**, **20**: 495-500, 1989. [[Links](#)]
3. BELDA Jr., W.; CUCÉ, L.C.; DIAS, M.C. & LACAZ, C.S. - Eumicetoma de grãos pretos por *Madurella grisea*. **Rev. Inst. Med. trop. S. Paulo**, **31**: 195-199, 1989. [[Links](#)]
4. BORELLI, D. - Ceni di micopathologia venezuelana. **G. ital. Derm. Sif.**, **5**: 507-526, 1956. [[Links](#)]
5. BUOT, G.; LAVALLE, P.; MARIAT, F. & SUGUIL, P. - Étude épidémiologique des mycetomas au Mexique. **Bull. Soc. Path. exot.**, **80**: 329-339, 1987. [[Links](#)]

6. BUTZ, W.C. & AJELLO, L. - Black grain mycetoma. A case due to *Madurella grisea*. **Arch. Derm.**, **104**: 197-201, 1971.
[[Links](#)]
7. CASTRO, L.G.M.; BELDA Jr., W.; SALEBIAN, A. & CUCÉ, L.C. - Mycetoma: a retrospective study of 41 cases seen in São Paulo, Brazil, from 1978 to 1989. **Mycoses**, **36**: 89-95, 1993.
[[Links](#)]
8. CHADFIELD, J.W. - Mycetoma of the foot. **Mycopathologia (Den Haag)**, **24**: 130-136, 1964. [[Links](#)]
9. DESTOMBES, P.; RAVISSE, P. & NAZZIMOFF, O. - Bilan des mycoses profondes établi en vingt années d'histopathologie a l'Institut Pasteur de Brazzaville. **Bull. Soc. Path. exot.**, **63**: 315-324, 1970. [[Links](#)]
10. GOKHALAY, B.B.; PADHYE, A.A. & THIRUMALACHAR, M.J. - Madura foot in India caused by *Madurella grisea*. **Sabouraudia**, **6**: 305-306, 1968. [[Links](#)]
11. HEINS-VACCARI, E.M.; TAKAHASHI, N.; OLIVEIRA, N.R.B.; LACAZ, C.S. & PORTO, E. - Eumicetoma de grãos pretos por *Madurella grisea*. Registro de um caso. **Rev. Inst. Med. trop. S. Paulo**, **24**: 116-123, 1982. [[Links](#)]
12. LACAZ, C.S. & BELFORT, A.E. - Maduromicose podal de grãos pretos, por *Madurella grisea*. **Hospital (Rio de J.)**, **60**: 367-374, 1961. [[Links](#)]
13. LACAZ, C.S. & FAVA NETTO, C. - Contribuição para o estudo dos agentes etiológicos de maduromicose. **Folia. clin. biol. (S. Paulo)**, **22**: 303-337, 1954. [[Links](#)]
14. LLERENA, J. - Micosis subcutaneas en el Salvador. Esporotricosis, cromoblastomicosis, micetomas. **Rev. Inst. Invest. med.**, **4**: 83-97, 1975. [[Links](#)]
15. MACHADO, L.A.P.; RIVITTI, M.C.M.; CUCE, L.C. et al. - Eumicetoma de grãos pretos por *Madurella grisea*. Registro de dois casos. **Rev. Inst. Med. trop. S. Paulo**, **34**: 569-580, 1992.
[[Links](#)]
16. MACKINNON, J.E.; FERRADA-URZUA, L.V & MONTEMAYOR, L. - *Madurella grisea* n. sp. A new species of fungus producing black variety of maduromycosis in South America. **Mycopathologia (Den Haag)**, **4**: 384-392, 1949. [[Links](#)]
17. MAHGOUB, E.I.S. - Mycetomas caused by *Curvalaria lunata*, *Madurella grisea*, *Aspergillus nidulans* and *Nocardia brasiliensis* in Sudan. **Saboraudia**, **11**: 179-182, 1973. [[Links](#)]
18. MARIAT, F. - Sur la distribution geographic et la répartition des agents de mycetomes. **Bull. Soc. Path. exot.**, **56**: 35-45, 1963.
[[Links](#)]

19. MARIAT, F. - Notes epidemiologiques a propos de mycetomes. **Recent Progr. Microbiol.**, **8**: 668-684, 1963. [[Links](#)]
20. MAYORGA, R.P. & CLOSE de LEON, J.E. - Sur une souche de *Madurella grisea* sporifera isolée d'un mycetome guatemalteque a grains boire. **Sabouraudia**, **4**: 210-214, 1966. [[Links](#)]
21. NEGRONI, R. - Contribución al estudio de los micetomas en la Republica Argentina. **Med cut. ibero lat. amer.**, **5**: 353-363, 1974. [[Links](#)]
22. REYES, C. & BORELLI, D. - Un caso de micetoma podal por *Madurella grisea*. **Rev. Sanid. Asist. soc.**, **22**: 445, 1957. [[Links](#)]
23. REYES, A.C.; TANGCO, F. & PUNSALANG Jr., A.P. - Maduromycosis. (maduromycotic mycetoma) in the Philippines caused by *Madurella grisea*. **Southeast Asian. J. trop. Med. publ. Hlth.**, **2**: 17-21, 1971. [[Links](#)]
24. SILVA, M.R.R.; FERNANDES, O.F.L.; OLIVEIRA, L.M.; COSTA, M.B. & CASTRO, L.C. - Eumycetoma por *Madurella grisea*. Relato de caso. **Rev. Soc. bras. Med. trop.**, **24**: 51-54, 1991. [[Links](#)]
25. VANDERPITTE, J.; BECKMAN, G. & NINANE, J. - Premier cas de pied de Madura par *Madurella grisea* au Congo Belge. **Ann. Soc. belge. Méd. trop.**, **36**: 493-497, 1956. [[Links](#)]

- (1) Pesquisador do CNPq; Faculdade de Medicina, Universidade Federal do Rio Grande do Sul (UFRGS), Brasil.
- (2) Serviço de Dermatologia, UFRGS, Santa Casa, Porto Alegre, RS, Brasil.
- (3) Laboratório de Microbiologia Clínica, Instituto Especializado em Pesquisa e Diagnóstico (IPD), Santa Casa, Porto Alegre, RS, Brasil.
- (4) Universidade Federal de Santa Maria, Santa Maria, RS, Brasil.

Correspondence to: Dr. L. C. Severo, Laboratório de Microbiologia Clínica, IPD - Santa Casa, Annes Dias 285, 90020-090 Porto Alegre, RS, Brazil. Fax (55 51) 214 8435. E-mail: severo@santacasa.tche.br

Received: 10 November 1998.
Accepted: 12 December 1998.