

**CUIDADOS DE ENFERMAGEM NA REDUÇÃO MANUAL DE PROLAPSO DE ESTOMIA  
NURSING CARE IN MANUAL REDUCTION OF STOMA PROLAPSE  
ATENCIÓN DE ENFERMERÍA EN LA REDUCCIÓN MANUAL DEL PROLAPSO DE OSTOMÍA**  
*Rosaura Soares Paczek<sup>1</sup>, Bruna Noschang de Brum<sup>2</sup>, Daniela Trintinaia Brito<sup>3</sup>, Ana Karina Silva da Rocha Tanaka<sup>4</sup>*

---

**RESUMO**

**Objetivo:** relatar um caso sobre a redução manual do prolapso em um estoma intestinal. **Método:** trata-se de um estudo, descritivo, tipo relato de caso clínico, sobre a redução manual do prolapso em um estoma intestinal de um paciente. Relata-se que o cenário foi um centro de referência no atendimento ao estomizado. Avaliaram a efetividade das intervenções de Enfermagem com base na comparação dos resultados iniciais e finais do procedimento. **Resultados:** nota-se a presença de lesões e permeabilidade na presença de prolapso, realizando a manobra de redução digital, até a sua total regressão, facilitando a limpeza da pele e a colocação do equipamento coletor, observando as possíveis lesões periestomais e na mucosa. **Conclusão:** informa-se que os pacientes com prolapso em estoma intestinal têm um desconforto devido ao volume dentro do equipamento coletor e ao pouco espaço para conter as suas eliminações. Utiliza-se a técnica de redução manual para facilitar a troca do equipamento coletor, esta deverá ser realizada por enfermeiro estomaterapeuta ou capacitado. Salienta-se que os casos em que se afeta o desenvolvimento de atividades cotidianas merecem uma avaliação da equipe cirúrgica.

**Descritores:** Estomaterapia; Prolapso; Cuidados de Enfermagem; Estomia; Relatos de Caso; Avaliação em Enfermagem.

---

**ABSTRACT**

**Objective:** to report a case about manual reduction of prolapse in an intestinal stoma. **Method:** it is a descriptive, case report type study on the manual reduction of prolapse in a patient's intestinal stoma. It is reported that the scenario was a reference center in the care of the stoma. They evaluated the effectiveness of nursing interventions based on the comparison of the initial and final results of the procedure. **Results:** the presence of injuries and permeability in the presence of prolapse is noted, performing the digital reduction maneuver, until its total regression, facilitating the cleaning of the skin and the placement of the collector equipment, observing the possible periestomal and mucosal lesions. **Conclusion:** it is reported that patients with prolapse in the intestinal stoma have a discomfort due to the volume inside the collector equipment and the

little space to contain their eliminations. The manual reduction technique is used to facilitate the exchange of the collector equipment, this should be performed by a stoma therapist or trained nurse. It is emphasized that the cases in which the development of daily activities is affected deserve an evaluation of the surgical team.

**Descriptors:** Stomatherapy; Prolapse; Nursing Care; Stomatology; Case Reports; Nursing Assessment.

---

## RESUMEN

**Objetivo:** reportar un caso de reducción manual del prolapso en un estoma intestinal. **Método:** se trata de un estudio, descriptivo, a modo de reporte de caso clínico, sobre la reducción manual del prolapso en el estoma intestinal de un paciente. Se informa que el escenario fue un centro de referencia en la atención de pacientes ostomizados. Evaluaron la efectividad de las intervenciones de Enfermería a partir de una comparación de los resultados iniciales y finales del procedimiento.

**Resultados:** se observa la presencia de lesiones y permeabilidad en presencia de prolapso, realizando la maniobra de reducción digital, hasta su total regresión, facilitando la limpieza de la piel y la colocación del equipo colector, observando las posibles lesiones periestomales y mucosas.

**Conclusión:** se informa que los pacientes con prolapso en estoma intestinal presentan molestias por el volumen dentro del equipo de recolección y el poco espacio para contener sus eliminaciones. La técnica de reducción manual se utiliza para facilitar el intercambio del equipo colector, esto debe ser realizado por un estomaterapeuta o enfermero capacitado. Cabe destacar que los casos en los que se ve afectado el desarrollo de las actividades diarias merecen una valoración por parte del equipo quirúrgico.

**Descriptores:** Estomaterapia; Prolapso; Cuidado de Enfermera; Estoma; Informes de Casos; Evaluación en Enfermería.

---

<sup>1</sup> Porto Alegre City Hall/PMPA. Porto Alegre (RS), Brazil. <sup>1</sup><https://orcid.org/0000-0002-4397-1814>

<sup>2,3,4</sup>Federal University of Rio Grande do Sul/UFRGS. Porto Alegre (RS), Brazil.

<sup>2</sup><https://orcid.org/0000-0003-0902-0449> <sup>3</sup><https://orcid.org/0000-0003-3666-360X>

<sup>4</sup><https://orcid.org/0000-0003-2488-3656>

### How to cite this article

Paczek RS, Brum BN, Brito DT, Tanaka AKSR. Manual reduction of stoma prolapse - case report. J Nurs UFPE on line. 2021;15:e247404 DOI: <https://doi.org/10.5205/1981-8963.2021.247404>

## INTRODUCTION

---

The intestinal stoma is defined as an orifice surgically constructed to allow the viscera to communicate with the external environment in order to divert the intestinal content.<sup>1-2</sup> It is known that the stomas can be permanent or temporary, depending on the cause and purpose for which they are constructed.<sup>1</sup> The stoma is named from the intestinal segment in which it is found, being ileostomy, when it is found in the small intestine, and colostomy, in the large intestine.<sup>1</sup> Temporary stomas are created for the prevention and protection of intestinal transit, avoiding complications such as dehiscence and infection in the anastomosis areas, allowing the reconstructed intestinal transit to heal.<sup>3</sup> Permanent stomas are used when total resection of the colon, rectum or anus is necessary, making reconstruction of intestinal transit impossible.<sup>3</sup> It is noteworthy that this situation often occurs with patients diagnosed with colon and rectal cancer, this being the second most common type of cancer in Brazil.<sup>4</sup>

It should be noted that the creation of a stoma is not a risk-free procedure, because its success is linked to factors such as preoperative evaluation, the demarcation of the stoma site in the abdomen, the surgical technique used and proper handling of equipment and special materials.<sup>5</sup> It is stressed that inadequate care can cause several complications in the stoma, which can be immediate, occurring in the first 24 hours, such as necrosis, ischemia, edema, bleeding and bleeding. It is emphasized that early complications occur between the first and seventh day and may occur through fistula and peri-estomal abscess, stoma retraction and cutaneomucous separation. Late complications are listed: prolapse of the intestinal loop; stenosis or retraction of the stoma and parastomal or paracolostomy hernia. It is added that another common complication in people with elimination stomas is periestomal dermatitis.<sup>1,6</sup> It is understood that prolapse is a complication in the stoma, usually associated with the presence of paracolostomal hernia, and occurs when a segment of the intestinal loop externalizes through the stoma.<sup>7-8</sup> It is most frequently seen in stomas made of loops, which may arise due to increased intra-abdominal pressure, increased body weight, poor suture of the intestinal loop in the abdominal wall or when the opening of the abdominal wall is too wide during the surgical procedure for making the stoma.<sup>3</sup> Among the risk factors are: advanced age; the presence of hernia and the manufacture of the stoma outside the rectus abdominus muscle.

It is noted that prolapse can bring problems in the daily life of the person with stoma, causing pain, intestinal obstruction, difficulty in adapting the collector equipment, psychological suffering and social isolation. In response, the manual and postural reduction of prolapse is performed with the use of lubricants or products that reduce edema.<sup>9</sup> When the patient has great difficulty in

keeping the collector equipment attached, affecting his daily life, it should be pointed out that the surgery indication for the correction should be evaluated by the surgical team.<sup>5</sup>

It is pointed out that the occurrence of complications generates negative impacts on the life of patients with stoma, mainly in terms of self-care and well-being. It is verified, regarding the measures of prevention of complications, that the demarcation, performed by the professional nurse in the preoperative, for the manufacture of the stoma must be within the limits of the rectus abdominus muscle, away from surgical wounds or body irregularities and the procedure should be performed with the appropriate surgical technique.<sup>6</sup>

The role of the nurse is to care for and follow up the patient with stoma, promoting and teaching self-care and helping in the social insertion of this person, based on orientations directed both to the patient and his family. In this way, the Nursing professional helps the patient to adapt, besides improving his/her quality of life, for a better acceptance of the estomy.<sup>10</sup> Health professionals should help these patients with measures that stimulate the quality of life, aiming that they live in harmony with their new life condition.<sup>11</sup>

The aim is to help people with stomachs in relation to the nursing care with the stomach, with the peristomal skin, how to use the collecting equipment and the adjuvants, in order to help in the care regarding the new condition, with the obtainment of an improvement in the quality of life, because the patients often go through a process of non-acceptance of the alteration of the body image, having difficulty with the use of the bag, bringing insecurity, fear of the noise of the gases, which it releases from the body.<sup>12</sup>

The importance of reporting the case of a manual reduction of the prolapse of an intestinal stoma is established in view of the need to instrumentalize health professionals to perform the care and guidance of people with stomas, helping to choose the best equipment to adapt to your stoma, teaching how to perform the reduction maneuver, guiding the need to frequently examine the appearance of your stoma.

This study is justified due to the difficulties encountered by patients when presenting with stoma prolapse, as well as to guide health professionals in the care of these patients.

The conducts taken were based on international taxonomies: Classification of Nursing Diagnosis (NANDA); Classification of Nursing Interventions (NIC) and Classification of Nursing Results (NOC). It is also considered necessary to conduct more studies on prolapse in intestinal stomas, since the number of articles in this area is scarce.

Thus, this study aims to report a case of manual reduction of prolapse of an intestinal stoma, emphasizing the need to instrumentalize health professionals to perform the care and guidance of people with stomas.

It is a descriptive, clinical case report type study on a single case related to the manual reduction of prolapse in an intestinal stoma, whose scenario was a reference center in the care of the stoma, in the southern region of Brazil. The study was carried out from November 2019 to May 2020, and the patient authorized the use of the image through the Term of Authorization and Assignment of the Right to Image Use. According to the ethical precepts, the commitment to maintain the patient's privacy was firm, with the guarantee of the preservation of the patient's identification, without bringing losses, risk or damages to the patient.

It can be seen that the experience report was based on the care provided at the reference center for people with stoma, and this specific case was chosen because it was under care during the period studied.

### RESULTS

It is pointed out that the NANDA, NIC and NOC taxonomies aim to standardize the classification of diagnoses, interventions and expected results, respectively, being used to list the diagnoses presented by the patient in this study, define the interventions to be taken and evaluate the result of these interventions.

#### **Presentation of clinical case**

He is a man, 71 years old, with complete superior level, who works as a driver, previously healthy, active smoker, using half a cigarette license per day, living in a city in the South of Brazil. There were changes in the frequency of fecal eliminations, with the patient evacuating approximately ten times a day, in addition to weight loss, which reached almost ten kg. A colonoscopy was performed that confirmed the diagnosis of malignant rectal neoplasia (C20). An abdominal rectosigmoidectomy was performed, with stapled anastomosis, protective transversostomy and stoma on the right flank on September 26, 2019. It was noticed that the patient evolved in clinical improvement, with vital signs and hemodynamically stable, until the hospital discharge.

In the first consultation at the Stomatherapy Service on November 29, 2019, the stoma with prolapse, which was reduced spontaneously when lying down, and the allergic dermatitis on the upper edge were identified. It was observed that the patient emptied and cleaned the bag, but could not perform the changes of the collecting equipment. In another consultation, the increase of prolapse and the difficulty of spontaneous reduction were registered, leading to the resolution of the allergic lesion and the application of chemotherapy. It is pointed out that the patient returned every one or two weeks to perform the bag change, with the prolapse being manually reduced. The patient was very uncomfortable with the use of the bag and with the prolapse, because he stopped

working and the volume of the prolapse caused him discomfort. In two consultations, the edema in the prolapsed mucosa was presented, making reduction difficult. In subsequent consultations, the persistence of the prolapse, which was still reduced manually, was detected. On one occasion, episodes of diarrhea were reported, causing irritative dermatitis in the peri-estomal skin and parastomal hernia. It was noticed that the patient was disgusted with his situation, saying he was upset because he couldn't work and that the prolapse bothered him a lot. The patient was instructed to contact the surgical team in a scheduled appointment in the service where he was doing the follow-up.

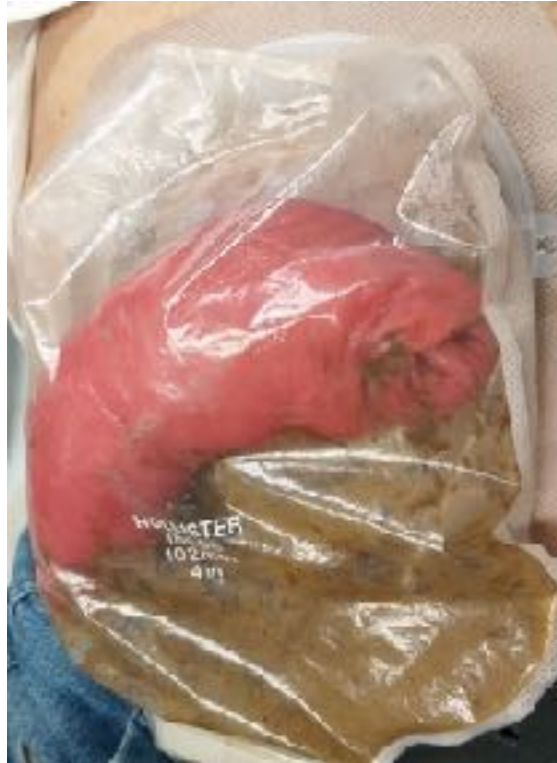

Figure 1. Stoma with prolapse. Porto Alegre (RS), Brazil, 2020. Source: Authors' collection (2020).

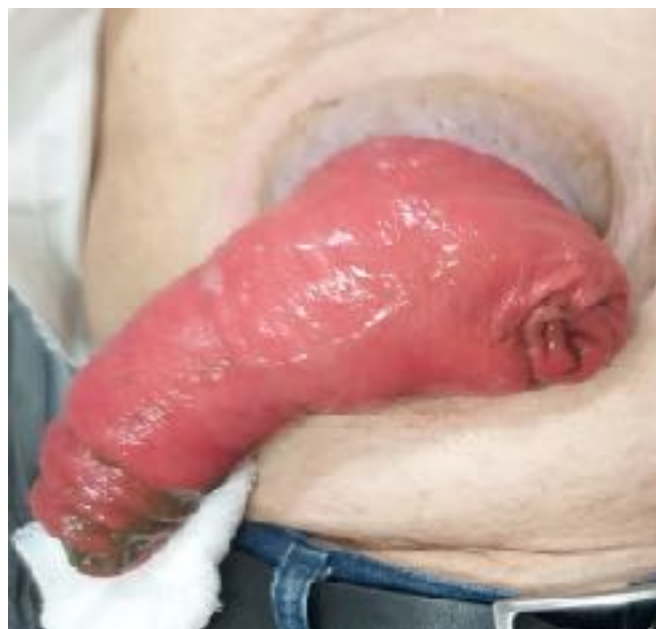

Figure 2: Stoma with prolapse. Porto Alegre (RS), Brazil, 2020. Source: Authors' collection (2020).

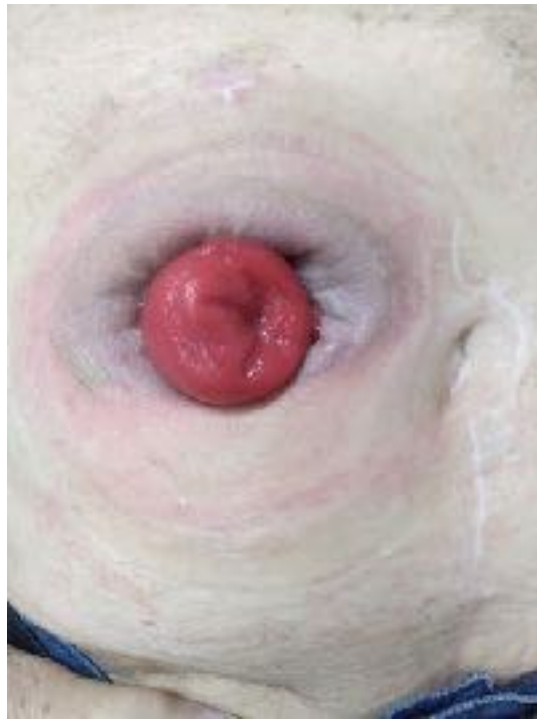

Figure 3. Stoma after manual  
2020. Source: Authors' collection

reduction. Porto Alegre (RS), Brazil,  
(2020).

It is noted that the nurse should evaluate the conditions of the stoma as to its coloration, presence of lesions and permeability. In the case of prolapse, it is recommended that a digital reduction maneuver be performed, using gauze soaked in water at room temperature, massaging the prolapsed segment with gentle and delicate movements until its total regression. This facilitates the cleaning of the skin and the placement of the collector equipment, allowing the observation of possible peristomal and mucosal lesions. For the procedure, it is requested that the patient be relaxed, with the upper limbs extended along the body. Visual inspection is performed to verify the presence of lesions on the mucosa and skin. After cleaning the peri-estomal skin, the skin protector powder is applied and, in case there is any lesion on the peri-estomal skin, the skin protector in spray form and the barrier paste.

It is important to guide the patient not to wear tight clothes or clothes that can rub on the stoma to avoid injury to the intestinal mucosa. It is observed, when the patient gets up, coughs or makes some effort, that the prolapse will return. It is suggested, for patients with prolapse, that the collecting equipment should be cut in size larger than the stoma, to prevent the prolapsed stoma from swelling, which would make it difficult to reduce spontaneously, leading to the suffering of the mucosa.

In case of the presence of edema on the prolapsed handle, soft movements with a cold compress are required, in order to try to reduce the edema and place the collecting equipment. If the edema does not regress, the prolapsed area must not be forced. In this case, the collector equipment must be placed and the patient must be guided about the elimination exit. It is observed, in case of abdominal pain, malaise or vomiting, accompanied by the non drainage of feces, that the patient should seek the emergency hospital service.

Selected Nursing Diagnostics (NANDA)<sup>13</sup> are linked to patient needs. The NIC,<sup>14</sup> includes activities that support nursing care, selecting them according to the teaching needs of the user and



the family. In the last stage, specific indicators were used according to the NOC,<sup>15</sup> which evaluated the effectiveness of nursing interventions based on the comparison of initial and final results.

NANDA Nursing Diagnosis	NIC Interventions
<p><b>Low situational self-esteem</b> (Domain 6: Self-perception) Characterized by the underestimation of the capacity to deal with the situation related to the alteration of the body image and the social role.</p>	<p><u>Decision Making Support (code 5250)</u></p> <ul style="list-style-type: none"> <li>• Provide the information requested by the patient;</li> <li>• Referral to support groups, as appropriate;</li> <li>• Informing the patient about points of view or alternative solutions in a clear and sympathetic manner.</li> </ul> <p><u>Humor Control (code 5330)</u></p> <ul style="list-style-type: none"> <li>• Monitor self-care capacity (e.g. cleanliness, hygiene, food/liquid intake and disposal);</li> <li>• Assist with self-care, as needed;</li> <li>• Monitor the patient's physical state (e.g., body weight and hydration).</li> </ul>
<p><b>Damaged tissue integrity</b> (Domain 11: Security/Protection) Characterized by tissue damage related to the invasive procedure.</p>	<p><u>Ostomy Care (code 0480)</u></p> <ul style="list-style-type: none"> <li>• Assist the patient in obtaining the necessary equipment;</li> <li>• Properly apply the adjustment of the ostomy device, as necessary;</li> <li>• Monitor the incision/healing of the stoma;</li> <li>• Monitor postoperative complications such as intestinal obstruction, paralytic ileum, fistula or mucocutaneous separation, as appropriate;</li> <li>• Monitor stoma healing tissue and adaptation to ostomy equipment;</li> <li>• Changing/deleting the ostomy bag, as appropriate;</li> <li>• Assisting the patient in providing self-care.</li> </ul>

Figure 1. Diagnostics and Nursing Interventions. Source: Adapted.<sup>10-1</sup>

SELFESTEEM (1205)	INITIAL NOC	EXPECTED NOC	FINAL NOC
Self-acceptance verbalization (120501)	2	4	3
Acceptance of own limitations (120502)	1	4	2
Description of oneself (120505)	2	4	2
Maintenance of storage/hygiene (120509)	1	5	4
Level of trust (120511)	1	5	3
Description of pride in oneself (120518)	1	4	2

Figure 2: Initial, expected and final results. Source: Adapted.<sup>10-1</sup>

**Key:**

Never positive: 1; Seldom positive: 2; Sometimes positive: 3; Often positive: 4; Consistently positive: 5.

**DISCUSSION**

It is known that inadequate stoma and skin care can lead to various complications. It is emphasized that prolapse is one of these complications, characterized by an intussusception of the intestinal stoma.<sup>1,9</sup> The stoma is related to the non-conformity of several factors, one of them being the demarcation of the stoma site, which can facilitate or hinder the self-care and rehabilitation process. The lack of adequate guidance and the care from a qualified professional during the treatment are also highlighted. In addition, gender, age and schooling also influence this aspect.<sup>1</sup>



The nurse is responsible for the evaluation of the stoma and peri-estomal skin regarding the alterations and lesions in this region. Manual reduction of the prolapse is performed to facilitate skin hygiene and to assist in the placement of the collector equipment.<sup>7</sup>

It is important that the nurse addresses topics of the patient's daily life that may be being hampered by lack of orientation, such as the sex life of the ostomized and their coexistence in society. The professional should also pay attention to the feelings of his patient and how he is dealing with his current condition. In addition, the nurse has the role of providing guidance for self-care, which should address fundamental issues such as proper use of the collection bag, hygiene of the peri-estomal region, where to acquire the necessary materials, in addition to guidance with food and prevention of complications<sup>16</sup>.

One of the limiting factors of this study is that it is a single case. In addition, there is a scarcity of references in the literature on the performance of manual prolapse reduction, revealing the need for further studies in the area.

## CONCLUSION

---

It is noted that patients who present prolapse in the intestinal stoma report discomfort due to the volume that the exteriorized portion of the intestine occupies inside the collector equipment, causing a decrease in the space for storage of the eliminations. The technique of manual reduction of the prolapse is used to facilitate the replacement of the collector equipment and to assist in the cleaning of the peri-estomal skin. It is warned that this technique should only be used by a nurse stoma therapist or trained. In cases where the prolapse affects the performance of daily activities, it is necessary to evaluate the surgical team in order to discuss the most appropriate conduct to be followed.

It is evaluated that the adequate orientation offered by a trained professional promotes the patient's rehabilitation, minimizing their suffering and encouraging self-care.

## CONTRIBUTIONS

It is informed that all authors contributed equally in the conception of the research project, collection, analysis and discussion of the data, as well as in the writing and critical review of the content with intellectual contribution and in the approval of the final version of the study.

## CONFLICT OF INTERESTS

Nothing to declare.

## REFERENCES

---

1. Salomé GM, Carvalho MRF, Massahud Junior MR, Mendes B. Profile of ostomy patients residing in Pouso Alegre city. *J Coloproctol* 2015 Apr/June; 35(2):106-12. DOI: [10.1016/j.jcol.2015.02.002](https://doi.org/10.1016/j.jcol.2015.02.002).
2. García-Pardo ARH, Maldonado YR, Savoini EN, Antônio RG, Miguel GA, Alonso FJG, González JBS. Prospective study of digestive stomas complications. *Rev Gastroenterol Peru* [Internet]. 2019 July/Sept [cited 2020 May 29]; 39(3):215-21. Available from: [http://www.scielo.org.pe/scielo.php?pid=S1022-51292019000300003&script=sci\\_abstract](http://www.scielo.org.pe/scielo.php?pid=S1022-51292019000300003&script=sci_abstract)
3. Sherman KL, Wexner SD. Considerations in Stoma Reversal. *Clin Colon Rectal Surg*. 2017 July; 30(3):172-7. DOI: 10.1055/s-0037-1598157
4. Ministério da Saúde (BR), Instituto Nacional de Câncer José Alencar Gomes da Silva. Vigilância Estimativa 2020: Estatísticas de câncer [Internet]. Rio de Janeiro: INCA; 2020 [cited 2020 May 29]. Available from: <https://www.inca.gov.br/numeros-de-cancer>
5. Costa JM, Ramos RS, Santos MM, Silva DF, Gomes TS, Batista RQ. Complications of intestinal stoma in post-operative patients of rectal tumor resection. *Rev Enferm Atual* [Internet]. 2017 Oct [cited 2019 Aug 10]. Available from: <https://revistaenfermagematual.com.br/index.php/revista/article/view/545>
6. Thum M, Paula MAB, Morita ABSP, Balista AL, Franck EM, Lucas PCC. Late complications in patients with intestinal ostomies who underwent a preoperative site marking. *ESTIMA, Braz J Enterostomal Ther*. 2019 Jan; 16:e4218. DOI: 10.30886/estima.v16.660\_PT
7. Costa JM, Ramos RS, Santos MM, Silva DF, Gomes TF, Batista RQ. Complications of intestinal stoma in post-operative patients of rectal tumor resectio. *Rev Enfermagem Atual In Derme*. 2017; Edição Especial: 35-42. DOI: 10.31011/reaid-2017-v.2017-n.0-art.545
8. Tsujinaka S, Tan KY, Miyakura Y, Fukato R, Oshima M, Konishi F, Rikiyama T. Current Management of Intestinal Stomas and Their Complications. *J Anus Rectum Colon*. 2020 Jan; 4(1):25-33. DOI: 10.23922/jarc.2019-032
9. Sobrado Junior CW, Guzela VR, Sobrado LF, Nahas SC, Cecconello I. Local treatment of colostomy prolapse with the MESH STRIP technique: a novel and highly efficient day hospital technique. *Clinics* [Internet]. 2019 Dec [cited 2020 June 10];75:e1353. Available from: <https://www.revistas.usp.br/clinics/article/view/167268>
10. LEITE MS, et al. Diagnósticos de enfermagem em pacientes submetidos à colostomia. *Enferm. Foco*, v.8, n.2, p: 72- 76, 2017.
11. Cirino HP, Andrade PCST, Kestenberg CCF, Caldas CP, Santos CN, Ribeiro WA. Repercussões emocionais e processos adaptativos vividos por pessoas estomizadas. *Saúde Coletiva (Barueri)* 2020; 10 (57): 3573-96. <https://doi.org/10.36489/saudecoletiva.2020v10i57p3573-3596>
12. Sena R, Nascimento E, Turato E, Torres G, Maia E. Correlação entre imagem corporal e

autoestima em pessoas com estomias intestinais. *Psic., Saúde & Doenças*. 2018 Dez; 19 (3): 578-90.

<http://dx.doi.org/10.15309/18psd1909>.


13. Herdman TH, Kamitsuru S. NANDA International. Diagnósticos de enfermagem: definições e classificação 2018-2020. 11th ed. Porto Alegre: Artmed; 2018.
14. Bulechek G, Butcher H, Dochterman J, Wagner C. Classificação das Intervenções de Enfermagem (NIC). 6th ed. Barcelona: Elsevier; 2016.
15. Moorhead S, Johnson M, Maas M, Swanson E. Classificação dos Resultados de Enfermagem (NOC): Medição dos Resultados de Saúde. 5th ed. Barcelona: Elsevier; 2016.
16. FREIRE DA, et al. Autoimagem e autocuidado na vivência de pacientes estomizados: o olhar da enfermagem. *Rev Min Enferm*

#### Correspondence

Rosaura Soares Paczek  
Email: [rspaczek@gmail.com](mailto:rspaczek@gmail.com)

Submission: 24/07/2020  
Accepted: 05/02/2021

Copyright© 2021 Journal of Nursing UFPE on line/REUOL.

 This is an open access article distributed under the CC BY 4.0 Assignment [Creative Commons Attribution-ShareAlike 4.0 International License](https://creativecommons.org/licenses/by/4.0/), which allows others to distribute, remix, adapt and create from their work, even for commercial purposes, as long as they give it due credit for the original creation. It is recommended to maximize the dissemination and use of the licensed materials.