

Reduced fronto-striatal volume in attention-deficit/hyperactivity disorder in two cohorts across the lifespan

Renata Basso Cupertino^{a,1}, Sourena Soheili-Nezhad^{b,c,1}, Eugenio Horacio Grevet^{d,e,f}, Cibele Edom Bandeira^{e,f,g}, Felipe Almeida Picon^{e,f}, Maria Eduarda de Araujo Tavares^{e,f,g}, Jilly Naaijen^{b,c}, Daan van Rooij^c, Sophie Akkermans^{b,c}, Eduardo Schneider Vitola^{e,f}, Marcel P Zwiers^c, Diego Luiz Rovaris^h, Pieter J. Hoekstraⁱ, Vitor Breda^{e,f}, Jaap Oosterlaan^{j,k}, Catharina A Hartman^{j,k}, Christian F Beckmann^{b,c}, Jan K Buitelaar^{b,l}, Barbara Franke^{m,n}, Claiton Henrique Dotto Bau^{e,f,g,2,*}, Emma Sprooten^{b,c,2,*}

^a Department of Psychiatry, University of Vermont, Burlington, VT, USA

^b Department of Cognitive Neuroscience, Donders Institute for Brain, Cognition and Behaviour, Nijmegen, Radboud University Medical Center, Nijmegen, The Netherlands

^c Centre for Cognitive Neuroimaging, Donders Institute for Brain, Cognition and Behaviour, Nijmegen, Radboud University Medical Center, Nijmegen, The Netherlands

^d Department of Psychiatry, Faculdade de Medicina, Universidade Federal do Rio Grande do Sul, Porto Alegre, Brazil

^e Adulthood ADHD Outpatient Program (ProDAH), Clinical Research Center, Hospital de Clínicas de Porto Alegre, Porto Alegre, Brazil

^f Developmental Psychiatry Program, Experimental Research Center, Hospital de Clínicas de Porto Alegre, Porto Alegre, Brazil

^g Department of Genetics, Instituto de Biociências, Universidade Federal do Rio Grande do Sul, Porto Alegre, Brazil

^h Universidade de São Paulo Instituto de Ciências Biomédicas Departamento de Fisiologia e Biofísica, São Paulo, Brazil

ⁱ University of Groningen, University Medical Center Groningen, Department of Psychiatry, Groningen, The Netherlands

^j Emma Children's Hospital, Amsterdam UMC, University of Amsterdam, Emma Neuroscience Group, Department of Pediatrics, Amsterdam Reproduction & Development, Amsterdam, The Netherlands

^k Vrije Universiteit, Clinical Neuropsychology Section, Van der Boechorststraat 7, 1081 BT Amsterdam, The Netherlands

^l Karakter Child and Adolescent Psychiatry University Centre, Nijmegen, The Netherlands

^m Department of Human Genetics, Donders Institute for Brain, Cognition and Behaviour, Radboud University Medical Center, Nijmegen, The Netherlands

ⁿ Department of Psychiatry, Donders Institute for Brain, Cognition and Behaviour, Radboud University Medical Center, Nijmegen, The Netherlands

ARTICLE INFO

Keywords:

ADHD
White matter
Fronto-striatal
Tensor-based morphometry
Independent component analysis

ABSTRACT

Attention-Deficit/Hyperactivity Disorder (ADHD) has been associated with altered brain anatomy in neuroimaging studies. However, small and heterogeneous study samples, and the use of region-of-interest and tissue-specific analyses have limited the consistency and replicability of these effects. We used a data-driven multivariate approach to investigate neuroanatomical features associated with ADHD in two independent cohorts: the Dutch NeuroIMAGE cohort (n = 890, 17.2 years) and the Brazilian IMPACT cohort (n = 180, 44.2 years). Using independent component analysis of whole-brain morphometry images, 375 neuroanatomical components were assessed for association with ADHD. In both discovery (corrected-*p* = 0.0085) and replication (*p* = 0.032) cohorts, ADHD was associated with reduced volume in frontal lobes, striatum, and their interconnecting white-matter. Current results provide further evidence for the role of the fronto-striatal circuit in ADHD in children, and for the first time show its relevance to ADHD in adults. The fact that the cohorts are from different continents and comprise different age ranges highlights the robustness of the findings.

* Corresponding authors at: Department of Genetics, Instituto de Biociências, UFRGS, Avenida Bento Gonçalves, 9500 Porto Alegre RS91501-970, Brazil (C.H.D. Bau). Department of Cognitive Neuroscience, Donders Institute for Brain, Cognition and Behaviour, Nijmegen, Radboud University Medical Center, Kapittelweg 29 – Nijmegen 6525, The Netherlands (E. Sprooten).

E-mail addresses: claiton.bau@ufrgs.br (C.H.D. Bau), e.sprooten@donders.ru.nl (E. Sprooten).

¹ Authors contributed equally to this work.

² Authors shared senior authorship.

<https://doi.org/10.1016/j.nicl.2020.102403>

Received 14 June 2020; Received in revised form 5 August 2020; Accepted 25 August 2020

Available online 28 August 2020

2213-1582/ © 2020 The Authors. Published by Elsevier Inc. This is an open access article under the CC BY-NC-ND license

(<http://creativecommons.org/licenses/by-nc-nd/4.0/>).

1. Introduction

Attention-Deficit Hyperactivity Disorder (ADHD) is one of the most common psychiatric disorders worldwide, characterized by age-inappropriate levels of inattention and/or hyperactivity/impulsivity leading to significant impairment. Its prevalence is about 5% in children and about 3% in adults (Franke et al., 2018; Vitola et al., 2017). ADHD is clinically highly heterogeneous, and around 70% of the affected individuals present with comorbid psychiatric disorders, further complicating diagnosis and treatment (Katzman et al., 2017; Sobanski et al., 2007; Torgersen et al., 2006). The clinical profile of ADHD changes throughout development: while children are more likely to present with symptoms of hyperactivity/impulsivity, adolescents and adults often experience more symptoms of inattention (Faraone et al., 2006; Franke et al., 2018). Cognitive functions such as inhibitory control and working memory (Willcutt et al., 2005), emotion regulation (Özbaran et al., 2018), and motivational processes (Luman et al., 2005) are also affected in many individuals with ADHD across the lifespan.

Although the underlying neurobiology of ADHD is only partly understood, neuroimaging studies have identified several structural and functional brain changes associated with this disorder (Albajara Sáenz et al., 2019; Castellanos and Tannock, 2002; Valera et al., 2007; van Ewijk et al., 2012). The most consistent findings in structural magnetic resonance imaging (MRI) studies on ADHD point to a reduction in total brain volume and grey matter in individuals with ADHD compared to controls (Albajara Sáenz et al., 2019; Castellanos and Tannock, 2002; Hoogman et al., 2017; Valera et al., 2007). More specifically, Albajara Sáenz et al. (2019) associated ADHD with structural alterations in the basal ganglia, prefrontal cortex, and the corpus callosum. A mega-analysis comprising over 3000 individuals found smaller volumes of five out of seven subcortical structures in ADHD, with strongest effects observed in the amygdala, nucleus accumbens, and putamen (Hoogman et al., 2017). Age-stratified analyses in that study showed that the effect of ADHD on brain structure was stronger in children, and no statistically significant effect was seen in adults above the age of 22 years (Hoogman et al., 2017). More recently, a coordinated analysis involving 36 centers showed that children with ADHD also have reduced cortical surface area, especially in frontal, cingulate, and temporal regions as well as reduced cortical thickness in fusiform gyrus and temporal pole (Hoogman et al., 2019). That study also did not find differences in surface area and cortical thickness in the adolescent and adult groups, again suggesting an age-dependent effect. Evidence from studies using diffusion-weighted imaging (DWI) implicates white-matter microstructural alterations in ADHD (Aoki et al., 2018; Chen et al., 2016; Franx et al., 2015; van Ewijk et al., 2014), possibly hampering neural communication amongst and between cortical and subcortical areas. Two meta-analyses found altered fractional anisotropy in widespread regions in patients with ADHD, with the most consistent findings in the corpus callosum, anterior corona radiata, right forceps minor, bilateral internal capsule, and left cerebellum (Chen et al., 2016; van Ewijk et al., 2012).

Previous structural MRI studies in ADHD either focused on *a priori*, automatically segmented, cortical or subcortical areas delimiting specific regions of interest (ROIs) (Hoogman et al., 2017; Valera et al., 2007), or explored changes in brain volume and cortical area and thickness using mass univariate methods at a voxel or vertex level (Bralten et al., 2016; Nakao et al., 2011; Sörös et al., 2017). While these methods are primarily sensitive to the detection of grey-matter differences, evidence from diffusion-weighted imaging shows that ADHD may also affect white matter microstructure (Franx et al., 2015; van Ewijk et al., 2014, 2012). In the present study, we used a combination of tensor-based morphometry (TBM) and independent component analysis (ICA), allowing us to optimize sensitivity to the detection of local differences in both grey- and white-matter tissue and their spatial covariation, in a whole-brain multivariate analysis.

TBM is a method for investigating brain volume differences at MRI

voxel resolution. It relies on non-linear deformation fields that warp each subject's brain anatomy to an average study template (Ashburner and Friston, 2000; Ashburner et al., 1998). By calculating the Jacobian determinant of subject-wise deformation fields, the amount of local volume contraction or expansion is calculated per voxel in every subject. These Jacobian fields are then statistically compared between groups to assess anatomical differences.

ICA is a data driven method for intuitive separation of raw data into a predefined number of linearly mixed sources (Beckmann and Smith, 2005). This is useful to discover hidden, maximally independent features, from a large amount of mutually dependent measurements. ICA has been frequently used in functional MRI studies, leading to the identification of several functional brain networks (Beckmann, 2012; Beckmann et al., 2005). More recently, ICA has also been successfully applied to whole-brain diffusion imaging data (O'Muircheartaigh and Jbabdi, 2018; Wu et al., 2015), and to structural grey-matter images (Gupta et al., 2015; Sprooten et al., 2015; Xu et al., 2009). The specific combination of ICA with TBM was recently shown to be robust and sensitive to describe to individual variation in brain structure (Llera et al., 2019). In relation to ADHD, multi-modal linked ICA has been used for data fusion across different MRI modalities (cortical thickness and area, voxel-based morphometry, and diffusion tensor imaging), showing association of ADHD symptom severity with several spatial modes of grey and white matter properties distributed across many brain regions (Ball et al., 2019; Franx et al., 2016; Wolfers et al., 2017; Wu et al., 2019). However, replication in neuroimaging remains scarce, and the generalizability across populations of different ethnic, social, and cultural backgrounds is unknown. Furthermore, it remains unclear how any potential neuroimaging markers of ADHD, being a neurodevelopmental disorder, vary with age across the lifespan.

The present study aimed to identify structural brain differences in association with ADHD across the lifespan in two relatively large, independent cohorts. Using TBM, we created images capturing local brain volume variation in both grey and white-matter. Subsequently, ICA was used to isolate spatial modes from these images. We assessed association of the independent brain components with ADHD diagnosis and symptom dimensions in a discovery sample of adolescents and young adults (NeuroIMAGE). Further, we appraised the effect of a significantly associated component in an independent and clinically different validation sample of individuals diagnosed with ADHD during adulthood (Brazilian ImpACT cohort).

2. Methods and materials

2.1. Samples

2.1.1. NeuroIMAGE cohort

The NeuroIMAGE cohort is a Dutch prospective multi-site study aimed to investigate the longitudinal course of ADHD relying on two MRI waves (NeuroIMAGE I/II). Details of this cohort have been described elsewhere (von Rhein et al., 2015). Participants were enrolled at two sites, the Vrije Universiteit in Amsterdam and the Radboud University Medical Center in Nijmegen. The study was approved by the local ethics committees, and written informed consent was obtained from all participants and their legal guardians. The cohort included unrelated participants ($n = 138$) as well as those with full sibling relationships in families of different sizes ($n = 241$ sibling pairs, $n = 70$ three siblings, $n = 15$ four siblings). Considering the cross-sectional character of the present study and in order to maximize sample size, data from the two longitudinal study waves were combined such that individuals who participated twice were only included at the first wave (NeuroIMAGE I). The ADHD diagnosis was primarily based on a semi-structured clinical interview using a Dutch translation of the Schedule for Affective disorders and Schizophrenia for school-age children - present and lifetime version (K-SADS-PL), based on the fourth version of the diagnostic and statistical manual (DSM-IV). To optimize the

diagnostic assessment, the information from the K-SADS-PL interview was combined with information from the Conners Adult ADHD Rating Scale (CAARS R-L), Conners Parent Rating Scale (CPRS R:L), and Conners Wells Adolescent Self-Report Scale: Short Form (CASS:S). For an ADHD full diagnosis, individuals had to have six or more symptoms in the inattention domain and/or in the hyperactivity/impulsivity domain causing impairment in multiple settings, as well as a Conners T-score ≥ 63 . Unaffected individuals had ≤ 3 symptoms and a Conners T-score < 63 . Participants who did not fulfill criteria for either category were classified as *subthreshold* ADHD. Psychiatric comorbidities, such as anxiety, depression, and oppositional behavior were assessed by the Dutch version of the Strengths and Difficulties Questionnaire (SDQ). Exclusion criteria were: Intelligence Quotient (IQ) < 70 , diagnosis of autism, neurological disorders, such as epilepsy, general learning difficulties, brain trauma, or known genetic disorders, such as Fragile X or Down syndrome.

From the NeuroIMAGE I study wave, 807 individuals were enrolled for a scan session. In both sites, 1.5T MRI scanners were employed (Siemens Magnetom SONATA and AVANTO, Erlangen Germany), using 8-channel phased array head coils. T₁-weighted anatomical scans were acquired at an isotropic resolution of 1 mm using a 3D magnetization prepared rapid acquisition with gradient echoes (MPRAGE) sequence with 176 slices, flip angle = 7°, TE = 2.95 ms, TR = 2730 ms, TI = 1000 ms, matrix size = 256 × 256, and parallel acquisition (GRAPPA) with an acceleration factor of 2. From NeuroIMAGE II study wave, 87 subjects were considered, only from one site (Nijmegen); MRI scanner and image acquisition parameters remained the same as the first wave. After quality control, structural brain MRI scans of a total of 890 individuals were considered (359 affected, 98 subthreshold, and 433 unaffected; ages range from 7 to 29 years). Sample characteristics of this cohort are provided in Table 1.

2.1.2. Brazilian IMPACT cohort

The Brazilian IMPACT cohort was assessed by the ADHD Outpatient Program – Adult Division at the Hospital de Clínicas de Porto Alegre (PRODAH-A). Further information of this cohort has been described elsewhere (Cupertino et al., 2016; Karam et al., 2015). All participants were unrelated adults of white (European descent) Brazilian ethnicity aged 18 years or older. ADHD diagnosis was based on DSM-5 diagnostic criteria, using the K-SADS epidemiologic version (KSADS-E) adapted for adults (Grevet et al., 2005). Individuals were recruited when seeking for psychiatric help (cases) or donating blood (controls). The Structured Clinical Interview for DSM-IV Axis I Disorders (SCID-I) was used for assessing other lifetime psychiatric comorbidities. Individuals with significant neurological disease, head trauma, history of psychosis,

Table 1
Demographic and clinical characteristics of the NeuroIMAGE cohort.

	ADHD (N = 359)		Subthreshold (N = 98)		Controls (N = 433)	
	n	%	n	%	n	%
Sex (male)	247	68.8	56	57.1	206	47.6
Scan site (Nijmegen)	195	54.3	48	49.0	203	46.9
Wave drawn (NeuroIMAGE I)	336	93.6	85	86.7	386	89.1
Age (years) ^a	17.0	3.7	18.1	3.9	17.2	3.8
<i>Comorbidities (lifetime)</i>						
Oppositional Defiant Disorder	109	30.4	7	7.1	7	1.6
Conduct disorder	22	6.1	2	2.0	0	0
Major depressive disorder	4	1.1	0	0	2	0.5
Generalized anxiety disorder	6	1.7	2	2.0	2	0.5
Avoidant/social phobia disorder	3	0.8	0	0	1	0.2
Panic disorder	0	0	1	1.0	0	0
<i>Symptoms (KSADS)^a</i>						
Inattention	6.6	1.9	3.6	1.4	1.2	0.9
Hyperactivity/Impulsivity	5.2	2.4	2.8	1.5	1.4	1.0

^a Data represented as mean (standard deviation).

Table 2
Demographic and clinical characteristics of the Brazilian IMPACT cohort.

	ADHD (N = 118)		Controls (N = 62)	
	n	%	n	%
Sex (male)	51	43.2	33	53.2
Age (years) ^a	46.9	10.5	39.2	9.6
<i>Comorbidities (lifetime)</i>				
Generalized Anxiety Disorder	77	65.3	18	29.0
Oppositional Defiant Disorder	82	69.5	4	6.4
Major Depressive Disorder	53	44.9	23	37.1
Social Phobia	43	36.4	11	17.8
Bipolar Disorder*	36	30.5	3	4.8
Substance Use Disorder	33	28.0	5	8.1
Eating Disorders ^c	25	21.2	8	12.9
Obsessive Compulsive Disorder	26	22.0	2	3.2
Antisocial Personality Disorder	4	3.4	1	1.6
<i>Symptoms (KSADS)^a</i>				
Inattention	6.3	2.5	1.3	2.3
Hyperactivity/Impulsivity	4.6	2.7	1.2	1.6

^aData represented as mean (standard deviation).

*Including other specified bipolar and related disorder cases.

^cincluding anorexia nervosa, bulimia nervosa or binge-eating.

and/or an estimated IQ score below 70 were excluded. Participants signed an informed consent form before the study, which was approved by the Ethics Committee of the hospital. Sample characteristic can be found in Table 2.

This is also a prospective cohort, where all the images were acquired in the last assessment, when participants were re-evaluated on average 13 years after diagnosis and underwent MRI scanning, using a 3.0 T Siemens SPECTRA scanner and a 12-channel head coil. A high-resolution structural MRI volume was acquired using a T₁-weighted 3D MPRAGE sequence with 192 slices, flip angle = 7°, TE = 2.55 ms, TR = 2530 ms, TI = 1100 ms, matrix size = 256 × 256, isotropic resolution of 1 mm, and a GRAPPA factor of 2. After quality control procedures, 180 individuals with structural MRI scan were included (118 affected and 62 unaffected; age range from 26 to 74 years).

2.2. Imaging preprocessing

T1-weighted brain volumes were visually assessed for motion and other MRI artifacts by experienced operators. Linear and nonlinear registrations were determined for anatomical correction in the common template space by superimposing subjects' warped volume into the common brain template. The data preprocessing was performed using

FSL version 6.0.1 and ANTS toolkit version 2.2.0 in a CentOS-7 environment and compute nodes with Intel Xeon(R) processors.

Preprocessing for TBM was performed similar to previous analyses by our group (Soheili-Nezhad et al., 2020). All T1-weighted images were corrected for magnetic field bias using the N4 algorithm (Tustison et al., 2010), and the brain field of view was cropped using the FSL standard_space_roi tool. For each cohort separately, images were registered to an average space to create a cohort-specific minimum deformation brain template (Supplementary Fig. 1). Four iterations of linear registration and five iterations of diffeomorphic SyN registration were used for template creation (Avants et al., 2011). The nonlinear warps that transformed each subject's native brain volume to the common template were used to derive Jacobian determinant fields that encode local brain volume variation across the study individuals. The Jacobian values were subsequently log-transformed to symmetrize their distribution around zero to obtain Jacobian determinant maps per participant. The Jacobian values were normalized within a brain mask in the standard template space, hence removing the global brain size effect.

2.3. Analysis

The Jacobian determinant maps of the NeuroIMAGE cohort ($n = 890$) were decomposed into spatially independent components using MELODIC, a probabilistic ICA method (Beckmann, 2012), similar to previous studies by our group (Llera et al., 2019; Soheili-Nezhad et al., 2020). Four decompositions were performed with varying dimensionality (25, 50, 100 and 200 components) to allow the identification of independent spatial sources in the Jacobian fields at various levels of spatial specificity. Thus, a total of 375 components were extracted. ICA performs a linear matrix factorization of the Jacobian determinant maps resulting in 2 matrices: a matrix of spatially independent component maps reflecting the contribution of each voxel to each component; and a mixing matrix containing the loading of each individual on each component. The latter was used to test case-control differences in each spatial component.

In the discovery cohort (NeuroIMAGE), a permutation-based general linear model (PALM) (Winkler et al., 2014) was used to correct for multiple testing of all 375 brain components loading values with ADHD, while controlling for age, sex, scan site and study wave. To control for family structure in the NeuroIMAGE sample, permutation analysis was used with exchangeability blocks that only allow permutations either within unrelated participants or siblings-blocks separately, or whole-block permutations across families of the same sizes (Winkler et al., 2015). Type I error rate was controlled across all tested brain components using 10,000 random permutations.

To test the significant NeuroIMAGE-based ICA component in the Brazilian IMPACT cohort, the brain component significantly associated with ADHD in the discovery cohort was mapped to the brain template of the Brazilian IMPACT cohort using non-linear SyN transformation. Spatial regression was used to derive the level of brain volume in this spatial component in each subject of the Brazilian IMPACT cohort. The obtained brain volume parameter, now containing the values of the NeuroIMAGE-based ICA-feature for the subjects in Brazilian IMPACT cohort, was used as an imaging feature and its association with ADHD was assessed using linear regression, controlling for sex and age confounders. The replication cohort served as validation, and we avoided discovery ICA in this data as a perfect out-of-sample voxel-to-voxel replication is rare in multivariate methods such as ICA, and the spatial maps can be driven by the (demographic) characteristics of the cohort. Our aim was to exactly replicate the same ICA brain feature in the replication cohort and avoid any new exploration in the validation phase. Also, the sample size of the replication cohort ($n = 180$) is much smaller than the discovery cohort ($n = 890$), and therefore ICA stability is expected to be higher in the discovery sample. Significant findings from our primary analysis were also re-ran excluding subjects with

medication (stimulants or atomoxetine for NeuroIMAGE cohort and stimulants for Brazilian IMPACT cohort) in order to see if this could be an effect of the medication.

In addition to the ICA-based morphometry, standard voxel-wise tensor-based morphometry was also performed in the validation cohort to compare the sensitivity of ICA to standard, more commonly applied analyses. For this aim, voxel-wise differences in the Jacobian determinant maps of the ADHD and control subjects were investigated using the non-parametric method FSL *randomise* (Winkler et al., 2014), while correcting for the age and gender confounds.

3. Results

3.1. NeuroIMAGE cohort

A total of 375 components were obtained by probabilistic ICA showing areas of structural brain covariation across individuals, of them 52 components were nominally associated ($p_{uncorrected} < 0.05$) with current diagnosis of ADHD. Only one component spanning frontal lobes and striatum remained significant after multiple testing correction. This component showed reduced loading in individuals with current ADHD ($n = 359$, participants, mixed model $t = -3.61$; uncorrected $p = 3 \times 10^{-4}$, permutation-corrected $p = 0.0085$) and lifetime history of ADHD ($n = 418$ participants, mixed model $t = -3.19$, uncorrected p mixed model $= 3 \times 10^{-4}$, permutation-corrected $p = 0.0015$). The maximal focus of brain volume reduction in this component localized to the bilateral fronto-striatal white-matter adjacent to the orbitofrontal cortex - Fig. 1, also represented in as an e-component). This association remained significant after exclusion of individuals with a positive history of ADHD medication ($n = 197$ drug naïve patients, $p = 9 \times 10^{-4}$; $t = -3.36$). Results depicted in Table 3.

There was significant correlation of the fronto-striatal component with Conners' ADHD symptom dimensions; inattention $p = 0.012$, $t = -2.53$; hyperactivity $p = 0.003$, $t = -3.01$, and with the number of hyperactivity/impulsivity symptoms ($p = 0.040$, $t = -2.06$) but not with the number of inattention symptoms ($p = 0.21$; $t = -1.26$) assessed by the KSADS. The fronto-striatal component was correlated with subjects' sex (reduced in females compared to males; $p < 0.0001$, $t = 9.35$) and age (greater volume reductions with age; $p < 0.0001$, $t = -5.46$), although no interaction effects with sex or age were observed ($p = 0.92$ and 0.27 , respectively). The smaller group of participants with subthreshold ADHD also showed similar trend for reduced brain volume in the fronto-striatal component (current subthreshold diagnosis $n = 98$ subjects, $p = 0.11$, $t = -1.61$; lifetime subthreshold diagnosis $n = 74$, $p = 0.13$, $t = -1.54$).

3.1.1. Brazilian IMPACT cohort

The association of the fronto-striatal ICA component was replicated in the Brazilian IMPACT cohort with current ADHD ($p = 0.032$, $t = -2.16$) and with lifetime history of ADHD ($p = 0.021$, $t = -2.33$), also controlling for age and sex (Table 3 and Fig. 1). Again, this result remained significant when excluding individuals currently under pharmacological treatment ($p = 0.030$, $t = -2.18$). The same direction of effect was observed as in NeuroIMAGE: adults with ADHD showed smaller brain volume in the fronto-striatal component. The component was also associated with the number of hyperactivity/impulsivity symptoms ($p = 0.046$, $t = -2.011$), where a larger number of symptoms was associated with reduced brain volume. The component was associated with sex ($p < 0.001$, $t = 5.47$), but not with age ($p = 0.75$). There was no interaction of lifetime ADHD with sex ($p = 0.412$) or age ($p = 0.076$) on the component.

Unlike ICA, voxel-wise tensor-based morphometry did not show any significant differences in the Jacobian values that passed the multiple comparisons correction (TFCE - Winkler et al., 2014). A suggestively smaller volume was observed in this secondary voxel-wise analysis in the subcallosal cortex near the focus of ICA map in the orbitofrontal

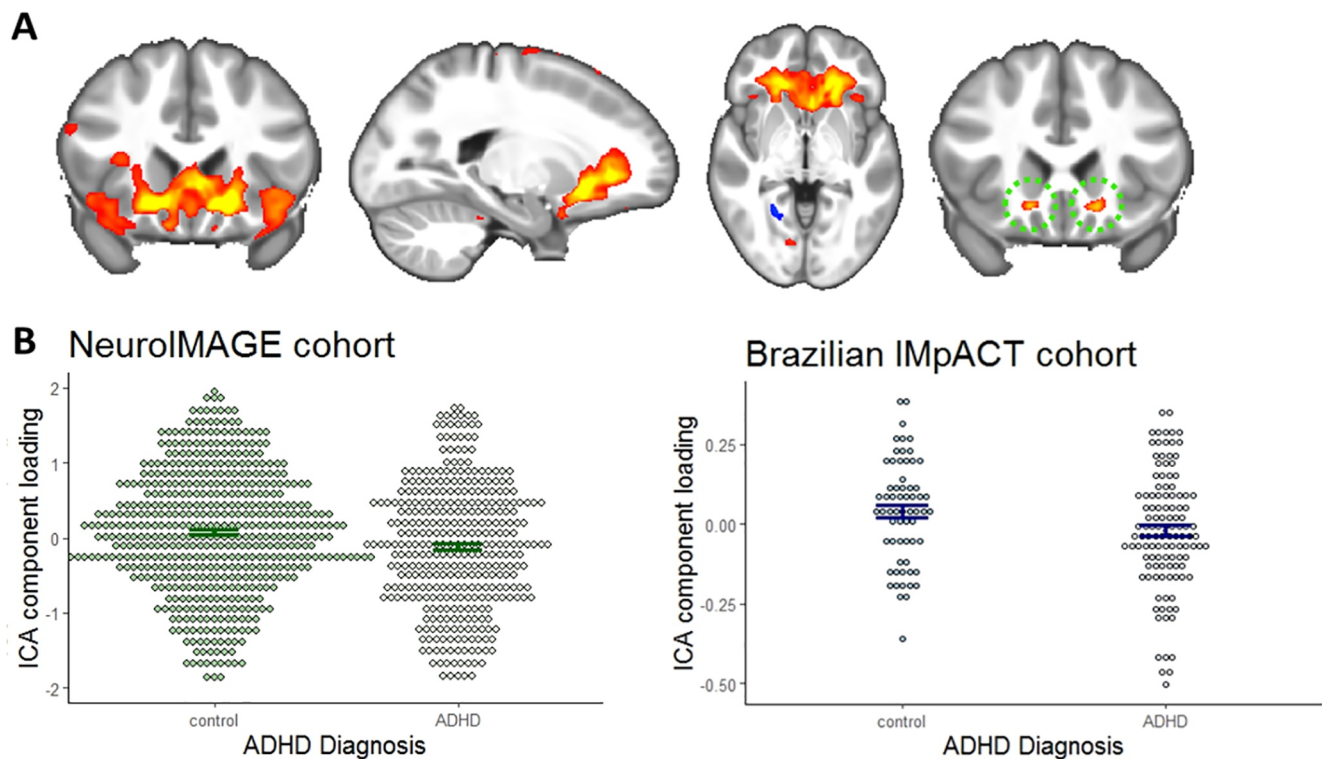


Fig. 1. ICA component associated with ADHD. **A.** ADHD patients demonstrated reduced loading of a component capturing volume of prefrontal white-matter together with orbitofrontal, striatal, and insular grey-matter (IC z-score > 3.6). The focal area of highest component probability (IC z-score > 8) is depicted on the right, showing orbitofrontal white-matter volume reduction bilaterally. **B.** Residualized ICA component loading in individuals with and without ADHD in both cohorts. Error bar indicates standard error.

Table 3

Loading of the ICA component spanning frontal lobes and striatum in both cohorts.

	<i>t</i>	P-value
<i>NeuroIMAGE cohort^a</i>		
ADHD lifetime	-3.20	0.0015*
ADHD current (at the time of scanning)	-3.62	0.0085*
ADHD symptoms (KSADS)		
Inattention	-1.26	0.21
Hyperactivity/Impulsivity	-2.06	0.04
ADHD symptoms (Conners ADHD)		
Inattention	-2.53	0.012
Hyperactivity/Impulsivity	-3.01	0.003
<i>Brazilian IMPACT cohort^b</i>		
ADHD lifetime	-2.33	0.021
ADHD current (at the time of scanning)	-2.16	0.032
ADHD symptoms		
Inattention	-1.455	0.15
Hyperactivity/Impulsivity	-2.011	0.046

P-values < 0.05 are represented in bold.

ICA = Independent component analysis; ADHD = Attention-Deficit/Hyperactivity Disorder. ^aAnalyses included age, sex, study site and study wave as covariates. ^bCalculated without considering ^{*}Permutation-corrected P-value ^bAnalysis included age and sex as covariates.

white-matter (Supplementary Fig. 2).

3.1.2. Secondary analyses

Considering the broad age-range of the two cohorts, and previously reported significant age-by-diagnosis interactions for brain volumes (Greven et al., 2015) or differences in brain volumes across the lifespan (Hoogman et al., 2019, 2017), other ICA components were also investigated for possible interactions with age. To reduce the number of tests, only components of the 200-component dimension were

investigated. In the NeuroIMAGE cohort, no ICA component showed significant interaction effects after multiple testing correction; however, a nominal effect was observed for 14 components (Supplementary Fig. 3). The strongest nominal finding was found for a component mapping to bilateral putamen (ICA 17 - Fig. 2), where participants with ADHD had a slower decrease in regional brain volume with age compared to controls ($P_{\text{uncorrected}} = 0.0043$ - Fig. 2). The 14 components showing nominal age-by-diagnosis interaction effect in the NeuroIMAGE cohort were also investigated in the Brazilian IMPACT cohort (Supplementary Fig. 3). In the adult cohort, a nominal interaction effect was observed only for the putamen-related component (ICA 17; $P_{\text{uncorrected}} = 0.025$; Fig. 2), in the same direction as in the NeuroIMAGE cohort, with the patients showing a less steep rate of decline with age compared to the controls.

4. Discussion

This study sought to identify structural brain associations with ADHD using a different approach from those used in previous structural MRI studies of ADHD. The data-driven approach presented here was sensitive to both grey- and white-matter volume variation, and the multivariate decomposition into independent spatial sources increased sensitivity to detect whole brain variations that are correlated, both spatially and across individuals. The results provide new evidence for the role of the fronto-striatal circuitry and point to the importance of white-matter in ADHD pathophysiology. Importantly, our work shows the robustness of this finding, as it was seen in two independent cohorts, which were geographically distant and comprised different stages of the lifespan. Also, the present study reported another component with a nominal age-by-diagnosis interaction effect in line with age-dependent effects previously observed in structural changes in ADHD.

A significant case-control brain volume difference was observed for a brain component localized to bilateral fronto-striatal white matter,

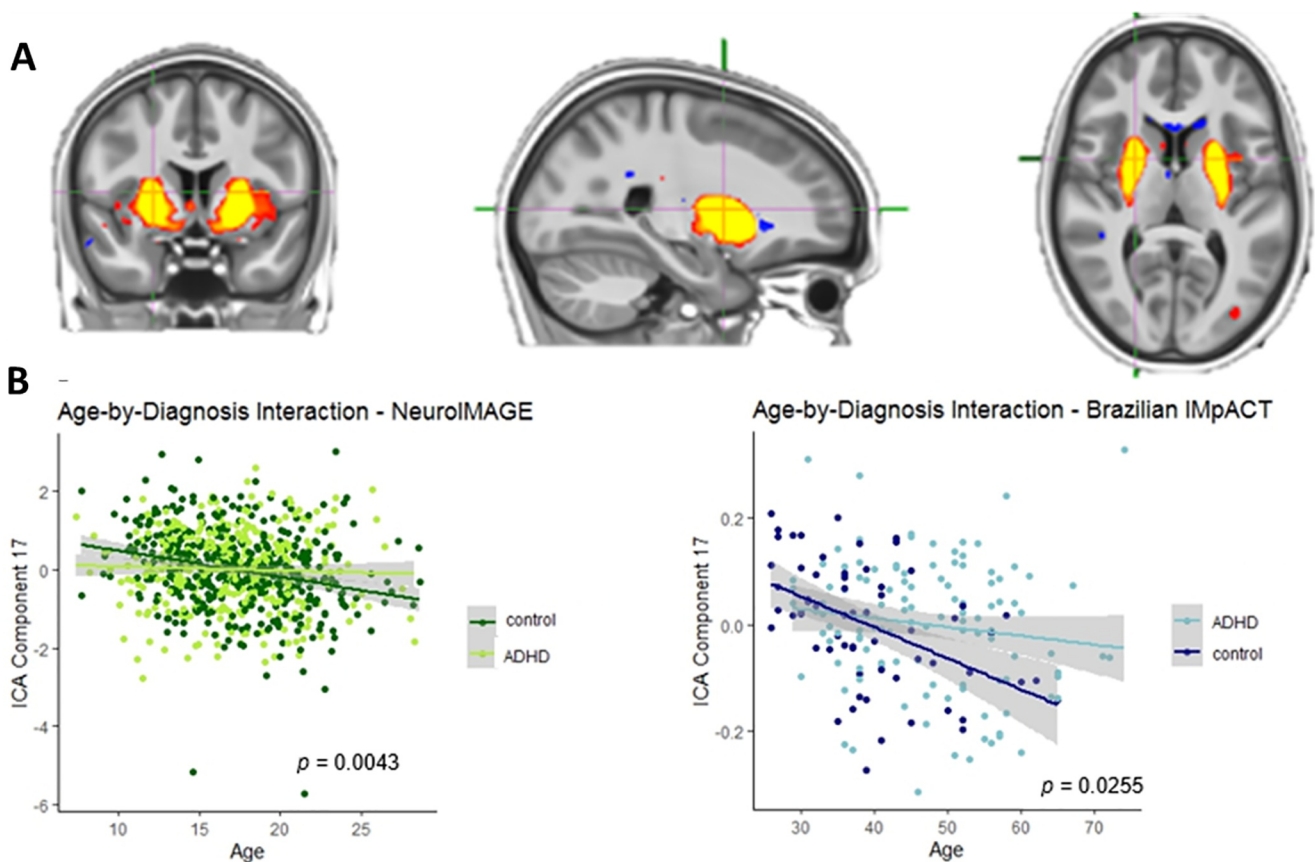


Fig. 2. Age-by-diagnosis interaction A. ICA component with strongest nominal age-by-diagnosis interaction effect. B. Plots of the age-by-diagnosis interaction on ICA component 17 in both cohorts.

adjacent to the orbitofrontal cortex. Interestingly, the subthreshold groups showed a similar trend, which is in line with ADHD as a continuous dimensional trait, rather than a strictly binary categorical disorder. Fronto-striatal circuits are implicated in complex behaviors, such as reward processing, emotion regulation, inhibition, and motivational states (Fettes et al., 2017), and the dysfunction of these circuits is implicated in several psychiatric disorders (Bonelli and Cummings, 2007; Fettes et al., 2017; Vaghi et al., 2017), including ADHD (Cubillo et al., 2012). Previous structural MRI studies have shown volume reductions in frontal lobes and the striatum (Albajara Sáenz et al., 2019; Hoogman et al., 2017) in individuals with ADHD compared to controls. Also, Ball et al (2019) found lower tissue volume in similar regions (i.e. dorso-lateral frontal regions and caudate) associate with ADHD symptoms (especially hyperactive). The absence of an age-by-group interaction and the replication across age-ranges in the present study indicates that this fronto-striatal association with ADHD is age-independent across adolescence and adulthood in two independent cohorts of different age ranges and shows for the first time that this fronto-striatal trait alterations generalizes to adults with ADHD up to middle age. ADHD has a different clinical profile across the lifespan, for instance children are more likely to present symptoms of hyperactivity (Franke et al., 2018). About 60% of children and 80% of adults with ADHD have some comorbidity (Gillberg et al., 2004; Jensen et al., 1997; Sobanski, 2006), and the comorbidity profile also differs with age. We also observed this here, between our two cohorts of different age-ranges. Despite these differences, we replicated our finding, supporting its robustness and its generalizability.

Our identification of a neurobiological alterations common to both children and adults with ADHD might help to elucidate the neurobiological etiology of ADHD in general, and in particular of its nature in adults versus children. In recent years, the diagnosis of ADHD across the

lifespan has been fiercely debated, with some authors suggesting that childhood and adulthood ADHD may have different neurobiological bases (Caye et al., 2017). Our findings indicate that the neurobiological underpinnings overlap at least partly between ADHD in adults and ADHD in children. There is no biological or neuroimaging marker to ADHD diagnosis. This is unlikely to be a diagnostic marker just like any other neuroimaging metric. Nevertheless, if more heterogeneity is accounted for it could contribute to a larger multivariate prediction model (Wolfers et al., 2019), but it is beyond the scope of the current paper to investigate this in detail.

Given that several studies, including the largest ADHD neuroimaging mega-analyses to date (Hoogman et al., 2019, 2017), suggested age-dependent associations of ADHD with brain anatomy, we also performed an exploratory analysis to identify potentially age-dependent associations of the ICA components with ADHD. We observed one nominal, but replicated, age-by-diagnosis interaction effect (of a different component from the main analysis) that was consistent in both cohorts. In line with Hoogman et al. (2017) and Greven et al. (2015), this component showing a nominal age-by-diagnosis interaction effect is mapped in the bilateral putamen, where the age-related volume decline occurred at slower rate in ADHD compared to the control group.

Contrary to most studies that use *a priori* segmented areas, we used data-driven ICA on voxel-wise data for separation of raw data into linearly mixed spatial sources. Assuming that the “true” biological impacts on brain structure are not randomly distributed across voxels, but caused by a mixture of underlying mechanisms that either augment or counteract each other’s effects, ICA can extract the non-Gaussian sources of these effects in a data-driven manner (Kundu et al., 2014; Pruim et al., 2015; Beckmann, 2012). Compared to univariate voxel-wise methods, ICA leverages the power of intrinsic covariance in the voxel-wise maps in two ways: it reduces the number of dependent

variables (voxels vs components), and it increases signal to noise (Beckmann, 2012; Pruim et al., 2015). Compared to region-of-interest analyses, decomposition of voxel-wise brain morphometry is useful to discover spatial features that covary beyond *a priori* defined regional boundaries, while avoiding mass univariate voxel wise tests. Extracting morphometric sources without predefined anatomical boundaries assists in deriving MRI features that may better reflect underlying pathophysiological processes. Moreover, using this approach, the maximal focus of brain volume deficits was detected in the bilateral fronto-striatal white-matter, suggesting the importance of considering both grey- and white-matter in conjunction. Comparison of the voxel-wise and ICA-based morphometry demonstrated that the impact of ADHD on brain structure is better captured by the latter method. Voxel-wise analysis only suggested reduction of grey-matter volume in the subcallosal frontal cortex at a trend level. However, ICA captured the impact on the whole fronto-striatal circuit at a statistically significant level. It is important to consider that our results might still be driven by local changes in grey matter alone that present as confluent changes in both grey and white voxels due to the smoothness of the nonlinear deformation fields. However we suspect that the ADHD-associated component is unlikely to be entirely driven by grey matter pathology since (1) similar studies using grey-matter segmented images have not found the same results as clearly, (2) indeed there is some contrast in white matter, and (3) the most evident boundaries around the associated component are the cortex (anterior) and subcortical nuclei (posterior), and if these are dilated it is most likely increased tissue in between, which is mostly white matter. Future studies in other imaging modalities (i.e. diffusion imaging) and, if possible post-mortem studies, would be highly valuable to further elucidate the presence and nature of white matter alterations in this area in detail. In fact, findings from diffusion MRI studies in correlate areas have supported our volumetric results from fronto-striatal regions, for example a meta-analysis reported white matter alterations in the uncinate fasciculus and parts of the anterior thalamic radiation (van Ewijk et al., 2012) in individuals with ADHD.

It is important to consider this study in the context of some strengths and limitations. This is a cross-sectional study of adolescents and adults, limiting conclusions with regard to brain structural changes across the lifespan and conclusions about developmental aspects, for which longitudinal imaging data would further increase sensitivity to within-subject longitudinal effects. Nevertheless, considering both cohorts, the study includes individuals of a wide age-range, even overlapping ages, allowing us to infer that the main result observed was independent of age.

In conclusion, using tensor-based morphometry driven by both grey- and white-matter, the present findings reinforce the importance of fronto-striatal circuitry and medial frontal white-matter in ADHD neurobiology. Identification of brain structural differences between individuals with and without ADHD provides new insights into the biology underlying this disorder and can contribute to improving diagnosis and treatment in the future. For this, the neural substrate observed here might be of particular interest, given its cross-cultural and age-independent validity.

CRedit authorship contribution statement

Renata Basso Cupertino: Conceptualization, Formal analysis, Writing - original draft, Visualization. **Sourena Soheili-Nezhad:** Conceptualization, Methodology, Software, Formal analysis, Writing - original draft. **Eugenio Horacio Grevet:** Resources, Supervision, Funding acquisition. **Cibele Edom Bandeira:** Data curation, Investigation. **Felipe Almeida Picon:** Investigation. **Maria Eduarda Tavares:** Data curation, Investigation. **Jilly Naaijen:** Data curation, Investigation. **Daan van Rooij:** Data curation, Investigation. **Sophie Akkermans:** Data curation, Investigation. **Eduardo Schneider Vitola:** Investigation. **Marcel P Zwiers:** Data curation. **Diego Luiz Rovaris:**

Investigation. **Pieter J. Hoekstra:** Conceptualization, Funding acquisition. **Vitor Breda:** Investigation. **Jaap Oosterlaan:** Conceptualization, Funding acquisition. **Catharina A Hartman:** Conceptualization, Funding acquisition. **Christian F Beckmann:** Methodology, Supervision. **Jan K Buitelaar:** Conceptualization, Funding acquisition, Supervision. **Barbara Franke:** Conceptualization, Funding acquisition, Supervision. **Claiton Henrique Dotto Bau:** Conceptualization, Supervision, Funding acquisition. **Emma Sprooten:** Conceptualization, Supervision, Project administration, Funding acquisition.

Acknowledgments

The NeuroIMAGE study was supported by NIH Grant R01MH62873 (to Stephen V. Faraone), NWO Large Investment Grant 1750102007010 (to Jan Buitelaar), ZonMW grant 60-60600-97-193, NWO grants 056-13-015 and 433-09-242, and matching grants from Radboud University Nijmegen Medical Center, University Medical Center Groningen and Accare, and Vrije Universiteit Amsterdam. The research leading to these results also received support from the European Community's Seventh Framework Programme (FP7/2007-2013) under grant agreement number 278948 (TACTICS). Brazilian IMPACT was financed by Conselho Nacional de Desenvolvimento Científico e Tecnológico (Grants 476529/2012-3, 466722/2014-1 and 424041/2016-2), the Coordenação de Aperfeiçoamento de Pessoal de Nível Superior - Brasil (CAPES) - Finance Code 001 and FIPE-HCPA 160600. Barbara Franke was supported by a personal Vici grant from the Innovation Program of the Netherlands Organization for Scientific Research (NWO; grant 016-130-669). Renata B Cupertino was supported by International Brain Research Organization-Latin America (IBRO LARC) Exchange Fellowship. Emma Sprooten is funded by a Hypatia Fellowship (Radboudumc) and a NARSAD Young Investigator Grant (Brain and Behavior Research Foundation, ID: 25034).

This study is part of the International Multicentre persistent ADHD Collaboration (IMPACT; www.impactadhdgenomics.com). IMPACT unites major research centres working on the genetics of ADHD persistence across the lifespan and has participants in The Netherlands, Germany, Spain, Norway, the United Kingdom, the United States, Brazil and Sweden. Principal investigators of IMPACT are: Barbara Franke (chair), Andreas Reif (co-chair), Stephen V. Faraone, Jan Haavik, Bru Cormand, J. Antoni Ramos-Quiroga, Marta Ribases, Philip Asherson, Klaus-Peter Lesch, Jonna Kuntsi, Claiton H.D. Bau, Jan K. Buitelaar, Alejandro Arias Vasquez, Tetyana Zayats, Henrik Larsson, Alysya Doyle, and Eugenio H. Grevet.

Disclosures

Eugenio Grevet was on the speaker's bureau for Novartis and Shire for the last 3 years. He also received travel awards (air tickets and hotel accommodations) for participating in two psychiatric meetings from Shire and Novartis. Barbara Franke has received educational speaking fees from Medice. Jan K Buitelaar has served as a consultant to/member of advisory board of/and/or speaker for Shire, Roche, Medice, and Servier. He is not an employee of any of these companies, and not a stock shareholder of any of these companies. He has no other financial or material support, including expert testimony, patents, royalties. All other authors declare that they have no conflict of interest.

Appendix A. Supplementary data

Supplementary data to this article can be found online at <https://doi.org/10.1016/j.nicl.2020.102403>.

References

Albajara Sáenz, A., Villemonteix, T., Massat, I., 2019. Structural and functional

- neuroimaging in attention-deficit/hyperactivity disorder. *Dev. Med. Child Neurol.* <https://doi.org/10.1111/dmcn.14050>.
- Aoki, Y., Cortese, S., Castellanos, F.X., 2018. Diffusion tensor imaging studies of attention-deficit/hyperactivity disorder: meta-analyses and reflections on head motion. *J. Child Psychol. Psychiatry Allied Discip.* 59, 193–202. <https://doi.org/10.1111/jcpp.12778>.
- Ashburner, J., Friston, K.J., 2000. Voxel-based morphometry - the methods. *Neuroimage* 11, 805–821. <https://doi.org/10.1006/nimg.2000.0582>.
- Ashburner, J., Hutton, C., Frackowiak, R., Johnsrude, I., Price, C., Friston, K., 1998. Identifying global anatomical differences: deformation-based morphometry. *Human Brain Mapping* 348–357. [https://doi.org/10.1002/\(SICI\)1097-0193\(1998\)6:5/6<348::AID-HBM4>3.0.CO;2-P](https://doi.org/10.1002/(SICI)1097-0193(1998)6:5/6<348::AID-HBM4>3.0.CO;2-P).
- Avants, B.B., Tustison, N.J., Song, G., Cook, P.A., Klein, A., Gee, J.C., 2011. A reproducible evaluation of ANTs similarity metric performance in brain image registration. *Neuroimage* 54, 2033–2044. <https://doi.org/10.1016/j.neuroimage.2010.09.025>.
- Ball, G., Malpas, C.B., Genc, S., Efron, D., Sciberras, E., Anderson, V., Nicholson, J.M., Silk, T.J., 2019. Multimodal structural neuroimaging markers of brain development and ADHD symptoms. *Am. J. Psychiatry* 176, 57–66. <https://doi.org/10.1176/appi.ajp.2018.18010034>.
- Beckmann, C.F., 2012. Modelling with independent components. *Neuroimage* 62, 891–901. <https://doi.org/10.1016/j.neuroimage.2012.02.020>.
- Beckmann, C.F., Smith, S.M., 2005. Tensorial extensions of independent component analysis for multisubject fMRI analysis. *Neuroimage* 25, 294–311. <https://doi.org/10.1016/j.neuroimage.2004.10.043>.
- Beckmann, C.F., DeLuca, M., Devlin, J.T., Smith, S.M., 2005. Investigations into resting-state connectivity using independent component analysis. *Philos. Trans. R. Soc. B Biol. Sci.* 360, 1001–1013. <https://doi.org/10.1098/rstb.2005.1634>.
- Bonelli, R.M., Cummings, J.L., 2007. Frontal-subcortical circuitry and behavior. *Dialoques Clin. Neurosci.* 9, 141–151.
- Bralten, J., Greven, C.U., Franke, B., Mennes, M., Zwiers, M.P., Rommelse, N.N.J., Hartman, C., van der Meer, D., O'Dwyer, L., Oosterlaan, J., Hoekstra, P.J., Heslenfeld, D., Arias-Vasquez, A., Buitelaar, J.K., 2016. Voxel-based morphometry analysis reveals frontal brain differences in participants with ADHD and their unaffected siblings. *J. Psychiatry Neurosci.* 41, 272–279. <https://doi.org/10.1503/jpn.140377>.
- Castellanos, F.X., Tannock, R., 2002. Neuroscience of attention-deficit/hyperactivity disorder: the search for endophenotypes. *Nat. Rev. Neurosci.* 3, 617–628. <https://doi.org/10.1038/nrn896>.
- Caye, A., Sibley, M.H., Swanson, J.M., Rohde, L.A., 2017. Late-onset ADHD: understanding the evidence and building theoretical frameworks. *Curr. Psychiatry Rep.* 19. <https://doi.org/10.1007/s11920-017-0858-7>.
- Chen, L., Hu, X., Ouyang, L., He, N., Liao, Y., Liu, Q., Zhou, M., Wu, M., Huang, X., Gong, Q., 2016. A systematic review and meta-analysis of tract-based spatial statistics studies regarding attention-deficit/hyperactivity disorder. *Neurosci. Biobehav. Rev.* <https://doi.org/10.1016/j.neubiorev.2016.07.022>.
- Cubillo, A., Halari, R., Smith, A., Taylor, E., Rubia, K., 2012. A review of fronto-striatal and fronto-cortical brain abnormalities in children and adults with Attention Deficit Hyperactivity Disorder (ADHD) and new evidence for dysfunction in adults with ADHD during motivation and attention. *Cortex* 48, 194–215. <https://doi.org/10.1016/j.cortex.2011.04.007>.
- Cupertino, R.B., Schuch, J.B., Bandeira, C.E., da Silva, B.S., Rovaris, D.L., Kappel, D.B., Contini, V., Salatino-Oliveira, A., Vitola, E.S., Karam, R.G., Hutz, M.H., Rohde, L.A., Grevet, E.H., Bau, C.H.D., Mota, N.R., 2016. Replicated association of Synaptotagmin (SYT1) with ADHD and its broader influence in externalizing behaviors. *Eur. Neuropsychopharmacol.* <https://doi.org/10.1016/j.euroneuro.2017.01.007>.
- Faraone, S.V., Biederman, J., Mick, E., 2006. The age-dependent decline of Attention Deficit Hyperactivity Disorder: a meta-analysis of follow-up studies. *Psychol. Med.* 36, 159–165. <https://doi.org/10.1017/s003329170500471x>.
- Fettes, P., Schulze, L., Downar, J., 2017. Cortico-striatal-thalamic loop circuits of the orbitofrontal cortex: promising therapeutic targets in psychiatric illness. *Front. Syst. Neurosci.* 11, 1–23. <https://doi.org/10.3389/fnsys.2017.00025>.
- Franx, W., Zwiers, M.P., Mennes, M., Oosterlaan, J., Heslenfeld, D., Hoekstra, P.J., Hartman, C.A., Franke, B., Faraone, S.V., O'Dwyer, L., Buitelaar, J.K., 2015. White matter microstructure and developmental improvement of hyperactive/impulsive symptoms in attention-deficit/hyperactivity disorder. *J. Child Psychol. Psychiatry Allied Discip.* 56, 1289–1297. <https://doi.org/10.1111/jcpp.12379>.
- Franx, W., Llera, A., Mennes, M., Zwiers, M.P., Faraone, S.V., Oosterlaan, J., Heslenfeld, D., Hoekstra, P.J., Hartman, C.A., Franke, B., Buitelaar, J.K., Beckmann, C.F., 2016. Integrated analysis of gray and white matter alterations in attention-deficit/hyperactivity disorder. *NeuroImage Clin.* 11, 357–367. <https://doi.org/10.1016/j.nicl.2016.03.005>.
- Franke, B., Michelini, G., Asherson, P., Banaschewski, T., Bilbow, A., Buitelaar, J.K., Cormand, B., Faraone, S.V., Ginsberg, Y., Haavik, J., Kuntsi, J., Larsson, H., Lesch, K.P., Ramos-Quiroga, J.A., Réthelyi, J.M., Ribases, M., Reif, A., 2018. Live fast, die young? A review on the developmental trajectories of ADHD across the lifespan. *Eur. Neuropsychopharmacol.* 28, 1059–1088. <https://doi.org/10.1016/j.euroneuro.2018.08.001>.
- Gillberg, C., Gillberg, I.C., Rasmussen, P., Kadesjö, B., Söderström, H., Råstam, M., Johnson, M., Rothenberger, A., Niklasson, L., 2004. Co-existing disorders in ADHD - implications for diagnosis and intervention. *Eur. Child Adolesc. Psychiatry.* <https://doi.org/10.1007/s00787-004-1008-4>.
- Greven, C.U., Bralten, J., Mennes, M., O'Dwyer, L., Van Hulzen, K.J.E., Rommelse, N., Schueren, L.J.S., Hoekstra, P.J., Hartman, C.A., Heslenfeld, D., Oosterlaan, J., Faraone, S.V., Franke, B., Zwiers, M.P., Arias-Vasquez, A., Buitelaar, J.K., 2015. Developmentally stable whole-brain volume reductions and developmentally sensitive caudate and putamen volume alterations in those with attention-deficit/hyperactivity disorder and their unaffected siblings. *JAMA Psychiatry* 72, 490–499. <https://doi.org/10.1001/jamapsychiatry.2014.3162>.
- Grevet, E.H., Bau, C.H.D., Salgado, C.A.I., Ficher, A., Victor, M.M., Garcia, C., de Sousa, N.O., Nerung, L., Belmonte-De-Abreu, P., 2005. Interrater reliability for diagnosis in adults of attention deficit hyperactivity disorder and oppositional defiant disorder using K-SADS-E. *Arq. Neuropsiquiatr.* 63, 307–310.
- Gupta, C.N., Calhoun, V.D., Rachakonda, S., Chen, J., Patel, V., Liu, J., Segall, J., Franke, B., Zwiers, M.P., Arias-Vasquez, A., Buitelaar, J., Fisher, S.E., Fernandez, G., Van Erp, T.G.M., Potkin, S., Ford, J., Mathalon, D., McEwen, S., Lee, H.E., Mueller, B.A., Greve, D.N., Andreassen, O., Agartz, I., Gollub, R.L., Sponheim, S.R., Ehrlich, S., Wang, L., Pearlson, G., Glahn, D.C., Sprooten, E., Mayer, A.R., Stephen, J., Jung, R.E., Canive, J., Bustillo, J., Turner, J.A., 2015. Patterns of gray matter abnormalities in schizophrenia based on an international mega-analysis. *Schizophr. Bull.* 41, 1133–1142. <https://doi.org/10.1093/schbul/sbu177>.
- Hoogman, M., Bralten, J., Hibar, D.P., Mennes, M., Zwiers, M.P., Schueren, L.S.J., van Hulzen, K.J.E., Medland, S.E., Shumskaya, E., Jahanshad, N., de Zeeuw, P., Szekely, E., Sudre, G., Wolfers, T., Onnink, A.M.H., Dammers, J.T., Mostert, J.C., Vives-Gilabert, Y., Kohls, G., Oberwandel, E., Seitz, J., Schulte-Rüther, M., Ambrosino, S., Doyle, A.E., Høvik, M.F., Dramsdahl, M., Tamm, L., van Erp, T.G.M., Dale, A., Schork, A., Conzelmann, A., Zierhut, K., Baur, R., McCarthy, H., Yoncheva, Y.N., Cubillo, A., Chantiluke, K., Mehta, M.A., Paloyelis, Y., Hohmann, S., Baumeister, S., Bramati, I., Mattos, P., Tovar-Moll, F., Douglas, P., Banaschewski, T., Brandeis, D., Kuntsi, J., Asherson, P., Rubia, K., Kelly, C., Martino, A.D., Milham, M.P., Castellanos, F.X., Frodl, T., Zentis, M., Lesch, K.-P., Reif, A., Pauli, P., Jernigan, T.L., Haavik, J., Plessen, K.J., Lundervold, A.J., Hugdahl, K., Seidman, L.J., Biederman, J., Rommelse, N., Heslenfeld, D.J., Hartman, C.A., Hoekstra, P.J., Oosterlaan, J., von Polier, G., Konrad, K., Vilarroya, O., Ramos-Quiroga, J.A., Soliva, J.C., Durston, S., Buitelaar, J.K., Faraone, S.V., Shaw, P., Thompson, P.M., Franke, B., 2017. Subcortical brain volume differences in participants with attention deficit hyperactivity disorder in children and adults: a cross-sectional mega-analysis. *Lancet Psychiatry* 4, 1–10. [https://doi.org/10.1016/S2215-0366\(17\)30049-4](https://doi.org/10.1016/S2215-0366(17)30049-4).
- Hoogman, M., Muetzel, R., Guimaraes, J.P., Shumskaya, E., Mennes, M., Zwiers, M.P., Jahanshad, N., Sudre, G., Wolfers, T., Earl, E.A., Soliva Vila, J.C., Vives-Gilabert, Y., Khadka, S., Novotny, S.E., Hartman, C.A., Heslenfeld, D.J., Schueren, L.S.J., Ambrosino, S., Oranje, B., de Zeeuw, P., Chaim-Avincini, T.M., Rosa, P.G.P., Zanetti, M. V., Malpas, C.B., Kohls, G., von Polier, G.G., Seitz, J., Biederman, J., Doyle, A.E., Dale, A.M., van Erp, T.G.M., Epstein, J.N., Jernigan, T.L., Baur-Streubel, R., Ziegler, G.C., Zierhut, K.C., Schranz, A., Høvik, M.F., Lundervold, A.J., Kelly, C., McCarthy, H., Skokauskas, N., O'Gorman Tuura, R.L., Calvo, A., Lera-Miguel, S., Nicolau, R., Chantiluke, K.C., Christakou, A., Vance, A., Cercignani, M., Gabel, M.C., Asherson, P., Baumeister, S., Brandeis, D., Hohmann, S., Bramati, I.E., Tovar-Moll, F., Fallgatter, A. J., Kardatzki, B., Schwarz, L., Anikín, A., Baranov, A., Gogberashvili, T., Kapilushniy, D., Solovieva, A., El Marroun, H., White, T., Karkashadze, G., Namazova-Baranova, L., Etheofer, T., Mattos, P., Banaschewski, T., Coghill, D., Plessen, K.J., Kuntsi, J., Mehta, M.A., Paloyelis, Y., Harrison, N.A., Bellgrove, M.A., Silk, T.J., Cubillo, A.I., Rubia, K., Lázaro, L., Brem, S., Walitza, S., Frodl, T., Zentis, M., Castellanos, F.X., Yoncheva, Y.N., Haavik, J., Reneman, L., Conzelmann, A., Lesch, K.-P., Pauli, P., Reif, A., Tamm, L., Konrad, K., Oberwandel, Weiss, E., Busatto, G.F., Louza, M.R., Durston, S., Hoekstra, P.J., Oosterlaan, J., Stevens, M.C., Ramos-Quiroga, J.A., Vilarroya, O., Fair, D.A., Nigg, J.T., Thompson, P.M., Buitelaar, J.K., Faraone, S. V., Shaw, P., Tiemeier, H., Bralten, J., Franke, B., 2019. Brain Imaging of the Cortex in ADHD: A Coordinated Analysis of Large-Scale Clinical and Population-Based Samples. *Am. J. Psychiatry* appi.ajp.2019.1. DOI:10.1176/appi.ajp.2019.18091033.
- Jensen, P.S., Martin, D., Cantwell, D.P., 1997. Comorbidity in ADHD: implications for research, practice, and DSM-V. *J. Am. Acad. Child Adolesc. Psychiatry* 36, 1065–1079. <https://doi.org/10.1097/00004583-199708000-00014>.
- Karam, R.G., Breda, V., Picon, F.A., Rovaris, D.L., Victor, M.M., Salgado, C.A.I., Vitola, E.S., Silva, K.L., Guimarães-da-Silva, P.O., Mota, N.R., Caye, A., Belmonte-de-Abreu, P., Rohde, L.A., Grevet, E.H., Bau, C.H.D., 2015. Persistence and remission of ADHD during adulthood: a 7-year clinical follow-up study. *Psychol. Med.* 45, 2045–2056. <https://doi.org/10.1017/S0033291714003183>.
- Katzman, M.A., Bilkey, T.S., Chokka, P.R., Fallu, A., Klassen, L.J., 2017. Adult ADHD and comorbid disorders: clinical implications of a dimensional approach. *BMC Psychiatry.* <https://doi.org/10.1186/s12888-017-1463-3>.
- Kundu, P., Santin, M.D., Bandettini, P.A., Bullmore, E.T., Petiet, A., 2014. Differentiating BOLD and non-BOLD signals in fMRI time series from anesthetized rats using multi-echo EPI at 11.7T. *Neuroimage* 102, 861–874. <https://doi.org/10.1016/j.neuroimage.2014.07.025>.
- Llera, A., Wolfers, T., Mulders, P., Beckmann, C.F., 2019. Inter-individual differences in human brain structure and morphology link to variation in demographics and behavior. *Elife* 8. <https://doi.org/10.7554/eLife.44443>.
- Luman, M., Oosterlaan, J., Sergeant, J.A., 2005. The impact of reinforcement contingencies on AD/HD: a review and theoretical appraisal. *Clin. Psychol. Rev.* 25, 183–213. <https://doi.org/10.1016/j.cpr.2004.11.001>.
- Nakao, T., Radua, J., Rubia, K., Mataix-Cols, D., 2011. Gray matter volume abnormalities in ADHD: voxel-based meta-analysis exploring the effects of age and stimulant medication. *Am. J. Psychiatry.* <https://doi.org/10.1176/appi.ajp.2011.11020281>.
- O'Muircheartaigh, J., Jabdi, S., 2018. Concurrent white matter bundles and grey matter networks using independent component analysis. *Neuroimage* 170, 296–306. <https://doi.org/10.1016/j.neuroimage.2017.05.012>.
- Özbaran, B., Kalyoncu, T., Köse, S., 2018. Theory of mind and emotion regulation difficulties in children with ADHD. *Psychiatry Res.* 270, 117–122. <https://doi.org/10.1016/j.psychres.2018.09.034>.
- Pruim, R.H.R., Mennes, M., van Rooij, D., Llera, A., Buitelaar, J.K., Beckmann, C.F., 2015. ICA-AROMA: A robust ICA-based strategy for removing motion artifacts from fMRI data. *Neuroimage* 112, 267–277. <https://doi.org/10.1016/j.neuroimage.2015.02.064>.

- Sobanski, E., 2006. Psychiatric comorbidity in adults with attention-deficit/hyperactivity disorder (ADHD). *Eur. Arch. Psychiatry Clin. Neurosci.* 256, 26–31. <https://doi.org/10.1007/s00406-006-1004-4>.
- Sobanski, E., Brüggemann, D., Alm, B., Kern, S., Deschner, M., Schubert, T., Philipsen, A., Rietschel, M., 2007. Psychiatric comorbidity and functional impairment in a clinically referred sample of adults with attention-deficit/hyperactivity disorder (ADHD). *Eur. Arch. Psychiatry Clin. Neurosci.* 257, 371–377. <https://doi.org/10.1007/s00406-007-0712-8>.
- Soheili-Nezhad, Sourena, Jahanshad, Neda, Guelfi, Sebastian, Khosrowabadi, Reza, Saykin, Andrew J, Thompson, Paul M, Beckmann, Christian F, Sprooten, Emma, Zarei, Mojtaba, the Alzheimer's Disease Neuroimaging, 2020. Imaging genomics discovery of a new risk variant for Alzheimer's disease in the postsynaptic SHARPIN gene. *Human Brain Mapping* 41 (13), 3737–3748. <https://doi.org/10.1002/hbm.25083>. In this issue.
- Sörös, P., Bachmann, K., Lam, A.P., Kanat, M., Hoxhaj, E., Matthies, S., Feige, B., Müller, H.H.O., Thiel, C., Philipsen, A., 2017. Inattention predicts increased thickness of left occipital cortex in men with attention-deficit/hyperactivity disorder. *Front. Psychiatry* 8. <https://doi.org/10.3389/fpsy.2017.00170>.
- Sprooten, E., Gupta, C.N., Knowles, E.E.M., McKay, D.R., Mathias, S.R., Curran, J.E., Kent, J.W., Carless, M.A., Almeida, M.A., Dyer, T.D., Göring, H.H.H., Olvera, R.L., Kochunov, P., Fox, P.T., Duggirala, R., Almasy, L., Calhoun, V.D., Blangero, J., Turner, J.A., Glahn, D.C., 2015. Genome-wide significant linkage of schizophrenia-related neuroanatomical trait to 12q24. *Am. J. Med. Genet. Part B Neuropsychiatr. Genet.* 168, 678–686. <https://doi.org/10.1002/ajmg.b.32360>.
- Torgersen, T., Gjervan, B., Rasmussen, K., 2006. ADHD in adults: a study of clinical characteristics, impairment and comorbidity. *Nord. J. Psychiatry* 60, 38–43. <https://doi.org/10.1080/08039480500520665>.
- Tustison, N.J., Avants, B.B., Cook, P.A., Zheng, Y., Egan, A., Yushkevich, P.A., Gee, J.C., 2010. N4ITK: improved N3 bias correction. *IEEE Trans. Med. Imaging* 29, 1310–1320. <https://doi.org/10.1109/TMI.2010.2046908>.
- Vaghi, M.M., Vértes, P.E., Kitzbichler, M.G., Apergis-Schoute, A.M., van der Flier, F.E., Fineberg, N.A., Sule, A., Zaman, R., Voon, V., Kundu, P., Bullmore, E.T., Robbins, T.W., 2017. Specific frontostriatal circuits for impaired cognitive flexibility and goal-directed planning in obsessive-compulsive disorder: evidence from resting-state functional connectivity. *Biol. Psychiatry* 81, 708–717. <https://doi.org/10.1016/j.biopsych.2016.08.009>.
- Valera, E.M., Faraone, S.V., Murray, K.E., Seidman, L.J., 2007. Meta-analysis of structural imaging findings in attention-deficit/hyperactivity disorder. *Biol. Psychiatry* 61, 1361–1369. <https://doi.org/10.1016/j.biopsych.2006.06.011>.
- van Ewijk, H., Heslenfeld, D.J., Zwiers, M.P., Buitelaar, J.K., Oosterlaan, J., 2012. Diffusion tensor imaging in attention deficit/hyperactivity disorder: a systematic review and meta-analysis. *Neurosci. Biobehav. Rev.* 36, 1093–1106. <https://doi.org/10.1016/j.neubiorev.2012.01.003>.
- van Ewijk, H., Heslenfeld, D.J., Zwiers, M.P., Faraone, S.V., Luman, M., Hartman, C.A., Hoekstra, P.J., Franke, B., Buitelaar, J.K., Oosterlaan, J., 2014. Different mechanisms of white matter abnormalities in attention-deficit/hyperactivity disorder: a diffusion tensor imaging study. *J. Am. Acad. Child Adolesc. Psychiatry* 53, 790–799. <https://doi.org/10.1016/j.jaac.2014.05.001>.
- Vitola, E.S., Bau, C.H.D., Salum, G.A., Horta, B.L., Quevedo, L., Barros, F.C., Pinheiro, R.T., Kieling, C., Rohde, L.A., Grevet, E.H., 2017. Exploring DSM-5 ADHD criteria beyond young adulthood: phenomenology, psychometric properties and prevalence in a large three-decade birth cohort. *Psychol. Med.* 47, 744–754. <https://doi.org/10.1017/S0033291716002853>.
- von Rhein, D., Mennes, M., van Ewijk, H., Groenman, A.P., Zwiers, M.P., Oosterlaan, J., Heslenfeld, D., Franke, B., Hoekstra, P.J., Faraone, S.V., Hartman, C., Buitelaar, J., 2015. The NeuroIMAGE study: a prospective phenotypic, cognitive, genetic and MRI study in children with attention-deficit/hyperactivity disorder. Design and descriptors. *Eur. Child Adolesc. Psychiatry* 24, 265–281. <https://doi.org/10.1007/s00787-014-0573-4>.
- Willcutt, E.G., Doyle, A.E., Nigg, J.T., Faraone, S.V., Pennington, B.F., 2005. Validity of the executive function theory of attention-deficit/hyperactivity disorder: a meta-analytic review. *Biol. Psychiatry*. <https://doi.org/10.1016/j.biopsych.2005.02.006>.
- Winkler, A.M., Ridgway, G.R., Webster, M.A., Smith, S.M., Nichols, T.E., 2014. Permutation inference for the general linear model. *Neuroimage* 92, 381–397. <https://doi.org/10.1016/j.neuroimage.2014.01.060>.
- Winkler, A.M., Webster, M.A., Vidaurre, D., Nichols, T.E., Smith, S.M., 2015. Multi-level block permutation. *Neuroimage* 123, 253–268. <https://doi.org/10.1016/j.neuroimage.2015.05.092>.
- Wolfers, T., Arenas, A.L., Onnink, A.M.H., Dammers, J., Hoogman, M., Zwiers, M.P., Buitelaar, J.K., Franke, B., Marquand, A.F., Beckmann, C.F., 2017. Refinement by integration: aggregated effects of multimodal imaging markers on adult ADHD. *J. Psychiatry Neurosci.* 42, 386–394. <https://doi.org/10.1503/jpn.160240>.
- Wolfers, T., Beckmann, C.F., Hoogman, M., Buitelaar, J.K., Franke, B., Marquand, A.F., 2019. Individual differences v. The average patient: mapping the heterogeneity in ADHD using normative models. *Psychol. Med.* <https://doi.org/10.1017/S0033291719000084>.
- Wu, L., Calhoun, V.D., Jung, R.E., Caprihan, A., 2015. Connectivity-based whole brain dual parcellation by group ICA reveals tract structures and decreased connectivity in schizophrenia. *Hum. Brain Mapp.* 36, 4681–4701. <https://doi.org/10.1002/hbm.22945>.
- Wu, Z.M., Llera, A., Hoogman, M., Cao, Q.J., Zwiers, M.P., Bralten, J., An, L., Sun, L., Yang, L., Yang, B.R., Zang, Y.F., Franke, B., Beckmann, C.F., Mennes, M., Wang, Y.F., 2019. Linked anatomical and functional brain alterations in children with attention-deficit/hyperactivity disorder. *NeuroImage Clin.* 23. <https://doi.org/10.1016/j.nicl.2019.101851>.
- Xu, L., Groth, K.M., Pearlson, G., Schretlen, D.J., Calhoun, V.D., 2009. Source-based morphometry: the use of independent component analysis to identify gray matter differences with application to schizophrenia. *Hum. Brain Mapp.* 30, 711–724. <https://doi.org/10.1002/hbm.20540>.