

Microscopic qualitative evaluation of fixation time and decalcification media in rat maxillary periodontium

Avaliação microscópica qualitativa do tempo de fixação e dos meios de descalcificação do periodonto de ratos

Marilene Issa Fernandes^(a)
Eduardo José Gaio^(b)
Cassiano Kuchenbecker Rosing^(a)
Rui Vicente Oppermann^(a)
Pantelis Varvaki Rado^(c)

^(a)Professors of Periodontology; ^(b)Graduate Student; ^(c)Professor of Oral Pathology – School of Dentistry, Federal University of Rio Grande do Sul.

Abstract: The rat model is widely used in periodontal research and the quality of histological sections is essential. The purpose of this study was to evaluate the histological characteristics of periodontal tissues in Wistar rat maxillae, with different times of fixation and decalcified by nitric acid or formic acid (Anna Morse Solution). Fifteen rats were used. Fixation was performed for 24, 48 and 72 hours. The maxillae were hemi-sectioned and each part was decalcified either in nitric acid for 7 days or in Anna Morse solution for 35 days. Two trained and blinded examiners performed the evaluation. Forty eight hours of fixation and decalcification with Anna Morse solution showed more clear characteristics of the epithelium-connective tissue interface and of the periodontal structures. Mean measurements between the cementum-enamel junction and the bone crest varied in the different experimental times from 176.5 (\pm 60.45) to 210.94 (\pm 39.33) pixels on the buccal aspect, and from 199.69 (\pm 38.33) to 298.55 (\pm 70.81) pixels on the palatal aspect, with no statistically significant differences (ANOVA, $p > 0.05$). In the same fixation period, decalcification with nitric acid or Anna Morse solution did not display any statistically significant differences. It may be concluded that for a qualitative histological analysis, fixation should preferably be for 48 hours and the demineralization should be made by Anna Morse solution. For a histomorphometric analysis, the decalcification solution does not interfere in the results.

Descriptors: Histology; Periodontium; Dental research.

Resumo: O modelo rato é extensamente usado na pesquisa periodontal, e a qualidade dos cortes histológicos é essencial. A proposta deste estudo foi avaliar as características histológicas dos tecidos periodontais nas maxilas de ratos Wistar, após diferentes períodos de fixação e descalcificação pelo ácido nítrico ou pelo ácido fórmico (Solução de Anna Morse). Quinze ratos foram usados. A fixação foi realizada nos períodos de 24, 48 e 72 horas. As maxilas foram divididas e parte foi descalcificada em ácido nítrico durante 7 dias e parte com solução de Anna Morse por 35 dias. Dois examinadores treinados e cegos executaram a avaliação. Quarenta e oito horas de fixação e descalcificação com solução de Anna Morse mostraram características mais evidentes da interface epitélio-conjuntivo, assim como das estruturas periodontais. As médias, por vestibular, entre a junção cimento-esmalte e a crista óssea nos diferentes tempos experimentais variaram entre 176,5 (\pm 60,45) e 210,94 (\pm 39,33) “pixels”, e, na face palatina, entre 199,69 (\pm 38,33) e 298,55 (\pm 70,81) “pixels”, sem nenhuma diferença estatisticamente significativa (ANOVA, $p > 0,05$). No mesmo período de fixação, a descalcificação com ácido nítrico ou solução de Anna Morse não mostrou diferenças estatisticamente significantes. Pode-se concluir que, para a análise histológica qualitativa, a fixação deve ser preferivelmente em 48 horas e a desmineralização por solução de Anna Morse. Para a análise histo-morfométrica, a solução descalcificadora não interferiu nos resultados.

Descritores: Histologia; Periodonto; Pesquisa em odontologia.

Corresponding author:

Eduardo José Gaio
Av. Montenegro, 160/701, Bairro Petrópolis
Porto Alegre - RS - Brazil
CEP: 90460160
E-mail: dudagaio@hotmail.com

Received for publication on Apr 25, 2006
Sent for alterations on Oct 09, 2006
Accepted for publication on Dec 18, 2006

Introduction

Animal models are used to investigate events associated with periodontal diseases. Wistar rats are utilized as an experimental model due to their characteristics, which are similar to those of humans, as well as to their similar patterns of periodontal disease development, mainly in the molar region.^{4,6,12}

Studies reporting on periodontal disease in animals are not standardized regarding histological procedures such as fixation time, decalcification and type of decalcification substances used. The fixation time of the histological specimens varies, and pre-established evaluation criteria are not presented, especially concerning the relationship between the fixation method and decalcification. Nishikawa *et al.*¹⁰ (1996) used 10% neutral buffered formalin in 20-day-old rats for 48 hours, not informing which decalcification method was used. Chiu *et al.*² (2001) used 10% formalin and 5% hydrochloric acid for decalcification, not specifying the time periods. Shimizu *et al.*¹⁴ (2002) did not state the fixation period neither which decalcifier was used.

It is important to point out that the fixation time and decalcifying agent used are relevant to the quality of the histological sections and, consequently, to the accuracy of the research results. It is necessary that the sections preparation process be also efficient without loss of quality. Thus, Stevens *et al.*¹⁵ (1996) reported that the fixation process involves a series of chemical events that differ depending on the tissues to be preserved, and have as the main objective to avoid autolysis of the specimens. The use of the decalcifying agent depends on four factors: urgency of the case, mineralization stage, aim of the research and staining technique to be used. All acids somehow affect tissue stability. This is dependent on the solution acidity and the time it will take to decalcify. Thus, the quicker the decalcifications, the greater will be the injury and its effects on H/E.¹⁵ Correa *et al.*³ (2003) reported that the decalcification process causes important molecular and morphological alterations in the tissues such as edema, vacuolation and ruptures not attributable to the pathologic condition.

Decalcifying agents are divided into strong and weak acids and chelators. The choice will depend on

the way the agent affects cell elements. Small specimens can rapidly be demineralized; however, with the purpose of removing the calcium from the center of the specimens, the superficial portion will be in contact with the acid for longer periods of time. This might lead to distortion of the specimens, reducing stability and affecting staining, especially with eosin.¹⁵

Anna Morse solution, composed of 50% formic acid and 20% sodium citrate apparently has shown the best decalcification results. The cell elements are practically not affected, and the staining looks as if the tissues had not been submitted to the decalcification process. Frequent alterations such as the tendency to cellular edema, caused by formic acid, can be minimized by using sodium citrate.⁹

Quantitative and qualitative analyses are used when examining periodontal specimens. Measurement of bone loss and attachment, analysis of sulcular epithelium characteristics, analysis of the junctional epithelium, observation of the presence of inflammatory infiltrate, and observation of the blastic and clastic cells require a histological evaluation of utmost quality, standardized and reproducible.⁵

Considering the need to optimize results with the fixation and decalcification of the specimens, the aim of this study was to evaluate the histological characteristics of the periodontal tissues in Wistar rat maxillae by comparing different fixation times associated with the decalcification of the specimens by means of 5% nitric acid or Anna Morse solution (50% formic acid + 20% sodium citrate).⁹

Material and Methods

Fifteen 60-day-old male Wistar rats were used. They were sacrificed by cervical displacement; their maxillae were removed and fixed in 10% buffered formalin for 24, 48 and 72 hours. Following a middle-line sectioning of the maxilla, half-maxilla was decalcified by 5% nitric acid for 7 days while the other half was decalcified in Anna Morse solution for 35 days. The specimens of around 4 mm² were immersed in single vials with 15 ml of acid and maintained at a room temperature of around 21°C. The acid solution was changed every 24 hours, without any adjunct procedure as vacuum

agitation or heating. The decalcification process was monitored radiographically (Dabi Atlante®, Ribeirão Preto, SP, Brazil) and by means of an explorer. Daily, the specimens were tested with a histologic needle. The decalcified specimens were each submitted to a neutralization process with sodium bicarbonate (buffered solution for 1 hour) and then submitted to a histological processing which comprised four sequential immersions in 95% alcohol (Pró-Cito®, Porto Alegre, RS, Brazil) (80 minutes), one immersion in absolute alcohol (60 minutes), three immersions in xylol (Pró-Cito®, Porto Alegre, RS, Brazil) (80 minutes) and two immersions in liquid paraffin (Biotec®, Porto Alegre, RS, Brazil) at 60°C (120 minutes each), and, at last, embedment in paraffin.

Care was taken during embedment so that the mesial aspect of the first molar faced the block section plan. Three μ thick sections were sliced in a microtome (E. Leitz®, Wetzlar, Hessen, Germany) until reaching the second molar. From each block, three sections were chosen, after each 20 μ , and evaluated by light microscopy. They should meet the following criteria in order to be included in the study: presence of the tooth with radicular and coronary portions, cementum-enamel junction evident in at least one side, buccal or palatal, and identifiable bone crest. The sections were mounted and submitted to two xylol immersions (10 minutes each), dehydration with two absolute alcohol immersions (5 minutes each), hydration (1 minute) and staining by means of Harris Hematoxylin (Pró-Cito®, Porto Alegre, RS, Brazil) (2 minutes) and eosin and fuchsin (1 minute), sequentially followed by quick dehydration by means of three immersions in absolute alcohol (1 minute each) and clearing (“diaphanization”) carried out in two xylol immersions (10 minutes each). Final mounting was carried out with the aid of Entelan (Merck Sharp & Dohme®, São Paulo, São Paulo, Brazil).⁸

Sections were analysed by two trained examiners blinded for fixation time and type of decalcification. Analysis of the sections was performed in an optical microscope (Zeiss®, Jena, Turíngia, Germany) (40 X magnification) with the aim of evaluating sulcular epithelium (intact or not); cementum dislocation

(absent, present at cervical third, present at medium/apical third); dentine demineralization (adequate or inadequate and whether coronal, cervical or apical); bone demineralization (adequate or inadequate).

Measurement of the distance from the cementum-enamel junction to the most coronal portion of the bone crest was carried out by analyzing pictures in a transmitted light microscope (Zeiss®, Jena, Turíngia, Germany), attached to a color video camera model TK – C 620 (JVC®, Oyama, Tochigi, Japan) with the following specifications: standard NTCS signal system, 1/3 inch picture, 479 horizontal lines resolution on TV, 380,000 pixels, 771 (H) and 490 (V). The CCD of the camera digitalized the pictures that were then processed by the Picture Analysis and Processing System Imagelab® (Sausage®, Blaine, Washington, USA), installed in a Unisys® computer (Univac, New York city, NY, USA).

Statistical analysis

Differences in the variables described in the histological evaluation were tested using the Wilcoxon test. ANOVA ($p = 0.05$) was used to analyze differences in distance between the cementum-enamel junction and the bone crest of the experimental groups.

Results

Linear evaluation of the distance between the bone crest and the cementum-enamel junction, measured in pixels, showed that no statistically significant differences were observed ($p > 0.05$) when the buccal and palatal surfaces were compared for both nitric acid and Anna Morse solution, regardless of the experimental times (Table 1).

Table 2 shows the situation of the acellular cementum after decalcification by nitric acid or Anna Morse solution after the different fixation times in 10% buffered formalin. The lowest rates of dislocation occurred after the 48-hour fixation period, especially when performed with Anna Morse solution. Under such conditions, 73.3% of the samples did not present any displacement; however, when nitric acid was used for the same experimental period, only 23.1% did not present dislocation. For all periods, statistically significant differences were

Table 1 - Mean value (standard deviation), in pixels, of the distance between the bone crest and the cementum-enamel junction, in buccal and palatal surfaces, for the different fixation periods and decalcification agents.

Decalcification	Fixation Time			p
	24 hours	48 hours	72 hours	
Nitric acid Buccal	205.99 (34.20)	210.95 (39.33)	176.59 (60.45)	0.496
Anna Morse Buccal	205.21 (54.77)	200.77 (45.78)	186.12 (35.73)	0.794
Nitric acid Palatal	199.69 (38.34)	254.14 (66.50)	248.83 (38.71)	0.202
Anna Morse Palatal	231.39 (46.55)	268.69 (69.26)	298.55 (70.82)	0.280

Table 3 - Dentine demineralization pattern (in percentage) by means of nitric acid and Anna Morse solution after the different fixation times in 10% buffered formalin.

Dentine demineralization pattern	Fixation time					
	24 hours		48 hours		72 hours	
	NA	AM	NA	AM	NA	AM
Adequate	6.7	26.7	38.5	13.3	0	33.3
Coronal inadequate	33.3	20	23.1	40	6.7	6.7
Coronal/cervical Inadequate	20	46.7	7.7	13.3	40	6.7
Coronal/cervical/apical Inadequate	40	6.7	7.7	33.3	53.3	53.3

NA: Nitric acid; AM: Anna Morse solution.

observed between nitric acid and Anna Morse solution.

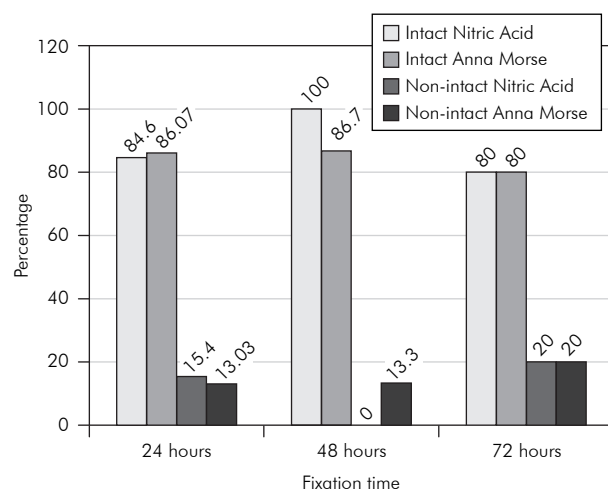
Table 3 shows the dentine demineralization pattern, in percentage values, using nitric acid or Anna Morse solution after the different fixation times in 10% buffered formalin. The results showed a variety of situations in the different stages of the experiment, for the different decalcifiers, which did not follow a pattern. Forty eight hours was found to be the best time for nitric acid, where 38.5% of the samples were considered adequate, whereas for Anna Morse solution the fixation time did not present an established pattern.

Descriptive microscopic evaluation of the histological sections showed more uniformity in staining and better differentiation between the epithelial and

Table 2 - Frequency distribution (%) of cementum dislocation.

Cementum dislocation	Fixation time					
	24 hours		48 hours		72 hours	
	NA	AM	NA	AM	NA	AM
Absent	0	53.3	23.1	73.3	6.7	66.7
Cervical Third	40	13.3	38.5	6.7	33.3	13.3
Apical/Medium third	60	33.3	38.5	20	60	20
p	0.006		0.015		0.014	

NA: Nitric acid; AM: Anna Morse solution.

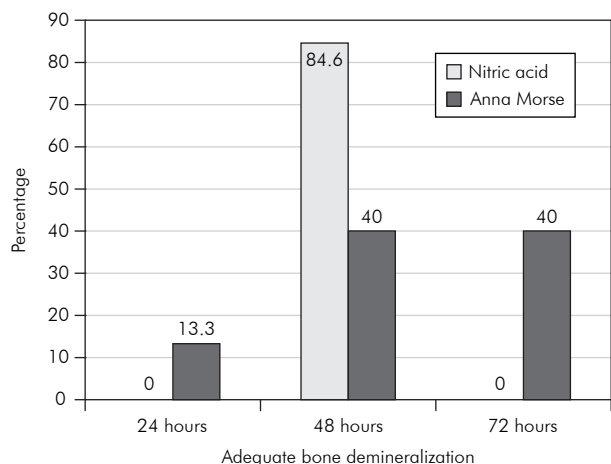


Graph 1 - Condition of the sulcular epithelium (intact or not) after decalcification with nitric acid or Anna Morse solution after the different fixation times in 10% formalin.

connective tissues when a 48-hour fixation period and Anna Morse solution decalcification were used. After the 24 hours and 72 hours periods, the tissues were less preserved and affinity to eosin and hematoxylin was diminished for both nitric acid and Anna Morse solution.

When the histological processing patterns were analyzed, it was noticeable that the best results obtained regarding the integrity of the sulcular epithelium were found after the 48-hour fixation period (Graph 1).

Analysis of the jaw bone decalcification pattern revealed that the best decalcification conditions were found after 48 hours of fixation. Nitric acid, in that period of time, showed the best demineralization results (Graph 2).



Graph 2 - Bone demineralization pattern after decalcification with nitric acid or Anna Morse solution after the different fixation times in 10% formalin.

Discussion

The understanding of the pathogenesis of periodontal diseases is based on microscopic studies in animal models. The aim of this study was to standardize histotechnical procedures in order to minimize possible bias in this experimental phase. Our discussion is thus focused on microscopic quality observation of the tissues involved in periodontal diseases.

It is important for histological analysis that the sections be obtained with the least possible alterations during the entire process. However, medullary and trabecular bone, as well as the tooth hard tissues (dentine and enamel), have different mineralization patterns. Often, epithelial and connective tissues are altered by long exposures to acids leading to degeneration. Frequently, while trying to obtain a good histological result for the calcified tissues, damage is done to the soft tissues. On the other hand, when the soft tissue is adequately preserved and the specimen is not completely decalcified, it is difficult to fulfill the requirements for the simultaneous analysis of mineralized and non-mineralized tissues. Fixation and decalcification techniques are routine practices in laboratories. However, in general, this routine is not questioned with regards to modifications leading to a better quality of the sections.

Studies performed in animals involving hard and soft tissues are frequently published^{1,11,13} without de-

tails concerning the histological processing, making this kind of discussion difficult in the literature.

It is known that the aim of fixation is to preserve tissues from autolysis and bacterial attack, and so that shape and volume remain unaltered.⁷ Among the main factors involving tissue fixation are temperature, penetration and duration. The temperature used during fixation in a histochemical process is the traditional room temperature; in warmer locations this process occurs more rapidly. The penetration phenomenon occurs relatively slowly and depends on the kind of tissue and size of specimens. Fixation time is of utmost importance in the histological process. Long periods of exposure of the specimens to the fixation agent can cause significant damage, such as oxidation, degeneration, tissue hardening and shrinking.⁷

The present study was carried out in a location where the average room temperature was about 21°C and a 24-hour routine fixation time was observed. The material comprised soft and hard tissues of about 120 mm³. In this study, three fixation periods were evaluated: 24, 48 and 72 hours. The period where best results were obtained, both for soft and mineralized tissues, was 48 hours. During this period, both epithelial and connective tissues presented adequate staining.

Decalcifying agents, classified in strong or weak, are influenced by a series of factors. Among the most important ones are chemical substances concentration, temperature and agitation.

Strong acids – commonly used in diagnostic urgencies – have a high free hydrogen ions concentration. They provoke significant alterations in the soft tissues, especially at the cellular level. Moreover, important damages can be observed depending on the quality of the histochemical technique employed. The decalcification process can be accelerated by increasing the medium temperature and agitation. It is important to point out that all decalcification processes cause some sort of damage to the specimens.^{3,7}

Conclusion

In the present study, we tried to evaluate the histological outcomes of the different fixation periods

in 10% formalin using two decalcifying solutions: One strong, with nitric acid, and the other weak, Anna Morse solution. Regarding the distance between the cementum-enamel junction and the bone crest, it was possible to observe that both acids kept the mineralized structures without significant altera-

tions. Histometric analysis revealed that the fixation time and decalcifying solution used did not alter the results. However, qualitative histological analysis showed that fixation time should preferably be 48 hours, and demineralization should be obtained with Anna Morse solution.

References

1. Chiu GN, Bally MB, Mayer LD. Selective protein interactions with phosphatidylserine containing liposomes alter the steric stabilization properties of poly (ethylene glycol). *Biochim Biophys Acta*. 2001;1510(1-2):56-69.
2. Chiu HC, Fu E, Chiang CY, Liu D. Does nifedipine aggravate cyclosporin-induced gingival overgrowth? An experiment in rats. *J Periodontol*. 2001;72(4):532-7.
3. Correa CR, Oliveira MG, Carrard V, Lauxen IS, Oliveira OR, Barbieri BP *et al*. Avaliação das alterações microscópicas em material submetido a agentes descalcificadores. *In: XV Salão de Iniciação Científica*; 2003. Porto Alegre: ESEF; 2003. p. 554. Res: 030.
4. Fitzgerald RJ, Jordan HV, Stanley HR. Experimental caries and gingival pathologic changes in the gnotobiotic rat. *J Dent Res*. 1960;39:923-35.
5. Gaio EJ, Fernandes MI, Oppermann RV, Rados PV, Rosing CK. Morphometric and histometric bone height analysis in induced periodontitis. *In: The 21st Annual Meeting of the Brazilian Society for Oral Research* (8-12 September 2003). [cited 2007 Feb 06]. Available from: http://iadr.confex.com/iadr/brazil04/preliminaryprogram/abstract_55977.htm.
6. Heijl L, Wennström J, Lindhe J, Socransky SS. Periodontal disease in gnotobiotic rats. *J Periodontol Res*. 1980;15:405-19.
7. Hopwood D. Fixation and fixatives. *In: Bancroft JD, Stevens A, Turner DR. Theory and practice of histological techniques*. 4th ed. London: Churchill Livingstone, 1996. p. 23-45.
8. Junqueira LCU, Junqueira LMMS. *Técnicas básicas de citologia e histologia*. São Paulo: Nobel; 1985.
9. Morse A. Formic acid-sodium citrate decalcification and butyl alcohol dehydration of teeth and bones for sectioning in paraffin. *J Dent Res*. 1945;24:143-53.
10. Nishikawa S, Nagata T, Morisaki I, Oka T, Ishida H. Pathogenesis of drug-induced gingival overgrowth. A review of studies in the rat model. *J Periodontol*. 1996;67(5):463-71.
11. Nociti Jr FH, Nogueira-Filho GR, Primo MT, Machado MA, Tramontina VA, Barros SP *et al*. The influence of nicotine on the bone loss rate in ligature-induced periodontitis. A histometric study in rats. *J Periodontol*. 2000;71(9):1460-4.
12. Page RC, Schroeder HE. *Periodontitis in man and other animals. A comparative review*. Basel: Karger; 1982.
13. Rovin S, Costich ER, Gordon HA. The influence of bacteria and irritation in the initiation of periodontal disease in germ-free and conventional rats. *J Periodontol Res*. 1966;1(3):193-204.
14. Shimizu Y, Kataoka M, Seto H, Kido J, Nagata T. Nifedipine induces gingival epithelial hyperplasia in rats through inhibition of apoptosis. *J Periodontol*. 2002;73(8):861-7.
15. Stevens A, Lowe J, Bancroft JD. *Bone*. *In: Bancroft JD, Stevens A. Theory and practice of histological techniques*. 4th ed. New York: Churchill Livingstone; 1996. p. 309-39.