

Cutaneous cryptococcosis due to *Cryptococcus neoformans* var. *gattii*

Luiz Carlos Severo, Isabele Berta e Zardo & Alberto Thomaz Londero

Laboratório de Microbiologia Clínica, Instituto Especializado em Pesquisa e Diagnóstico (IPD), Santa Casa, Porto Alegre, RS, Brasil

Summary A case of cutaneous cryptococcosis due to *Cryptococcus neoformans* var. *gattii* in an immunocompetent host is presented. In addition a review of the literature on this subject was carried out and a brief comment made on occurrence of the variety *gattii* in Brazil.

Key words Cryptococcosis, Cutaneous infection, *Cryptococcus neoformans* var. *gattii*

Criptococosis cutánea por *Cryptococcus neoformans* var. *gattii*

Resumen Se presenta un caso de criptococosis cutánea por *Cryptococcus neoformans* var. *gattii* en un paciente inmunocompetente junto con una revisión de lo publicado sobre este tema. Se hace, también, un breve comentario sobre la incidencia de la variedad *gattii* de *C. neoformans* en Brasil.

Palabras clave Criptococosis, Infección cutánea, *Cryptococcus neoformans* var. *gattii*

Cutaneous lesions may occur in two clinical forms of cryptococcosis: disseminated and cutaneous form. In the disseminated form the lesions result from hematogenous dissemination of the fungus; in the cutaneous form, presumably, caused by transcutaneous introduction of the fungus. Both these types of cutaneous lesions most often occur in infections caused by *Cryptococcus neoformans* var. *neoformans*, that usually affect an immunocompromised host [1-3].

The rarity of skin lesions caused by *C. neoformans* var. *gattii* justify this report of a case with a brief comment on occurrence of the variety *gattii* in Brazil.

CASE REPORT

After one month history of cough with mucoid sputum, weight loss and fatigue, the patient, a 37-year-old, Caucasian man, presented many cutaneous lesions on his face. Later on, because he complained of headache, photophobia, double vision and vomiting, he was admitted to our hospital.

Physical examination revealed a lucid, oriented, coherent patient. He presented stiff neck and positive Kernig's, Brudzinski's, and Lasègue's signs. Many erythematous, sessile, dome-shaped nodules, covered with crusts, distributed on the cheeks and chins were observed (Figure 1). Ophthalmoscopy revealed bilateral papilledema. Hemogram and biochemistry blood profile were within normal values. Chest X-ray shows a mass in the left upper lobe. No abnormalities were disclosed by a brain TC scan. Lumbar puncture yielded a clear fluid with hydrostatic pressure of 700 mm and at examination presented the following values: protein 120 mg/dl, glucose 57 mg/dl and leukocytes 75/mm³, 80% of which lymphocytes. Mycological examination detected encapsulated yeast like organisms in the CSF, sputum and in cut sections of the skin lesions; these organisms were isolated in culture and identified as *C. neoformans* var. *gattii* serotype B. Cryptococcal antigen testing of CSF and serum was positive at dilution of 1:2048 in both specimens.

The patient was treated with amphotericin B and flucytosine. At the fourth month of therapy remission of skin lesions was obtained (Figure 2), however a persistent headache and cough remained. A new chest X-ray was performed showing nodules and micronodules in the right upper lobe and a subpleural lesion in the left upper lobe. Sputum examination disclosed acid-fast bacilli. For this reason the patient was treated with isoniazid, rifampicin and ethambutol and antifungal therapy was discontinued. Eight months later the patient was readmitted to the hospital presenting a relapse of pulmonary cryptococcosis. Then he was submitted to a lobectomy for the resection of a lung mass in the left upper lobe and received ketoconazole. Histologic examination of the excised lesion revealed a granulomatous inflammatory reaction with fibrosis and necrosis; special stains revealed a large number of encapsulated budding yeast identified as *C. neoformans*. After four months of antifungal therapy, cryptococcus antigen tests in the serum and cerebrospinal fluid were negative.

Dirección para correspondencia:

Dr. Luiz C. Severo
Laboratório de Microbiologia Clínica
IPD - Santa Casa, Annes Dias, 285
Porto Alegre 90020-090 RS Brazil
Fax: +55 51 3214 8435
E-mail severo@santacasa.tche.br

Aceptado para publicación el 8 de Octubre de 2001

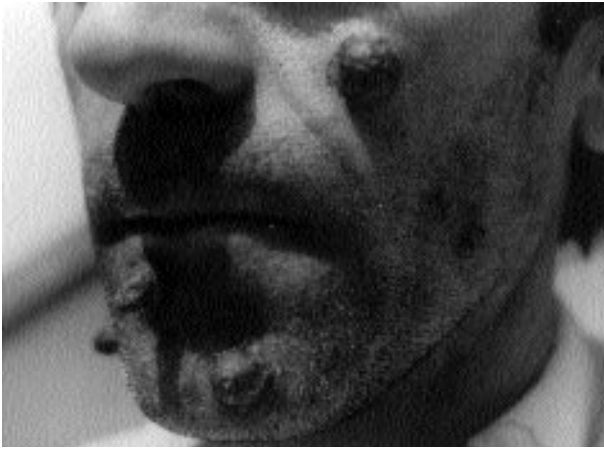

Figure 1. Cutaneous lesions on the face due to *C. neoformans* var. *gattii*.




Figure 2. At four months of therapy, showing the remission of the skin lesions.

Fifteen years (1984-1999) later the patient was seen free of symptoms.

DISCUSSION

To our knowledge only two reports on cutaneous lesions caused by *C. neoformans* var. *gattii* have been published. One of them in a patient with the disseminated form of cryptococcosis [4]; another one in a patient with the cutaneous (primary) form of the disease [1]. Both patients lived in Australia, where *C. neoformans* var. *gattii* is an important pathogen [3].

Our case in a Brazilian patient presents some similarities with the Australian case of Riddell and Entwisle [4]: the localization of the skin lesions and the association with cerebral and pulmonary manifestations of the disease.

In Brazil, *C. neoformans* var. *gattii* is endemic in the Northeastern Brazilian region, where it is the agent of 71% of the cases of cryptococcosis [5]. In the Southeastern and Southern Brazilian regions, respectively, it was identified in 36% of the serotyped isolates [6] and was the agent of 13% of the cases of the disease [7].

Special thanks are due to Dr. John E. Bennett (National Institute of Allergy and Infectious Diseases, Bethesda, USA) for identifying the serotype and to Dr. Leo Kaufman (Center for Disease Control and Prevention, CDC, Atlanta, USA) for performing the cryptococcal antigen tests.

References

1. Hamann ID, Gillespie RJ, Ferguson JK. Primary cryptococcal cellulitis caused by *Cryptococcus neoformans* var. *gattii* in an immunocompetent host. *Australian J Dermatol* 1997; 38: 29-32.
2. Mitchell TG, Perfect JR. Cryptococcosis in the era of AIDS-100 years after the discovery of *Cryptococcus neoformans*. *Clin Microbiol Rev* 1995; 8: 515-548.
3. Speed B, Dunt D. Clinical and host differences between infections with the two varieties of *Cryptococcus neoformans*. *Clin Infect Dis* 1995; 21: 28-34.
4. Ridell RJ, Entwisle BR. Cryptococcal granulomata of the skin with pulmonary and cerebral cryptococcosis. *Australian J Dermatol* 1969; 10: 100-108.
5. Cavalcanti MAS. Criptococose e seu agente etiológico no meio norte, Estados do Piauí e Maranhão, Brasil. Thesis. Rio de Janeiro, Instituto Oswaldo Cruz, 1997.
6. Lacaz CS, Rodrigues NC. Sorotipagem do *Cryptococcus neoformans*. *Rev Bras Med* 1983; 40: 297-300.
7. Severo LC. Criptococose: duas doenças? Thesis. Porto Alegre, Fundação Faculdade Federal de Ciências Médicas, 1993.