

## BOTRYOMYCOSIS MIMICKING ACUTE ABDOMEN:

## A CASE REPORT

*BOTRIOMICOSE SIMULANDO UM ABDOME AGUDO.**RELATO DE CASO*

Tomaz de Jesus Maria Grezzana Filho<sup>1</sup>, Lisiane Treis<sup>1</sup>,  
Samanta Daiana De Rossi<sup>1</sup>, Emanuel Burck dos Santos<sup>1</sup>,  
Karla Pêgas<sup>2</sup>, Cleber Dario Pinto Kruehl<sup>1</sup>

**ABSTRACT**

Botryomycosis is a rare chronic granulomatous bacterial infection affecting mostly the skin and subcutaneous tissues. The nomenclature is a misnomer as the disease is caused by bacteria, not by fungus. This uncommon infection sometimes mimics neoplasia and actinomycosis. *Staphylococcus aureus* is the most common agent in botryomycosis, followed by *Pseudomonas sp.* strains. We report an unusual case of invasive umbilical botriomycosis mimicking an acute abdomen. The patient recovered fully after being treated with surgery and antibiotics. This is the first report of umbilical botryomycosis, which usually affects the skin.

**Keywords:** *Botryomycosis; splendore-hoepli phenomenon; granulomatous; staphylococcus aureus; abdomen acute*

**RESUMO**

Botriomicose é uma infecção bacteriana granulomatosa crônica rara que afeta principalmente a pele e tecidos subcutâneos. A nomenclatura é imprópria, uma vez que a infecção é causada por bactérias e não por fungos. Esta infecção incomum simula por vezes uma neoplasia ou actinomicose. O *Staphylococcus aureus* é o agente mais comum na botriomicose, seguido por cepas de *Pseudomonas sp.* Relatamos um caso incomum de botriomicose umbilical invasiva simulando um abdome agudo. A paciente recuperou-se totalmente após ser tratada com cirurgia e antibióticos. Essa doença é mais frequente na pele, e este é o primeiro relato de botriomicose umbilical.

**Palavras-chave:** *Botriomicose; fenômeno de splendore-hoepli; granulomatosa; staphylococcus aureus; abdome agudo*

Revista HCPA. 2013;33(2):161-165

1 Department of Surgery, Hospital de Clínicas de Porto Alegre, Universidade Federal do Rio Grande do Sul. Porto Alegre, RS, Brazil.

2 Department of Pathology, Hospital de Clínicas de Porto Alegre, Universidade Federal do Rio Grande do Sul. Porto Alegre, RS, Brazil.

**Contato:**

Tomaz Grezzana Filho,  
tomaz.grezzana@gmail.com  
Porto Alegre, RS, Brazil.

“Botryomycosis” comes from Greek words “botrys”, meaning grape bunch, which refers to the microscopic grape-like appearance of granules, and “mycosis”, as the disease was originally believed to be a fungal infection (1). The

most common etiologic agents are the *Staphylococcus aureus*, found in 40% of the cases, and *Pseudomonas sp.*, found in 20% of them. *Escherichia coli*, *Proteus vulgaris*, *Bacillus spp.*, *Actinobacillus*, *Serratia*,

*Peptostreptococcus*, *Propionibacterium acnes*, *Staphylococci coagulase negative*, *Streptococci*, and *Micrococci* are isolated less frequently (1). Skin lesions may be single, multiple or pleomorphic, and may resemble cysts, abscesses, fistulas, plates or ulcers (2,3). Most of the infected patients are immunocompromised (4-6). There is also an intertegumentar form which affects muscles and bones and is related to former trauma, surgery or foreign bodies. A visceral form has been described, affecting mainly the lungs, but there are reports of the tongue, orbits, liver, spleen, kidneys, and brain being affected. Treatment is often a combination of antibiotic therapy and resection of the affected areas (7).

### CASE REPORT

A 35-year-old obese and hypertense woman was admitted to our hospital with continuous periumbilical pain and vomiting. A clinical examination revealed a bulge in the umbilicus and local hyperemia. A plain film showed air in the subcutaneous tissue

and the laboratory tests showed leukocytosis. There were no past records of herniation, trauma or discharge from the umbilicus. The patient was presumptively diagnosed with strangulated umbilical hernia with inflammatory signs and was submitted to surgery. Surgical findings showed a purulent discharge from the umbilicus after pressure and a hard inflammatory mass affecting the subcutaneous tissues, umbilicus, and adjacent aponeurosis, mimicking a tumor. A biopsy of the frozen sections showed no signs of neoplasia. We suspected a patent urachus or omphalomesenteric duct, and the mass was resected in block. The gross specimen revealed a central cavitation with a 4 cm diameter (figure 1). The patient was administered antibiotics according to the Gram stain. The recovery was uneventful and she left the hospital after four days. Culture of the abscess was positive to *Staphylococcus aureus*. Histologically, the specimen was compatible with the Splendore-Hoeppli phenomenon (figure 2). Based on these findings and on the clinical picture, we confirmed the diagnosis of botryomycosis.

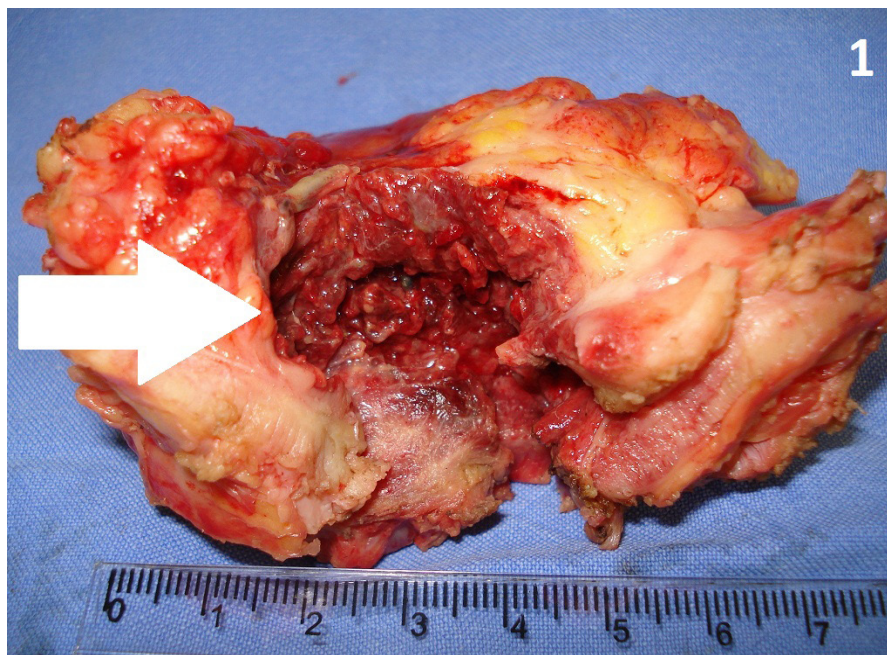


Figure 1: Specimen resected including umbilicus, subcutaneous and aponeurosis. A central red cavity with rugous surface resembling granules revealed foci of Botryomycosis (white arrow)

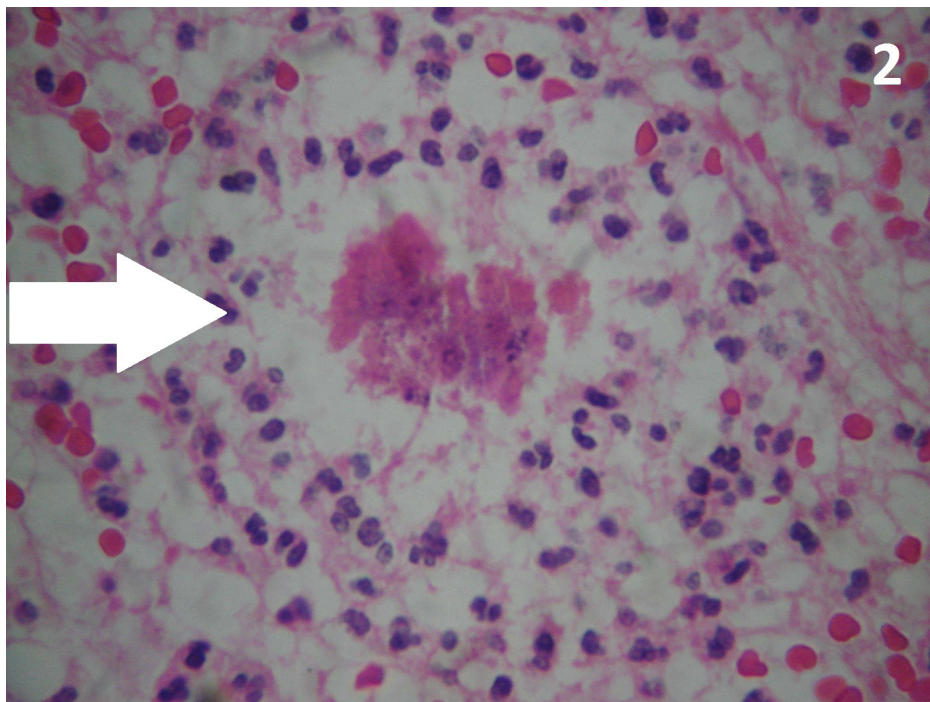


Figure 2: A colony of bacteria surrounded by an eosinophilic matrix characteristic of Splendore-Hoeppli phenomenon (white arrow). HE 400x.

Botryomycosis is a rare bacterial infection in which bacterial masses form granules. These granules may resemble the sulphur granules of actinomycosis, which are also colonies of microorganisms embedded in a matrix. It is still unknown why infections caused by common pathogens such as *Staphylococcus aureus* or *Pseudomonas aeruginosa* may occasionally lead to the formation of mycetoma-like structures, which behave clinically like chronic fungal infections (8). It probably results from a combination of factors, including a trigger event, number of inoculated organisms, virulence, and host immunity(9).

There is a number of risk factors associated with the disease: skin trauma, complicated postoperative period, diabetes, cystic fibrosis, asthma, high doses of corticotherapy, alcoholism, AIDS, glomerulonephritis, Job syndrome, and follicular mucinosis (1). Some differential diagnoses may be considered, such as mycetoma,

actinomycosis, atypical mycobacterial infection, cutaneous leishmaniasis, herpes zoster, simple abscess, neoplasia, and Kaposi sarcoma (10). In many patients, there were no apparent predisposing conditions or diseases (11).

The cutaneous form resembles multiple abscesses and infected epidermal cysts. Sinuses, fistulas, and multiple ulcerated nodules may be found. Frequently exposed skin areas, such as hands, feet, and head, are commonly affected sites. However, botryomycosis may develop in any part of the skin. Similarly to our case, some authors reported that other tissues may be affected secondarily by contiguous extension.

In this report, the clinical picture resembled a strangulated umbilical hernia. Due to the intense pain, obesity, and skin hyperemia, physical examination was difficult. The subcutaneous air suggested the presence of small bowel and surgical exploration was mandatory. During surgery, we found a mass surrounding the umbilicus. We

suspected a patent omphalomesenteric duct or urachus. In some cases there is malignant degeneration if these ducts are patent. However, the patient had no history of discharge from the umbilicus or urinary tract infections, which are common symptoms in cases of persistent urachus and omphalomesenteric ducts. Moreover, we observed no communication between the inflammatory mass and abdominal organs. After resection and specimen analysis, we noticed a red, deep, ridged cavity on the site where the infection had developed.

A definitive diagnosis may be difficult to make, but it is strongly suggested by the identification of bacteria in granules, culture of the ulcers when the clinical picture is consistent with botryomycosis, and anatomopathological examinations (12).

Botryomycosis is histopathologically characterized by a necrotic center surrounded by chronically inflamed tissue, with the presence of histiocytes, epithelioid cells, multinucleated giant cells and fibrosis. Bollinger granules, which are clusters of bacteria surrounded by an eosinophilic matrix with club-like projections, are an important sign. The Splendore-Hoeppli phenomenon describes eosinophilic deposits that surround certain fungi, parasites, and bacterial colonies, and is thought to represent antigen-antibody complexes. The

immunoglobulin component of the eosinophilic matrix presumably represents a localized attempt at containment on the part of the host. Whether this degree of immunological responsiveness is ultimately helpful or harmful to the host remains unclear (13).

There are reports of the Splendore-Hoeppli phenomenon being associated with a wide range of fungal and parasitic infections, especially by helminthes and schistosome eggs, and it is particularly striking in actinomycosis, mycetoma, and botryomycosis (13). In our patient, it was associated with botryomycosis.

In the superficial cutaneous form of botryomycosis, treatment usually involves prolonged intravenous antibiotic therapy and sometimes drainage and resection. Surgical resection is the first choice when the infection extends to deep tissues, in the visceral form or in immunocompromised individuals (14). The prognosis of cutaneous botryomycosis is generally good and is much better than that of the visceral type (11).

As far as we know, no other case of umbilical botryomycosis has been reported. Botryomycosis is a rare infection with an unclear pathogenesis. The infection usually affects the skin, but extension to adjacent tissues is possible and resection is a choice in antibiotics-resistant infections.

## REFERENCES

- Marcano MJ, Landaeta JM, Andrade RE, Brito A, Cerrada O. Botriomicosis: infección bacteriana granulomatosa poco frecuente: revisión de la literatura. *Rev Soc Ven Microbiol.* 2003;23:65-9.
- Fernandes NC, Maceira JP, Knackfuss IG, Fernandes N. Botriomicose cutânea. *An Bras Dermatol.* 2002;77:65-70.
- Mehregan DA, Su WP, Anhalt JP. Cutaneous botryomycosis. *J Am Acad Dermatol.* 1991;24:393-6.
- Conti-Diaz IA, Almeida EA, Rondan M, Algorta G, Otero M. Cutaneous botryomycosis. Report of the two first Uruguayan cases. *Rev Inst Med Trop.* 1996;38:375-8.
- Yencha MW, Walker CW, Karakla DW, Simko EJ. Cutaneous botryomycosis of the cervicofacial region. *Head Neck.* 2001;23:594-8.
- Katkar V, Mohammad F, Raut S, Amir R. Red grain botryomycosis due to *Staphylococcus aureus*: a novel case report. *Indian J Med Microbiol.* 2009;27:370-2.
- Bersoff-Matcha SJ, Roper CC, Liapi H, Little JR. Primary pulmonary botryomycosis: case report and review. *Clin Infect Dis.* 1998;26:620-4.
- Follows GA, Mathew J, Lucas S, Black MJ, Goodship TH. Cutaneous botryomycosis in a patient with lupus nephritis. *Nephrol Dial Transplant.* 1998;13:3200-1.
- Bonifaz A, Carrasco E. Botryomycosis. *Int J Dermatol.* 1996;35:381-8.
- de Vries HJ, van Noesel CJ, Hoekzema R, Hulsebosch HJ. Botryomycosis in an HIV-positive

- subject. J Eur Acad Dermatol Venereol. 2003;17:87-90.
11. Chu WO, Fruauff A, Rivas R, Donovan V. Cutaneous botryomycosis: MR findings. Am J Roentgenol. 1994;163:647-8.
12. Neafie RC, Marty AM. Unusual infections in humans. Clin Microbiol Rev. 1993;6:34-56.
13. Schlossberg D, Pandey M, Reddy R. The Splendore-Hoeppli phenomenon in hepatic botryomycosis. J Clin Pathol. 1998;51:399-400.
14. Ellerbe DM, Parsons DS, Cook PR. Botryomycosis: improved therapy for a difficult infection. Int J Pediatr Otorhinolaryngol. 1997;41:363-9.

*Recebido: 03/11/2012*

*Aceito: 03/04/2013*