

GORLIN-GOLTZ SYNDROME: CASE REPORT AND REVIEW OF LITERATURE

Adrienne Rahde Bischoff¹, Yina Mercedes Timana Delgado¹,
Fabiano de Oliveira Poswar³, Eduardo Tarasconi Ruschel²,
Eduardo Kohls Toralles², Gabriel Lona Curubeto Lona de Miranda²,
Mario Francisco Silveira Rita¹

ABSTRACT

Description of a case report of Gorlin-Goltz Syndrome diagnosed in a male newborn who presented increased head circumference and bifid ribs. Mother and grandmother presented typical physical findings of the syndrome, including palmar pits, odontogenic cysts, and history of multiple skin cancer resections. The diagnosis was based on clinical findings of three relatives. A literature review is also presented.

Keywords: Gorlin-Goltz Syndrome; bifid rib; skin cancer

The Gorlin-Goltz Syndrome or Nevoid Basal Cell Carcinoma Syndrome is a dominant autosomal genetic disorder that predisposes the emergence of skin neoplasia as well as other developmental abnormalities¹.

Caused by a mutation in the PTCH1 gene, its presentation is variable, although it has been classically described as the triad: basal cell carcinoma, keratocystic odontogenic tumors, and bifid ribs¹. The diagnosis is clinical, if the patient presents two major criteria or one major criterion with two minor criteria; genetic testing is only necessary if those are absent².

Here we present a case report of a newborn evaluated at this hospital (HCPA) with suggestive findings of this syndrome, followed by a brief literature review.

Case report:

Twenty-year-old woman, 39 weeks and 6 days pregnant, spontaneously came to the hospital due to high blood pressure. She had no comorbidities, and her prenatal course had been uneventful. An obstetric morphologic ultrasound in the first trimester presented nuchal translucency of 5 mm. A cesarean was performed (fail to induce labor), with intact membranes and normal amniotic fluid. Male newborn, birth weight 3,685 g, Apgar 5/9, Capurro of 39 weeks and 5 days, appropriate for gestational age.

The first physical examination of the newborn demonstrated a 38 cm head circumference (percentile>98), two bone prominences in the sternum and no further findings, including a normal neurologic exam. A normal cerebral ultrasound was performed. A chest x-ray showed structural alterations in the sternum and in the ribs (specially a right bifid rib – Figure 1) without cardiopulmonary findings. Mother and maternal grandmother were examined, presenting head circumference of 60.5 and 58.5 cm respectively (both >p98) and palmar pits in both hands. Family history showed that the mother had a delayed neurodevelopment during childhood and is currently

Clin Biomed Res. 2014;34(3):313-317

1 Department of Pediatrics, Hospital de Clínicas de Porto Alegre (HCPA). Porto Alegre, RS, Brazil.

2 Medical School, Universidade Federal do Rio Grande do Sul (UFRGS). Porto Alegre, RS, Brazil.

3 Department of Genetics, HCPA, Porto Alegre, RS, Brazil.

Corresponding author:

Adrienne Rahde Bischoff
E-mail: arahdebischoff@gmail.com
Porto Alegre, RS, Brazil.

being treated for odontogenic cysts elsewhere; the grandmother has had more than one resected skin cancer. Based on physical findings of the newborn, mother and grandmother, the main diagnostic hypothesis was Gorlin-Goltz Syndrome. The family was properly informed (they were unaware of any

genetic disease in their family).

The patient had an excellent postnatal evolution and had hospital discharge with his mother a few days after birth, with scheduled ambulatory return in the genetics department of the same hospital.

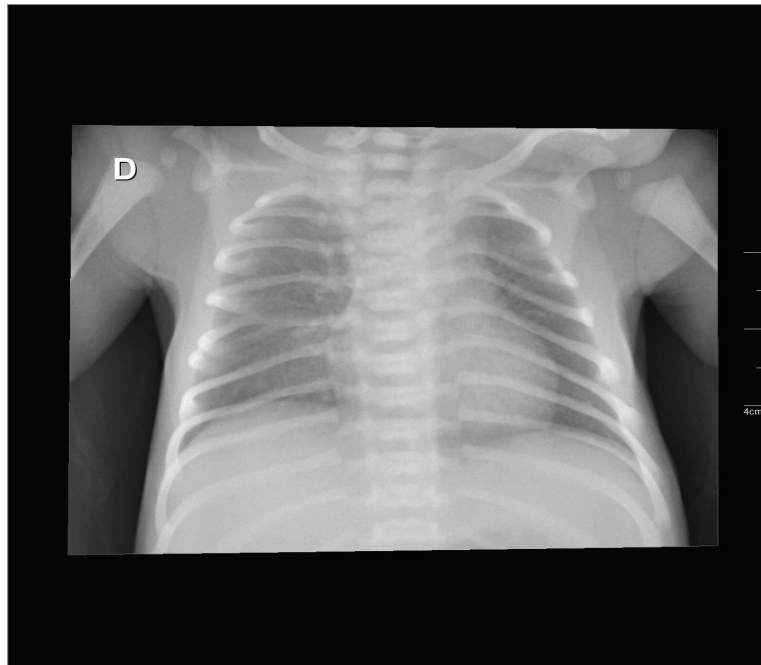


Figure 1: Thorax radiography - Bifid rib

DISCUSSION

The Gorlin-Goltz Syndrome is an inherited, autosomal dominant, completely penetrant disorder with variable expressivity³. Isolated cases are frequent, representing up to 60% of the affected people, and its estimated prevalence varies among populations, between 1:55,600 and 1:256,000, with no gender difference^{4,5}.

Most cases are caused by heterozygous mutations in the PTCH1 membrane receptor gene⁵. PTCH1 is a component of the hedgehog (Hh) signaling pathway, working as a receptor for the ligand sonic hedgehog (SHH)⁶. In the absence of the ligand, PTCH1 inhibits the expression of smoothened (SMO) and its signaling cascade, including transcription factors of the family of glioma-associated oncogenes (GLI). This way,

loss-of-function mutations in PTCH1 result in abnormal activation of Hh signaling pathway, which is involved in many physiologic processes, such as axial, facial, and appendicular skeleton formation, lip fusion, and the hair follicle cycle⁷. Moreover, the excessive activation of the Hh signaling pathway is associated with different types of cancer, especially basal cell carcinoma, and mutations in this pathway were identified in more than 90% of sporadic cases of this cancer. Mutations in PTCH2, which encodes a close homolog of the PTCH1 receptor, and SUFU, which encodes a negative regulator of GLI transcription factors, have been described in a few families with Gorlin syndrome without mutations in PTCH1⁸. The clinical diagnosis is made in the presence of two major criteria or one major associated with two minor (table 1)⁹. This case presented bilateral structural alterations in the

ribs, including a bifid rib, and a first-degree relative presenting the syndrome (as two major criteria) and macrocephaly (as one minor).

Basal cell carcinoma is the main component of the syndrome, occurring between puberty and 35 years of age^{5,9} in any part of the body, especially in those exposed to sunlight. Other cutaneous manifestations include sebaceous cysts and palmar and plantar pits, that develop in the second decade and increase in number with age^{9,10}.

Odontogenic tumors are also frequent and may be the first manifestation of the syndrome, occurring in the first decade and in up to 75% of the patients^{9,10}. Multiple radiolucent lesions (uni- or multiloculated) in the mandible or maxilla are frequent in this individuals¹⁰. Ectopic calcifications of the central nervous system may occur. Guenova et al reported a case of incidental finding of lamellar calcification of the falx cerebri leading to the diagnosis of Gorlin-Goltz Syndrome¹¹.

Skeletal abnormalities are present in up to 70% of patients, and bifid, fused or flattened ribs are

the most common of them, as seen in this patient. Up to 31% present vertebrae alterations such as spina bifida occulta, kyphoscoliosis, fusion defects, hemivertebra, and Sprengel deformity (congenital elevation of scapula)^{2,9}. High and wide forehead, frontal bossing, and increased head circumference (as in this case) may also occur. Enlarged nasal bone is common and may be associated with ocular hypertelorism⁹.

Hypoplastic maxilla or hyperplasia of mandible (with variable prognathism) may also be present. Other less common abnormalities include ogival palate, cleft lip, impactation and agenesis of teeth, syndactyly and polydactyly, mesenteric cysts, mesenteric, mammary, ovarian and cardiac fibroma^{2,9}.

Medulloblastoma presentation (malignant posterior fossa tumor) is uncommon, however it is important due to its potential risk of life. This tumor is present in up to 10% of cases, and diagnosis usually occurs by 5 years of age¹⁰.

Table 1: Major and minor criteria for Gorlin-Goltz Syndrome

Major Criteria	Minor Criteria
Three or more basal cell carcinoma or one before 20 years old	Macrocephaly (adjusted for height)
Histology confirmed odontogenic keratocysts	Congenital malformations: cleft palate or lip, frontal bossing, hypertelorism, coarse <i>facies</i>
Three or more palm depressions in the hands or feet	Skeletal alterations: Sprengel deformity, deformed chest, hemivertebra, fused or enlarged vertebrae, hand or feet malformations, syndactyly, bone cysts in the hands
Bilamellar calcification of the <i>falx cerebri</i>	<i>Sella turcica</i> pontification
Bifid, fused or flattened ribs	Mesenteric, mammary, ovarian or cardiac fibroma
First-degree relative with the syndrome	Medulloblastoma

Management of patients includes surveillance of the complications related to the syndrome and specific treatment of postnatal tumors and odontogenic keratocysts. Treatment of most other abnormalities consists in cosmetic interventions.

Frequent dermatologist consultations are recommended, especially during puberty. A magnetic resonance of the skull should be performed every year until 8 years of age to exclude medulloblastoma, as well as panoramic x-ray of mandible annually after this age. An echocardiography is recommended periodically to exclude cardiac fibroma.

Only a small fraction of the basal cell carcinoma (BCC) tumors become invasive, rarely leading to death by cerebral or pulmonary dissemination. The affected patients should avoid ultraviolet light exposure and therapeutic ionizing radiation, if possible¹².

BCC should be early treated clinically or surgically. Topical application of 5% 5-fluorouracil (0,1% tretinoin added or not) could be performed in superficial lesions¹³. A surgical approach to the growing or invasive lesions include excision, curettage or electrical dissection.

Vismodegib, an agent targeting the sonic hedgehog pathway, offers a new approach for patients with metastatic disease or no longer amenable to local therapy, slowing the rate of BCC development and reducing tumor burden in NBCCS¹⁴. Although these findings are promising,

side effects, such as loss of taste, muscle cramps, hair loss, and weight loss limited the use of vismodegib. More studies are required in order to determine whether vismodegib has the potential to truly cure individual BCCs in NBCCS, as well as to clarify the optimal treatment regimen for vismodegib in this setting.

Odontogenic keratocystic tumor standard treatment is a wide surgical excision and curettage with extraction of associated teeth by an oral and maxillofacial surgeon or by an otorhinolaryngologist¹⁵.

Patients presenting medulloblastoma require intensive multimodal therapy. The best results are achieved with aggressive resection, chemotherapy, and radiation therapy. Radiotherapy may induce multiple BCC¹⁶ or others intracranial and sinus nasal tumors¹⁷ in these patients, therefore postoperative radiotherapy should be performed judiciously.

Life expectation for patients with this syndrome is not significantly altered, since the most common lesions are benign. However, the morbidity of its complications could be important, such as the medulloblastoma as a potential cause of premature death.

In summary, Gorlin-Goltz Syndrome is a dominant autosomal genetic disorder that can lead to cancer and other developmental abnormalities. Clinical evaluation is key to correct diagnosis, leading to early treatment to the affected patients.

REFERENCES

- Casaroto AR, Loures DC, Moreschi E, Veltrini VC, Trento CL, Gottardo VD, et al. Early diagnosis of Gorlin-Goltz syndrome: case report. *Head Face Med.* 2011;7:2.
- Lo Muzio L. Nevoid basal cell carcinoma syndrome (Gorlin syndrome). *Orphanet J Rare Dis.* 2008;3:32.
- Evans DG, Farndon PA. Nevoid basal cell carcinoma syndrome. In: Pagon RA, Adam MP, Ardinger HH, Bird TD, Dolan CR, Fong C-T, et al., editors. *GeneReviews*(®) [Internet]. Seattle (WA): University of Washington, Seattle; 1993 [cited 2014 Jun 7]. Available from: <http://www.ncbi.nlm.nih.gov/books/NBK1151/>.
- Bonifas JM, Bare JW, Kerschmann RL, Master SP, Epstein EH Jr. Parental origin of chromosome 9q22.3-q31 lost in basal cell carcinomas from basal cell nevus syndrome patients. *Hum Mol Genet.* 1994;3:447-8.
- Muzio LL, Pastorino L, Levanat S, Musani V, Situm M, Ponti G, et al. Clinical utility gene card for: Gorlin Syndrome - update 2013. *Eur J Hum Genet [serial online].* 2013 Oct [cited 2014 Jun 7];21(10). Available from: <http://www.nature.com/doi/10.1038/ejhg.2012.299>
- Stone DM, Hynes M, Armanini M, Swanson TA, Gu Q, Johnson RL, et al. The tumour-suppressor gene patched encodes a candidate receptor for Sonic hedgehog. *Nature.* 1996;384:129-34.
- Lam C, Ou JC, Billingsley EM. "PTCH"-ing it together: a basal cell nevus syndrome review. *Dermatol Surg.* 2013;39:1557-72.
- Dreier J, Felderer L, Barysch M, Rozati S, Dummer R. Basal cell carcinoma: a paradigm for targeted therapies. *Expert Opin Pharmacother.* 2013;14:1307-18.

9. Kimonis VE, Goldstein AM, Pastakia B, Yang ML, Kase R, DiGiovanna JJ, et al. Clinical manifestations in 105 persons with nevoid basal cell carcinoma syndrome. *Am J Med Genet.* 1997;69:299-308.
10. Hilgert R, Fonseca LAM, Ribeiro FF. Síndrome de Gorlin: relato de envolvimento familiar. *Rev Cir Traumatol Buco-Maxilo-Fac.* [serial online] 2010 [cited 2012 Jun 21];10(3):[6 pages]. Available from: <http://www.revistacirurgiabmf.com/2010/v10n3/7.pdf>.
11. Guenova E, Saulite I, Voykov B, Mehra T, Hoetzenecker W. Incidental finding of lamellar calcification of the falx cerebri leading to the diagnosis of gorlin-goltz syndrome. *Case Rep Dermatol.* 2013;5:301-3.
12. Frentz G, Munch-Petersen B, Wulf HC, Niebuhr E, da Cunha Bang F. The nevoid basal cell carcinoma syndrome: sensitivity to ultraviolet and x-ray irradiation. *J Am Acad Dermatol.* 1987;17:637-43.
13. Gorlin RJ. Nevoid basal cell carcinoma syndrome. *Dermatol Clin.* 1995;13:113-25.
14. Tang JY, Mackay-Wiggan JM, Aszterbaum M, Yauch RL, Lindgren J, Chang K, et al. Inhibiting the hedgehog pathway in patients with the basal-cell nevus syndrome. *N Engl J Med.* 2012;366:2180-8.
15. Shanley S, Ratcliffe J, Hockey A, Haan E, Oley C, Ravine D, et al. Nevoid basal cell carcinoma syndrome: review of 118 affected individuals. *Am J Med Genet.* 1994;50:282-90.
16. Mancuso M, Pazzaglia S, Tanori M, Hahn H, Merola P, Rebessi S, et al. Basal cell carcinoma and its development: insights from radiation-induced tumors in Ptch1-deficient mice. *Cancer Res.* 2004;64:934-41.
17. Choudry Q, Patel HC, Gurusinghe NT, Evans DG: Radiation-induced brain tumours in nevoid basal cell carcinoma syndrome: implications for treatment and surveillance. *Childs Nerv Syst.* 2007;23:133-6.

Received: 28/07/2014

Accepted: 12/09/2014