

# Improvement of behavioural and manic-like symptoms secondary to herpes simplex virus encephalitis with mood stabilizers: a case report



Received 28 July 2010; Reviewed 5 September 2010; Revised 10 September 2010; Accepted 13 November 2010;  
First published online 4 February 2011

Herpes simplex encephalitis (HE) is one of the most common aetiologies of fatal sporadic encephalitis (Whitley, 1990). Although acyclovir has greatly decreased mortality, HE is still associated with significant mortality (19–28%) and morbidity with rates of complete recovery less than 50% (Skoldenberg *et al.* 1984; Taira *et al.* 2009). Behavioural and cognitive symptoms are common sequelae of HE, even when appropriate antiviral therapy is administered in the acute stage of the illness (McGrath *et al.* 1997). Therefore, there is a need for novel therapeutic regimens for HE, given that current available treatment is not fully effective and the scarce available literature suggests benefit with alternative treatments.

The effect of drugs on neuroplasticity has received greater attention in psychopharmacology, with recent studies showing that neurotrophic properties may be important for the behavioural and symptomatic effect of mood stabilizers such as valproate and lithium (Frey *et al.* 2006). Therefore, it could be hypothesized that these pharmacological properties may be useful in the treatment of HE, given that it is often associated with neuronal damage and behavioural symptoms. Here, we report on a 20-yr-old woman with HE and prominent secondary behavioural and manic-like symptoms. To the best of our knowledge this is the first report of HE that was responsive to pharmacotherapy which is the first-line treatment for acute mood episode.

## Case report

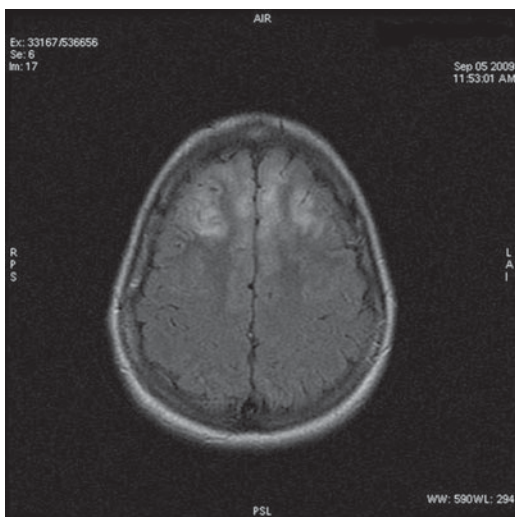
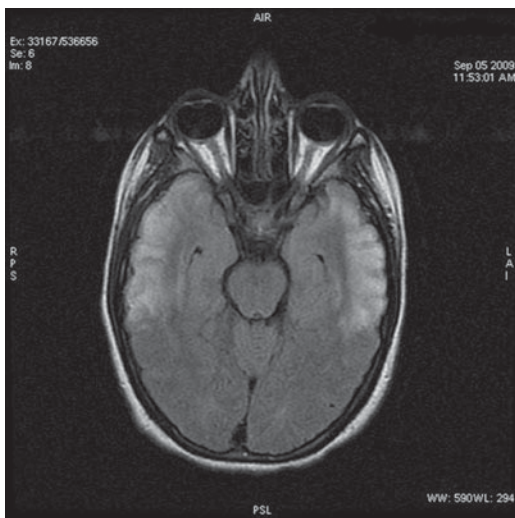
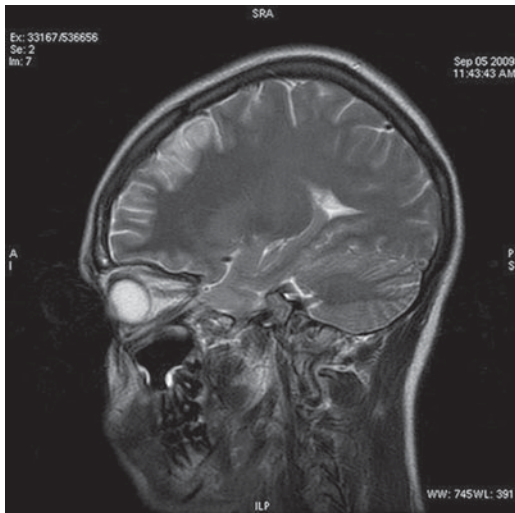
Ms. X, a 20-yr-old woman, was admitted to the emergency room with headache, vomiting, cough and dyspnoea; these had gradually developed within the previous 2 wk. Within the first 48 h, Ms. X showed a gradual decrease in consciousness level; a diagnosis of HE was considered and acyclovir treatment was

initiated (10 mg/kg). The initial HE hypothesis was confirmed by detection of herpes simplex virus (HSV) with polymerase chain reaction (PCR) in CSF. Despite acyclovir treatment, there was a rapid progressive deterioration up to coma (Glasgow rating scale 6). The first cranial computed tomography was normal, but when repeated a few days later, it showed bilateral fronto-temporal hypodensity. In addition, electroencephalogram showed bilateral periodic lateralized epileptiform discharges, which is suggestive of HE.

After 16 d of acyclovir treatment, Ms. X showed improvement of consciousness level and was admitted to a psychiatric ward due to behavioural changes, such as inappropriate laugh, elevated mood, hypersexuality, disinhibition, impaired memory, executive function and confusion (i.e. she was not able to formulate complete sentences, often answering just 'yes'/'no'). At admission to the psychiatric in-patient unit, Ms. X showed poor insight and judgement associated with inappropriate behaviour in the ward (i.e. tried to break decorative objects). Further, she showed mood lability and attention deficit at times. With the purpose of evaluating these symptoms compared to those of mood episodes, we completed mood scales, even though the symptoms were secondary. The Young Mania Rating Scale (YMRS) and Hamilton Depression Rating Scale (HAMD) scores were 14 and 2, respectively. Behavioural symptoms persisted even after acyclovir treatment was completed and HSV-PCR in CSF was negative.

In a symptomatic treatment approach, we decided to start her on mood stabilizers (valproate up to 1000 mg/d and olanzapine up to 10 mg/d). Ms. X showed a marked response within 10 d of treatment initiation. She fulfilled discharge criteria after 14 d of valproate and olanzapine treatment. The control magnetic resonance imaging with gadolinium – by discharge, showed increased signal intensity in frontal-temporal lobes (Fig. 1), suggesting persistent inflammation; despite this, there was remission of psychiatric (YMRS and HAMD scores were 6 and 0 points, respectively) and cognitive symptoms (Mini Mental State Examination score 30). The patient gave

Address for correspondence: Dr M. Kauer-Sant'Anna, Bipolar Disorders Program, Hospital de Clínicas de Porto Alegre, Rua Ramiro Barcelos, 2350, 90035-903, Porto Alegre, RS, Brazil.  
Tel.: +55 51 33598845 Fax: +55 51 33598846  
Email: marciaks@terra.com.br



**Fig. 1.** MRI with gadolinium showing increase in signal intensity in frontal-temporal lobes.

informed consent for this case report which was approved by the ethics committee.

Additional information included a pre-morbid history of chronic use of snorted cocaine for about 2 yr (on average 3 times a week), which was stopped 10 d before hospitalization. There was a possible family history of drug addiction and undiagnosed mood disorder. Ms. X showed normal development and regular performance in school and no psychiatric symptom other than drug abuse prior to HE. We were unable to obtain follow-up information following discharge due to a change in Ms. X's address and phone number. In addition, according to family report, she was no longer living in the same city as her family; therefore they had no contact with her. As far as we could ascertain, she was living independently.

### Discussion

This is the first report to suggest a benefit of a treatment approach to HE including mood stabilizers. This is in line with the fact that psychiatric symptoms in HE are associated with inflammation of inferomedial temporal lobe and limbic system, which are similar to those regions involved in bipolar disorder (Fisher, 1996). Moreover, current findings are consistent with previous studies showing that manic symptoms secondary to brain injury may respond to valproate. Furthermore, based on recent studies which suggest that valproate can increase neurotrophic factors, such as brain-derived neurotrophic factor in the hippocampus (Frey *et al.* 2006), and clinical trials suggesting olanzapine and valproate are effective in treating manic symptoms, there may be neurobiological support for the hypothesis of a 'neuroprotective' and symptomatic treatment approach in HE.

This case report highlights the high rates of morbidity of HE, in particular the behavioural consequences and the difficulty in treating these symptoms. We report a surprisingly rapid response to treatment when valproate and olanzapine were added to the regimen. Given this outcome, it could be viewed that early initiation of mood stabilizers may be important in the rapid resolution of symptoms secondary to brain injury in HE. Previous studies have demonstrated that although acyclovir reduced HE mortality, there was still 30% mortality or severe neurological deficit (McGrath *et al.* 1997). Therefore, based on Ms. X's case outcome, we consider the hypothesis that mood stabilizers can possibly improve these residual symptoms or diminish the morbidity rates.

Caution is warranted when interpreting the findings in this case report. First, we cannot exclude that

the beneficial effect of the treatment was associated with previous cocaine dependence diagnosis or subthreshold mood disorder and not just with HE. Second, as we used concomitantly an anticonvulsant and an antipsychotic drug, we cannot determine if the benefit was due to one of those or the combination. In this case report, we use the term 'mood stabilizers' referring to valproate and olanzapine, but their mechanisms of action differ. In addition, there is a possibility that the improvement was associated with the natural history of the disease; given this is a single case report. However, as the rapid and significant clinical response was not expected, we suggest that at least this treatment approach should be taken into consideration in future research and in HE cases with prominent behavioural symptoms.

HE is a highly disabling disease, so efficacy of treatment strategies should be investigated in favour of prevention of persistent neuropsychiatric sequelae. This case report raises the possibility that classical treatment for mood stabilization may be useful in improving neuropsychiatric symptoms and in preventing further damage in HE. We stress that future clinical trials and prospective reports are needed to investigate this hypothesis.

#### Acknowledgements

None.

#### Statement of Interest

Dr Kapczinski has been an investigator in clinical trials sponsored by Stanley Medical Research Institute and AstraZeneca. He is also a NARSAD Independent Investigator and has received unrestricted research grants from CNPq-INCT-TM, CNPq-Universal, CAPES. He has received speakers' fees or travel assistance from Eli Lilly, GlaxoSmithKline and Janssen.

Dr Kauer-Sant'Anna has been an investigator in clinical trials sponsored by Stanley Medical Research Institute and AstraZeneca. She is also a NARSAD Young Investigator and has received unrestricted research grants from CNPq-Universal, CNPq-INCT-TM, CAPES, APA/AstraZeneca. She has received speakers' fees or travel assistance from Eli Lilly and Janssen.

#### References

- Fisher CM** (1996). Hypomanic symptoms caused by herpes simplex encephalitis. *Neurology* **47**, 1374–1378.
- Frey BN, Andreazza AC, Ceresér KM, Martins MR, et al.** (2006). Effects of mood stabilizers on hippocampus BDNF levels in an animal model of mania. *Life Sciences* **79**, 281–286.
- McGrath N, Anderson NE, Croxson MC, Powell KF** (1997). Herpes simplex encephalitis treated with acyclovir: diagnosis and long term outcome. *Journal of Neurology, Neurosurgery & Psychiatry* **63**, 321–326.
- Skoldenberg B, Alestig K, Burman L, Forkman A, et al.** (1984). Acyclovir vs. vidarabine in herpes simplex encephalitis: randomised multicentre study in consecutive Swedish patients. *Lancet* **324**, 707–711.
- Taira N, Kamei S, Morita A, Ishihara M, et al.** (2009). Predictors of prolonged clinical course in adult patients with herpes simplex virus encephalitis. *Internal Medicine* **48**, 89–94.
- Whitley RJ** (1990). Viral encephalitis. *New England Journal of Medicine* **323**, 242–250.
- Mirela P. Vasconcelos-Moreno<sup>1,2</sup>, Aroldo Ayub Dargél<sup>2</sup>, Pedro Dominguez Goi<sup>2</sup>, José Augusto Bragatti<sup>3</sup>, Flavio Kapczinski<sup>1,2</sup>, Marcia Kauer-Sant'Anna<sup>1,2</sup>**  
<sup>1</sup> *Department of Psychiatry, Universidade Federal do Rio Grande do Sul, Rua Ramiro Barcelos, Porto Alegre, RS, Brazil*  
<sup>2</sup> *Bipolar Disorders Program, Hospital de Clínicas de Porto Alegre, Rua Ramiro Barcelos, Porto Alegre, RS, Brazil*  
<sup>3</sup> *Division of Neurology, Universidade Federal do Rio Grande do Sul, Rua Ramiro Barcelos, Porto Alegre, RS, Brazil*