



## Oral metastasis of angiosarcoma of the bladder: A case report

M Curra<sup>1</sup>, MD Martins<sup>1\*</sup>, M AT Martins<sup>3</sup>, L Meurer<sup>2</sup>, MC Munerato<sup>3</sup>

### Abstract

#### Introduction

Bladder cancer is one of the most common cancers worldwide. Oral bladder cancer metastasis are unusual. The aim the present study was to describe a uncommon case of oral metastasis of angiosarcoma of the bladder and discuss this case with literature.

#### Case report

This study describes a case of a 28 year-old male patient presenting a symptomatic mouth lesion. The lesions exhibited erythematous and ulcerative surface and the incisional biopsy was done followed by histopathological analysis. An immunohistochemical panel (AE1/AE3, CK7, CK9, CK10, CK20, s-100, HMB-45, desmine, actin, Factor VIII, CD-34, vimentin and CD-31) was necessary to establish the definitive diagnosis of angiosarcoma.

#### Conclusion

Angiosarcoma is a rare tumour in the oral cavity, especially in cases of metastasis of a tumour found in the bladder.

### Introduction

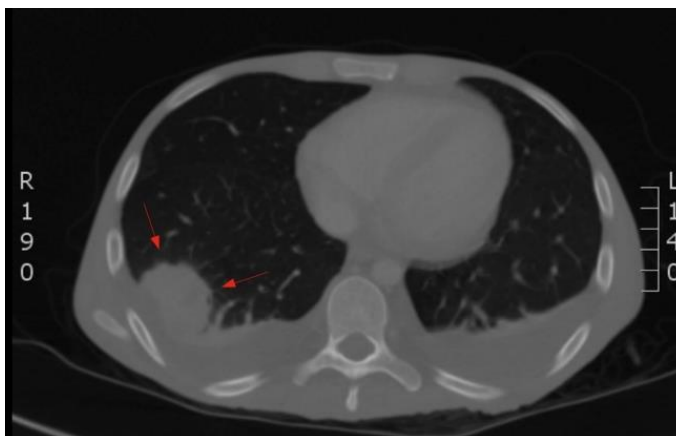
Bladder cancer is the most common malignancy involving the urinary system and the ninth most common malignancy worldwide. Urothelial (transitional cell) carcinoma is the most frequent form of bladder cancer, accounting for approximately 90% of cases, followed by squamous cell carcinoma (5%) and adenocarcinoma (2%).<sup>1,2,3</sup>

Angiosarcoma is a rare mesenchymal tumour of the vascular endothelium, accounting for less than 1% of all sarcomas. The most commonly affected sites are the soft tissues and skin. Only one third of such tumours are deep, mainly affecting the liver, spleen and heart, whereas angiosarcoma of the bladder is extremely rare.<sup>4,5,6</sup> In the head and neck region, angiosarcoma accounts for approximately 10% of soft tissue sarcomas.<sup>7</sup> The presence of this tumour in the oral cavity is uncommon, representing less than 2% of all angiosarcomas.<sup>8</sup> Angiosarcoma in the oral cavity may occur in bone tissue, glands or soft tissue as either a primary or metastatic lesion.<sup>9</sup> In the case of angiosarcoma of the bladder, distant

metastases are commonly found in the lungs, liver, lymph nodes and skin.<sup>10</sup> Metastatic lesions in the oral cavity comprise around 0.1% of oral tumours and mainly affect the gingiva.<sup>4,11</sup> The aim of this paper is to report a case of oral metastasis of angiosarcoma of the bladder showing its clinical aspect, histopathological and discuss the diagnosis and management of hypotheses performed.

### Case report

A 28-year-old male farmer was referred to the Oral Medicine Department complaining of a symptomatic mouth lesion with a 20-day history. The patient was in chemotherapy (paclitaxel) for angiosarcoma of the bladder with metastatic lesions in the large intestine, oesophagus and lungs (Figure 1). The medical history revealed chronic kidney failure, which had led to hospitalization two years earlier for dialysis. During this period, the patient was submitted to cystoscopy, which led to the discovery of bladder cancer with a histopathological diagnosis of infiltrative high-grade bladder carcinoma. The patient received four months of radiotherapy sessions, followed by surgery to remove the tumour. After one year, the patient reported localized pain in other parts of the abdomen (acute peritonitis). Endoscopy, colonoscopy and biopsies were performed. The diagnosis was undifferentiated malignant tumours in the oesophagus and large intestine. Reexamination of the biopsy material and immunohistochemical analysis led the pathologists to conclude that the tumour in the bladder was an angiosarcoma. The clinical oral exam revealed a nodular erythematous exophytic lesion with surface ulceration involving the upper and lower gingival, buccal mucosa and soft palate (Figure 2). The diagnostic hypothesis was either metastatic lesion or primary malignant neoplastic lesion



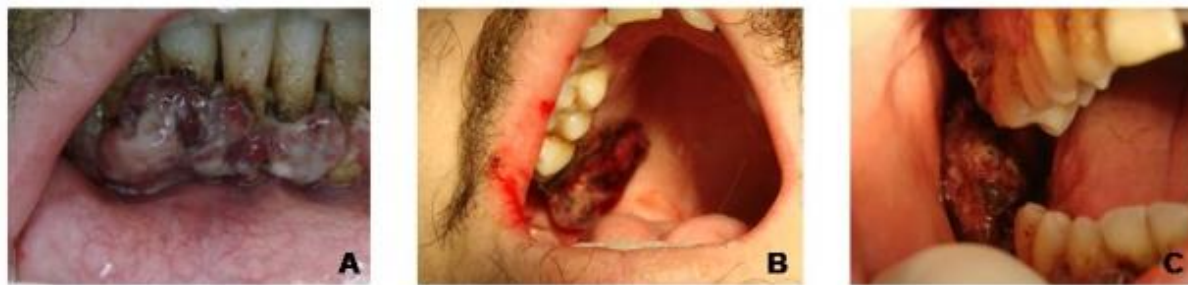**Figure 1:** In computed tomography of the lungs is observed heterogeneous lesion with heterogeneous impregnation located in the right lower lobe. It measures approximately 5 inches in higher diameter. The radiological report of this lesion indicates probable metastasis.

\*Corresponding author  
Email: manomartins@gmail.com

<sup>1</sup> Department of Oral Pathology, School of Dentistry, Universidade Federal do Rio Grande do Sul, Brazil.

<sup>2</sup> Department of Pathology of Hospital de Clínicas de Porto Alegre, Brazil

<sup>3</sup> Department of Stomatology of Hospital de Clínicas de Porto Alegre, Universidade Federal do Rio Grande do Sul, Brazil.

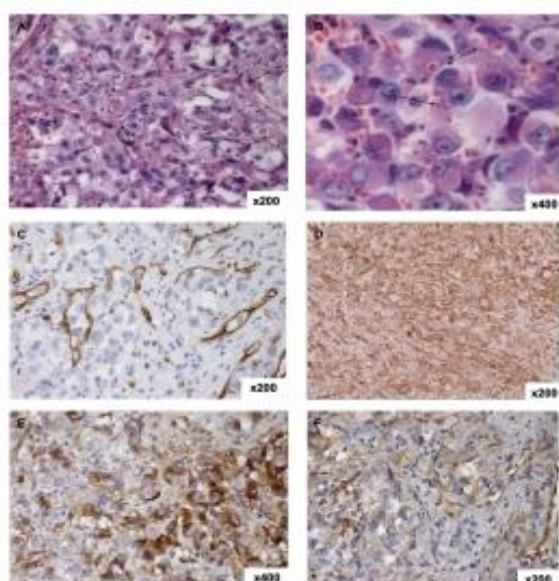


**Figure 2:** Clinical view of nodular exophytic lesion with erythematous, ulcerative surface in lower gingiva (A), soft palate (B), buccal mucosa and upper gingiva (C).

(sarcoma X carcinoma). Incisional biopsy was performed.

The histopathological examination revealed an infiltrative undifferentiated malignant tumour with a predominantly solid pattern and areas of necrosis. The tumour cells exhibited vasoformative channels containing red blood cells. Cellular pleomorphism was observed under high magnification, with cells exhibiting a large, round, eosinophilic cytoplasm, large vesicular nucleus and hyperchromatic nucleolus. Spaces containing erythrocytes were observed in the cytoplasm (Figure 3 A/B). An immunohistochemical panel was performed (Table 1), which revealed no labelling for epithelial, muscular or neural lesions or melanoma. Labelling was also negative for CD-34, but positive for blood vessels feeding the tumor. Positive reactions were found for vimentin, CD-31 and factor VIII, revealing an angioblastic origin and

Antibody	Reaction	Investigating
AE1/AE3	negative	Epithelial lesions
CK 7		
CK 9		
CK 10		
CK 20		
Vimentine	positive	Mesenchymal lesions
Actin	negative	Muscle lesions
Desmin		
S-100	negative	Neural lesions/melanoma
HMB-31	negative	Melanoma
CD-31	positive	Vascular lesions
Factor VIII	positive	
CD-34	negative-tumor	



**Figure 3:** A) Tumor cells with vasoformative channels containing red blood cells; B) Under high magnification, cellular pleomorphism and cells exhibiting large, round, eosinophilic cytoplasm, large vesicular nucleus, hyperchromatic nucleolus (1) and spaces in cytoplasm containing erythrocytes (2). Immunohistochemical panel revealing positive labeling for CD-34 (C), indicating vessels feeding tumor, and intense labeling for vimentin (D), factor VII (E) and CD-31 (F).

mesenchymal features of the tumour (Figure 3 C/D/E/F). A diagnosis of angiosarcoma was established. The patient was referred to the head-and-neck surgeon for treatment of the oral lesion, but unfortunately died two months following the diagnosis.

### Discussion

Angiosarcoma is generally a highly malignant, rapidly metastasizing and often fatal tumour. Its behaviour depends on the location and degree of differentiation.<sup>9,12</sup> Patients with metastatic lesions in the oral cavity have a poor prognosis and die from the disease within 1 to 15 months in most cases.<sup>8</sup> In the present case, the patient was evaluated 20 days after the appearance of the lesion in the oral cavity and died two months later.

The correct diagnosis is very important to the establishment of the best treatment and requires the combination of clinical, histopathological and immunohistochemical findings.<sup>4</sup> Clinically, the differential diagnosis of an oral lesion should include pyogenic granuloma, giant cell granuloma, Kaposi sarcoma and melanoma.<sup>7,13</sup> All these tumours exhibit a nodular aspect with a reddish colour due to the increase in blood vessels and fast evolution. In the present case, a benign lesion was ruled out based on the predominant features, such as the ulcerative, erythematous surface and the patient's medical history.

Competing interests: None declared. Conflict of interests: None declared. All authors contributed to conception and design, manuscript preparation, read and approved the final manuscript. All authors abide by the Association for Medical Ethics (AME) ethical rules of disclosure.



The initial histopathological diagnosis of the bladder lesion was carcinoma. However, the analysis of the metastatic tumour led to the diagnosis of angiosarcoma. This mistake may be explained by the fact that the tumour had a predominant component of epithelioid cells, indicating undifferentiated angiosarcoma, which can mimic an epithelial tumour.<sup>14</sup>

Therefore, an immunohistochemical panel is necessary to establish the definitive diagnosis of angiosarcoma. For such, the most important markers are vimentin, CD-31, CD-34, factor VIII and UEA-1.<sup>15</sup> Positive labelling for these markers reveals the angioblastic origin and mesenchymal features of the tumour. Among these markers, CD-31 is considered the most sensitive and specific, as it is positive in nearly 90% of angiosarcomas.<sup>7,14,15</sup>

### Conclusion

Angiosarcoma is a rare tumour in the oral cavity, especially in cases of metastasis of a tumour found in the bladder. As this neoplasm is highly malignant and fatal, the diagnosis should be established as soon as possible for the early institution of adequate treatment.

### Consent

Written informed consent was obtained from the patient for publication of this case report and accompanying images. A copy of the written consent is available for review by the Editor-in-Chief of this journal.

### References

1. Ploeg M, Aben KK, Kiemeney LA. The present and future burden of urinary bladder cancer in the world. *World J Urol.* 2009, 27: 289.
2. Siegel R, Naishadham D, Jemal A. Cancer statistics, 2013. *CA Cancer J Clin.* 2013, 63: 11.
3. Williams SK, Romaguera RL, Kava B. Angiosarcoma of the Bladder: Case Report and Review of the Literature. *The Scientific Works Journal.* 2008, 8: 508-511.
4. Medina BR, Barba EM, Torres AV, et al. Gingival metastases as first sign of a primary uterine angiosarcoma. *J Oral Maxillofac Surg.* 2001, 59: 467-471.
5. Skarin A. Angiosarcoma. *Journal of Clinical Oncology.* 1997, 15: 1708-1709.
6. Seethala RR, Gomez JA, Vakar-Lopez F. Primary Angiosarcoma of the Bladder. *Arch Pathol Lab Med.* 2006, 130: 1543-1547.
7. Yang XJ, Zheng JW, Zhou Q, et al. Angiosarcoma of the head and neck: a clinico-immunohistochemical study of 8 consecutive patients. *Int J. Oral Maxillofac. Surg.* 2012, 39: 568-572.
8. Fanburg-Smith JC, Furlong MA, Childers ELB. Oral and Salivary Gland Angiosarcoma: A Clinicopathologic Study of 29 cases. *Mod Pathol.* 2003, 16: 263-271.
9. Terada T. Angiosarcoma of the mandibular gingiva. *Int J Clin Exp Pathol.* 2011, 4: 791-793.
10. Skarin A. Unusual Tumors Involving the Head and Neck Region. *Journal of Clinical Oncology.* 2001, 19: 4173-4179.

11. Epstein JB, Knowling MA, Le Riche JC. Multiple gingival metastases from angiosarcoma of the breast. *Oral surg oral med oral pathol.* 1987, 64: 554-557.

12. Carr RJ, Green DM. Oral Presentation of Disseminated Angiosarcoma. *British Journal of Oral and Maxillofac Surg.* 1986, 24: 277-285.

13. Muñoz M, Hoyo JA, Martín-Granizzo R. Oral Angiosarcoma Misdiagnosed as a Pyogenic Granuloma. *J Oral Maxillofac Surg.* 1998, 56: 488-491.

14. Kao YC, Chow JM, Wang KM, et al. Primary pleural angiosarcoma as a mimicker of mesothelioma: a case report. *Diagnostic Pathology.* 2011, 6: 130-134.

15. Terada T. Angiosarcoma of the Oral Cavity. *Head and Neck Pathol.* 2011, 5: 67-70.