

LUNG AND LIVER CHANGES DUE TO THE INDUCTION OF CIRRHOSIS IN TWO EXPERIMENTAL MODELS

Renata Salatti **FERRARI**^{1,3}, Maurício **TIEPPO**^{1,2}, Darlan Pase da **ROSA**^{1,2,3},
Luiz Alberto **FORGIARINI JR**¹, Alexandre Simões **DIAS**^{1,3} and Norma Possa **MARRONI**^{1,2,3}

ABSTRACT - Context - To evaluate lung and liver changes in two experimental models using intraperitoneal carbon tetrachloride (CCl₄) and bile duct ligation (BDL). **Methods** - Twenty-four male Wistar rats were divided into a control group (CO) and an experimental group (EX). We evaluated the liver transaminases (AST, ALT, AP), arterial blood gases (PaO₂, PCO₂ and SpO₂) and lipid peroxidation by TBARS (substances that react to thiobarbituric acid) and chemiluminescence. We also evaluated the antioxidant enzyme superoxide dismutase (SOD) and histology of lung tissue and liver. **Results** - There were significant differences in AST, ALT, ALP and PaO₂ between CO group and EX group ($P < 0.05$). The levels of TBARS, chemiluminescence and activity of enzyme superoxide dismutase were increased to different degrees in the CCl₄ groups: CO and in the BDL -EX ($P < 0.05$, respectively). In the lung histology, an increase in the wall thickness of the pulmonary artery and a diameter reduction in the CCl₄ animal model were observed: comparing CO group with EX group, we observed a reduction in thickness and an increase in the diameter of the artery wall lung. **Conclusion** - Both experimental models have caused liver damage and alterations in the artery wall that are associated with major changes in pulmonary gas exchange. **HEADINGS** - Liver diseases. Lung diseases. Liver cirrhosis experimental. Carbon tetrachloride, diagnostic use. Common bile duct, physiopathology. Diseases models, animal.

INTRODUCTION

Fibrosis is an important process that results from hepatic injury and chronic disease process. Both of these causes can have common etiologies that can contribute to the onset of cirrhosis⁽²⁾.

Cirrhosis is considered to be the most advanced stage of tissue fibrosis and is characterized by the disruption of hepatic parenchyma, the appearance of the septa and fibrotic nodules, changes in hepatic blood flow and a risk of liver failure⁽¹⁰⁾.

Cirrhosis can be caused by altered vascular tissue, which causes a shift in the supply of blood and portal blood flow directly to the liver (central vein). The altered vascular tissue compromises the hepatic sinusoids and hepatocytes. Some of the circulatory changes found in cirrhosis are splanchnic vasodilatation, vasoconstriction and renal hypoperfusion, salt and water retention and increased cardiac output, which are all closely linked to vascular disease of the liver that may cause portal hypertension^(8, 25).

Portopulmonary hypertension (PPH) is a relatively rare complication occurring in cirrhosis, and its prevalence is high in patients with refractory ascites. PPH is mostly likely caused by excessive pulmonary vasoconstriction and factors such as transforming

growth factor beta1 (TGF- β 1)⁽⁴⁾. However, we do not have a perfect experimental model for the study of PPH, making the discovery of effective substances that can reduce and even prevent the progression of the disease impossible. Developing an experimental model is be very useful, as such a model could lead to substantial cost savings in treatment.

Carbon tetrachloride (CCl₄) can be applied both intraperitoneally and by inhalation. CCl₄ induces fibrosis liver cirrhosis and may be used for the study of PPH. The signals observed in the CCl₄ liver injury model are similar to those found in cirrotic patients⁽¹⁹⁾. The CCl₄ trichloromethyl radical is converted to (\bullet CCL₃) and trichloromethyl peroxide (\circ OOCCl₃). The CCl₄ trichloromethyl radical has been described as causing hepatotoxic effects such as fibrosis, steatosis, necrosis and hepatocellular carcinoma^(9, 22).

Bile duct ligation is another experimental model related to secondary biliary cirrhosis because it causes cell proliferation, hepatocellular necrosis, apoptosis, activation of stellate cells, and finally the formation of liver fibrosis and cirrhosis. This model has been described by our group as causing Experimental Hepatopulmonary Syndrome^(26, 29).

Given the complications of cirrhosis, the aim of this study was to evaluate two types of pulmonary and

Declared conflict of interest of all authors: none

¹ Research performed at: Laboratório de Hepatologia e Gastroenterologia, Hospital das Clínicas de Porto Alegre (HCPA); ² Universidade Luterana do Brasil (ULBRA); ³ Universidade Federal do Rio Grande do Sul (UFRGS), Porto Alegre, RS, Brasil. Financial Support: Fundo de incentivo à pesquisa e eventos do Hospital de Clínicas de Porto Alegre. FIPE / HCPA.

Correspondence: Dr. Renata Salatti Ferrari - Street Evaristo da Veiga, 196/04 - 90620-230 - Porto Alegre, RS, Brasil. E-mail: renatasalattiferrari@gmail.com

hepatic injury that cause liver cirrhosis, a CCl₄ model and a BDL model, to evaluate which model can best reproduce characteristics found in PPH.

METHODS

Animals and experimental groups

We used 24 male Wistar rats (average weight 250 g), purchased from the Center for Reproduction and Laboratory Animal Experimentation (CREAL), Federal University of Rio Grande do Sul (UFRGS). The animals were housed in plastic cages (47×34×18 cm) and maintained in light/dark cycles of 12/12 hs with a controlled temperature (20-25 °C) and ad libitum access to food and water. All of the procedures followed the parameters established by the Ethics and Research of Hospital Clinics of Porto Alegre, and all of the animals received care according to the "Principles of Laboratory Animal Care" formulated by the National Society for Medical Research and the "Guide for the Care and Use of Laboratory Animals" published by the National Institutes of Health (NIH publication 86-23, revised 1985).

The animals were randomly divided into four groups, an experimental and a control group (CO), for each of the two models used in the study, intraperitoneal Carbon tetrachloride (CCl₄) and bile duct ligation (BDL):

- CCl₄-CO: animals that received only phenobarbital in drinking water;
- CCl₄-EX: animals that received phenobarbital in drinking water one week before starting the injections of CCl₄ inductions + ip;
- BDL-CO: animals that underwent laparotomy and only manipulation of the duct biliar.
- BDL-EX: animals subjected to BDL.

Experimental procedures

To develop the CCl₄ model, we used the standard recommended by Pavanato et al.⁽²¹⁾. Phenobarbital was added to the drinking water of animals (0.3 mL/dL), serving as an enzyme inducer to potentiate the effect of CCl₄.⁽⁶⁾

To develop the BDL model, we followed the standard described by Kontouras et al.⁽¹⁴⁾ where, after the experimental procedures, the animals were caged individually for a period of 28 days.

When sacrificing animals from either group, the animals were anesthetized with xylazine (50 mg/kg body weight) and ketamine (100 mg/kg body weight), both administered intraperitoneally. Post mortem, blood samples were collected via retro-orbital plexus for liver function analysis⁽¹²⁾.

After the abdominal region was shaved, a laparotomy was performed to collect blood from the abdominal aorta for arterial blood gas analysis. After collection of blood samples, the animals were sacrificed with an "overdose" of anesthetics.

Histology

For histological analysis of the lung, a fragment of the

right lower lobe was collected for histological analysis, and a fragment of the liver was removed from the right hepatic lobe. The tissues were cut and fixed by immersion in 10% buffered formalin for 24 hours. The remainders of lung and liver were immediately frozen in liquid nitrogen and stored at -80°C for later analysis.

Integrity liver enzymes

Blood samples taken from the retro-orbital plexus were used to assess the levels of aspartate aminotransferase (AST), alanine aminotransferase (ALT), and alkaline phosphatase (AP) and were expressed in IU/L and measured with routine laboratory methods in the Hospital Clinics of Porto Alegre.

Determination of oxidative stress

The liver tissue and lung of each animal were homogenized in phosphate buffer solution (140 mM KCl, 20 mM phosphate, pH 7.4) and centrifuged at 3,000 rpm for 10 minutes. Lipid peroxidation was determined by levels of thiobarbituric acid reactive substances (thiobarbituric acid reactive substances - TBARS) mg/prot. read at 535 nm. For the determination of chemiluminescence (CL), 0.5 mL of homogenate was added to 120 mM KCl, 30 mM phosphate buffer, pH 7.4, and 3 mM tert-butyl hydroperoxide at 30°C and analyzed for chemiluminescence in a counter liquid scintillation expressed as cps/mg/prot^(12, 18).

Superoxide dismutase enzyme activity

The activity of the antioxidant enzyme superoxide dismutase (SOD) was determined by quantifying the oxidation of adrenaline to adrenochrome according to Misra and Fridovich and was expressed in U/mg/prot⁽¹⁸⁾.

Statistical analysis

The results were expressed as mean ± standard error. Data were compared by analysis of variance (ANOVA), and if the analysis indicated a statistically significant difference, we used a post hoc Student Newman-Keuls test. The statistical significance level was set at $P < 0.05$. The Statistical Package for Social Sciences, version 13.0 (SPSS Inc., Chicago, IL, USA), was used.

RESULTS

Activity of transaminases

Table 1 indicates a significant difference between the CCl₄ and CCl₄-CO-EX groups and between BDL and BDL-CO-EX in serum AST, ALT and AP, which were higher in the experimental groups compared to the controls ($P < 0.05$).

Arterial blood gas analysis

To verify changes in gas exchange, we performed arterial blood gas analysis (Table 1) in which the variables PaO₂ (mmHg), PCO₂ (mmHg) and SpO₂ (%) showed changes in both experimental models. We can see that the animals belonging to the experimental groups (CCl₄-EX and BDL-EX) showed significant differences when compared to their

TABLE 1. Activity of transaminases and arterial blood gas analysis

Variable	CCl ₄ - CO	CCl ₄ - EX	BDL - CO	BDL - EX
AST (IU/L)	119±37	5407± 2592*	169±107	348±148*
ALT (IU/L)	39±7	3306±1308	53± 11	213±324*
FA (IU/L)	67±20	307±88*	116± 45	213±324*
PaO ₂ (mmHg)	106,91±22,01	68,98±17,46*	95,10±17,00	5,97±14,55*
PaCO ₂ (mmHg)	49,85±10,30	55,06±6,04	46,07±7,03	41,40±12,58
SaO ₂ (%)	96,56±3,53	86,65±18,71*	96,52±1,67	93,17±9,72

CCl₄:Carbon tetrachloride; BDL:bile duct ligation; CO:control; EX:experimental; AST:aspartate aminotransferase; ALT:alanina aminotransferase; AP:alkaline phosphatase; PaO₂:pressure oxygen; PaCO₂:cabon dioxide partial pressure; SaO₂: oxygen saturation. Results expressed as mean ± standard deviation. * *P*<0,05 corresponding control group

respective controls (*P*<0.05). Only the variable PCO₂ showed no significant difference between the CO and EX animals in the BDL model.

Markers of Oxidative Stress and Antioxidant Activity

Analysis of lipid peroxidation in lung tissue (Table 2) it appears that TBARS as well as high CL in two models are used in the study (*P*<0.05). Regarding the antioxidant enzyme SOD, a significant increase (*P*<0.05) in both experimental models was observed compared to control animals.

Histology

On the photomicrograph of the lung tissue (Figure 1), we observed an increase of 47.87 mM in wall thickness in

TABLE 2. Evaluation of lipid peroxidation in the lung tissue (TBARS e QL) and antioxidant enzyme SOD

Model	TBARS (nmol/mg prot)	QL (cps/mg prot)	SOD (IU/mg prot)
CCl ₄			
CO	0,56±0,22	16764,20±515,48	11,24±4,99
EX	1,48±0,52*	17797,20±531,65	27,27±1,23*
BDL			
CO	0,835±0,16	16008,41±1171,45	6,66±1,34
EX	1,91±0,91*	20250,36±827,82*	16,06±2,67*

TBARS: thiobarbituric acid reactive substances; QL: chemiluminescence; SOD: superoxide dismutase; CO: control; EX: experimental. Results expressed as mean ± standard deviation. * *P*<0,05 corresponding control group

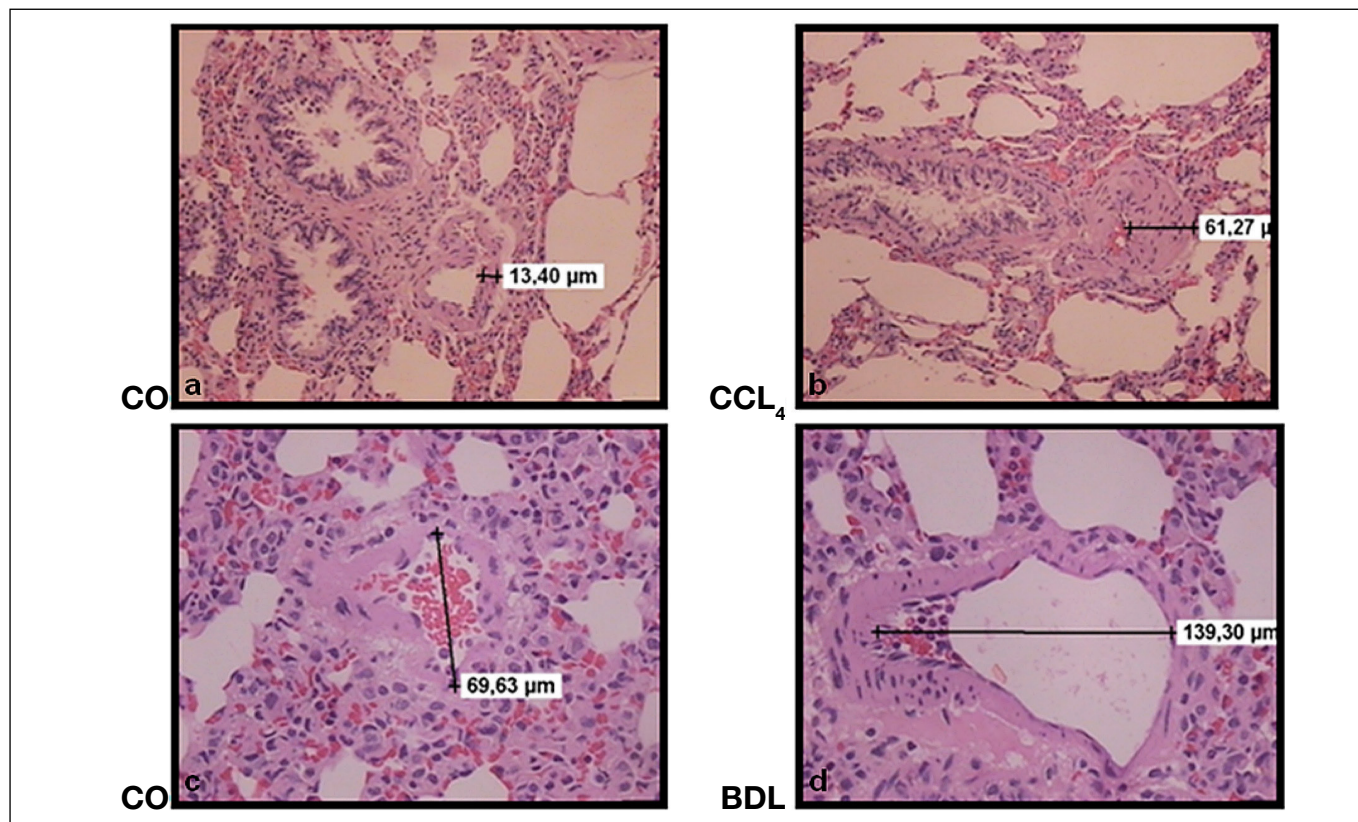


Figure 1. Histology of the pulmonary tissue
Photomicrograph of the lung tissue in the models experimentals. a) CCl₄-CO; b) CCl₄-EX; c) BDL-CO; d) BDL-EX

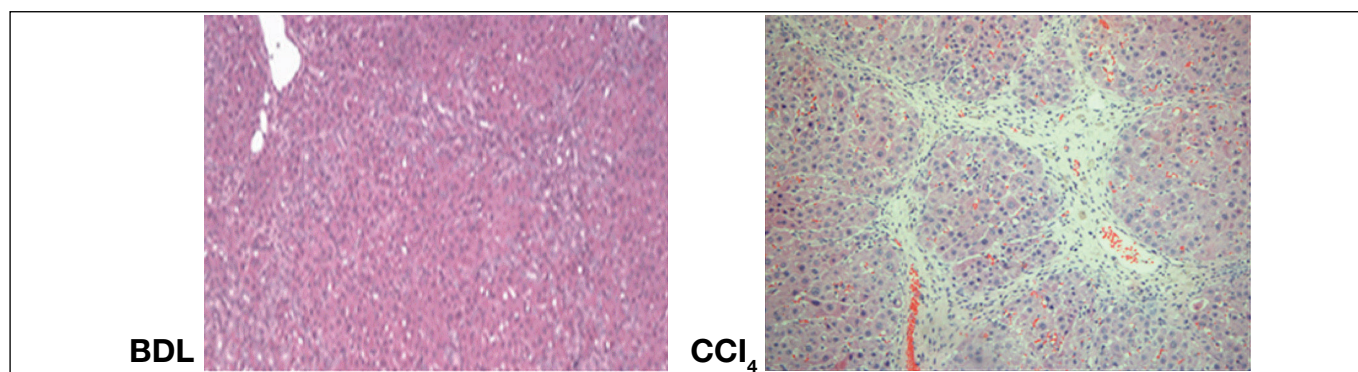


Figure 2. Histology of the liver tissue.

Photomicrograph of the liver tissue in the models experimentals. BDL- and CCl₄-EX

the pulmonary artery model CCl₄ as compared to the CO. However, when analyzing the histology of the pulmonary tissue of the animal model BDL, we observed an increase of 69.67 mM in vascular diameter when compared to controls. The photomicrograph of the liver (Figure 2) revealed the presence of necrotic foci, fibrotic nodules, lymphocytic infiltration, steatosis and cellular changes, suggesting that cirrhosis was present in the two models.

DISCUSSION

In an attempt to develop a specific model for the study of PPH, we used two experimental models developed in our laboratory that cause cirrhosis.

The CCl₄ has been used to reproduce liver cirrhosis due to its potent hepatotoxic effect in which a single dose of CCl₄ is associated with steatosis and necrosis but a prolonged administration leads to liver fibrosis, cirrhosis and hepatocellular carcinoma. CCl₄ acts directly on hepatocytes by changing the permeability of the plasma and mitochondrial membranes. This model has been widely used to elucidate the pathogenesis of cirrhosis⁽¹⁾.

Secondary biliary cirrhosis is a chronic and diffuse liver disease that alters intrahepatic or extrahepatic biliary function. The BDL model is used as an animal model for secondary biliary cirrhosis and cirrhosis caused by progressive and fatal damage to the liver. This model simulates the effects of the disease present in humans, causing changes in the inflammatory reaction by leaking bile and the subsequent disorganization of parenchymal inflammation, collagen deposition and formation of fibrosis^(7, 13, 20).

Studies by Kontouras et al.⁽¹⁴⁾ showed that 15 days after bile duct ligation (BDL), the metabolic and biochemical changes were not fully established. Thus, in our experiment, the animals were sacrificed only after 28 days of BDL, when studies confirmed liver cirrhosis^(17, 29).

In this study, both the BDL and the CCl₄ caused liver damage and elevated serum levels of AST, ALT and ALP, which are commonly known to be markers of liver injury. These changes in liver enzyme levels indicate a loss of tissue integrity with consequent apoptosis and necrosis of hepatocytes. These enzymes are eventually released into circulation

after cellular damage, and this finding has been reported in several studies using models of BDL and CCl₄^(3, 27, 31).

Patients who have secondary biliary cirrhosis exhibit hyperbilirubinemia due to biliary obstruction resulting from liver damage and present results of liver function tests in higher ranges for FA and aminotransferases. High levels of these enzymes are largely caused by the necrosis of tissues that are rich in aminotransferases^(1, 7).

In the presence of liver cirrhosis, there is an increase in lipid peroxidation due to the formation of reactive oxygen species and lipid peroxidation. Some authors report that these phenomena determine the changes in the structures and cell membranes by two mechanisms, covalent binding to macromolecules and cell action on lipids, and that these two mechanisms are the result of the metabolism of CCl₄ by cytochrome P-450, which produces two radicals which are highly toxic and CCl₃, CCl₃O₂••⁽²⁸⁾ Additionally, reactive oxygen species (ROS) are involved in the BDL model.

Cholestasis in the BDL model reduces the excretion of bile salts, causing the retention of hydrophobic bile salts within hepatocytes and apoptosis and necrosis, the destruction of liver parenchyma, which contributes to a redox imbalance, and the formation of ROS. In addition, ROS cause oxidation of cellular proteins and extensive damage to mitochondrial DNA and mitochondrial synthesis by liver damage^(8, 24, 34).

When we evaluated lipid peroxidation in the two models of cirrhosis, animals in the EX group had significantly higher values compared to those in the CO group, and the level of TBARS and QL were elevated in the lung and liver in both groups. This overproduction of ROS might occur in several pathophysiological situations and may explain the finding that in our study, the levels of TBARS and QL were high^(22, 23).

Physiological defense mechanisms are effective in preventing or counteracting the damage caused by free radicals, which can include a set of endogenous antioxidant enzymes such as superoxide dismutase (SOD), catalase (CAT), and glutathione peroxidase (GPx). The two models used in this study showed an increase in lipid peroxidation in lung tissue and are likely to increase in response to an increase of ROS in the SOD, which plays an important role in the balance of the redox cell, as the catalyst free radicals are generated in an attempt to protect the tissue against lesions^(1, 2, 7).

Arterial blood gas analysis is an indicator used to facilitate the evaluation of trade gasosas⁽²⁰⁾. In our study, there was a significant difference between the experimental and control groups with respect to arterial blood gasses. We found that PaO₂ and SpO₂ were significantly lower in the CCl₄ group. In the BDL model, the values of SpO₂ were also reduced, although this did not reach statistical significance.

Approximately 85% of PPH patients show an increase in pulmonary vascular resistance in the course of the disease, of which, 15% experience increases in their pulmonary pressures that are caused by just a state of high flux⁽¹⁵⁾.

The relationship between arterial hypoxemia and PPH has received little attention because PPH is a clinical problem that involves an altered hemodynamic status. PPH patients exhibit arterial hypoxemia and arterial oxygenation that is significantly worse when comparing liver transplantation candidates with normal vascular resistance as determined by echocardiography Doppler⁽¹⁶⁾.

In the BDL model, hypoxemia may be associated with bacterial translocation occurring in 45%-75% of cirrhotic animals whereby the induced hepatocellular damage prevents adequate blood filtration and promotes the development of portosystemic shunts; this phenomenon dramatically decreases the phagocytic ability of the liver, and it also allows the entry of bacteria and endotoxins into the lung circulation⁽²³⁾.

Furthermore, studies have reported arterial hypoxemia in BDL animals, which contributes to a reduction in the values of PaO₂ due to increased volume of lung shunt⁽³²⁾.

The differences found in this study between the BDL and CCl₄ gas analyses showed that regardless of etiology, animals with cirrhosis are hypoxemic because the values of PaO₂ and SpO₂ were lower in both experimental models. This hypoxemia might be triggered by the activation of macrophages as well as the presence of cytokines and nitric oxide in the extracellular medium. Nitric oxide is a potent vasodilator that promotes dilation of intrapulmonary vessels, leading to hypoxemia. Nitric oxide may also be involved in the mechanisms that cause an imbalance between the antioxidants and oxidants⁽²³⁾.

Regarding photomicrographs of the lung tissue, the BDL

model caused an increase in diameter of arterioles of the lung tissue. This finding corroborates studies reporting the increase of animals subjected to BDL⁽²⁹⁾. This result may be due to the increased intrapulmonary shunt caused by liver injury leading to an accumulation of blood in the body, which in turn dilates the arterioles of the lung tissue and releases nitric oxide. In the CCl₄ model, the observed reduction of these structures can be explained by the fact that cirrhotic CCl₄ animals had increased levels of ET-1 and collagen deposition, promoting the reduction in thickness of lung tissue.

The histology of liver tissue revealed damage to liver cells and confirmed the changes observed in biochemical analyses. The presence of necrotic foci, fibrotic nodules, the infiltration of lymphocytes, and the fatty changes in liver cells are typical characteristic after the induction of cirrhosis^(5, 33).

The two experimental models used in this study reinforce and confirm the onset of liver damage and cirrhosis of the liver with consequent changes in gas exchange. The BDL model is most often used to evaluate the Hepatopulmonary Syndrome because it shows changes that are typical characteristic of the disease. The CCl₄ model seems to be promising for the study of portopulmonary hypertension (PPH) as well as cirrhosis and changes the thickness and diameter of the pulmonary artery wall. More studies are needed to assess and investigate the specific mechanisms involved in these changes.

CONCLUSION

The model of hepatic cirrhosis caused by CCl₄ modifies the gas exchange, increases the thickness of the pulmonary artery and reduces its diameter. The CCl₄ model is a promising model for the study of PPH. The BDL model also causes alterations in the lung and liver, reinforcing that is a reliable model of HPS.

ACKNOWLEDGEMENTS

Hospital Clinics of Porto Alegre – HCPA.
Fund research incentive events of Hospital Clinics of Porto Alegre - FIPE/HCPA.

Ferrari RS, Tieppo M, Rosa DP, Forgiarini Jr LA, Dias AS, Marroni NP. Alterações hepáticas e pulmonares decorrentes da indução de cirrose em dois modelos experimentais. *Arq Gastroenterol.* 2013,50(3):208-13.

RESUMO - Objetivo - Avaliar as alterações pulmonares e hepáticas em dois modelos experimentais de cirrose hepática pelo uso de tetracloreto de carbono intraperitoneal (CCl₄) e ligadura de ducto biliar. **Métodos** - Vinte e quatro ratos machos Wistar foram divididos em grupo controle (CO) e experimental (EX). Foram avaliadas as transaminases hepáticas (AST, ALT, FA), gasometria arterial (PaO₂, PCO₂ e SatO₂) e a lipoperoxidação através de TBARS (substâncias que reagem ao ácido tiobarbitúrico) e por quimiluminescência. Também foi avaliada a atividade antioxidante da enzima superóxido dismutase e a histologia do tecido pulmonar e hepático. **Resultados** - Nas enzimas hepáticas (AST, ALT e FA), bem como na PaO₂ foram observadas diferenças significativas ($P \leq 0,05$) entre os grupos CO vs EX em ambos modelos. Os níveis de TBARS, quimiluminescência e a atividade da enzima superóxido dismutase encontram-se aumentados nos grupos CCl₄ e ligadura de ducto biliar: CO vs EX ($P \leq 0,05$). Na análise histológica do pulmão observamos um aumento na espessura da parede da artéria pulmonar e uma redução no diâmetro no modelo CCl₄; CO vs EX, e no modelo de ligadura de ducto biliar podemos observar uma redução da espessura e aumento no diâmetro da parede da artéria pulmonar. **Conclusão** - Ambos os modelos experimentais provocaram dano hepático, além de causar alterações na parede da artéria pulmonar contribuindo na redução das trocas gasosas.

DESCRIPTORIOS - Hepatopatias. Pneumopatias. Cirrose hepática experimental. Tetracloreto de Carbono, uso diagnóstico. Ducto colédoco, fisiopatologia. Modelos animais de doenças.

REFERENCES

1. Ahmed AF, Mahmoud MF, Ouf MA, El-Fathaah EA. Aminoguanidine potentiates the hepatoprotective effect of silymarin in CCL4 treated rats. *Ann Hepatol.* 2011;10:207-15.
2. Ali SI, Said MM, Hassan EK. Prophylactic and curative effects of purslane on bile duct ligation-induced hepatic fibrosis in albino rats. *Ann Hepatol.* 2011;10:340-346.
3. Amália PM, Possa MN, Augusto MC, Francisca LS. Quercetin prevents oxidative stress in cirrhotic rats. *Dig Dis Sci.* 2007;52:2616-21.
4. Blendis L, Wong F. Portopulmonary hypertension: an increasingly important complication of cirrhosis. *Gastroenterology.* 2003;125:622-4.
5. Bona S, Filippin LI, Di Naso FC, de David C, Valiatti B, Isoppo Schaub MI, Xavier RM, Marroni NP. Effect of Antioxidant Treatment on Fibrogenesis in Rats with Carbon Tetrachloride-Induced Cirrhosis. *ISRN Gastroenterol.* doi: 10.5402/2012/762920.
6. Buege JA, Aust SD. Microsomal lipid peroxidation. *Methods Enzymol.* 1978;52:302-10.
7. Cuevas MJ, Tieppo J, Marroni NP, Tuñón MJ, González-Gallego J. Suppression of amphiregulin/epidermal growth factor receptor signals contributes to the protective effects of quercetin in cirrhotic rats. *J Nutr.* 2011;141:1299-305.
8. Fallon MB. Mechanisms of Pulmonary Vascular Complications of Liver Disease Hepatopulmonary Syndrome. *J Clin Gastroenterol.* 2005;39:S138-42.
9. Fang HL, Lin WC. Lipid peroxidation products do not activate hepatic stellate cells. *Toxicology.* 2008;253:36-45.
10. Friedman SL. Mechanisms of hepatic fibrogenesis. *Gastroenterology.* 2008;134:1655-69.
11. Fujii T, Fuchs BC, Yamada S, Lauwers GY, Kulu Y, Goodwin JM, Lanuti M, Tanabe KK. Mouse model of carbon tetrachloride induced liver fibrosis: Histopathological changes and expression of CD133 and epidermal growth factor. *BMC Gastroenterology.* 2010;10:79.
12. Gonzalez Flecha B, Llesuy S, Boveris A. Hydroperoxide-initiated chemiluminescence: an assay for oxidative stress in biopsies of heart, liver, and muscle. *Free Radic Biol Med.* 1991;10:93-100.
13. Gonzalez-Gallego JAE. El hígado. Fisiopatología de las Hepatopatías. Madrid, Spain: McGraw-Hill-Interamericana; (Fundamentos de fisiopatología, edited by E. A. M. Cordero). 1998.
14. Kountouras J, Billing BH, Scheuer PJ. Prolonged bile duct obstruction: a new experimental model for cirrhotoses in the rat. *Br J Exp Pathol.* 1984;65:305-11.
15. Krowka MJ, Cortese DA. Hepatopulmonary syndrome: an evolving perspective in the era of liver transplantation. *Hepatology.* 1990;11:138-42.
16. Krowka MJ. Hepatopulmonary syndromes. *Gut.* 2000;46:1-4.
17. Milstersteiner A, Milstersteiner D, Pereira-Filho N, Frota AR, Ely PB, Zettler CG, Marroni CA, Marroni NP. Uso da quercetina a longo prazo em ratos cirróticos. *Acta Cir Bras.* 2003;18:232-7.
18. Misra HP, Fridovich I. The role of superoxide anion in the autoxidation of epinephrine and a simple assay for superoxide dismutase. *J Biol Chem.* 1972;247:3170-5.
19. Miyazaki T, Karube M, Matsuzaki Y, Ikegami T, Doy M, Tanaka N, Bouscarel B. Taurine inhibits oxidative damage and prevents fibrosis in carbon tetrachloride-induced hepatic fibrosis. *J Hepatol.* 2005;43:117-25.
20. Pastor A, Collado PS, Almar M, Gonzalez-Gallego J. Antioxidant enzyme status in biliary obstructed rats: effects of N-acetylcysteine. *Journal of Hepatology.* 1997;27:363-70.
21. Pavanato A, Tuñón MJ, Sánchez-Campos S, Marroni CA, Llesuy S, González-Gallego J, Marroni N. Effects of quercetin on liver damage in rats with carbon tetrachloride-induced cirrhosis. *Dig Dis Sci.* 2003;48:824-9.
22. Pérez Tamayo R. Is cirrhosis of the liver experimentally produced by CCl₄ and adequate model of human cirrhosis? *Hepatology.* 1983;3:112-20.
23. Rabiller A, Nunes H, Lebrec D, Tazi KA, Wartski M, Dulmet E, Libert JM, Mougeot C, Moreau R, Mazmanian M, Humbert M, Hervé P. Prevention of gram-negative translocation reduces the severity of hepatopulmonary syndrome. *Am J Respir Crit Care Med.* 2002;166:514-7.
24. Sangameswaran B, Reddy TC, Jayakar B. Hepatoprotective Effect of Leaf Extracts of *Andrographis lineata* Nees on Liver Damage Caused by Carbon Tetrachloride in Rats. *Phytother.* 2008;22:124-6.
25. Schuppan D, Afdhal NH. Liver Cirrhosis. *Lancet.* 2008;371:838-51.
26. Silva Jr OC, Mazzetto SA, Souza MEJ, Picinato M, Sankarankutty AK. Obstrução biliar extra hepática. Modelos experimentais de pesquisa em cirurgia. São Paulo: Robe, 1998.
27. Tieppo J, Vercelino R, Dias AS, Marroni CA, Marroni N. Common bile duct ligation as a model of hepatopulmonary syndrome and oxidative stress. *Arq Gastroenterol.* 2005;42:244-8.
28. Tieppo J, Vercelino R, Dias AS, Silva Vaz MF, Silveira TR, Marroni CA, Marroni NP, Henriques JAP, Picada JN. Evaluation of the protective effects of quercetin in the hepatopulmonary syndrome. *Food and Chemical Toxicology.* 2007;7:1140-6.
29. Vercelino R, Tieppo J, Forgiarini Junior LA, Dias AS, Marroni CA, Marroni NP. [Experimental models for assessment of pulmonary alterations in hepatopulmonary syndrome]. *J Bras Pneumol.* 2008;34:453-60.
30. Vieira EK, Bona S, Di Naso FC, Porawski M, Marroni NP. Quercetin Treatment Ameliorates Systemic Oxidative Stress in Cirrhotic Rats. *ISRN Gastroenterology.* 2011;6.
31. Vieira EK, Bona S, Di Naso FC, Porawski M, Tieppo J, Marroni NP. Quercetin Treatment Ameliorates Systemic Oxidative Stress in Cirrhotic Rats. *ISRN Gastroenterol.* 2011;2011:1-6. doi: 10.5402/2011/604071.
32. Wang G, Shen H, Rajaraman G, Roberts MS, Gong Y, Jiang P, Burczynski F. Expression and antioxidant function of liver fatty acid binding protein in normal and bile-duct ligated rats. *Eur J Pharmacol.* 2007;560:61-8.
33. Yuan LP, Chen FH, Ling L, Bo H, Chen ZW, Li F, Zhong MM, Xia LJ. Protective effects of total flavonoids of *Bidens bipinnata* L. against carbon tetrachloride-induced liver fibrosis in rats. *J Pharm Pharmacol.* 2008;60:1393-402.
34. Zhang XJ, Katsuta Y, Akimoto T, Ohsuga M, Aramaki T, Takano T. Intrapulmonary vascular dilatation and nitric oxide in hypoxemic rats with chronic bile duct ligation. *J Hepatol.* 2003;39:724-30.

Received 11/9/2012.

Accepted 7/5/2013.